

---

**“Pattern of cervical lymph node metastasis  
and its association with clinico-pathological  
variables in primary mandibular gingivo-  
buccal sulcus squamous cell carcinoma”**

---

**Thesis submitted to**

**KLE ACADEMY OF HIGHER EDUCATION AND RESEARCH  
(Deemed -to -be -University)**

**[Declared as Deemed-to-be-University u/s 3 of the UGC Act, 1956 vide  
Govt. of India Notification No.F.9-19/2000-U.3 (A)]**

**Accredited ‘A’ Grade by NAAC (2<sup>nd</sup> Cycle)**

**Placed in Category ‘A’ by MHRD (GoI)**

***For the award of the degree of***



***Doctor of Philosophy***

**FACULTY OF DENTISTRY**

**(Oral and Maxillofacial Surgery)**

**By**

**Dr Sidramesh Muttagi MDS, FHNO**

**(Registration No: KLE/Ph.D/12-13/ DOUN12009)**

**Research Guide**

**Dr Ashok S Godhi MS, FRCS (Glas)**

**Former Principal, JNMC**

**Professor, Department of Surgery**

**KLE'S JAWAHARLAL NEHRU MEDICAL COLLEGE,  
BELAGAVI-590010**

---

**2019**

---

## UNDERTAKING

I, **Dr Sidramesh Muttagi** hereby declare that the information and the data mentioned in my thesis entitled “**Pattern of cervical lymph node metastasis and its association with clinico-pathological variables in primary mandibular gingivo-buccal sulcus squamous cell carcinoma**” belongs to me and is original.

I am aware of definition of plagiarism as detailed below:

- An act or instance of using or closely imitating the language and thoughts of another author without authorization and the representation of that author’s work as one’s own, as by not crediting the original author.
- A piece of writing or other work reflecting such unauthorized use or imitation.
- The deliberate or reckless representation of another’s words, thoughts or ideas as one’s own without attribution in connection with submission of academic work, whether graded or otherwise.

I hereby declare that the thesis prepared by me is original-one and does not involve plagiarism anywhere. In case at a later stage it is found that I have indulged in plagiarism, then I am solely responsible for the same and the Institution is at liberty to take any disciplinary action against me including cancellation of dissertation or any other penalties imposed by the University.

**Date:**

**Place:** Belagavi

**Dr Sidramesh Muttagi**

Ph.D Research Scholar

KAHER –Belagavi-10

# PLAGIARISM REPORT

**KLE**  
POWERING PROFESSIONALS  
0831-2444444

**KLE ACADEMY OF HIGHER EDUCATION AND RESEARCH**  
(Formerly known as KLE University)  
(Deemed-to-be-University established u/s 3 of the UGC Act, 1956)  
Accredited '**A**' Grade by NAAC (2<sup>nd</sup> Cycle) Placed in **Category 'A'** by MHRD (GoI)  
*JNMC Campus, Nehru Nagar, Belagavi-590 010, Karnataka State, India*  
FAX: 0831-2493777 Web: <http://www.kledeemeduniversity.edu.in> E-mail: [info@kledeemeduniversity.edu.in](mailto:info@kledeemeduniversity.edu.in)

Ref. No. KAHER/AA/19-20/D- 004

Date: 23<sup>rd</sup> September 2019


## Acceptance Letter

Sir,

The soft copy of Ph.D. research thesis of **Dr. Sidramesh Muttagi, Faculty of Dentistry** of KAHER, Belagavi had submitted for anti-plagiarism check at the office of the undersigned through "Turn-it-in" package. The scan has been carried out and the scanned output reveals a match percentage of **5%** which is within the acceptable limit of **10%**.

To obtain the comprehensive report of the plagiarism test, research scholar can send a mail to [diracademic@kledeemeduniversity.edu.in](mailto:diracademic@kledeemeduniversity.edu.in) along with the Registration Number, Name of the Scholar, Name of Guide/Co-guide and title of the thesis.



  
(Dr.) Daksha Dixit  
Director, Academic Affairs

To,

**Dr. Sidramesh Muttagi**  
Part-Time Ph.D. Scholar, 2012 Batch  
Faculty of Dentistry, KAHER,  
**Belagavi**

**KLE ACADEMY OF HIGHER EDUCATION AND RESEARCH**  
**(Deemed-to-be-University)**

[Declared as Deemed-to-be-University u/s 3 of the UGC Act, 1956 vide Govt. of India Notification No.F.9-19/2000-U.3 (A)]

**Accredited 'A' Grade by NAAC (2<sup>nd</sup> Cycle)**

**Placed in Category 'A' by MHRD (GoI)**



**Copyright Declaration**

We hereby declare that **KLE Academy of Higher Education and Research, Belagavi, Karnataka**, shall have the rights to preserve, use and disseminate this thesis in print or electronic format for academic/research purpose.

**Signature**

**Dr Sidramesh Muttagi**  
Ph.D Research scholar

**Place:** Belagavi

**Signature**

**Dr Ashok S Godhi** MS, FRCS  
Former Principal, JNMC  
Professor,  
Department of Surgery  
KLE'S Jawaharlal Nehru Medical  
College  
Belagavi

**©KLE ACADEMY OF HIGHER EDUCATION AND RESEARCH,  
BELAGAVI**

**KLE ACADEMY OF HIGHER EDUCATION AND RESEARCH  
(Deemed-to-be-University)**

[Declared as Deemed-to-be-University u/s 3 of the UGC Act, 1956 vide Govt. of India Notification No.F.9-19/2000-U.3 (A)]

**Accredited 'A' Grade by NAAC (2<sup>nd</sup> Cycle)  
Placed in Category 'A' by MHRD (GoI)**



***Declaration by the candidate***

I hereby declare that the thesis entitled “**Pattern of cervical lymph node metastasis and its association with clinico-pathological variables in primary mandibular gingivo-buccal sulcus squamous cell carcinoma**” is a bonafide and original research carried out by me under the guidance of **Dr Ashok S Godhi, former Principal, JNMC and Professor, Department of Surgery, KLE’S Jawaharlal Nehru Medical College, KAHER Belagavi**. The thesis or any part thereof has not formed the basis for the award of any degree/fellowship or similar title to any candidate of any University.

**Place:** Belagavi

**Date:**

**Signature**

**Dr Sidramesh Muttagi**  
Ph.D Research Scholar  
KAHER, Belagavi

**KLE ACADEMY OF HIGHER EDUCATION AND RESEARCH  
(Deemed-to-be-University)**

[Declared as Deemed-to-be-University u/s 3 of the UGC Act, 1956 vide Govt. of India Notification No.F.9-19/2000-U.3 (A)]

**Accredited 'A' Grade by NAAC (2<sup>nd</sup> Cycle)**

**Placed in Category 'A' by MHRD (GoI)**



**Certificate by the Dean**

This is to certify that the thesis entitled **“Pattern of cervical lymph node metastasis and its association with clinico-pathological variables in primary mandibular gingivo-buccal sulcus squamous cell carcinoma”** is a bonafide and genuine research carried out by **Dr Sidramesh Muttagi** under the guidance of **Dr Ashok S Godhi, former Principal JNMC and Professor, Department of Surgery, KLE’S Jawaharlal Nehru Medical College, KAHER Belagavi.**

**Place:** Belagavi

**Date:**

**Signature**

**Dr K. M. Keluskar** MDS, Ph.D  
Dean, Faculty of Dentistry  
KAHER, Belagavi-10

**KLE ACADEMY OF HIGHER EDUCATION AND RESEARCH**

**(Deemed-to-be-University)**

[Declared as Deemed-to-be-University u/s 3 of the UGC Act, 1956 vide Govt. of India Notification No.F.9-19/2000-U.3 (A)]

**Accredited 'A' Grade by NAAC (2<sup>nd</sup> Cycle)**

**Placed in Category 'A' by MHRD (GoI)**



**Certificate by the Guide**

This is to certify that the thesis entitled **“Pattern of cervical lymph node metastasis and its association with clinico-pathological variables in primary mandibular gingivo-buccal sulcus squamous cell carcinoma”** is a bonafide record of original research carried out by **Dr. Sidramesh Muttagi** for the award of degree of **DOCTOR OF PHILOSOPHY** in faculty of Dentistry (Oral and Maxillofacial Surgery) under my supervision and guidance.

**Place:** Belagavi

**Date:**

**Signature**

**Dr Ashok S Godhi** MS.FRCS, (Glas)

**Former Principal, JNMC  
Professor**

**Department of Surgery  
KLE'S Jawaharlal Nehru Medical College  
Belagavi- 590010**

## ACKNOWLEDGMENTS

*At the outset I would like to thank **Almighty** for always being by my side, bestowing me with strength and patience to successfully complete this work.*

अखण्डमण्डलाकारं व्याप्तं येन चराचरम् ।  
तत्पदं दर्शितं येन तस्मै श्रीगुरवे नमः ॥

***Guru** is the one who guide us to the supreme knowledge, that pervades all the living and non-living beings in this Universe. I salute such a **Guru**.*

*I am privileged to express my deep sense of gratitude to my respected teacher, and guide **Dr Ashok S Godhi**, former principal and Professor of Surgery, JNMC Belagavi, for his valuable and expert guidance, vehement personal interest, constant encouragement and constructive criticism with valuable suggestions for improvement, without whom this study would not have been possible. I sincerely thank you sir for believing in me and guiding my path when I was lost. I am blessed to be your student.*

*I consider it my utmost privilege and honor to express my sincere gratitude to my Guruji, **Dr B. R. Patil**, Chief surgical oncologist, **Karnataka Cancer Therapy and Research Institute**, Navanagar, Hubli, Karnataka, for his meticulous supervision and never-ending willingness to render generous help to me in carrying out this study. His immense knowledge and experience in the field of Head-Neck oncology and thought-provoking concepts have been my constant source of inspiration to do more. I sincerely thank you sir for not only guiding me, but for being beside me in every step. Following your footsteps, I aspire to improve on, to be a competent head-neck surgeon.*

*I extend my sincere thanks to Prof (Dr) Alka. D. Kale Principal, KLEVKIDS for her kind, unending help and support throughout the journey of this study tenure. She has been a constant source of inspiration, guidance and unending encouragement for me. Learning difficult concepts of pathology for a surgeon is made-easy by her teachings. I look forward to learn more under you madam.*

*I am extremely thankful to late **Padmashree Dr R. B Patil** FRCS (Eng& Edin), for his constant encouragement for research in head neck oncology and permitting me to carry out this research at the **Karnataka Cancer Therapy & Research Institute, Navanagar, Hubli.***

*I am thankful to **Dr Punya Angadi**, Professor, Department of Oral and Maxillofacial Pathology, for helping me to understand certain aspects of oral pathology essential for this study and helping me with the photographs. **Dr Seema Hallikerimath, Dr Veena Naik, Dr Deepa Mane** and all other faculty members including post-graduate students of the Department of Oral and Maxillofacial Pathology, KLEVKIDS, have generously helped me during grossing of the specimens leaving no room for any error. I sincerely thank them for their patience and time they offered me for successful completion of this study.*

*I express my sincere thanks to Prof (Dr) **N.K.Tyagi** Ph.D Professor and Head Department of Biostatistics, for making me understand the basics of biostatistics and guiding me in the statistical analysis of this study. I would like to acknowledge help rendered by **Dr S. B. Javali** Ph.D, department of Biostatistics, **USM-KLE** for guiding me during publications.*

*The **Fellows** (Dr Rachita, Dr Deepak and Dr Gaurav), **Observers** and **Nursing staff** in the department of Head Neck Surgical Oncology, **Karnataka Cancer***

*Therapy and Research Institute, Navanagar, Hubli, were enthusiastic in rendering their help in assisting me during surgical procedures and data. I thank them for their sincere help.*

*I would like to utilize this opportunity to thank Prof (Dr) **Jatin P Shah**, senior attending, Professor and Head, Department of Head Neck Surgery, **Memorial Sloan Kettering Cancer Center, New York, USA** for helping me to refine certain aspects in my study and giving me valuable suggestions with regards to my study during my visit as a trainee to his esteemed unit.*

*My heartfelt thanks to my friend and colleague **Dr Arati Neeli** for helping me with corrections. I thank my colleagues **Dr S. D Baliga, Dr Lingaraj Balihallimath, Dr Tejraj P Kale, Dr S. M. Kotrashetti, Dr. Sanjay Rao, Dr Vijaylaxmi Shettar, Dr Abishek Motimath, Dr Poorvi and Dr Snehalata** for helping me during my study. I thank all the **post graduate students** of the **Department Oral and Maxillofacial surgery** for their support and encouragement throughout this study. **Dr Shristi Deshpande**, my post-graduate student has been very helpful to me and deserves special thanks. I would also like to acknowledge the support rendered by Non-teaching staff of our department for successful completion of the study.*

*I would also like to thank the honorable Vice-Chancellor **Dr Vivek Saoji**, honorable Ex Vice-Chancellor **Dr Chandrakant Kokate**, Registrar **Dr V.D. Patil**, Director of Academic Affairs **Dr Daksha Dixit**, and **KLE Academy of Higher Education and Research** for providing facilities and giving me an opportunity to avail such a great teaching-learning experience. My sincere acknowledgements to our University for rendering financial help to participate in **IFHNOS congress** for my paper presentation in New York, USA.*

*My sincere acknowledgements to all the patients who volunteered in this study, without whom this study would never be completed.*

*I thank **Mr. Irappa. S. Mallapur** of Dental Library for helping me in editing. I thank **Mr. Anand, Mr. Manoj** and **Mr. Arun** of Anand Xerox Centre for printing and binding of the thesis.*

*A special thanks to my family. Words cannot express how grateful I am to **my mother**, and **my in-laws** for all the sacrifices they have made on my behalf. Your blessings were the reason I could reach this far. This research project would never be complete without the help and support of my beloved wife **Dr Roopali**. She always stood by my side and have been a constant source of encouragement in my research endeavors. Her valuable suggestions and help in research methodology have been a constant blessing for me.*

*A big thank you to my dear children, **Koushal** and **Manasvi** for always cheering me up, for being patient and always reminding me that I should complete my PhD work! My daughter Manasvi always admonished me for my lagging PhD work.*

**Date:**

**Dr Sidramesh Muttagi**

## **ABBREVIATIONS**

AJCC	American Joint Committee on Cancer
CECT	Contrast Enhanced Computed Tomography
CLN	Cervical Lymph Node(s)
CLNM	Cervical Lymph Node Metastasis
cN	Clinical Nodal Status
DFS	Disease Free Survival
ECS	Extra-Capsular Spread
FNAC	Fine Needle Aspiration Cytology
GBC	Gingivo-Buccal Complex
GTT	Gross Tumour Thickness
HD	Histological Differentiation
HNC	Head Neck Cancer
IJV	Internal Jugular Vein
L/R	Loco-regional
LN	Lymph Node
LNy	Lymph Node Yield
LVE	Lympho-Vascular Emboli
MRND	Modified Radical Neck Dissection
MSKCC	Memorial Sloan Kettering Cancer Center
ND	Neck Dissection
NuM	Nuclear Morphometry
OSMF	Oral Submucous Fibrosis

PET-CT	Positron Emission Tomogram- Computed Tomography
PMD	Potentially Malignant Disorders
PMMC	Pectoralis Major Myo-cutaneous
PNI	Perineural Invasion
pN	Pathological Nodal Status
QoL	Quality of Life
RCP	Royal College of Pathologists
RFS	Recurrence Free Survival
RND	Radical Neck Dissection
ROC	Receiver Operating Characteristic
SAN	Spinal Accessory Nerve
SCC	Squamous Cell Carcinoma
SCM	Sternocleidomastoid Muscle
SND	Selective Neck Dissection
SOND	Supra-Omohyoid Neck Dissection
SPECT	Single Photon Emission Computed Tomography
TTh	Tumour Thickness
USG	Ultra Sonography
WHO	World Health Organization

## ABSTRACT

**“Pattern of cervical lymph node metastasis and its association with clinico-pathological variables in primary mandibular gingivo-buccal sulcus squamous cell carcinoma”**

**Background:** Squamous cell carcinoma (SCC) of mandibular Gingivo-Buccal Complex (GBC) or “Indian Oral Cancer,” is a distinct cancer of oral cavity in the Indian subcontinent. Cervical lymph node metastasis (CLNM) is a validated prognostic factor in mandibular GBC-SCC like other subsites of oral SCC. CLNM in oral SCC is known to occur in a foreseeable manner, involving mainly level I, level II and to lesser extent level III nodes unlike tongue or floor-mouth SCC wherein, the CLNM tends to be extensive. The available guidelines for neck dissection (ND) in node-positive necks for oral SCC are based on western studies, which comprise more of tongue and floor-mouth SCC and lack patients with mandibular GBC-SCC. Also, the literature about accurate nodal staging in Indian patients with mandibular GBC-SCC is scanty with regards to adequacy of lymph-nodes to be harvested following ND. Furthermore, the extent of CLNM in advanced oral SCC is influenced by clinico-pathological factors that have to be identified for risk stratification with regards to decision making on the extent of ND in patients with mandibular GBC-SCC. This will help surgeons to practice oncologically safe ND for patients with high risk of extensive CLNM and contrarily to perform limited-extent ND in low risk patients, thus avoiding morbidities related to comprehensive ND.

**Aim and Objectives:** To study the metastatic involvement of cervical lymph-nodes (CLNs) at various levels in the neck from primary mandibular GBC-SCC and quantify the number of lymph-nodes harvested from comprehensive ND. To study the

contribution of clinico-pathological factors like T-size, histological differentiation (HD), infiltration of bone by the tumor, lympho-vascular tumor emboli (LVE) and perineural Invasion (PNI) in CLNM.

**Methodology:** Prospective observational study was conducted on 130 hospital-based patients with biopsy-confirmed, unilateral primary SCC of mandibular GBC. The patients presenting with operable, classical primary mandibular GBC-SCC, without any previous treatments, requiring level I to level V nodal clearance were included. Also, the patients requiring pectoralis major myo-cutaneous (PMMC) flap reconstruction at the primary site were included in this study. The need for sacrificing sternocleidomastoid muscle to facilitate inset of PMMC flap in these patients enabled us to study involvement of lymph-nodes at all the levels in the neck due to primary mandibular GBC-SCC. The patients' Clinical details like clinical presentation, tumor extent, bone infiltration, AJCC 2009 clinical stage, and pathological details like histologic differentiation (HD) on biopsy, bone invasion, LVE, PNI, number of nodes per level, number of metastatic nodes and extra-capsular spread (ECS) were noted. T-size and gross tumor thickness (GTT) were measured intraoperatively after tumor resection. The protocol for grossing was based on The Royal College of Pathologists, Standards and datasets for reporting head and neck cancers (December 2011).<sup>27</sup>

**Statistical Analysis:** descriptive analysis, Chi-square test, logistic regression and Receiver Operating Characteristic (ROC) curve were used for statistical analysis.

**Results:** Totally 3046 lymph-nodes were harvested and studied in 130 patients. On multivariate analysis, infiltration of masticator space, intra-operative T-size and GTT >1cm were significantly associated with multi-level CLNM including level IV and level V. CLNM involving level IV and level V was seen in only 15 (11%) cases and that involving tail parotid nodes was seen in 13 (10%) cases. Average number of

CLNs harvested by comprehensive ND in our patients with primary mandibular GBC-SCC was  $23.61 \pm 5.15$  and ranged from 14-37.

**Conclusion:** Level IB is common site of CLNM. Comprehensive ND (level I-level V) yields an average of 23 nodes in Indian patients with primary mandibular GBC-SCC. GTT of over 1cm, locally advanced T-stage and infiltration of masticator space are significant predictors of multi-level CLNM in patients with primary mandibular GBC-SCC. The prevalence of nodal metastasis at level IV, level V and tail parotid nodes is approximately 11% even in clinically node-positive necks in primary mandibular GBC-SCC. When the tumor is not locally advanced, ECS is negative and GTT <1cm these levels of CLNs may not be dissected during ND. Further studies with higher number of patients are required to validate the findings of this study.

## TABLE OF CONTENTS

<b>SL.NO</b>	<b>TITLE</b>	<b>PAGE NO</b>
<b>1.</b>	<b>INTRODUCTION</b>	<b>1-5</b>
<b>2.</b>	<b>REVIEW OF LITERATURE</b>	<b>6-28</b>
<b>3.</b>	<b>JUSTIFICATION</b>	<b>29-31</b>
<b>4.</b>	<b>AIM AND OBJECTIVES</b>	<b>32</b>
<b>5.</b>	<b>MATERIALS AND METHODS</b>	<b>33-43</b>
<b>6.</b>	<b>PHOTOGRAPHS</b>	<b>44-63</b>
<b>7.</b>	<b>RESULT</b>	<b>64-90</b>
<b>8.</b>	<b>DISCUSSION</b>	<b>91-114</b>
<b>9.</b>	<b>CONCLUSION</b>	<b>115-116</b>
<b>10.</b>	<b>SUMMARY</b>	<b>117-120</b>
<b>11.</b>	<b>BIBILOGRAPHY</b>	<b>121-147</b>
<b>12.</b>	<b>ANNEXURES</b>	<b>148-168</b>

## LIST OF TABLES

<b>Table No.</b>	<b>Legend</b>	<b>Page No</b>
<b>1.</b>	<b>Linen Suture ligatures and their number of cut ends representing nodal levels.</b>	<b>36</b>
<b>2.</b>	<b>Format for data collection with regards to nodal characteristics.</b>	<b>39</b>
<b>3.</b>	<b>Guidelines of identifying histological front and Histologic Differentiation.</b>	<b>40</b>
<b>4.</b>	<b>Demographic details of patients.</b>	<b>68</b>
<b>5.</b>	<b>Laterality of the tumor in 130 patients with primary mandibular GBC-SCC.</b>	<b>68</b>
<b>6.</b>	<b>Details of patient's deleterious habits.</b>	<b>69</b>
<b>7.</b>	<b>Clinical factors of 130 study patients.</b>	<b>70</b>
<b>8</b>	<b>Intra-operative factors measured during surgery in 130 study patients.</b>	<b>71</b>
<b>9.</b>	<b>Pathological factors of 130 study patients.</b>	<b>72</b>
<b>10.</b>	<b>Clinical and pathological nodal status in 130 study subjects.</b>	<b>72</b>
<b>11.</b>	<b>Demographic details and their association with level of positive nodes.</b>	<b>73</b>
<b>12.</b>	<b>Laterality of the tumor and its association with level of positive node.</b>	<b>73</b>
<b>13.</b>	<b>Habits and their association with level of positive nodes.</b>	<b>74</b>

<b>14.</b>	<b>Potentially Malignant Disorders and their association with level of positive nodes.</b>	<b>75</b>
<b>15.</b>	<b>Clinical factors and their association with level of positive nodes.</b>	<b>76</b>
<b>16.</b>	<b>Clinical nodal status and level of positive nodes in N0, early and advanced CLNM</b>	<b>77</b>
<b>17.</b>	<b>Pathological factors and their association with level of positive node.</b>	<b>77</b>
<b>18.</b>	<b>Intra-operative factors and level of positive node.</b>	<b>78</b>
<b>19.</b>	<b>Details of surgery in 130 patients with primary mandibular GBC-SCC.</b>	<b>78</b>
<b>20.</b>	<b>Results of step-wise logistic regression for studying the association of clinico-pathological factors (independent variables) and level of positive node (dependent variable).</b>	<b>79</b>
<b>21.</b>	<b>Results of ROC test for studying the association of clinico-pathological factors (independent variables) and level of positive node (dependent variable).</b>	<b>80</b>
<b>22.</b>	<b>Distribution and reference range of nodes at each level in 130 patients with primary mandibular GBC-SCC.</b>	<b>81</b>
<b>23.</b>	<b>the status of tail parotid nodes in 130 patients with primary mandibular GBC-SCC.</b>	<b>81</b>
<b>24.</b>	<b>Details of Lymph node yield (LNY) in 130 patients with primary mandibular GBC-SCC.</b>	<b>82</b>

## LIST OF GRAPHS

Graph No	Legends	Page No
1.	Distribution of the study subjects according to age	83
2.	Distribution of study subjects according to gender.	83
3.	Side of the tumor.	84
4.	Adverse Habits present in the study subjects.	84
5.	Duration of the adverse habits	85
6	Distribution of various precancerous lesions and conditions among study subjects	85
7.	Distribution of the study subjects according to histological differentiation of the tumors	86
8.	Distribution of study subjects according to tumor size	86
9.	Distribution of study subjects according to involvement of masticator space	87
10.	Distribution of the study subjects according to clinic-pathological bone erosion	87
11.	Distribution of the study subjects according to Gross Tumor Thickness	88
12.	Distribution of the lympho-vascular emboli among the study subjects.	88
13.	Distribution of perineural invasion among the study subjects	89
14.	Percentage of N0, single and multi-level node positivity among study subjects	89
15.	Percentage distribution of 3040 nodes at various nodal levels in the neck	90

## LIST OF PHOTOGRAPHS

Sl.no	Legends	Page No
<b>1.</b>	<b>Structure of a lymph-node.</b>	<b>44</b>
<b>2.</b>	<b>Distribution of regional lymph nodes in humans.</b>	<b>44</b>
<b>3.</b>	<b>Normal GBC.</b>	<b>45</b>
<b>4A</b>	<b>Typical SCC of Mandibular GBC included in the study.</b>	<b>46</b>
<b>4B</b>	<b>Typical SCC of Mandibular GBC included in the study.</b>	<b>46</b>
<b>5A</b>	<b>Suspected gross bone erosion clinically in a patient with Mandibular GBC- SCC</b>	<b>47</b>
<b>5B</b>	<b>Gross bone erosion confirmed by Contrast Enhanced CT images.</b>	<b>47</b>
<b>6A</b>	<b>A patient with trismus and skin infiltration by primary GBC-SCC.</b>	<b>48</b>
<b>6B</b>	<b>A patient with trismus and skin infiltration by primary GBC-SCC.</b>	<b>48</b>
<b>7A</b>	<b>A patient (XYZ) with left mandibular GBC-SCC.</b>	<b>49</b>
<b>7B</b>	<b>Palpable left level IB node</b>	<b>49</b>
<b>7C</b>	<b>Node positivity of left level IB in patient XYZ confirmed by CECT imaging</b>	<b>49</b>
<b>8A</b>	<b>A patient (ABC) with SCC of left mandibular GBC-SCC</b>	<b>50</b>
<b>8B</b>	<b>Neck incisions for level I-V clearance and palpable left IB node in patient ABC</b>	<b>50</b>
<b>9A</b>	<b>Defining the limits of ND field and nodal levels</b>	<b>51</b>
<b>9B</b>	<b>Preparing to dissect level VA and VB nodes with spinal accessory nerve under vision (Haemostat pointing at level VB node)</b>	<b>51</b>

<b>10</b>	<b>Lower end of SCM muscle sacrificed and level IV nodes being dissected from their territory with suture ligatures denoting their identity.</b>	<b>52</b>
<b>11</b>	<b>Dissection of other nodal levels.</b>	<b>53</b>
<b>12 A</b>	<b>Identification of tail parotid nodes</b>	<b>53</b>
<b>12 B</b>	<b>Tail parotid nodes overlying posterior digastric muscle along the exit of retromandibular vein.</b>	<b>54</b>
<b>13</b>	<b>Completion of en-block MND-II with resection of tumor</b>	<b>54</b>
<b>14 A</b>	<b>Measurement of T- length</b>	<b>55</b>
<b>14 B</b>	<b>T-length measured 2.3 cm.</b>	<b>55</b>
<b>15 A</b>	<b>T-breadth measurement</b>	<b>56</b>
<b>15 B</b>	<b>T-breadth measured 1.4cm</b>	<b>56</b>
<b>16 A</b>	<b>Measurement of GTT- black silk sutures used to ensure measurement between fixed points</b>	<b>57</b>
<b>16 B</b>	<b>GTT measured 0.9 cm</b>	<b>57</b>
<b>17</b>	<b>Orientation of specimen and identification of nodal levels</b>	<b>58</b>
<b>18</b>	<b>Separation of all nodal levels and primary tumour with level IB nodes</b>	<b>58</b>
<b>19A</b>	<b>Harvest of nodes from individual levels 48 hours after 10% buffered formalin fixation</b>	<b>59</b>
<b>19B</b>	<b>Harvest of nodes from individual levels 48 hours after 10% buffered formalin fixation</b>	<b>59</b>
<b>20</b>	<b>Completion of node harvesting from individual nodal levels with number of nodes harvested from each level</b>	<b>59</b>
<b>21 A</b>	<b>Gross bone erosion by GBC-SCC</b>	<b>60</b>
<b>21 B</b>	<b>Gross bone erosion evident during grossing of the specimen after 48 hours of 10% buffered formalin fixation.</b>	<b>60</b>

<b>22 A</b>	<b>Extra-capsular spread in a patient MNO</b>	<b>61</b>
<b>22 B</b>	<b>ECS in IB node during grossing evident in histopathological section in patient MNO</b>	<b>61</b>
<b>22 C</b>	<b>ECS in IB node during grossing evident in histopathological section in patient MNO</b>	<b>61</b>
<b>23.</b>	<b>Peri-neural invasion</b>	<b>62</b>
<b>24.</b>	<b>Well differentiated tumour with advancing front showing moderate differentiation</b>	<b>62</b>
<b>25.</b>	<b>Failure at tail parotid region after therapy for GBC-SCC – such failures seen in our previous cases promoted us to include tail parotid nodes in this study</b>	<b>63</b>
<b>26</b>	<b>The ratio of number of positive nodes (colored fonts) and number of nodes harvested from each nodal level (LNR) in 130 patients with primary mandibular GBC-SCC.</b>	<b>80</b>

## INTRODUCTION

Carcinoma of lip and oral cavity is third largest cancer in the Indian subcontinent, with approximately 200,000 (10.4%) new cases diagnosed in the year 2018 as per the GLOBOCAN data.<sup>1</sup> It is the second largest cancer in males in India that affected over 92,000 male population in the year 2018.<sup>1</sup> The high prevalence of risk factors like chewing tobacco and /or betel nut, smoking or betel-quid chewing and consumption of alcohol in the Indian population contributes to higher incidence of oral cancer.<sup>3</sup>

Among the various sub-sites of oral cavity, the carcinoma of Gingivo-buccal complex (GBC) forms a distinguished subsite that is affected by oral squamous cell carcinoma (SCC) in India and some parts of Asia due to abuse of chewable tobacco products, arecanut and betel quid.<sup>3-5</sup> Placement of the tobacco products or betel quid in the mandibular buccal sulcus by tobacco abusers has shown to promote this type of cancer. Therefore, this type of cancer is popularly known as “Indian Oral Cancer.”<sup>6,7</sup>

Anatomically, the mandibular GBC is a distinct area in oral cavity that is bounded laterally by buccal mucosa, mandibular buccal sulcus and oral-commissure anteriorly.<sup>6</sup> Posteriorly there is retro-molar triangle and pterygo-mandibular raphe and superiorly the upper buccal sulcus. On the medial side the buccal gingiva of mandible and mandibular dento-alveolar complex are present<sup>6</sup> (**Photograph 3**). SCC arising in this region can involve buccal mucosa and retro-molar triangle to variable depths, at times infiltrating into the overlying buccinator muscle and skin of the cheek, can extend to upper buccal sulcus superiorly and to oral-commissure anteriorly<sup>6, 7</sup> (**Photograph 4A and 4B**). The tumor can infiltrate bone at the medial dento-alveolar complex of the mandible, depending on dentulous or edentulous status and integrity

of periosteum of the mandible (**Photograph 5A and 5B**). Posteriorly the tumor can infiltrate into masticatory muscles, especially masseter or medial pterygoid resulting in trismus<sup>8,9</sup> (**Photograph 6A and 6B**)

The lymph from GBC drains primarily into the submandibular and submental group of lymph- nodes, followed by the lymph-nodes present in the uppermost region of the internal jugular vein which are called “Jugulo-diagastric” nodes.<sup>6,7</sup> These lymph-nodes are closely associated with spinal accessory nerve (eleventh cranial nerve) and are labelled as level II node group.<sup>6</sup>

In comparison to Western data with regards to the oral subsite of SCC, the oral tongue, floor-mouth and oropharynx are more common subsites of oral SCC in the West.<sup>10-14</sup> The buccal or mandibular GBC-SCC account for less than 10% in the West whereas, they are found to be five-folds higher in India, accounting for over 50%.<sup>10</sup> The mandibular GBC-SCC is even common in Indian immigrants to various parts of the world.<sup>15-17</sup>

Like SCC affecting other subsites of oral cavity, cervical lymph-node metastasis (CLNM) is a most important and reliable factor that determines prognosis in these patients.<sup>6, 8,18</sup> The presence of CLNM is known to reduce the survival to less than 50% in patients with oral cancer. Therefore, dissection of lymph-nodes forms a fundamental aspect in the absolute management of oral SCC.<sup>18,19</sup> The neck dissection (ND) essentially involves surgical removal of lymph-nodes affected or at risk of being affected by metastatic disease.<sup>20-22</sup> The CLNM in oral SCC is known to occur in foreseeable manner as shown by previous studies and are often known to involve level I and level II nodes followed by level-III nodes.<sup>23-25</sup> However, when large scale studies comprising of isolated buccal or mandibular GBC-SCC patients are

considered, the CLNM in these cases is found to occur with a similar predictability, affecting levels I and II commonly (40%-100%), with level III being affected in less than 8% cases and level IV and V being the least affected (less than 3%).<sup>7, 25</sup> The CLNM by-passing the levels I or II to affect levels III-V which is commonly seen in tongue and floor-mouth SCC due to their closer proximity to lymphatics, rarely occurs in GBC or buccal SCC.<sup>27, 28</sup>

The regional recurrence in mandibular GBC-SCC is known to occur in the range of 7.5-20% after comprehensive therapy, which is less in comparison to tongue or floor-mouth SCC. Also, the SCC of oral tongue or floor mouth are known to have higher prevalence of occult CLNM and can commonly involve nodal levels at level II to level IV.<sup>7, 26, 29</sup> On the contrary, mandibular GBC-SCC has a tendency to cause local tissue destruction and higher incidence of occult metastasis over 25% are seen in patients presenting with locally advanced stage.<sup>26, 30</sup> Additionally, the occult CLNM in mandibular GBC-SCC is often confined to level I and level III lymph nodes.<sup>7</sup>

The current guidelines in decision making for ND in patients with node-positive necks are derived from Western literature which, unlike Indian patient's scenario, are based on patients with tongue and floor-mouth SCC. Most of the Western studies have grouped all oral subsites into one major group without demarcating a specific and single anatomical territory. Therefore, the application of ND concept that is based on unspecified oral subsites or that proposed for tongue or floor mouth SCC cannot be extrapolated to Indian Oral Cancer. Also, the number of lymph-nodes that have to be harvested following ND in Indian patients with mandibular GBC-SCC for accurate nodal staging has never been established so far,

although this is well established for the cancers of stomach, colo-rectum, oesophagus, and breast.<sup>31-34</sup>

The possibility of distinct CLNM in Indian patients with GBC- SCC needs to be thoroughly studied to provide guidelines for modifications in the ND procedures, in order to practice oncologically safe surgery with less morbid outcomes.

Several clinico-pathological factors contribute to CLNM and predict prognosis in patient with oral SCC. These include histologic differentiation, tumor thickness, tumor size, lympho-vascular invasion, peri-neural spread and extra-capsular spread of tumor in neck node.<sup>35,36</sup> Studying the association of these factors in mandibular GBC- SCC with CLNM is of paramount importance in order to arrive at a consensus on identification of high-risk patients that require aggressive ND and adjuvant therapy for optimizing disease control. On the contrary, patients with absence of high risks factors for CLNM can benefit by undergoing less morbid surgery and better quality of life (QoL).

Although, intra-operative frozen section can help in determining the node-positivity and ND can be modified based on the frozen report, this facility is not widely available, requires advanced equipment and expertise and increases treatment cost to the patient.<sup>37</sup> Therefore, a frugal method that intraoperatively guides the surgeon in decision making on extent of ND in patients with mandibular GBC- SCC, based on reliable clinical parameters is much needed in developing countries, given the large volume of patients and paucity of expertise.

This study was designed solely on patients diagnosed with lateralized mandibular GBC-SCC, to assess the extent of CLNM in these patients, establish the lymph node yield (LNY) and optimal count of lymph-nodes to be harvested for adequacy of nodal staging. This study also evaluates the association of clinico-pathological factors namely histological differentiation (HD), gross tumor thickness (GTT), tumor size, lympho-vascular emboli (LVE) and peri-neural invasion (PNI) with CLNM in these patients.

## REVIEW OF LITERATURE

The lymph, lymph-vessels including capillaries, lymph nodes, diffuse lymphoid tissues in addition to major lymphoid organs and bone marrow form the lymphatic system.<sup>1</sup>

The tissue fluid left behind by the venous system is carried into circulation by lymphatic vessels and the lymph-nodes come in between the lymphatic vessels before the lymph is deposited into the venous circulation.<sup>38</sup>

Lymph-nodes are rounded, nodule like structures often covered by a capsule and have smooth outer surface. The inner surface differs from the outer surface, in that it has an indentation which is called hilum. This hilum forms an area where the lymphatic vessels either pass into or leave the lymph-node. Normally the size of lymph-nodes when they are not challenged by an insult varies from 2 mm to 20 mm.<sup>39</sup> A schematic picture (**Figure 1**) depicts the structure of a normal lymph node.

Normally, when a cut section of lymph-node is grossly examined, it shows densely accumulated whitish material which is formed due to collection of lymphoid tissue.<sup>40</sup> On microscopic examination using light microscopy, the lymph-node shows lymphatic lobules and lymph filled sinuses covered by a true capsule which is made of collagen and elastin. Apart from this, three distinct areas can be appreciated in a lymph-node namely: outer cortical areas that is, B-cell rich zone, area around the outer cortex, that is para-cortical area which is rich in T-cells and lastly the medullary area that has sinuses.<sup>1, 40</sup> The connective tissue of the capsule also forms trabeculae in the lymph-nodes. The outflowing lymph normally has more lymphocytes.

The supporting structure within a lymph-node is composed of networking elastin and reticular fibres, in addition to leucocytes with predominant lymphocytes.<sup>38</sup> <sup>41</sup>The lymphocytes are closely packed similar to follicles in the cortex. This supporting system is called reticular network, which permits transfer of material and blood through endothelial venules, provides factors for growth, activation and maturity of cells apart from provision of surface for adhesion of immune cells.<sup>41-43</sup> The number and content of follicles depend on the activity of antigenic influence. In response to presence of an antigen, a germinal center can form. A track like structure lined with endothelial cells and supporting fibro-reticular cells which transfers lymph is called lymph sinus.<sup>43</sup> There are two such distinct sinuses: cortical sinus and medullary sinus. These sinuses are interconnected through trabeculae. The lymph after flowing through the medullary sinuses, drains into efferent vessels.<sup>43</sup> The hilum is concave surface on the lymph-node and it has relatively thick reticular structure that attaches it to efferent channel. The lymph exits the lymph-node from this channel.<sup>43</sup>

**Cortex:**

The flow of lymph occurs in a lymph-node in an orderly manner, starting from the subcapsular sinuses to trabecular sinuses, reaching medullary sinuses. The most peripheral region of the cortex shows the presence of follicles that are dominated by B-lymphocytes.<sup>42</sup> These follicles are sensitive to an antigenic insult and form germinal centers in response to antigens. The innermost region of the cortex is dominated by T-lymphocytes. Apart from this, the T- lymphocytes are predominant cells in a region known as para-cortical area. The cells like dendritic cells are also seen here.<sup>44</sup>

**Medulla:**

The main components of the medullary region include the medullary cords and medullary sinuses. The cord like arrangement of lymphatic cells contains plasma cells, B-lymphocytes and macrophages.<sup>44</sup> In contrast to the medullary cords, the medullary sinuses show spatial arrangement and contain specialized cells called histiocytes (stagnant macrophages) and reticular cells. The other components in the medulla include vascular structures, cordal and sinusoidal structures and antibodies involved in secretion of plasma cells.<sup>38,44</sup>

**Shape and size of lymph-node in Humans:**

The Lymph-nodes are fabiform in shape and their size can vary from few millimeters to 2 cm in length.<sup>44</sup> The size of a lymph-node increases in response to inflammatory conditions, malignant disorders or infections that affect the region of drainage. The discrepancy resulting from intensified ingress of lymphocytes into a lymph-node from blood and decreased exit from it, in response to inflammation is known to cause lymph-node enlargement.<sup>44</sup> The increased activity and multiplication of lymphocytes can also contribute to enlargement of lymph-node. At times an enlarged lymph-node may fail to regress in size after infection subsides.

**Circulation of lymph:**

The pathway of circulation of the lymph begins from its entry into the lymph-node from afferent vessels to reach sub-capsular sinus, followed by trabecular and medullary sinuses.<sup>41,43</sup> The phagocytes line across this passage to filter the foreign bodies from the circulating lymph. There is a dense looping of medullary sinus close

the hilum where the lymph exits the node through the efferent channel traversing to reach the subclavian vein.

The human lymph-nodes are distributed as clusters in the axilla, abdomen, neck, groin and chest as shown in **figure 2**. There are approximately 500-600 lymph-nodes in an average human body.<sup>38,44</sup>

**Morphologic aspects of human lymph-nodes and its application in pathologic interpretation:**

The human lymph-nodes are known to resemble rat and other eight mammalian species. The following factors are shown to influence the interpretation of a particular lymph-node section:

1. Larger the node greater is its compartmentalization due to irregular septae arising from the outer capsule.<sup>45</sup>
2. Due to non-uniformity of the compartmental region the structural components can appear variable in morphology, depending on the cutting angle.<sup>45</sup>
3. The diversity in the lymphoid tissue content in the standard tissue section of the lymph-node is seen to have ill-defined outline.<sup>46</sup>
4. The smallest lymph-nodes are uni-compartmental and have one afferent lymphatic vessel whereas, in larger organs the number of compartments is equivalent to either the number of afferent vessels or their terminal branches, depending on the size.<sup>47,48</sup>
5. The outermost cortex and sub-sinusal layer can appear thinned out and stretched in larger lymph-nodes.<sup>49</sup>

6. The deep cortical layer is semispherical and lies above the lymphatic opening and is less appreciated in the sections, in order to get accurate assessment of a pathological node.<sup>50-53</sup>
7. The high endothelial-venules are specialized vascular structures present inside the lymphoid organs that are involved in the recruitment of blood cells. They exist in extra-follicular region of the outer cortex and go down into the outer aspect deep cortex and terminate in venules on entering the medullary cordal region.<sup>53, 54</sup>

### **Surgical Anatomy of the Cervical Lymph-Nodes (CLNS)**

To specifically label a particular group of lymph-nodes with respect to the areas of their primary drainage and establish a common language between surgeons and pathologists, the head-neck department of the Memorial Sloan Kettering Cancer Centre (MSKCC), New York, USA<sup>55, 56</sup> has classified the CLNS from Levels I through level VII. The levels VI and VII are beyond the scope of oral cancer and will not be included here.

The head-neck department at MSKCC has described the five nodal groups.<sup>55, 56</sup> The intent of this levelling was to provide an accepted mode of referral among surgeons and pathologists. Also, there was a need for a consistent, easy reproducible and user-friendly way for delineating CLNS. The detailed anatomy of the CLNS is described in figures1-4.

**Investigative modalities for evaluation of cervical Lymph-nodes in head-neck cancer (HNC):**

The CLNM is a single most important independent prognostic factor in HNC. Evaluation of CLNM in a patient diagnosed with oral SCC is most important for staging, planning of curative and adjuvant therapy, and determining the prognosis.

**Role of ultrasonography (USG)**

The use of USG in investigating CLNS is well established in the literature<sup>57-59</sup>. The probe sensitivity of 10-14MHz is effective in diagnosis of CLNM. Currently several modifications of USG have been used like serial USG examinations and use of triplex USG.<sup>59-61</sup>

When USG was compared for its sensitivity, specificity, positive and negative predictive value and accuracy, with clinical palpation of CLNS, the values for USG were approximately 85%, 90%, 91%, 80% and 87% whereas those for clinical palpation were 69%, 87%, 90%, 58% and 75%.<sup>61, 62</sup>

The criteria for diagnosis of malignant cervical lymphadenopathy using USG include: size of the lymph-nodes, shape, L/W ratio, status of fatty hilum, central necrosis, enhanced pericapsular vascularity and violation of the capsular lining, suggesting extra-capsular spread (ECS).<sup>63</sup>

The size criteria for pathological level I lymphadenopathy has been suggested to be 1.5-2 cm and that for level II as 2cms. In other regions of neck, lymph-nodes over 2cm in size are considered positive for metastasis.<sup>64</sup>

Other major role of USG in HNC is its application in USG guided Fine Needle Aspiration Cytology (FNAC).<sup>65</sup> This has improved the accuracy of FNAC in detecting occult CLNM. A study comparing the efficacy of USG alone and USG guided FNAC in detecting occult CLNM showed that with USG alone, the accuracy never exceeded over seventy percent. When USG was used in performing FNAC, the accuracy improved over 89% with sensitivity of 75% and specificity of 100%. Currently, this modality is validated in assessment of CLNM in follow up of N-0 patients treated for oral SCC and neck being observed.<sup>65,66</sup>

However, the lack of accuracy in detecting node-positivity when nodal size is less than 1cm and failure to detect lymph-node involvement in deeper areas of the neck, especially when the area of assessment is deep to bony structures, are major shortcomings of USG.<sup>66</sup>

#### **Role of CT scan and MRI:**

The assessment of primary tumor and the neck nodes is major factor in GBS-SCC.<sup>67</sup> The assessment of primary tumor is done to determine the clinical extent, tumor thickness and infiltration into tissue spaces and bone.<sup>68</sup> The coronal CT images with puffed-cheek technique is well-established in assessment of primary tumor.<sup>69</sup> Cross-sectional methods are useful and add to the specificity and sensitivity of clinical examination of CLNS that are involved by malignancy. This technique is based on cross-sectional diameter of the lymph-nodes and internal diameter changes in the lymph-nodes.<sup>70</sup> Several studies have been done to investigate the usefulness of imaging modalities namely panoramic view (OPG), CT scans, MRI, Denta-scan and Single-photon emission computed tomography (SPECT) to evaluate infiltration of GBS-SCC in the mandible.<sup>71-80</sup> Some of these studies have also compared clinical and

radiological evidence of infiltration into mandible on final histopathological examination of the tumour.<sup>75, 76</sup> Among the several modalities, contrast enhanced computed tomographic (CECT) scans were seen to have specificity of 87% whereas, MRI and SPECT showed higher sensitivity, in the range of 96%-97%.<sup>76, 77, 79</sup> In a study, mandibular invasion was over-valued by MRI, with higher rates of inferior alveolar canal erosion.<sup>79</sup> However, the evaluation of perineural invasion is more efficient using MRI, which appears as over-enhancement of foraminae or reduced density of fat.<sup>79</sup>

When CT scan and MRI were compared for their efficacy in evaluating CLNM in mandibular GBS-SCC, the specificity and sensitivity were in the ranges of 55%-95% and 39%-96% respectively for CT and 64%-92%, 40-81% respectively for MRI.<sup>79, 80</sup> Central necrosis is often a hallmark of malignancy within lymph-nodes. In the absence of central necrosis, especially in a homogenous node, the size criteria considering the maximum lengthways diameter and minimal cross-wise diameter are helpful in identifying a metastatic node.<sup>81</sup> The presence of ECS in the lymph-nodes is also an important determinant in defining the prognosis and need for adjuvant therapy and MR imaging is a reliable modality in detecting it.<sup>82</sup> In addition to clinical examination, presence of ECS can be established preoperatively using any of the available imaging modalities and establishing operability of neck node on MR imaging is most validated.<sup>82, 83</sup>

### **Role of Positron Emission Tomograms- Computed Tomography (PET-CT) in GBS -SCC:**

The current literature suggests that PET-CT is sensitive in the range of 70%-90% and specific in the range of 80%-90% in evaluation of CLNM, with negative-

predictive value of 90%.<sup>84</sup> The reason for such high accuracy is over 40% of metastatic lymph-nodes being greater than 7mm in size, that are picked up easily in PET-CT scans.<sup>70</sup> Tzu-Chen Yen and colleagues evaluated the role of PET-CT in staging of buccal mucosal SCC with an objective of its comparison with CT and MR imaging for detecting regional and distant metastasis in 102 patients.<sup>85</sup> The role of PET-CT in this study using 18-F fluoro-deoxy-glucose was significant in detecting regional metastasis at level II and distant metastasis. Two percentage of patients were detected with distant metastasis and in these patient's futile surgery could be avoided as there was no survival benefit. However, the loco-regional control rates in patients that underwent PET-CT upfront and those did not was similar. This study concluded that the only major benefit of upfront PET-CT in buccal SCC before surgery was uncovering distant metastasis that was effective in only 2% of the patients.

A meta-analysis has evaluated the efficacy of imaging techniques for the diagnosis of CLNM in clinically N zero neck.<sup>86</sup> The imaging techniques chosen in this analysis were Computed Tomograms, Magnetic Resonance Imaging, Ultrasonography and Positron Emission Tomograms. Results showed that all the modalities used were similar with respect to sensitivity and specificity. However, it was found that CT was superior to Ultrasound in terms of specificity and the range of values of specificity and sensitivity with other techniques in comparison were approximately same. It was concluded that in patients with "cN-zero", the accuracy of current imaging techniques in detection of occult CLNM remains the same.

A novel technique called "Nuclear Morphometry (NuM)" has been developed in Japan for pre-operative evaluation of risk of CLNM in oral SCC.<sup>87</sup> Using a digital imaging method, the morphologic factors of lymph-nodes like nuclear area, perimeter,

L:W ratio and area coefficient of variation were analyzed in over 50 tongue, 29 GBC and floor mouth SCC. The nuclear expanse and circumference were larger in node-positive cases in contrast to node-negative cases. The L:W ratio area coefficient of variation and primary subsite of SCC were not significant. The authors of this study concluded that pre-operative NuM can add to valuable information as a non-invasive technique for evaluating CLNM by identifying them. This can help a surgeon to modify his ND technique depending on level and extent of CLNM.

**Neck Dissection (ND) in the management of Oral Cancer:**

ND forms an integral aspect in management of oral SCC.<sup>88</sup> It comprises of removal of the lymph-nodes that are specific to the draining area of head and neck.<sup>88</sup> The lymphatics are distributed in the fibro-fatty tissue along the major veins, salivary glands and 11<sup>th</sup> cranial nerve. The occurrence of metastasis of oral SCC to CLNS is a significant factor in determining the overall-survival (OS) of a patient and its presence has shown to reduce the OS to less than 50%.<sup>88, 89</sup> Therefore, CLNM by oral SCC has emerged as single most important and independent prognostic factor.<sup>89</sup> ND has evolved from being more radical in 19<sup>th</sup> century to being more conservative in the current era with the realization of quality of life as an important factor that determines the patient's well-being.<sup>25, 90</sup> Also, in view of elaborate data available in existing literature regarding the pathways of lymphatic spread to lymph-node groups from the primary subsite of oral cavity, several modifications of ND have come into current practice.<sup>24, 56</sup> The radical neck dissection (RND) was described by George W. Crile in the year 1906.<sup>91</sup> This procedure included lateralized surgical removal of the CLNS in addition to extra-lymphatic structures namely sternomastoid muscle, internal jugular vein, 11<sup>th</sup> cranial nerve, submandibular gland and tail of parotid gland. Later in the

year 1957, Hayes Martin described the use of this procedure in regional control of head neck cancer.<sup>92</sup> However, with increase in the popularity of RND that was very commonly being performed for the regional control of the disease, post-surgical morbidity related to this procedure increased. The morbidity mainly included shoulder pain and restricted mobility and inability of its application in both sides of neck whenever indicated.<sup>93</sup> In view of increasing morbidity of this procedure, the modifications were described by Ward and Robben to prevent morbidities related to shoulder and later by Saunders and co-workers, who showed that when 11<sup>th</sup> cranial nerve was preserved or reconstructed during ND, the complications related to shoulder were minimal.<sup>94, 95</sup> Magrin J and co-workers showed that preservation of internal jugular vein was possible in most of the cases of oral cancer, during ND and its preservation reduced the post-operative edema in most of the patients.<sup>96</sup> Studies by Suarez and colleagues showed that the “Functional Neck Dissection (FND)” or “Modified Radical Neck Dissection (MRND)” are acceptable treatment modalities in patients with CLNM by primary oral cancer whenever there is no extra-nodal extension.<sup>97</sup> Later in 1980s another concept of ND called “Selective Neck Dissection (SND)” emerged. Ballantyn and co-workers who proposed that in this procedure a selected group of lymph-nodes may be dissected leaving behind the rest of them that are normally removed in a RND.<sup>98</sup> This procedure was based on the understanding of the pattern of CLNM due to malignancies occurring at a well-defined sub-site in head-neck region. A study published in the year 1999 compared the QoL, one-year after various types of ND that were described earlier.<sup>99</sup> This study compared consequences of SND, RND and MRND in 84 patients and the outcomes were similar in SND and MRND group. However, the outcomes were poor in terms of QoL in RND group, in comparison to MRND and SND groups.

The studies that were performed later focused on the occurrence of CLNM from head -neck SCC to specific group of lymph-nodes, so as to decide on which group of lymph-nodes to be removed and which of them can be spared during therapeutic neck dissection. Davidson BJ and colleagues found that in 1277 patients who underwent RND for various head neck sub-site-specific SCC, only 3% of the lymph-nodes were found positive in the posterior-triangle and the positivity for metastatic nodal deposits increased to 5% when clinically metastasis-positive nodes were present at other lower levels, that is levels I to IV.<sup>100</sup> Over the years, SND became popular as a procedure of choice when ND is being carried out on elective basis.<sup>101</sup> This helped the surgeons to efficiently manage micro-metastasis, which cannot be detected by using non-invasive techniques pre-operatively.<sup>102-104</sup> With the advent of SND the ambiguity regarding the need for adjuvant therapy or observation was resolved, as it helped the surgeons to know about the micro-metastasis and served as a medium for pathological staging of the neck. Some literature also supported the concept that SND can be a therapeutic procedure for node-positive neck and the nodes that are left unremoved in the neck with possible micro-metastasis can be effectively radiated post-operatively to reduce neck-nodal recurrence.<sup>105</sup> With this method of practice, some studies showed the mean failure rate in the neck to be 8.3% and in the range of 5.5%-11.1%.<sup>106</sup> Carefully selecting patients with clinical CLNM, Andersen and colleagues in the year 2002 showed that the regional control of over 90% can be achieved in 129 patients with SND and the results were comparable to those treated by MRND and RND.<sup>105</sup> The advantages of SND over other comprehensive ND were lesser surgical time and reduced shoulder dysfunction.<sup>105, 106</sup>

The first attempt to assess the order of CLNM from oral cancer was made in a retrospective study that was published in the year 1990.<sup>24</sup> This study was conducted

on 501 biopsy proven SCC patients with different sub-sites of oral cavity, of which 206 patients were positive for CLNM and 295 patients were negative for the same on clinical examination. RND was performed on all the patients and the order in which the metastasis occurred in various nodal groups was analyzed following surgery. It was found that neck nodal levels from I to III in majority were involved by metastasis from oral SCC and these groups were established to be at high risk of containing metastatic disease. It was interesting to note in this study that the level IV nodes were seldom involved (less than 3%) in patients that were diagnosed to have clinically node-negative neck and rarest nodal level that was involved by metastatic disease in both clinically node-positive and node-negative necks was level V. It was also found that level V nodes were involved by CLNM only if the positive nodes existed in other lower levels, that is levels I to IV.

Following this study, the concept of modifications in the standard RND started and focus was on achieving high regional cure rates with lesser morbidity. However, the follow up of the patients is equally important to validate the high regional cure rates achieved after ND. It is utmost important to follow up the patients with suitable imaging in order to detect the nodal metastasis either in the ipsilateral or contralateral neck so that early detection is made effective and possible curative therapy can be initiated. After several modifications in the ND were described, there was a constant debate on whether to do ND upfront on patients with oral cancer (elective neck dissection, END) or to do it when there is nodal recurrence during follow up (therapeutic neck dissection, TND).<sup>107-109</sup> A prospective randomized trial on clinically node-negative patients presenting with operable, biopsy proven SCC of oral cavity was conducted.<sup>110</sup> This study included early cases (T1 and T2) of oral SCC and comprised of total 500 patients that were randomized into two arms, 245 underwent

elective neck dissection and 255 underwent therapeutic ND and were followed up for median 40 months. When the results were compared after follow up, the number of recurrences and disease related deaths were highest in the therapeutic ND group. This study effectively showed that elective ND reduced the recurrence rates. Also, there was improvement in disease specific survival rates in oral cavity SCC.

A multi-centric study which was conducted on 98 patients diagnosed with buccal mucosal SCC with clinically node-negative status.<sup>111</sup> This cohort study compared the local recurrence, distant metastasis and 5-year survival in patients that underwent elective ND versus the patients that did not. The results and the analysis showed that elective ND reduced the rates of regional recurrences and distant metastasis and improved the 5-year survival rates. Although, the number of cases with locally advanced buccal SCC were limited in this study and most of the cases studied were early (T1 and T2) cases, the extent of ND that was performed in each patient is unclear in this study.

Kowalski LP and Sanabaria A, reviewed the evidence regarding role of END in oral cancer.<sup>112</sup> This review showed that for a patient with clinically node-negative oral SCC, END is well established modality for optimal regional control of the disease. However, according to this review, there is still a controversy in the literature with regards to extent of ND in the clinically node-positive neck. They found that with extended supra-omohyoid ND in a node-positive neck, the rate of regional failure was 6%, provided that post-operative adjuvant radiotherapy was administered in these patients.<sup>112</sup> Also, when the extended supra-omohyoid ND was compared with MRND, neck-failure rates and overall survival was similar in both arms, in a group of over 200 patients with oral SCC.<sup>112</sup> In addition to this, there were reduced

complication rates and improved results with regards to appearance and functional outcomes in supra-omohyoid ND group (SOHND). Among the patients that recurred regionally, in 50% of them relapse was within the fields of SOHND.<sup>112, 113</sup> They advocate extended SOHND covering level IV nodes in every case of CLNM in oral SCC.<sup>113</sup> However, it is unclear in this review regarding the specific subsite of oral SCC. The review included all subsites of oral SCC and extrapolating the outcomes of this critical review to GBS-SCC still remains controversial.

**Role of clinical and pathological factors that contribute to lymph-node metastasis in GBS-SCC:**

Various clinico-pathological factors were studied with regards to buccal SCC and some were found to influence CLNM either directly or indirectly.<sup>114-121</sup> The patients age, tobacco habits: their duration and frequency, presence of potentially malignant disorders, clinical skin and/or bone infiltration, trismus, clinical T-size and extent of tumor and clinically palpable lymphadenopathy are important from clinical standpoint in a patient with GBS-SCC. The HD, pT-stage, tumor thickness (TTh), LVE, PNI, lymph-node yield (LNY) and ECS are pathologic factors that influence the prognosis in oral SCC cases.<sup>122-124</sup>

The contribution of age, tobacco habits and potentially malignant disorders have not been significant in their associated with CLNM. However, they have contributed in likelihood of local recurrence after definitive therapy for buccal SCC.<sup>35, 122, 123</sup> Infiltration of bone and/or skin, clinical extent of tumor and presence of trismus due to infiltration of GBS-SCC into masticator space are the markers of higher T-stage which influences CLNM by increasing overall tumor volume.<sup>122, 123</sup>

**Histologic differentiation (HD) and nodal metastasis:**

The behavior of well differentiated tumors was associated with better prognosis compared to moderate and poor histologic differentiation. In a study highlighting histologic prognostic markers by Woolgar JA, the amount of cellular-keratin deposition, pleo-morphic activity at the cellular and nuclear levels and mitotic changes influence the extent of differentiation in the tumor cells.<sup>35, 119</sup> The reliability of HD as a pointer for CLNM in current studies has been questionable in view of it being more subjective, heterogenous nature of the tumors, non-representative sampling during biopsy and interpretation based on structure of tumor cells rather than function.<sup>35</sup>

However, some studies on multi-variate analysis have found that HD is a reliable predictor of local and regional recurrence in oral SCC. The regional control rates in study by Larsen SR and colleagues were notably associated with HD and showed better control rates with well to moderate differentiation compared to poor differentiation.<sup>124</sup> The HD was also significantly found corresponding to the presence of nodal-positivity during diagnosis on multivariate statistics.<sup>124</sup> In another study by Kademani D and colleagues that comprised of 46 patients with primary buccal and retromolar trigone SCC and rest 154 patients with other subsite SCC, HD was associated with local and regional failure and significantly contributed to lymph-node metastasis.<sup>125</sup> The findings of this study and one by Mataga O and co-workers suggested that moderate to poor HD was major contributor to CLNM independent of T-stage or size of the tumour.<sup>125, 126</sup>

**T-stage or Tumor size and Tumor thickness (TTh):**

The increased size of tumor on initial clinical presentation has shown to contribute directly to CLNM.<sup>35</sup> The size of tumor is the measure of overall tumor diameter and roughly represents the volume of disease. In the SCC of mandibular GBC, the infiltration into masticator space, erosion of bone and infiltration of skin are the manifestation of overall tumor size.<sup>127</sup> However, in some studies, the tumor size did not contribute to CLNM on multi-variate analysis.<sup>128, 129</sup> In a study by Vincent N and colleagues, the tumor measured on resected specimen was more accurate in predicting CLNM compared to clinical tumor size.<sup>130</sup> In a retrospective study that evaluated spreading pattern in buccal mucosal SCC with contrast computed tomogram imaging it was found that Stensen's duct was most often invaded structure by buccal SCC in over 70% of cases followed by GBC (60%) and buccal space.<sup>131</sup> The cases of long-standing tumor showed presence of invasion into masticatory muscles, skin subcutaneous fat and bone. The skull base was invaded in late stages. These findings were confirmed and correlated with histopathology and were found significant ( $p < 0.05$ ).<sup>130, 131</sup> The pathways of spread of buccal SCC are linked to CLNM and they determine prognosis in these patients.<sup>130</sup>

With the emerging evidence from several studies based on tumor thickness (TTh) as a major contributor of CLNM the importance of tumor size has reduced. The current literature highlights the TTh as a distinguished pathologic factor, accurately representing tumor volume and marker of CLNM and prognosis.<sup>127</sup> As per the definition by Moore and colleagues, the "deepest invasion of the tumor in the tissues from mucosal surface" is known as TTh.<sup>132</sup> Based on this definition a meta-analysis by Huang HS and co-workers, comprising of sixteen studies on over 1130 patient's

pooled data has shown that TTh is a potential predictor of regional metastasis in oral SCC.<sup>122</sup> In this analysis the investigators found that the TTh break-off differs in terms of CLNM from 4mm to 5mm, with latter value being highly associated with CLNM and former as a borderline value. They concluded that the most appropriate break-off of TTh is 4mm that predicts occult CLNM in oral SCC. However, in this entire analysis only one study was based on buccal mucosal SCC (Mishra et al<sup>127</sup>) and other studies reveal that break-off varies with the subsite depending on variability in depth, measurements and abundance of lymphatic tissues of that subsite.<sup>127</sup> Thus, the interpretative value of TTh in floor-mouth region is much less (1.6mm) compared to buccal mucosa (6mm) and tongue (4mm).<sup>122</sup>

The accurate predictability of CLNM in the current literature using TTh has replaced tumor size and its wide application has given way for modifications in the recent AJCC staging of cancer to incorporate TTh as one of the measures.<sup>133</sup>

In addition to TTh infiltration into skin and soft tissue over GBS has shown not only to result in ipsilateral multi-level metastasis but also contralateral neck nodal metastasis.<sup>134, 135</sup> The infiltration of skin and/or gross bone involvement irrespective of size of the tumor will upstage the T stage to T4. A study by Mair and colleagues has shown that among the 53 patients with mandibular GBC-SCC involving skin of the cheek, 28 had multi-level CLNM unilaterally and 18/53 had bilateral CLNM. These patients required bilateral ND for comprehensive therapy.<sup>135</sup> Contrarily, gross erosion of bone by mandibular GBC-SCC has not shown to contribute to CLNM. Studies by Brown JS and colleagues has shown that isolated bone infiltration in comparison to skin infiltration is less likely to cause CLNM but likely to contribute in local recurrence of the tumor, especially at the stump of the bone remaining after resection

of the mandible.<sup>136-137</sup> On the contrary Kuk SK and co-workers showed that tumor size significantly correlated with bone infiltration and CLNM.<sup>138</sup> Taking neck node metastasis as an end point, there was significant association with this factor and bone infiltration in this study. When the extent of bone infiltration by tumor was studied, the patients with bi-cortical destruction had a higher propensity for CLNM compared to those having subtle bone erosion and were lesser in size (T1 / T2 or  $\leq 4$ cm in size). The authors suggested modifications in the TNM staging against unnecessary upstaging of T stage when foci of bone infiltration are small or questionable.<sup>138</sup>

Apart from application of TTh in oncologic studies there is broad disparity in the literature regarding techniques used to measure TTh.<sup>122, 139-141</sup> Some authors suggest measurement from apparently healthy mucosal surface to deepest point of invasion whereas, other measure it from ulcer base or highest point on the surface of tumor.<sup>122, 142</sup> Also, the changes in the measurement resulting from dehydration of tissues, following formalin fixation leads in erroneous interpretation of results.<sup>142</sup>

In view of paucity in the standards of measurement there is a broad disparity in the literature regarding measurements of TTh and can range from 2-10mm and above.<sup>122, 141, 142</sup>

The shrinkage of tumor and the surgical margins after formalin fixation is yet another factor that adds to erroneous interpretation of tumor size and margin status in oral SCC, especially the pTNM staging which is often done after 48 hours of fixation of the specimen in 10% buffered formalin.<sup>143</sup> Studies on 52 specimens of resected buccal mucosal SCC showed that average decrease in tumor size and margins that were measured following formalin-fixation were statistically significant ( $p < 0.05$ ) in 65% of the cases. This study showed that resected margins around the tumor are

expected to show shrinkage of 25% after formalin fixation and cautions both surgeon and pathologist to be familiar with this shrinkage factor. According to this study the measurement of tumor related factors like T-size and TTh are best done intraoperatively, immediately after resection of tumor so that the accuracy of pT-staging is not compromised or is based on erroneous interpretation after formalin fixation.<sup>143</sup>

The application of AJCC TNM staging, in terms of clinical or pathological factors has also shown a difference in accuracy. This was evaluated in a study by comparing clinical TNM (cTNM) and pathologic TNM (pTNM) so as to ascertain which one is more accurate as a staging method for oral SCC. The retrospective data of over 390 patients were subjected to clinical and radiological evaluation pre-operatively and surgery with adjuvant therapy, as per tumor board decision, was evaluated. Identification of prognostic factors was done by univariate analysis (log rank test) and multivariate analysis (Cox regression). The cTNM and pTNM showed concordance in over 60% of primary tumor and 60% for cN negative and pN negative classification. There was over-staging in 58% of cases by cTNM. When the relationship of metastatic tumors to cervical lymph-nodes was evaluated, there was over-staging in 78% of cases by cTNM. When overall survival was assessed in multivariate analysis, pT and pN classification was significant. Thus, it was concluded that for all practical purposes related to staging, the accuracy of pTNM was much higher and reliable compared to cTNM.<sup>144</sup>

#### **Lympho-vascular emboli (LVE) and Peri-neural Invasion (PNI):**

According to Woolgar JA and co-workers, LVE refers to “presence of tumor cell clumps in the endothelium-lined lumens or infiltration of vessel-wall media and

causing ulcer in the intimal lining” and PNI refers to “presence of tumor cells in the peri-neural space of the nerves”.<sup>35</sup> In the studies based on large scale population, the occurrence of LVE and PNI were approximately similar in tongue and buccal mucosa in one study based on Taiwanese population whereas, in another study based on Indian population there was a slightly higher rate of PNI in tongue SCC compared to GBS -SCC (27% versus 16%) but rate of LVE was comparable in both sub-sites.<sup>29, 128</sup> In a study by Tai SK that comprised of over 220 patients with combined buccal and tongue SCC, with the increase of TTh from 4mm to 10mm, both LVE and PNI predicted CLNM on univariate analysis.<sup>145</sup> However, in absence of LVE and PNI even the TTh>6mm was not a predictor of CLNM on multivariate analysis. In contrast to LVE, PNI on multivariate analysis showed significant association with CLNM and poor disease specific survival for 5 years, in this study. LVE was significant contributor of CLNM in the study by Woolgar JA and colleagues, which comprised of oral SCC cases with unspecified sub-sites.<sup>35</sup> However, it was insignificant contributor in a study by Nair S and colleagues, that was based on buccal and tongue SCC patients, in Indian population.<sup>128</sup> In the latter study the authors were unable to ascertain the role of PNI in anticipating CLNM from either buccal or tongue SCC even though the study was based on larger population.<sup>128</sup>

In another Indian study that intended to investigate the predictive and prognostic factors in GBS-SCC that was based on over 30 patients, 21% patients were positive for PNI and 18% were positive for LVE. In this study, with exception of TTh (p=0.009), neither LVE nor PNI was associated with CLNM on univariate and multivariate analysis.<sup>146</sup>

**Extra-capsular spread (ECS):**

ECS is a distinguished factor that impacts the disease specific survival in oral SCC.<sup>35, 147</sup>

Two Asian studies consisting largest number of mandibular GBC-SCC patients have shown the incidence of ECS to range from 16%-24%.<sup>26, 30</sup> However, in contrast to buccal or mandibular GBC-SCC, studies from west that mainly comprised of SCC of tongue have shown a higher incidence of ECS, ranging from 21%-63%.<sup>148, 149</sup> The ECS is known to influence further dissemination of metastatic disease into multi-nodal levels. From the surgical standpoint, positivity for ECS in the CLNS requires not only aggressive surgical dissection but also post-operative adjuvant chemo-radiation for optimal loco-regional control.<sup>149</sup> Also, presence of ECS is a potential marker of inoperable disease. Studies on oral SCC show that in absence of ECS the chance of metastasis to level IV and level V is less than 3% and with positive-ECS the incidence of nodal metastasis to these levels increases to 10%.<sup>7, 26</sup> The presence of ECS can be detected by ultrasonography and other imaging modalities like CT and MRI.<sup>150</sup> Also, there is possibility of smaller nodes presenting with ECS and not necessarily larger sized nodes should be suspected of having ECS. In a study conducted on 66 oral SCC patients, the relationship of CT and histologic findings in the lymph nodes was assessed. It was found that patients having nodes >100 mm<sup>2</sup> area in the CT scan were likely to harbor metastatic disease and were positive for ECS.<sup>151</sup> These patients when compared to others showed poor outcome in terms of disease-free survival. ECS has significantly been associated with contralateral CLNM and distance metastasis.

There is still a controversy in detecting ECS pre-operatively based on imaging and post-operatively by histopathology. Few authors presume that increased size of lymph-nodes beyond 3cms and correlated findings on imaging is expected to be graded as ECS whereas, others suggest that under microscopic examination a complete rupture of lymph-node capsule to be labelled as ECS.<sup>152</sup> Wreesmann VB and co-workers have overcome this by suggesting a method of identification of ECS wherein, distance between inner capsule and the outer infiltrating front of the tumor is measured. Also, in borderline or doubtful ECS cases, examination of the entire node and status of perinodal fat tissue suggests ECS.<sup>153</sup>

**Lymph Node yield (LNY):**

In the recent studies the lymph node yield (LNY) and lymph node ratio (LNR) has gained popularity as a reliable predictor of regional recurrence and disease-specific survival in oral SCC.<sup>154</sup> Studies have defined LNY as “the number of lymph-nodes harvested in ND.” This factor forms an important basis for calculating lymph-node ratio which is defined as “the ratio of number of positive nodes to the number of lymph-nodes harvested”. This factor represents the level of CLNM, extensiveness of the ND, requirement of adjuvant therapy and prognosis.<sup>155</sup> Although LNR and LNY have been validated as a marker of prognosis, their accurate estimation can vary with respect to the field of ND, experience of the pathologist and build of the patient.<sup>156</sup> The existing studies in the literature on LNY and LNR are based on oral cavity SCC without specifying the subsite of the disease.<sup>155, 157</sup> Also, there is paucity of studies on Indian population regarding the adequacy of LNY for faultless nodal staging postoperatively and estimation of LNR.

## **JUSTIFICATION OF THE STUDY**

Among the various subsites of SCC of oral cavity occurring worldwide, SCC of the mandibular GBC is a unique malignant disease of oral cavity in India.<sup>6, 7</sup> It is associated with abuse of chewable forms of tobacco and betel nut and affects working age group most commonly.<sup>6</sup> The treatment of this disease is surgery which includes ND, resection of the primary tumor with clear margins, reconstruction of the surgical defect and adjuvant therapy depending on the final histopathology of the tumor.<sup>6, 7, 26</sup>

ND is an essential component of the surgical therapy for mandibular GBC-SCC like any other subsite of oral SCC. Although CLNM is a major survival and outcomes determinative in mandibular GBC-SCC, it tends to occur less frequently in lateralized cases, in comparison to oral tongue and floor mouth SCC.<sup>7, 26, 129</sup> In most of the cases of mandibular GBC-SCC the CLNM is reported to occur in a foreseeable manner, unlike other subsites, affecting mainly the level I, II and less frequently level III lymph-nodes.<sup>7</sup>

Most of the current literature on presence of CLNM and extent of ND is based on Western literature with predominance of unspecified oral sub-sites, tongue and floor mouth SCC, which necessitates aggressive ND unlike mandibular GBC-SCC.<sup>12, 20, 23, 24</sup> Also, less importance is given to mandibular GBC-SCC in these studies. Furthermore, the available evidence is based on retrospective studies that lack accuracy and uniformity in defining subsite-specific oral SCC, the extent of ND performed, the number of lymph-nodes evaluated, the methods of grossing of the specimen, the clinico-pathological factors studied and methods used for their estimation.<sup>7, 26, 129</sup> The drawbacks in the existing literature justify the need for

prospective assessment of extent of CLNM in mandibular GBC-SCC and possible modifications in the ND in dealing with such type of cancer, based on the knowledge of extent of CLNM, that can be oncologically safe and less morbid to our patients.

The LNY has emerged as a reliable prognostic-marker in various malignant disorders that affect mankind.<sup>154</sup> This factor has been defined in the current literature depending on the organ affected by the cancer and field of lymph-node dissection, so as to improve the accuracy of staging which in turn is mandatory for planning adjuvant therapy.<sup>155, 156</sup> As per previous studies, LNY tends to differ depending on the field of ND, surgeon, pathologist, race and built of the patient.<sup>156, 157</sup> However, there is paucity of literature with regards to LNY in cases with mandibular GBC-SCC. The number of CLNS to be harvested from specimens of ND in patients with mandibular GBC-SCC for accurate pN staging has not been defined so far. The need to find minimal number of lymph-nodes to be studied for optimal pN staging has to be established in mandibular GBC-SCC, which justifies this study. The CLNM in oral SCC is influenced by various clinico-pathological factors like tumor size, tumor thickness, histological grading, peri-neural spread and lympho-vascular emboli.<sup>35, 36, 89, 121, 123</sup> The existence of most of these factors, if not all, will be known to the operating surgeon before performing ND on patients with mandibular GBC-SCC. The association of these clinico-pathological factors with the CLNM needs to be studied in patients with mandibular GBC-SCC in order to provide guidelines in decision-making regarding the extent and adequacy of ND. The T-size in mandibular GBC-SCC can vary depending on extent of tumour and infiltration into mandibular bone or surrounding soft tissue like skin and/or muscles.<sup>7, 35, 26</sup> Its influence on degree of CLNM requires to be investigated. This can help in deciding the extent of ND pre-

operatively. Currently TTh is a valid marker of CLNM in head-neck SCC.<sup>122</sup> The accurate estimation TTh in mandibular GBC-SCC can be affected by proximity of this subsite to bone and at times, major portion of the tumor being intra-bony.<sup>127</sup> However, the gross TTh into the soft-tissues is measurable intraoperatively by the surgeon after resection of the tumour. The extent of role played by this soft tissue gross TTh in influencing the CLNM needs to be ascertained, especially to the lymph-nodes at levels IV and level V. The surgeon can clear these levels if they are found to be influenced by intra-operative gross TTh or can avoid unnecessary dissection which would otherwise entail dissection of level IV and level V with associated shoulder morbidity. Studies have shown that LVE and PNI are potential determinants of prognosis and need for adjuvant therapy in HNC.<sup>35, 130</sup> Although, these factors will be known to the surgeon only after resection, following final histopathologic reporting, their incidence in mandibular GBC-SCC in our patients and their influence on CLNM requires to be assessed in order to validate their importance, plan for adjuvant therapy and explain the prognosis to the patients.

There is a need to establish reliable pre-operative and intra-operative clinico-pathologic factors that can independently help a surgeon in deciding the extent of ND, without adding to the cost of therapy to the patients and yet providing oncologically safe and reliable practice of ND.

## **RESEARCH PROBLEM**

- Extent of CLNM in primary mandibular GBC- SCC and its association with clinico-pathologic factors
- Suggesting possible modifications for extent of ND in mandibular GBS-SCC

## **AIM AND OBJECTIVES**

Evaluate the pattern of CLNM due to primary SCC of mandibular GBC and study its association with clinico-pathologic variables. The pattern refers to involvement of lymph nodes at different levels in the neck by the primary mandibular GBC-SCC.

- To study the involvement of lymph-nodes at various levels in the neck from primary mandibular GBC-SCC.
- To quantify the number of lymph-nodes that are harvested in a comprehensive ND (level I-level V) for mandibular GBC-SCC.
- To study the association of CLNM in mandibular GBS-SCC with clinico-pathologic characteristics namely: T-size, involvement of bone, HD, PNI and LVE.
- To suggest possible modifications for extent of lymph-node dissection in patients with primary mandibular GBC-SCC.

## **MATERIALS AND METHODS**

**Study design:** Prospective Observational study

**Definition of subsite:** The mandibular GBC was defined in this study as a subsite in oral cavity comprising of Gingivo-buccal sulcus (GBS), buccal mucosa, buccal mandibular gingiva and retromolar trigone as shown in **photograph 3**.

**Inclusion Criteria:**

1. Patients with lateralized GBC lesions, not crossing midline of the oral cavity (**photographs 4A and 4B**).
2. Patients with confirmed histopathologic diagnosis of SCC of mandibular GBC who underwent level I to level V NDs.
3. Patients with clinically node positive necks.
4. Patients with large size defect at primary GBC tumor-resection site necessitating pectoralis major myo-cutaneous (PMMC) flap for reconstruction.
5. Patients that accept to undergo curative surgery.
6. Patients fit for surgery as a curative therapy.

**Exclusion Criteria:**

1. Patients with clinically node-negative neck (cN0) and selective ND.
2. Patients who have undergone previous treatments (surgery, radiotherapy/ chemotherapy).
3. Patients in whom level I to level V nodal clearance was not done or was not advised.

4. Patients who were unfit or reluctant for surgical therapy.
5. Patients with oral SCC presenting with unspecified subsite.

**Study sample:** the patients meeting the inclusion criteria that were operated at KLE Dr Prabahkar Kore Hospital and Medical Research Centre, Belagavi, and Karnataka Cancer Therapy and Research Institute, Navanagar, Hubballi were included in this study.

Ethical clearance from institutional board was obtained before commencing this study. This study was conducted between June 2014 to December 2015. The patient's clinical data, findings on imaging, intra-operative findings, measurements after resection of the tumor and histological findings after formalin fixation of the specimen were noted.

**Data Collection**-the data on following aspects were collected:

1. Clinical details: patients' demographic details (Name, Age, Gender, Contact Details).
2. Tobacco and/or alcohol Habits: Type of tobacco product abused, duration and frequency of habits.
3. Details of clinico-radiological examination: clinical location and extent of tumor, involvement of adjacent structures (Skin/bone/Muscle/), trismus, paresthesia and presence of potentially malignant disorders and lymph node status (**Photographs 5A to 8A**).
4. Preoperative biopsy report revealing histological differentiation of the tumor.
5. Clinical TNM staging as per AJCC 2009 (7<sup>th</sup> edition) manual<sup>158</sup>

6. Intra-operative details (following resection of the tumor and neck dissection): length and breadth of tumor, gross tumor thickness, type of resection (composite or bite composite), type of neck dissection and sacrifice of extra-lymphatic structures, and number of CLNS harvested per level.
7. Details in final histopathology:
  - a) Primary Tumor Related: pT size, histological differentiation, Gross Tumor Thickness, Medullary bone invasion, LVE and PNI
  - b) Cervical Node Related: pN status, Number of positive nodes, level of positive nodes, LNY and ECS.

**Standard Operating Procedure (SOP):**

1. In-continuity, en-block NDs were done starting from level V to level I as per oncologic principles (**Photograph 9A to 11**).
2. The sternocleidomastoid muscle was sacrificed to facilitate inset of PMMC flap. Therefore, the nodal levels adjacent to this muscle namely level V B, Level V A, level IV, level III, level II B and level II A were included in the ND specimen, in addition to level I. This facilitated clearance of all these nodal levels and made them available for studying their metastatic involvement.
3. After dissecting each level of lymph-nodes from their anatomic area during neck dissection, ligatures were tied to the fibrofatty tissue to demarcate their level with number of cut ends of the ligatures denoting each level (**Photographs 10, 17 and 18**). For this, **white linen** suture ligatures were used as follows:

4. **Table 1:** Linen suture ligatures with their cut ends denoting the nodal levels after dissection from their anatomical territory.

Number of cut ends	Nodal level
Seven	V B
Six	V A
Five	IV
Four	II B
Three	III
Two	II A

5. **Level I A** nodes were removed separately during ND and **level I B** nodes were removed along with primary tumor and submandibular gland and hence were not suture-ligated (**Photograph 17 and 18**).
6. The tail-parotid lymph-nodes were identified as the lymph-nodes around the inferior pole of the parotid gland, below a straight-line joining angle of mandible and a point corresponding to angle of mandible on the anterior border of SCM muscle. It overlies posterior belly of the digastric muscle, at the exit of retromandibular vein from the inferior pole of parotid gland.<sup>159</sup> These lymph-nodes were removed separately and labelled as tail parotid nodes (**Photographs 12A and 12B**).
7. The resection of primary tumor was done with adequate surgical margins, either by midline lip split or commissure split approach. The orientation of primary tumor was done by passing silk sutures submucosally after palpating for submucosal extension of the tumor. The measurements of antero-posterior dimension (tumor length) and medio-lateral dimension (breadth) that

represents pT size, was done using survey dividers and metric scale, by measuring the distance between the sutures (**Photographs 14A, 14B, 15A and 15B**).

8. Measurement of gross TT: following resection of the tumor, the mucosal surface of the specimen was fixed on the flat board. The induration denoting the lateral extent of tumor (soft tissue infiltration) was palpated from the external surface. At the point of palpable induration, a cut was made at right angle to the horizontal axis of the specimen through overlying soft tissue and tumor up to the mucosa. The gross TT was measured from mucosal surface to the inferior-most point of infiltration of tumor into the soft tissue, using survey divider and metric scale. In cases where the induration was impalpable or the tumor infiltration into lateral soft tissues was apparently uniform, multiple perpendicular cuts at a distance of 0.5 cm were made through overlying soft tissue and section showing maximum depth was considered as gross TT (**Photographs 16A and 16B**).
9. After resection of the tumor, the surgical bed was washed thoroughly with saline and betadine, hemostasis achieved and reconstruction done according to the defect by reconstruction team (**Photograph 13**).
10. The levels of lymph-nodes were identified by the suture ligatures tied and were separated from the main specimen. These were transferred to containers filled with 10% buffered formalin for 48 hours fixation (**Photograph 17 and 18**).
11. The lymph-nodes were harvested from each nodal level after 48 hours of formalin fixation of the fibrofatty tissue. The CLNS were identified by inspection and palpation, and were separated from the fibro-fatty tissue with

the capsule. The harvested CLNs were preserved in 10% buffered-formalin for further processing (**Photographs 19A to 20**).

12. In case of obvious ECS (spread through the full thickness of node capsule) during processing, the lymph-nodes and area of fixity to them were processed en-block. Such nodes were sectioned transversely and their size and level of fixity to surrounding structures were noted (**Photographs 22A, B and C**).

13. The transected specimens were sutured back and immersed in bottled containing 10% buffered formalin. The grossing of specimens was done after 48 hours of formalin fixation.

**Method of grossing the specimen:**

The grossing method was on the basis of protocol established and validated by the “Royal College of Pathologists, Standards and datasets for reporting head and neck cancers (December 2011)”<sup>160</sup>

At each anatomical level of CLNS, the total number of lymph-nodes and the number of positive-nodes per level were noted. For lymph-nodes over 2mm-size, sections were made across the long axis of the lymph-node. For lymph-nodes which are less than 2mm in size, transverse sections were made. Four  $\mu$ m sections of all lesional and lymph-nodes sections were stained by routine Hematoxylin and Eosin staining.

The following pathological details were obtained after microscopic examination of the specimens:

- Histological grade: well/moderate/poor
- Involvement of bone
- Perineural invasion
- Lympho-vascular emboli

The data on CLNS were tabulated with the following information and analysis of the lymph-nodes were done as per the following format proposed by the “Royal College of Pathologist”<sup>160</sup>:

**Table 2:** Format for data collection with regards to nodal characteristics

Nodal levels submitted	IA	IB	IIA	IIB	III	IV	VA	VB	PAROTID NODES
No. of nodes per level									
No. of positive nodes									
ECS									
Total									

**Histologic grading (Table x):**

The degree of similarity of tumour cells to normal epithelium as per the descriptions proposed by WHO classification was used.<sup>161</sup> As per this method, the most aggressive area seen in 100x magnification field was graded as well, moderate and poorly differentiated. The other microscopic factors that were considered in identification of the histologic differentiation were based on the descriptions proposed by Bryne et al and this included degree of keratinization, cellular and nuclear pleomorphism, mitotic activity, pattern of invasion and host immune response.

**(Photograph 24)**

**Pattern of Invasive front:** <sup>162</sup>

The histological differentiation of the tumour at the invasive-front was noted. The invasive front was identified at tumour stroma interface as proposed by Odell EW et al **(Photograph 24)**.

**Lympho-vascular Emboli (LVE):**

LVE was identified as “presence of malignant cells within the lumen of blood vessels and/ or lymphatics.”<sup>35</sup> This finding occurring in thin walled vessels, with presence of tumour cells in the clear spaces completely lined by endothelial cells was noted.

**Perineural Invasion (PNI):**

The invasion into the perineural space ahead of the invasive front of the carcinoma was noted. The size of the nerve was not considered while detecting PNI and invasion of any sized nerve structure ahead of invasive front was considered as positive PNI as suggested by Binmadi NO et al.<sup>164</sup> (**Photograph 23**)

**Table 3:** Guidelines of identifying histological front and HD

Morphologic Feature	1	2	3	4
Degree of keratinization	Highly keratinized (>50% of the cells)	Moderately keratinized (5-20% of the cells)	Minimal keratinisation (5-20% of the cells)	No keratinisation (0-5%)
Nuclear polymorphism	Little nuclear polymorphism (>75% mature cells)	Moderately abundant (50-75% mature cells)	Abundant nuclear (25-50% mature cells)	Extreme nuclear (0-25% mature cells)
No. of mitoses	0-1	2-3	4-5	>5
Pattern of invasion	Pushing, well delineated infiltrating borders	Infiltrating, solid cords, bands and or strands	Small groups or cords of infiltrating cells (n > 15)	Marked and Cellular dissociation (n<15) and or in single cells
Host response *	Marked	Moderate	Slight	None

Host response<sup>\*</sup>: Lympho-plasmacytic Infiltrate. Bryne's (ITF) Invasive Tumor Front Grading System<sup>163</sup>

**Bone Invasion:**

The findings of presence or absence of bone erosion in the CT images were confirmed in the final histopathology. The bone erosion was assessed preoperatively with plain and contrast CT scans with 1mm cuts. In case of questionable bone infiltration by tumor on CT images, the findings in the final histopathologic examination was considered reliable. The nature of infiltrative front was assessed to evaluate if it was infiltrative or erosive. Only the cases showing diffuse infiltration into the medullary bone in the final histopathology were considered positive bone erosion. The cases with non-invasive cortical erosion were considered negative for bone erosion.<sup>165</sup> **(Photograph 21A and B)**

**Sample size calculation:**

- **Sample size: 130 cases, hospital-based samples**
- **The sample size calculation is as follows:**

$$n = Z_{1-\alpha/2}^2 pq/d^2$$

$$Z_{1-\alpha/2}^2 = 1.96^2$$

$$p = \text{prevalence } 17.99\%$$

$$q = 100 - p$$

$$d = \text{allowable error}$$

Recommended 130 Cases

### **Protection of Human Subjects**

The present study involves human subjects. The study protocol was implemented after ethical board clearance from institutional ethical board.

### **Methods of statistical analysis:**

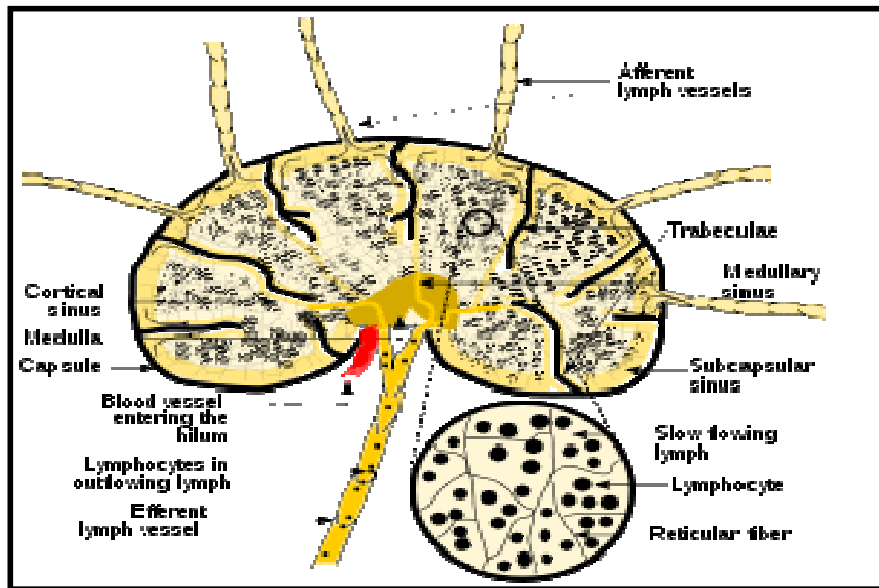
The data was entered in the Microsoft Excel Sheet after coding to enable statistical analysis. The level of CLNM was divided into two categories. The first category comprised of patients with node negative and single level I metastasis. The second category consisted of patients with multiple level lymph node metastases. After completing the data entry, manual checking was conducted separately for each parameter to minimize the data entry error. The statistical analysis was done using SPSS version 20 software (SPSS Inc, Chicago IL). For all the tests, the p-value less than 0.05 was considered statistically significant.

### **Statistical tests used:**

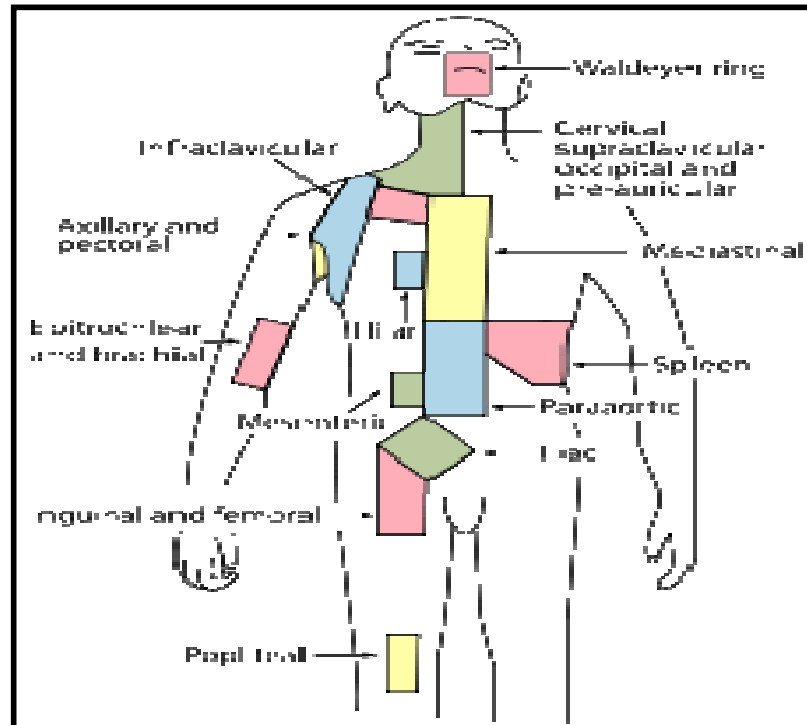
1. **Descriptive statistics** was used to evaluate frequencies and percentages.
2. **Chi-square test** was used for analogy of clinico-pathological variables.
3. **Logistic regression:** the relationship between various clinico-pathological dependent variables and levels of positive node as independent variable was analyzed using logistic regression test to estimate the probabilities and predict the likelihood of their contribution in multi-level lymph node metastases.
4. **Receiver Operating Characteristic (ROC) curve:** The predictors of multilevel lymph node metastasis obtained after logistic regression were further analyzed to evaluate their sensitivity and specificity using ROC curves.

In the usual logistic regression model, all variables were taken. The multiple logistic regression was applied and the significant factors were obtained. The significant factors were re-analyzed using stepwise logistic regression analysis.

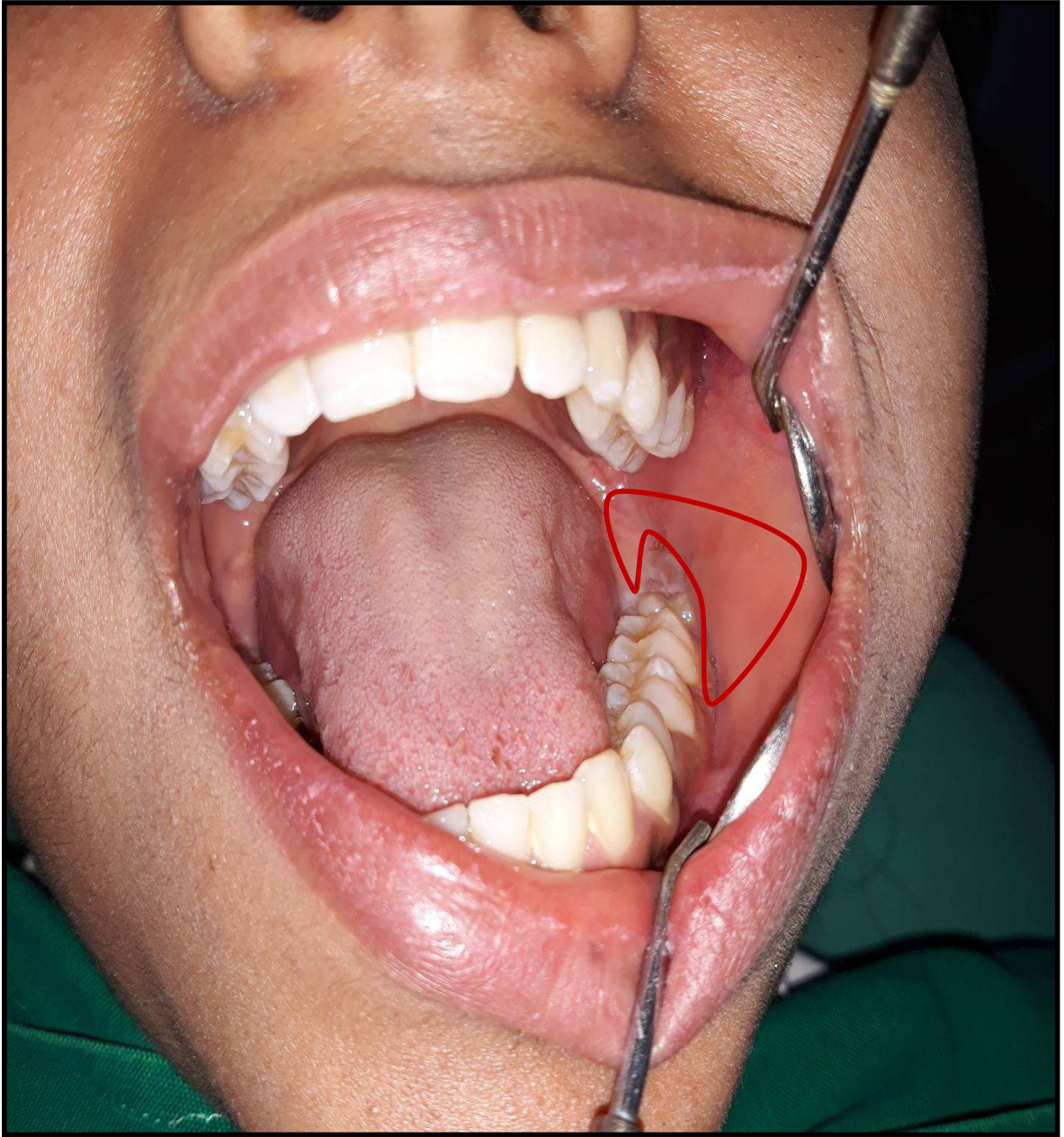
PHOTOGRAPHS



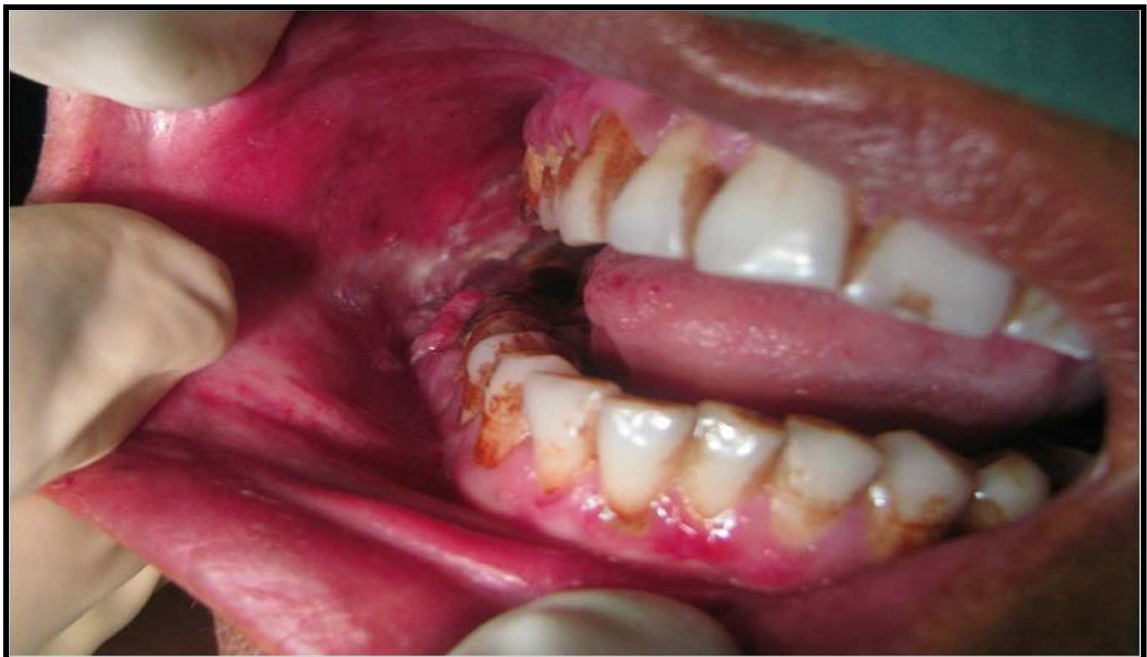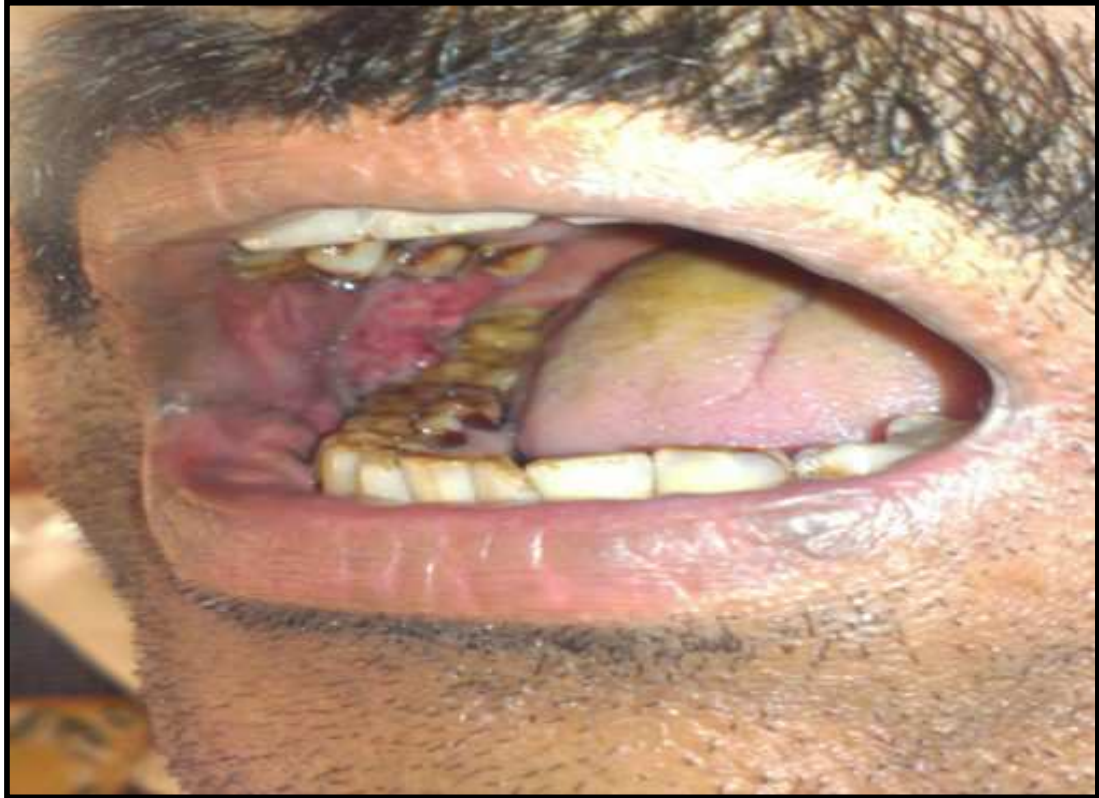1: Structure of a lymph-node



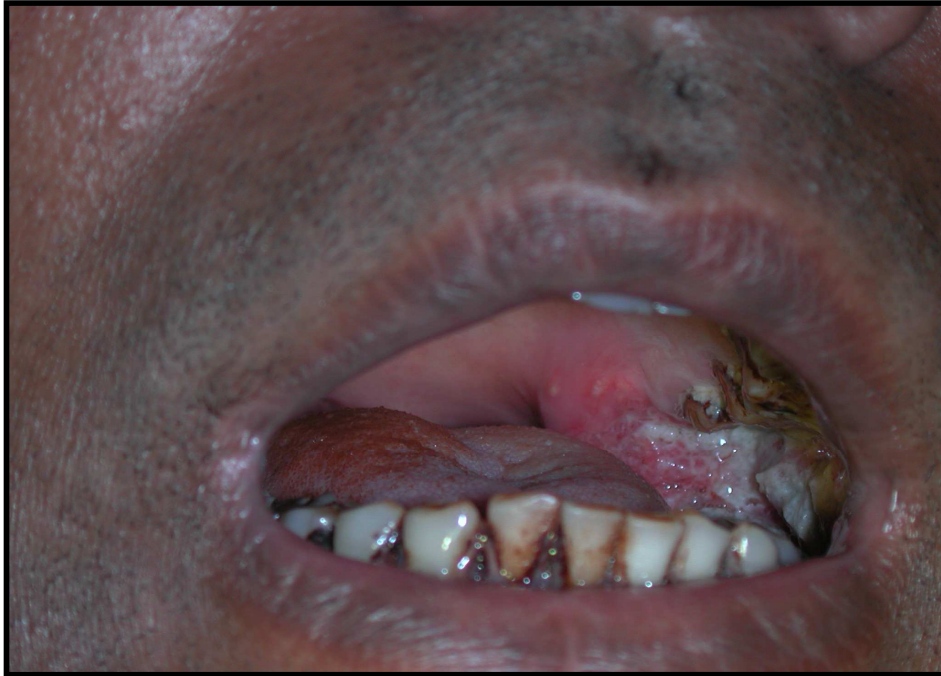2: Distribution of Regional lymph tissue in humans



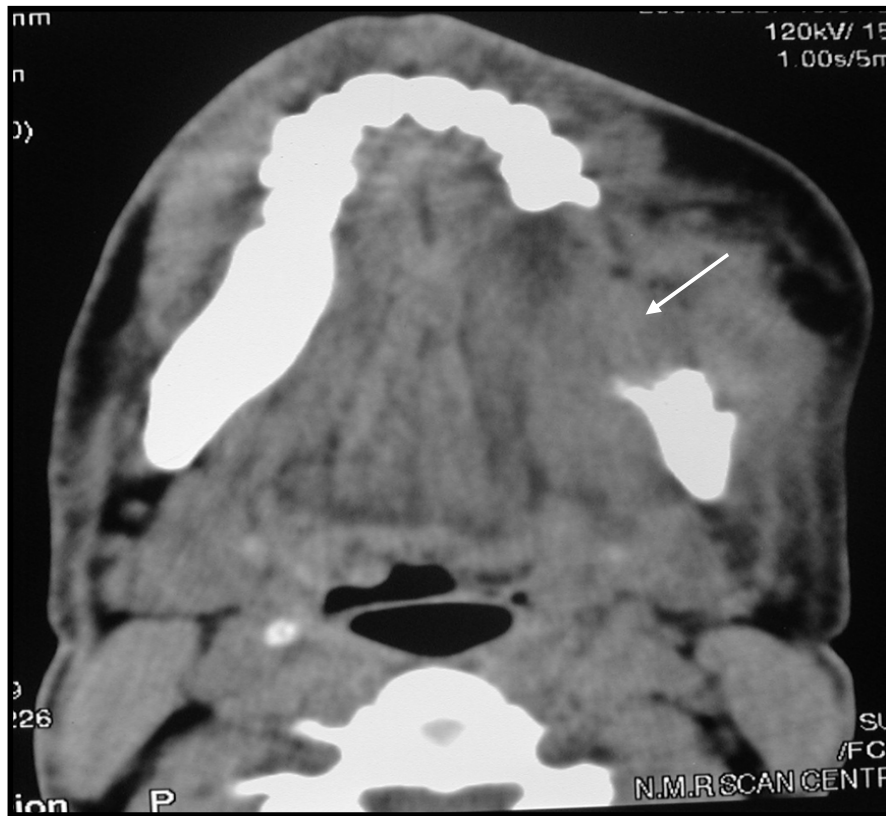
**3: Normal GBC**



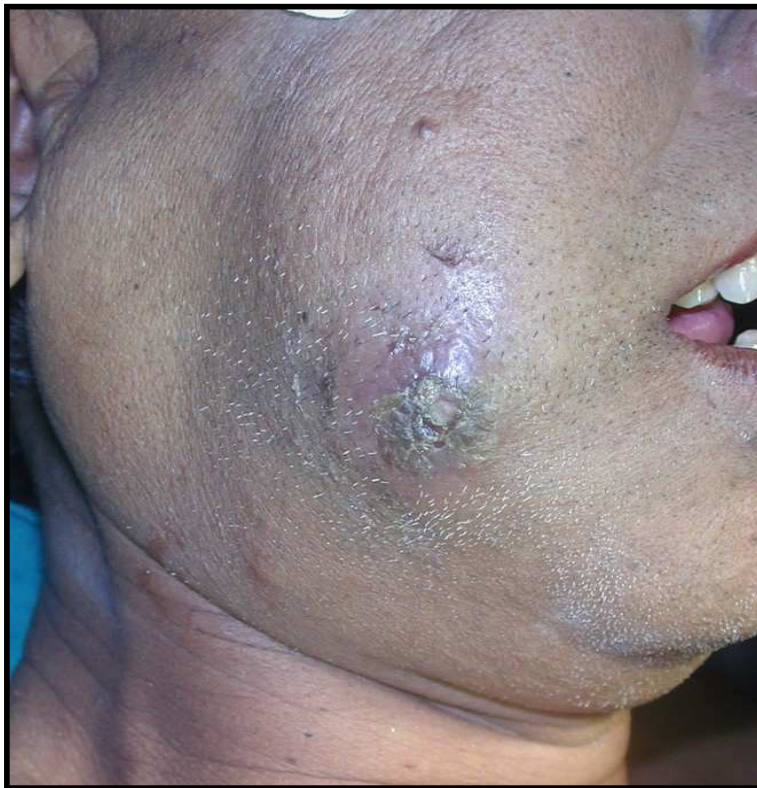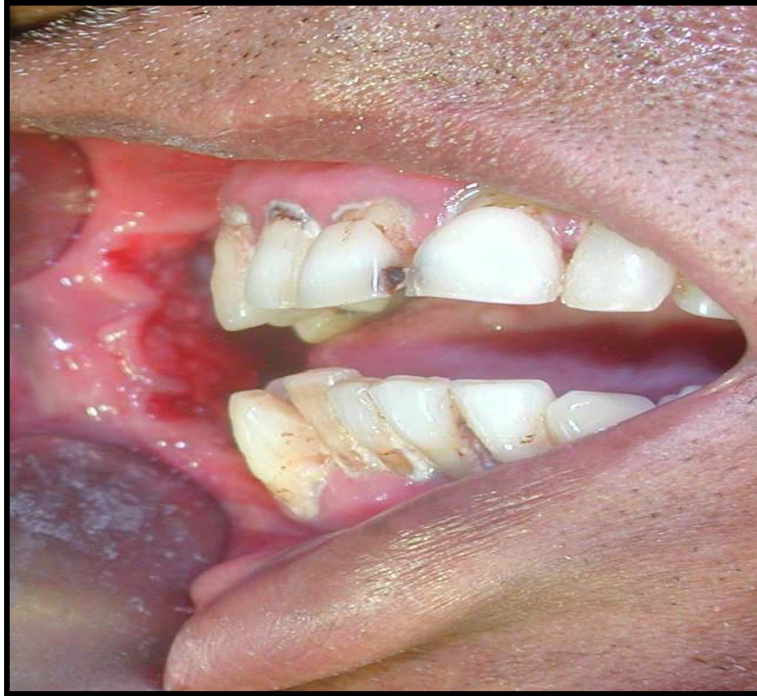**4A and 4B:** Typical SCC of Mandibular GBC included in the study.



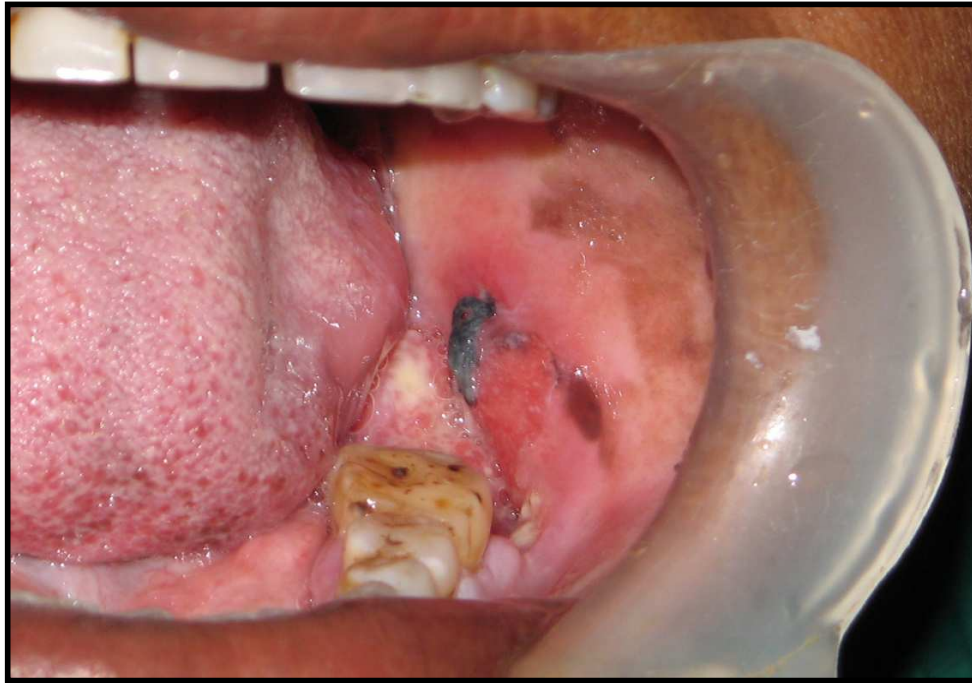
**5A:** Suspected gross bone erosion clinically in a patient with Mandibular GBC- SCC



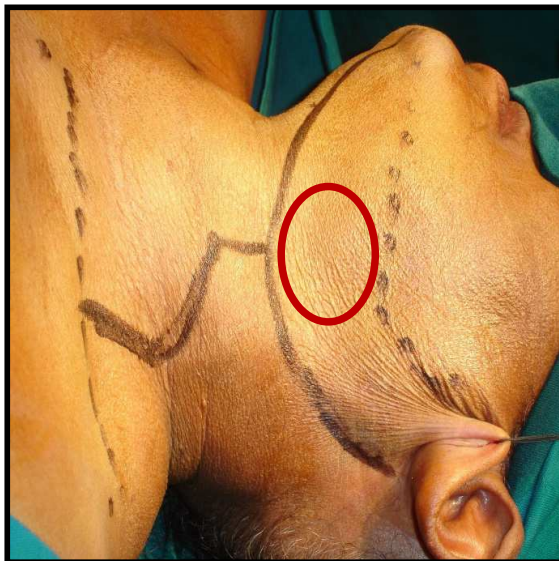**5B:** Gross bone erosion confirmed by Contrast Enhanced CT images



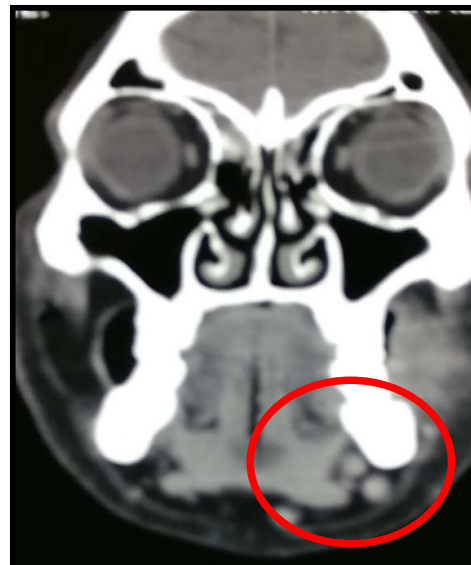
**6A and 6B:** A patient with trismus and skin infiltration by primary GBC-SCC



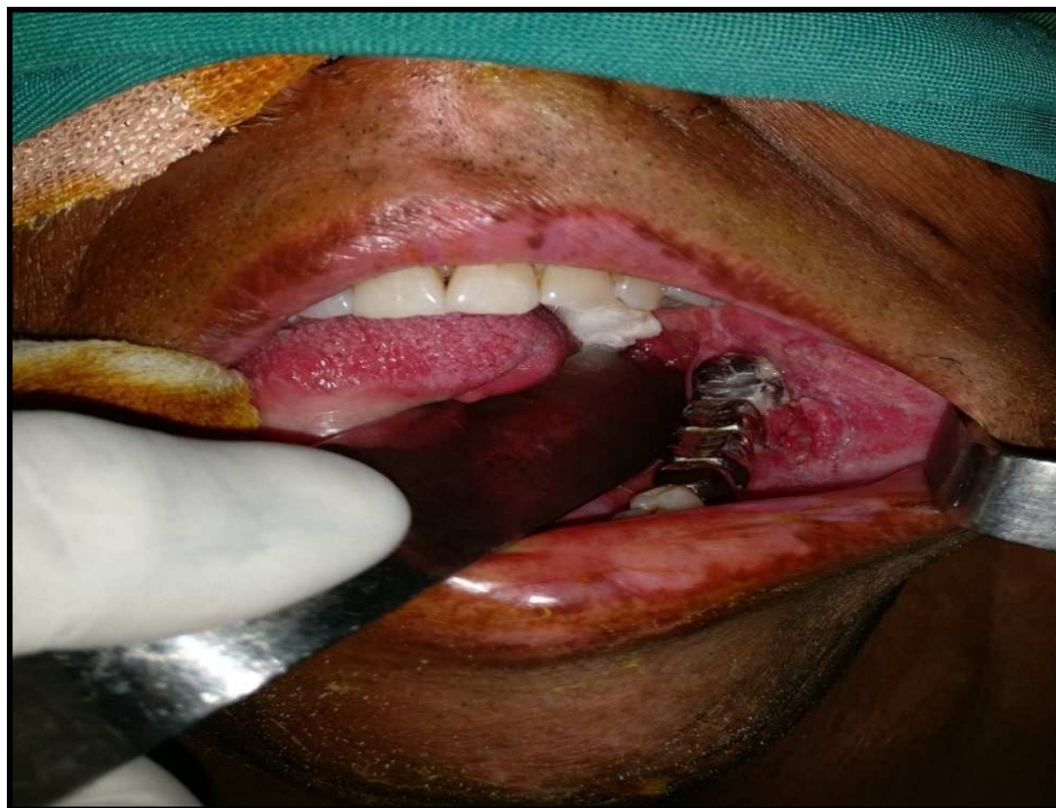**7A:** A Patient (XYZ) with left GBC-SCC



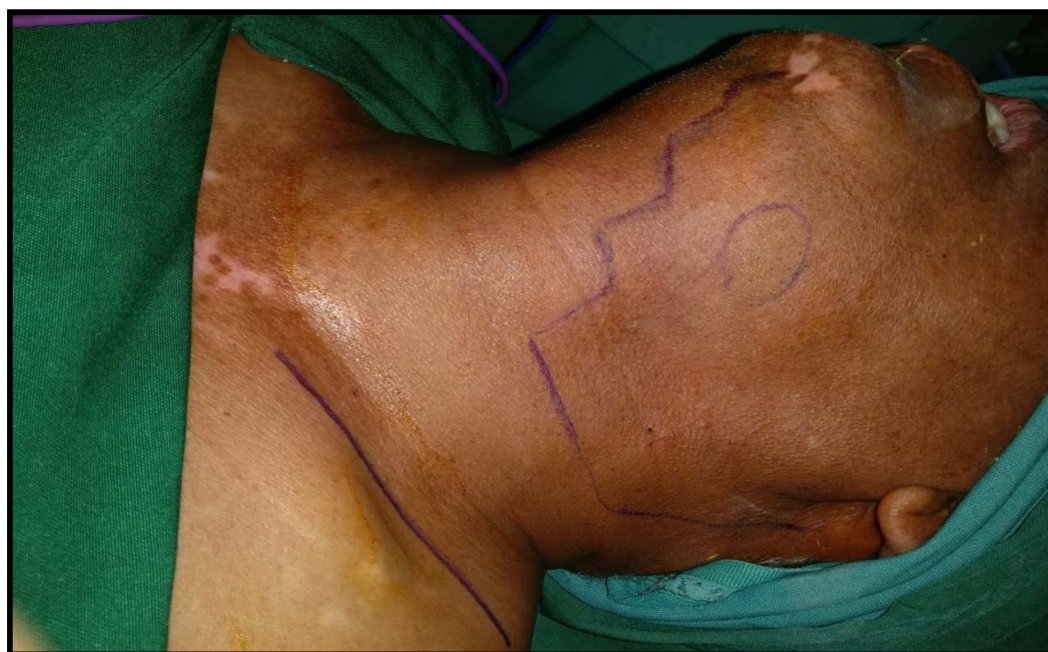**7B:** Palpable left level IB node



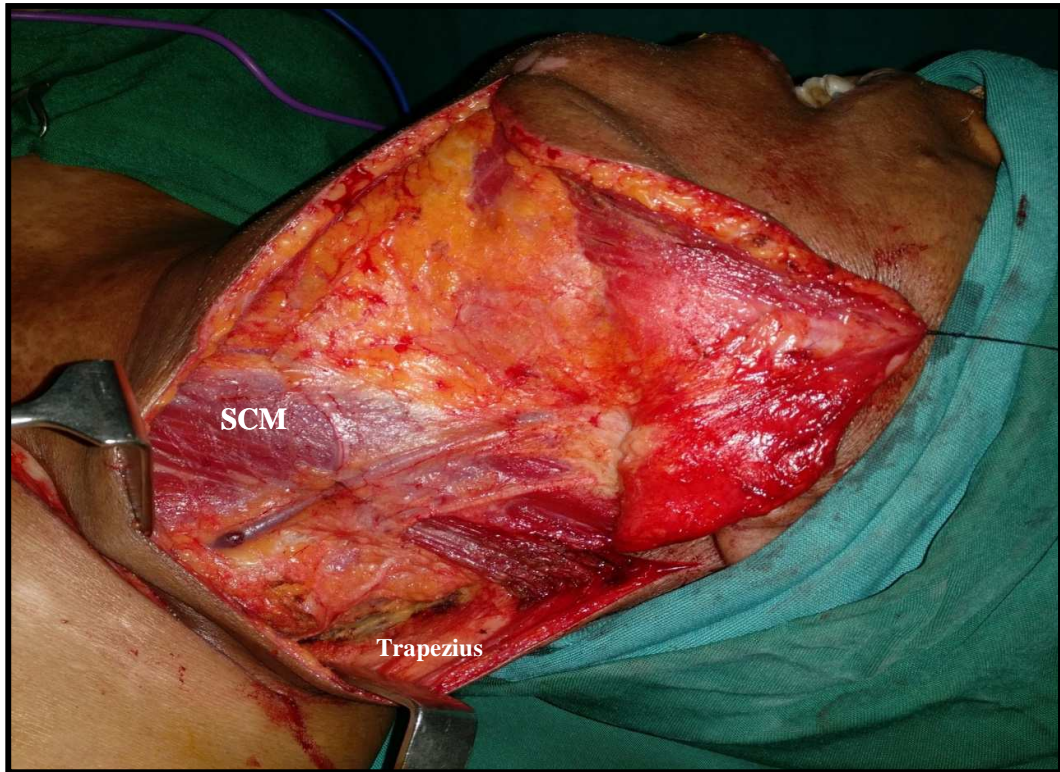
**7C:** Node Positivity of left level IB node in Patient (XYZ) confirmed CECT imaging



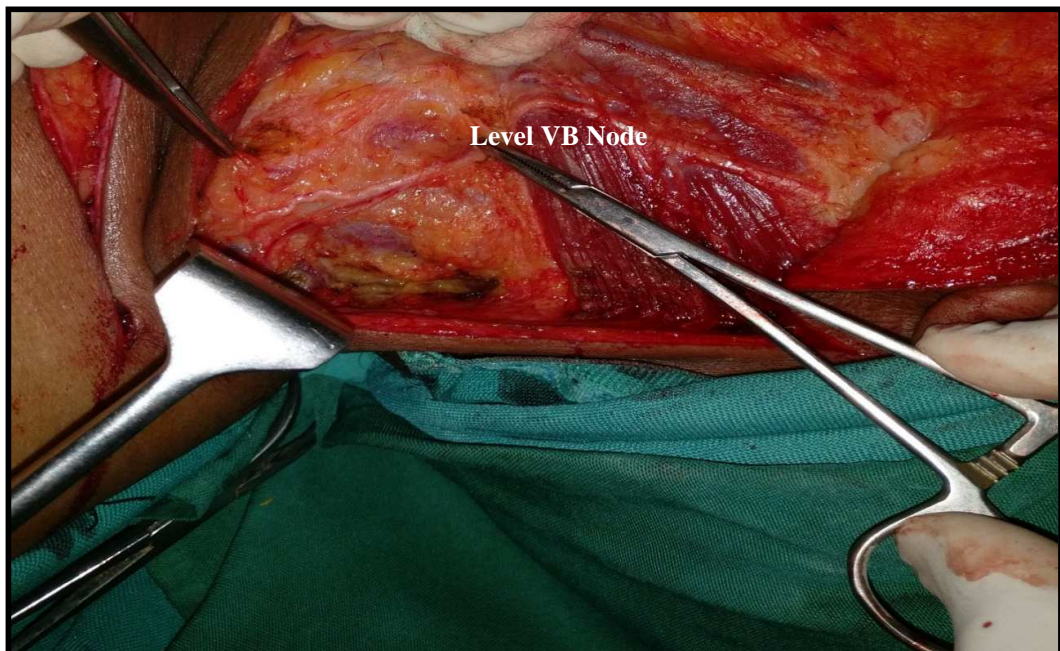
**8A:** A patient (ABC) with SCC of left mandibular GBC-SCC.



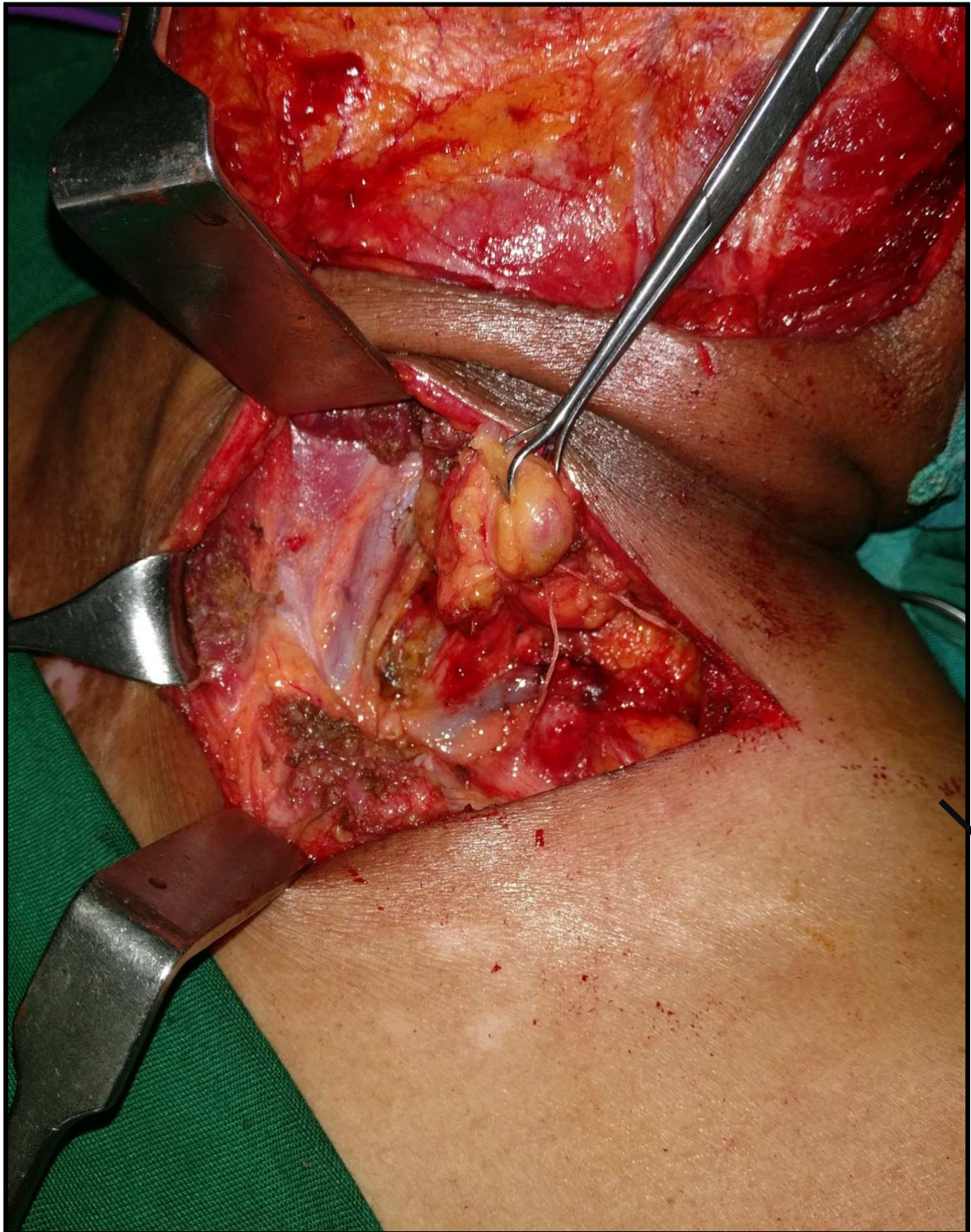**8B:** Neck incisions for level I-V clearance and palpable Left level IB node.



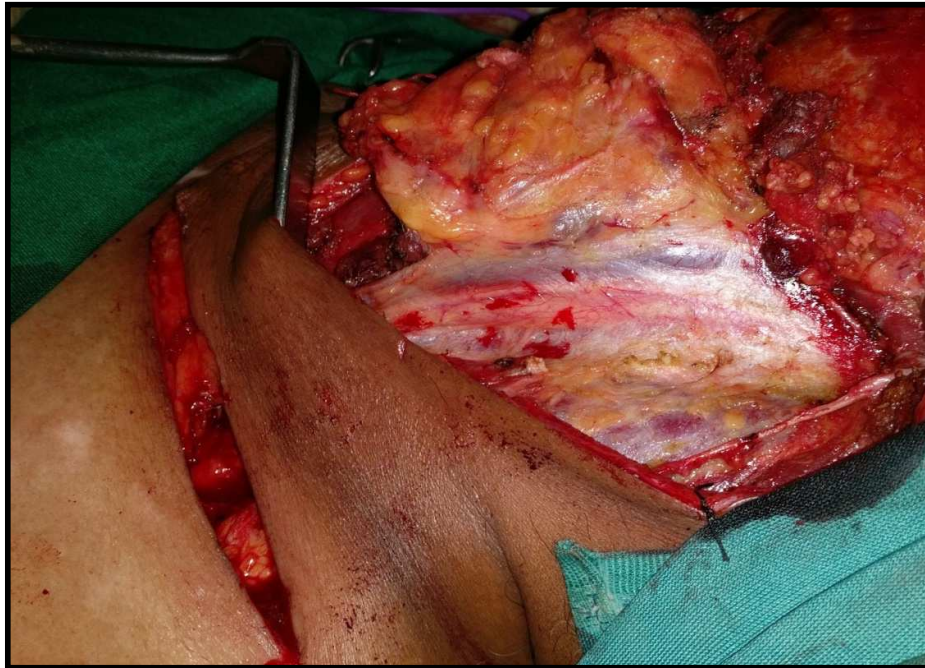
**9A:** Defining the limits of ND field and nodal levels



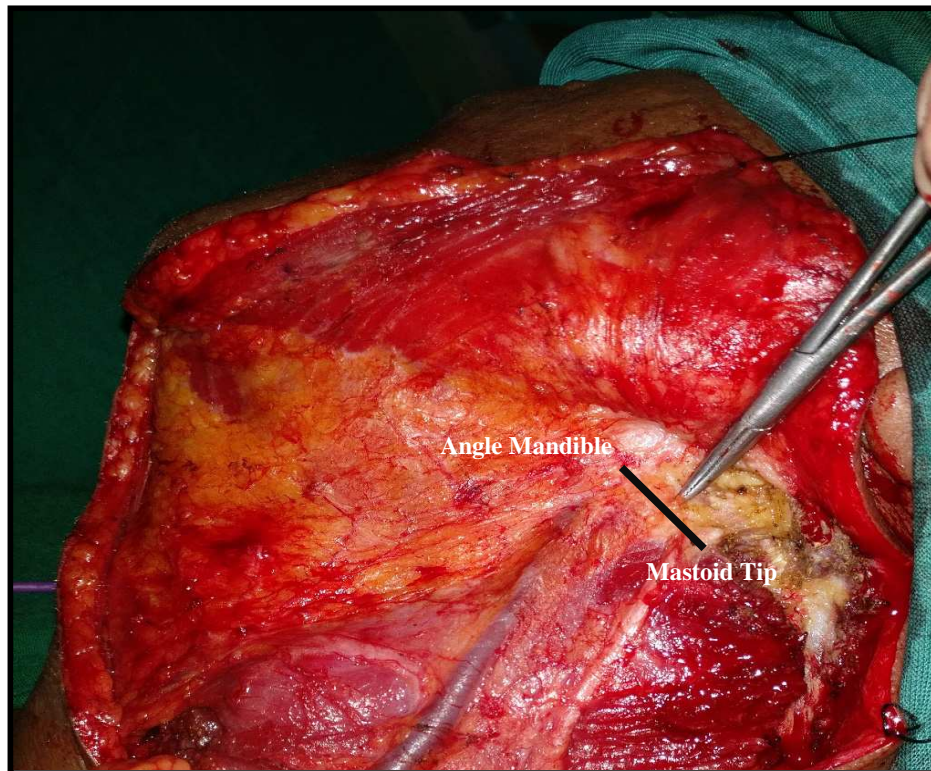
**9B:** Preparing to dissect level VA and VB nodes with spinal accessory nerve under vision (Haemostat pointing at level VB node)



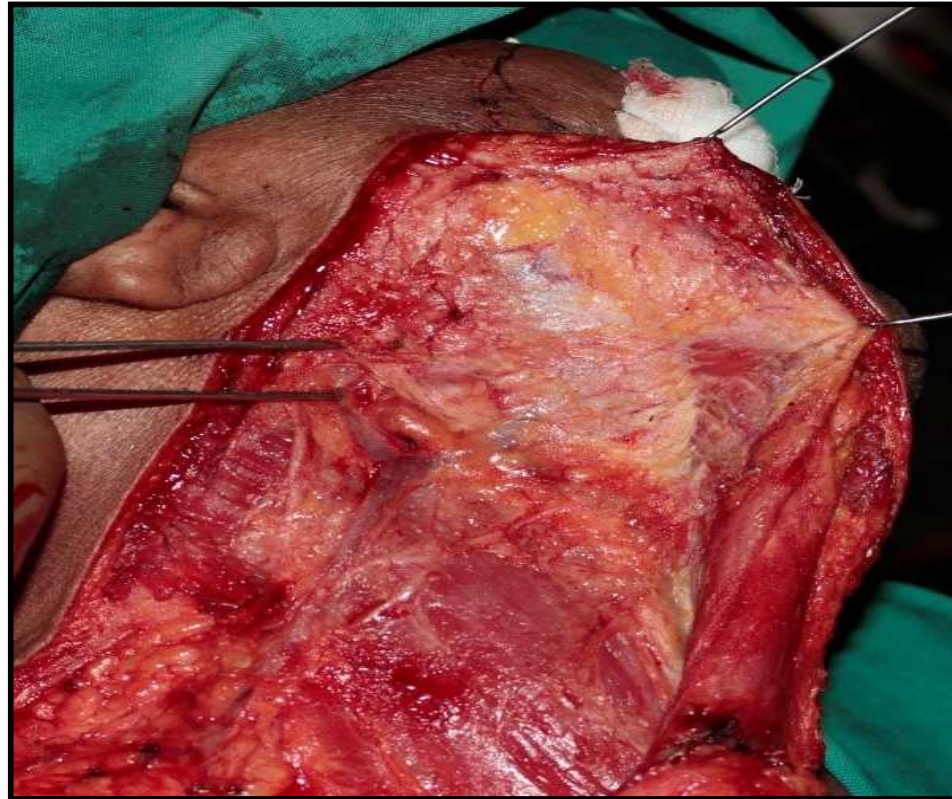
**10:** Lower end of SCM muscle sacrificed and level IV nodes being dissected from their territory with suture ligatures denoting their identity



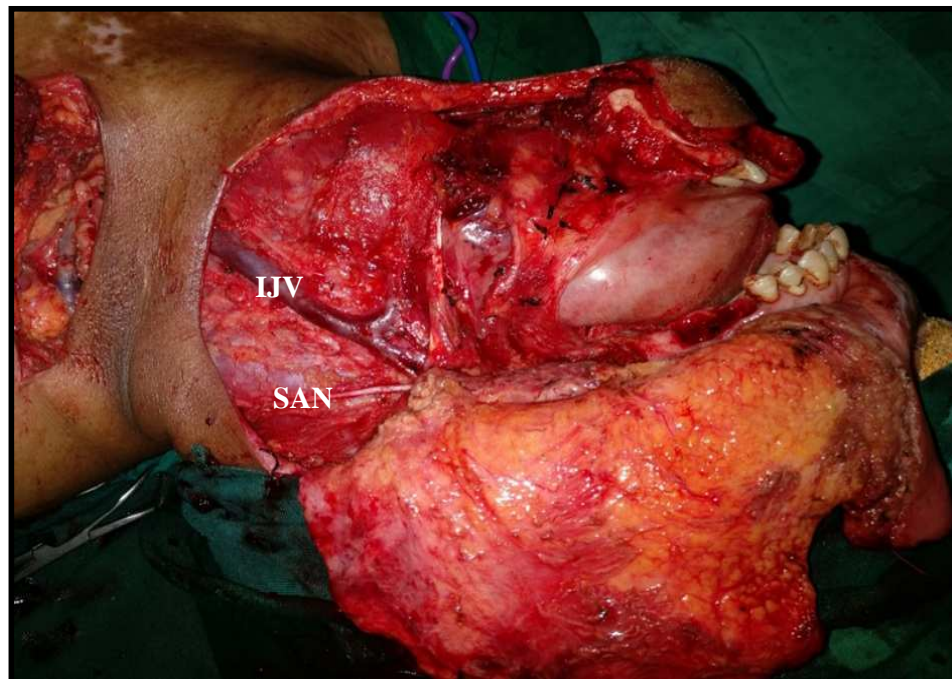
11: Dissection of other nodal levels



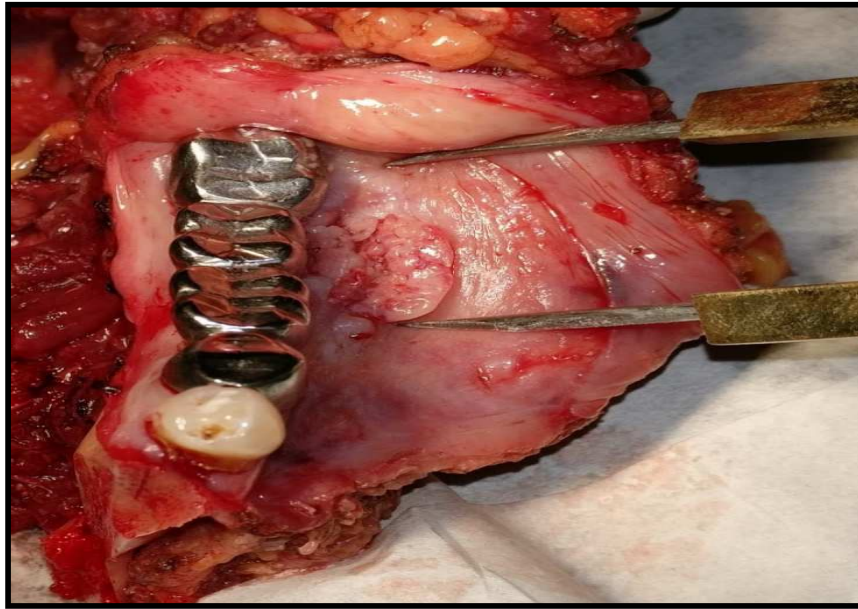
12A: Identification of tail parotid nodes



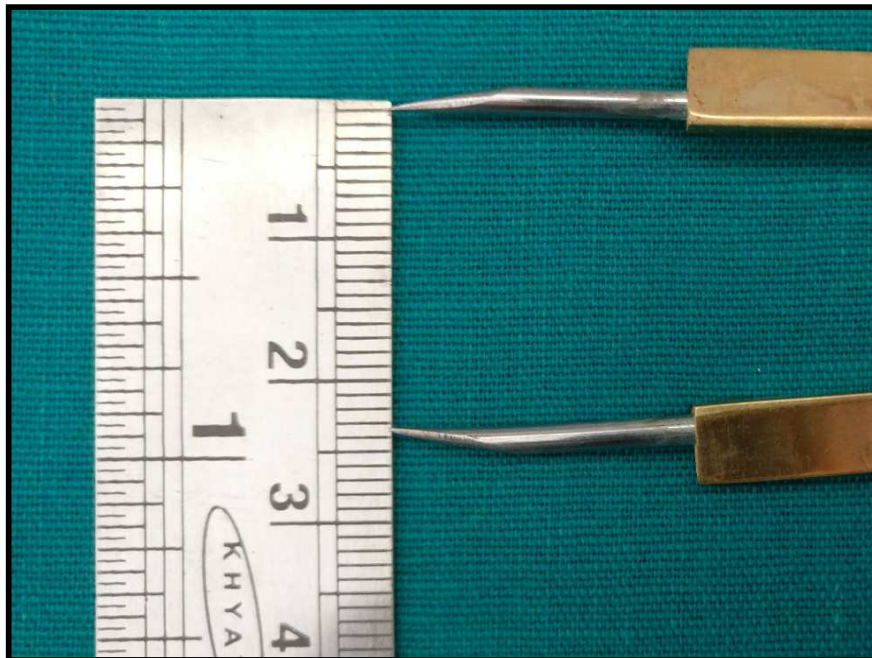
**12B:** Tail parotid nodes overlying posterior digastric muscle along the exit of retromandibular vein.



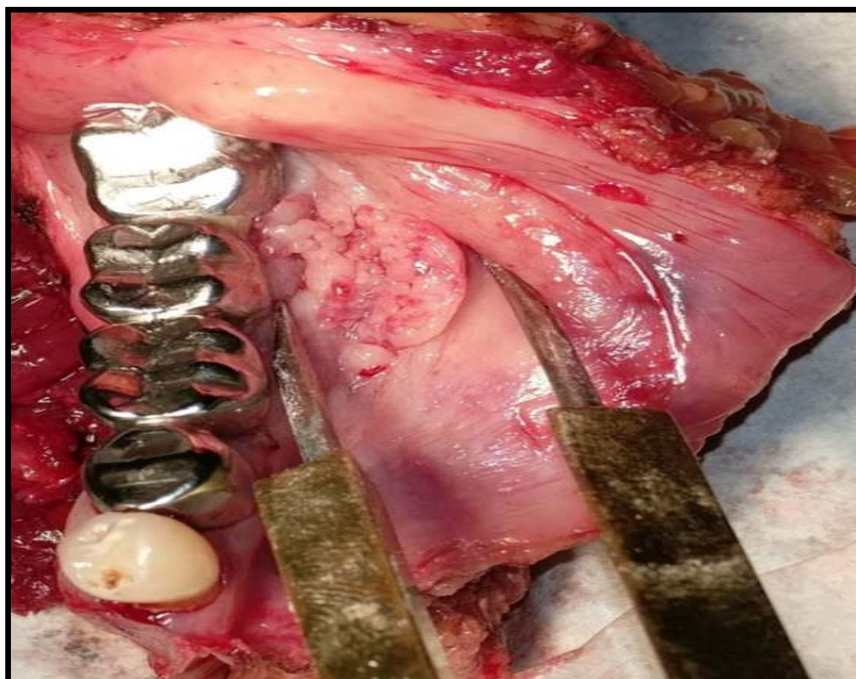
**13:** Completion of en-block MND II with resection of tumor.




**14A:** Measurement of T- length



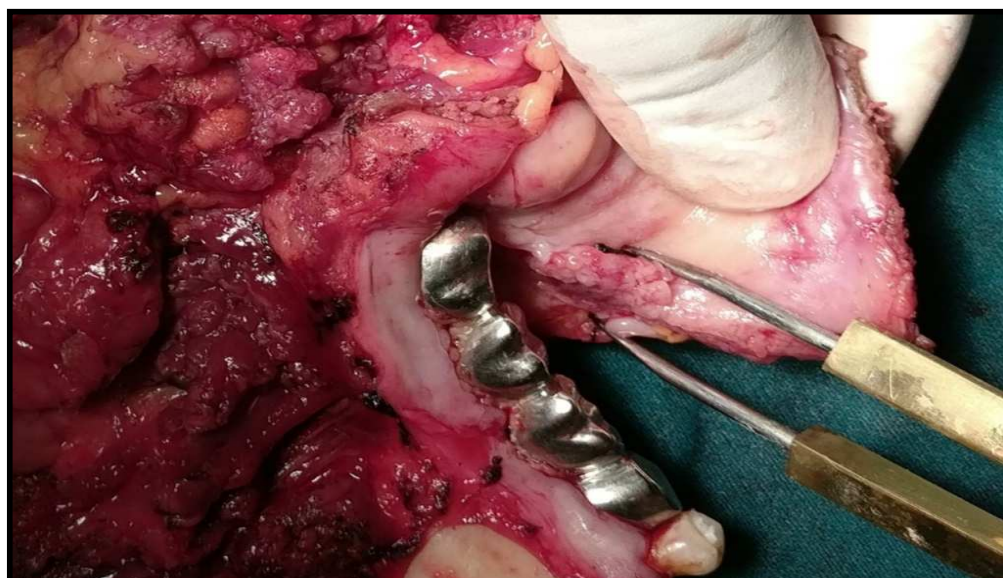
**14 B:** T-length measured 2.3 cm



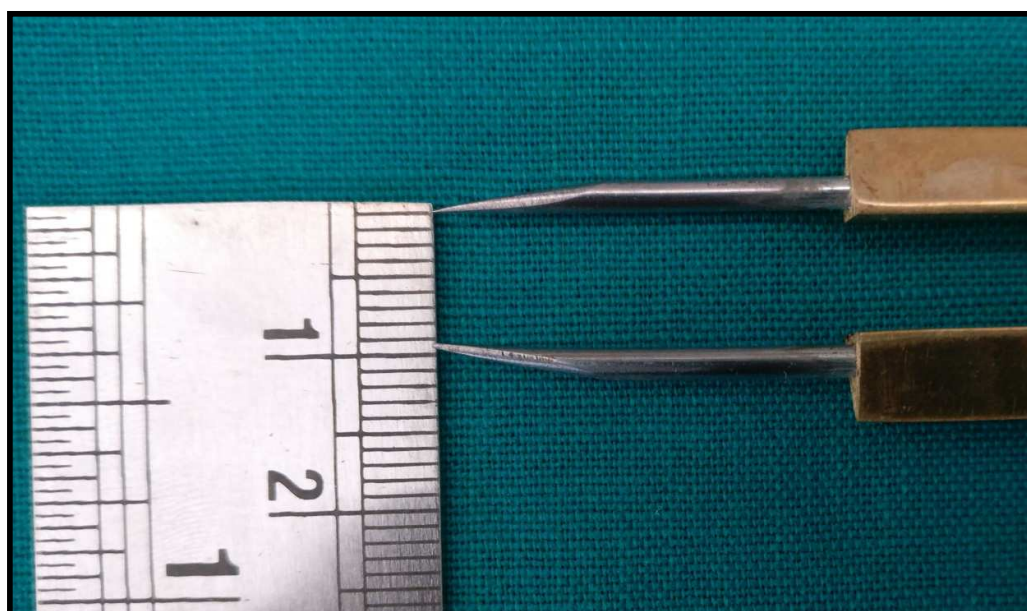**15A:** T-breadth measurement



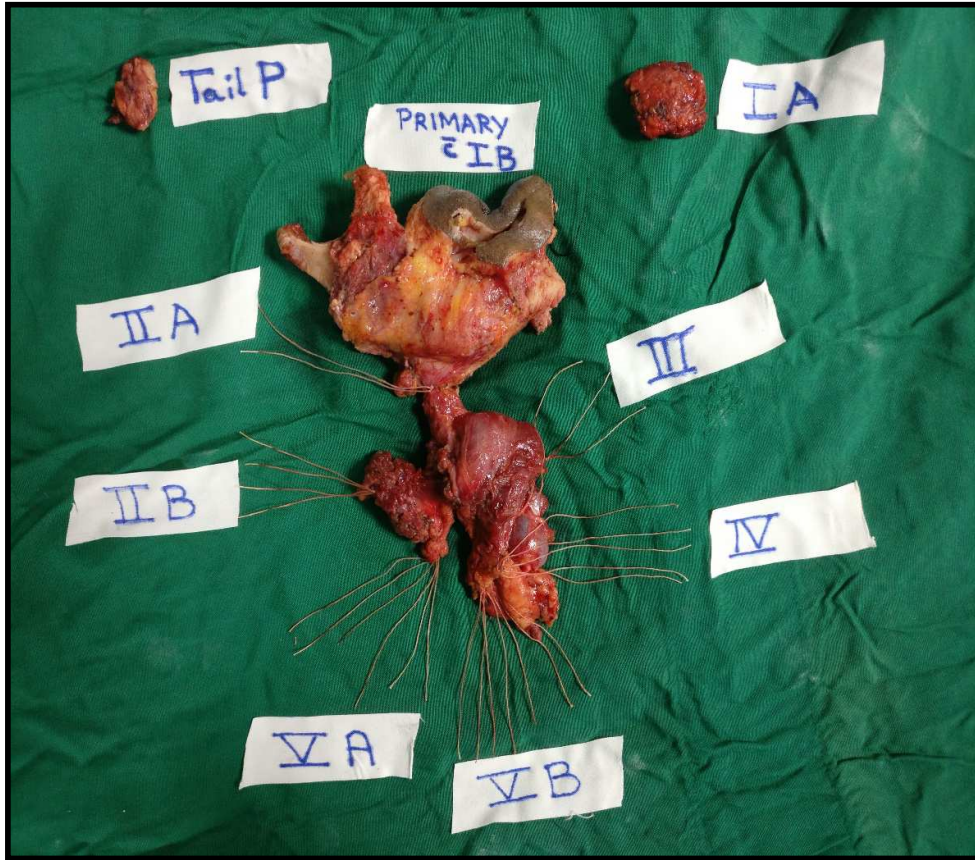
**15B:** T-breadth measured 1.4cm



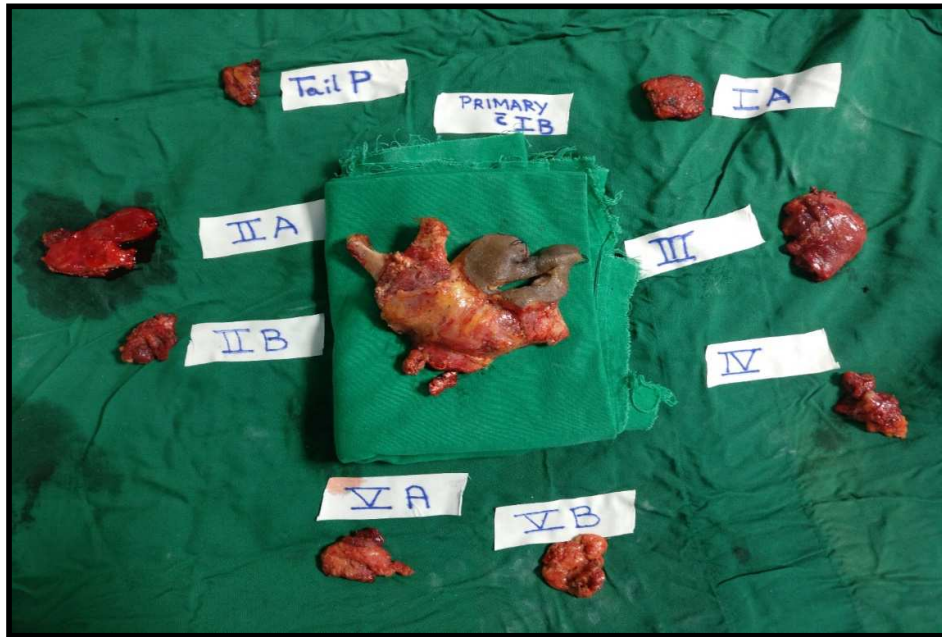
**16A:** Measurement of GTT- black silk sutures used to ensure measurement between fixed points



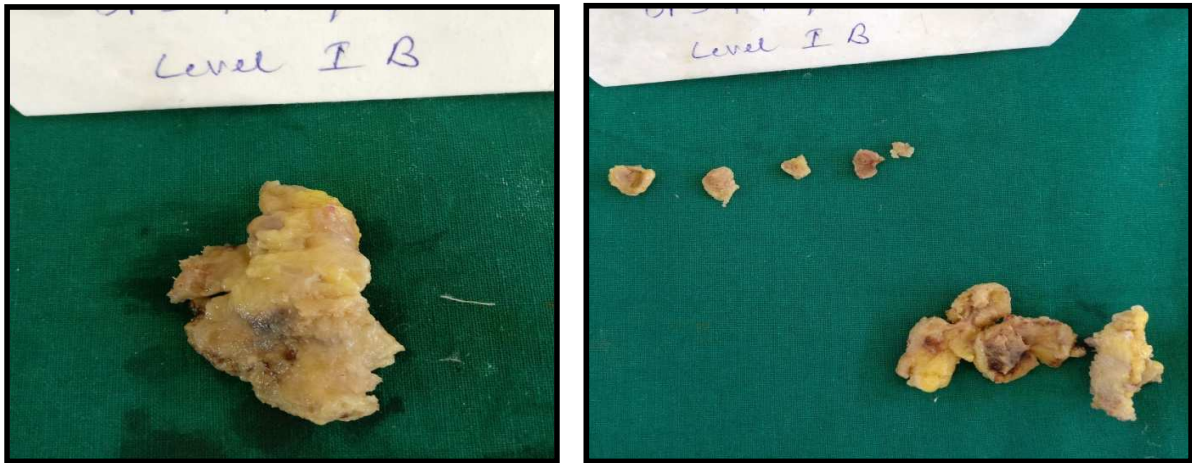**16B:** GTT measured 0.9 cm



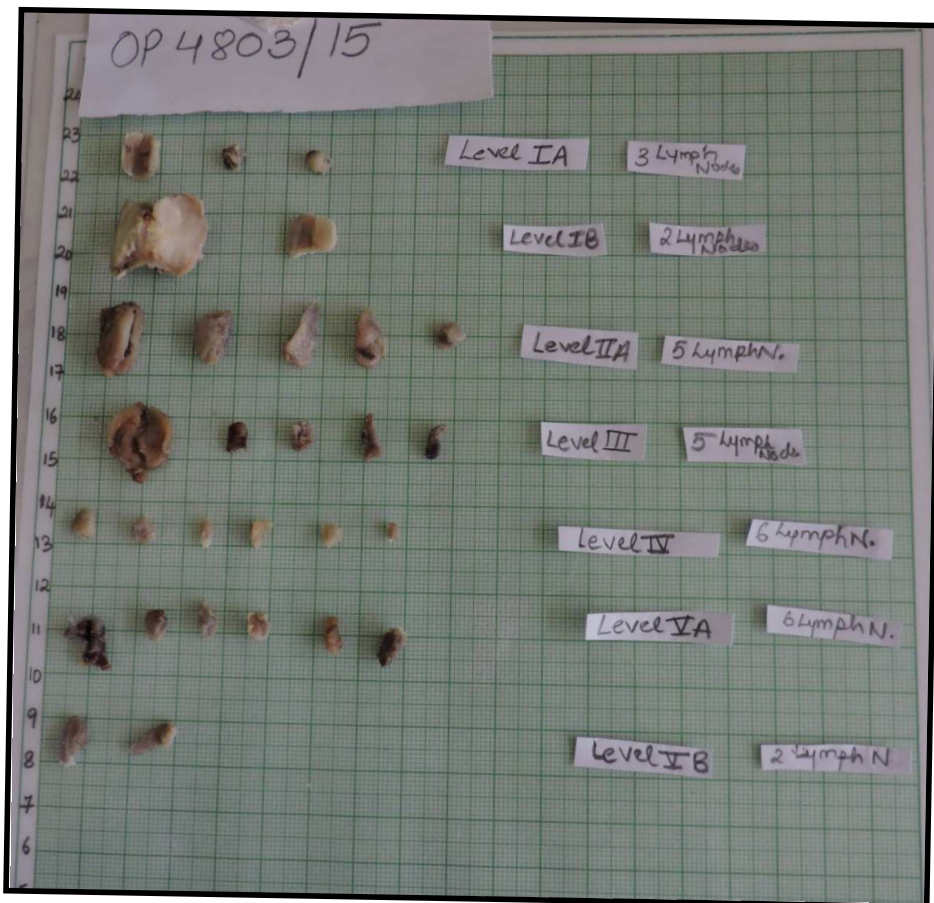
17: Orientation of specimen and identification of nodal levels (with reference to Table 1).



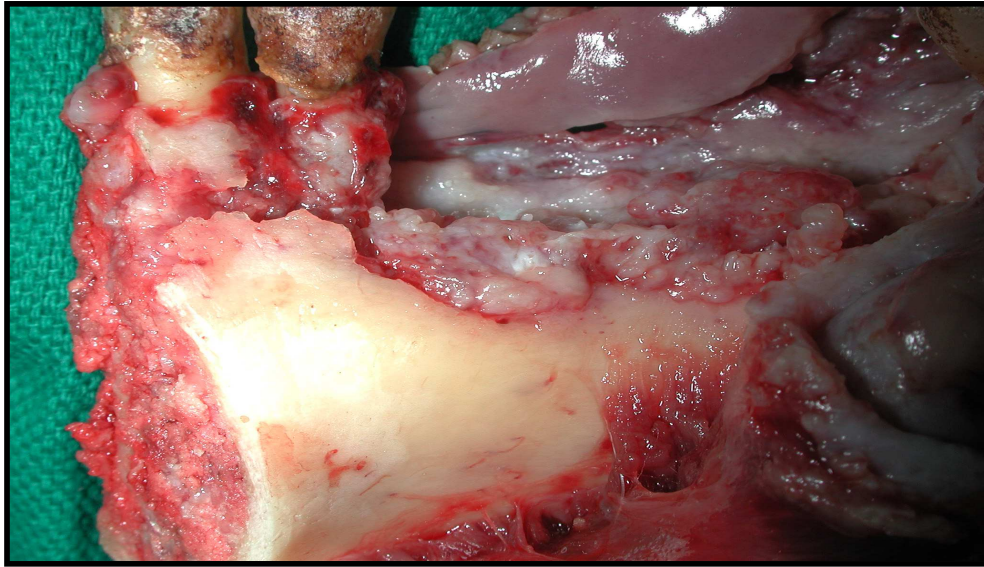
18: Separation of all nodal levels and primary tumor with level IB nodes.



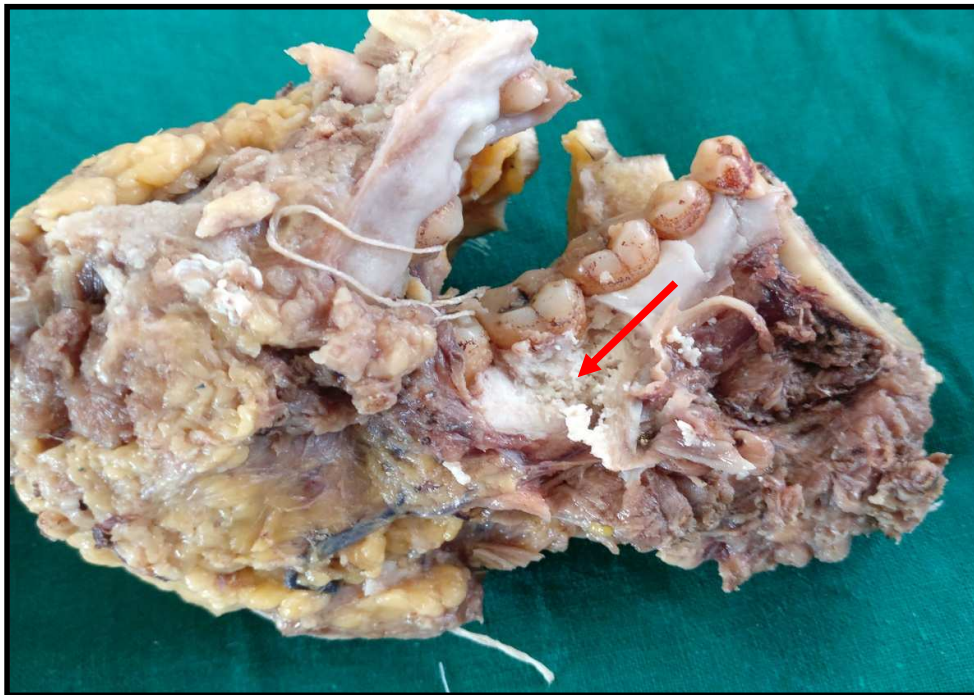
**19A and 19B:** Harvest of nodes from individual levels 48 hours after 10% buffered formalin fixation



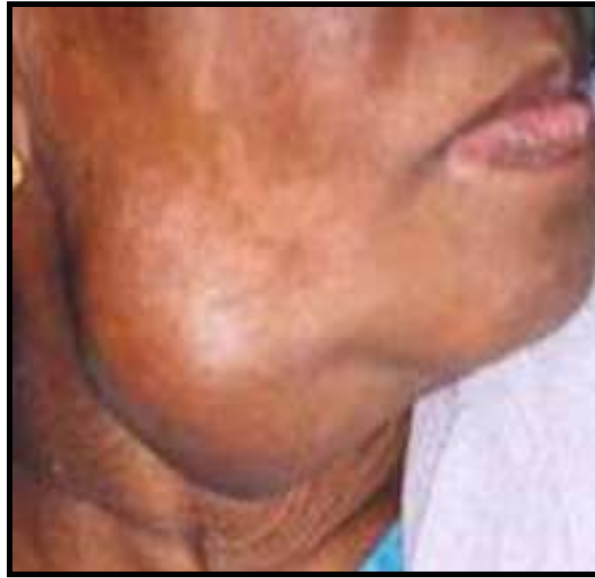**20:** Completion of node harvesting from individual nodal levels with number of nodes harvested from each level



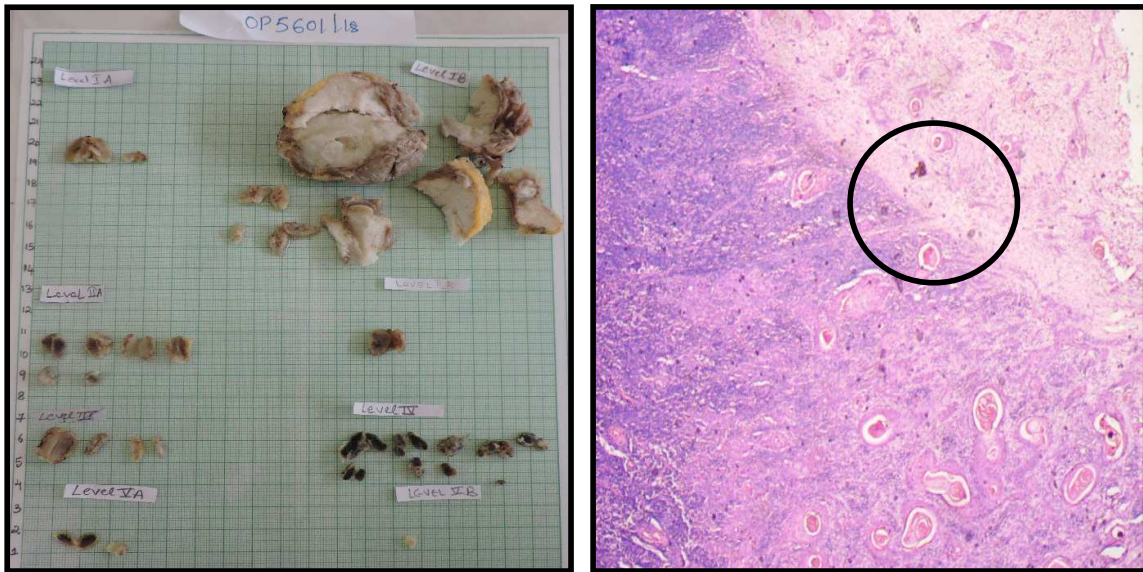
**21A.** Gross bone erosion by GBC-SCC



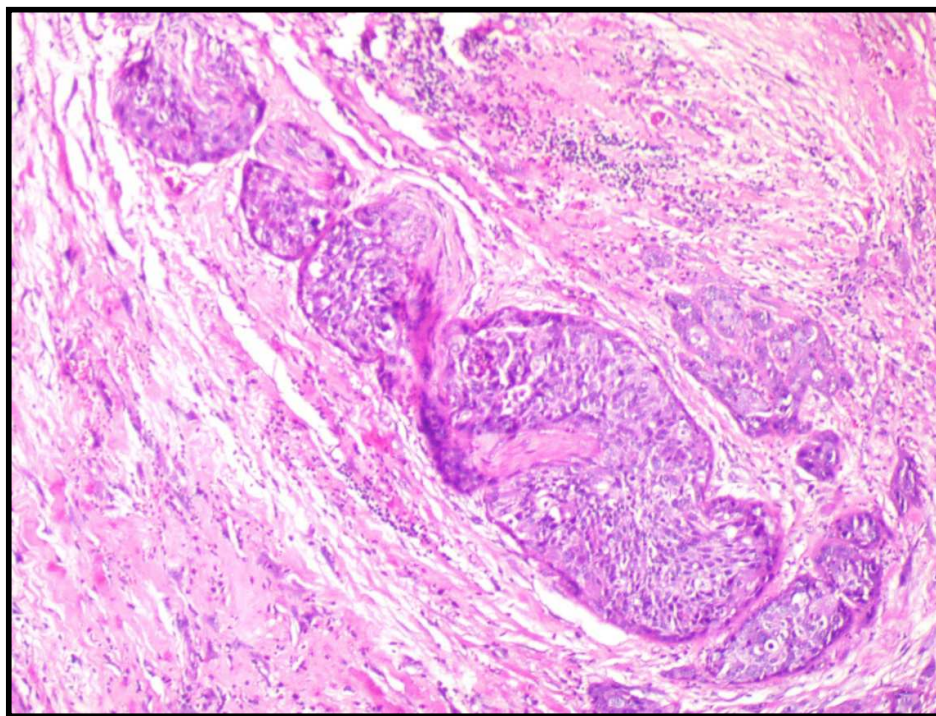
**21 B:** Gross bone erosion evident during grossing of the specimen after 48 hours of 10% buffered formalin fixation.



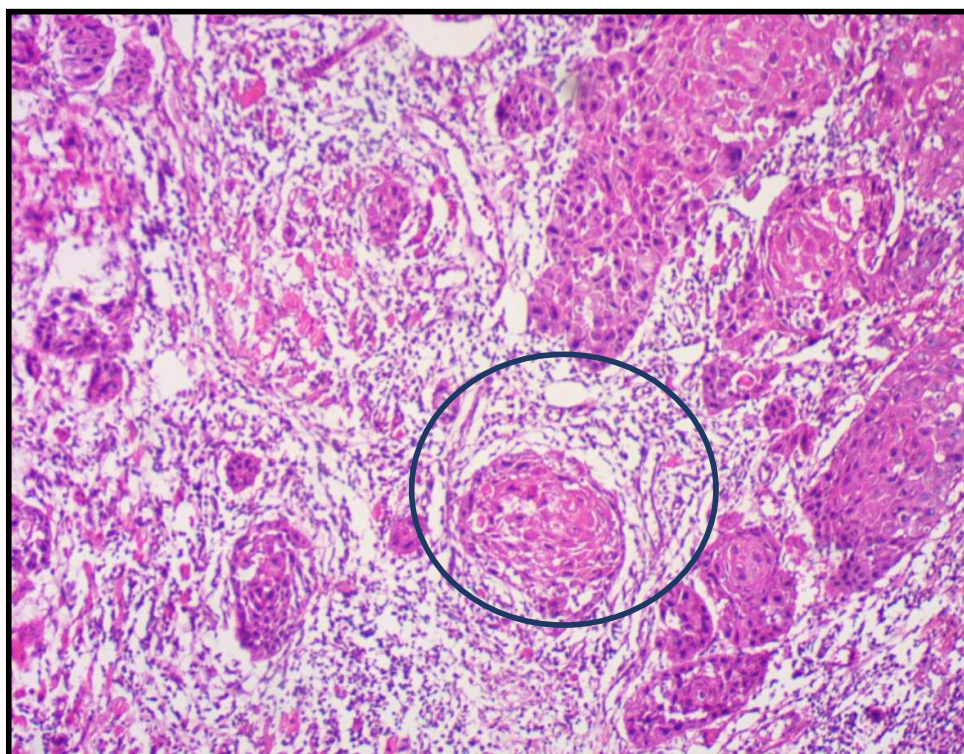
22A. Extra-capsular spread at level IB in a patient MNO



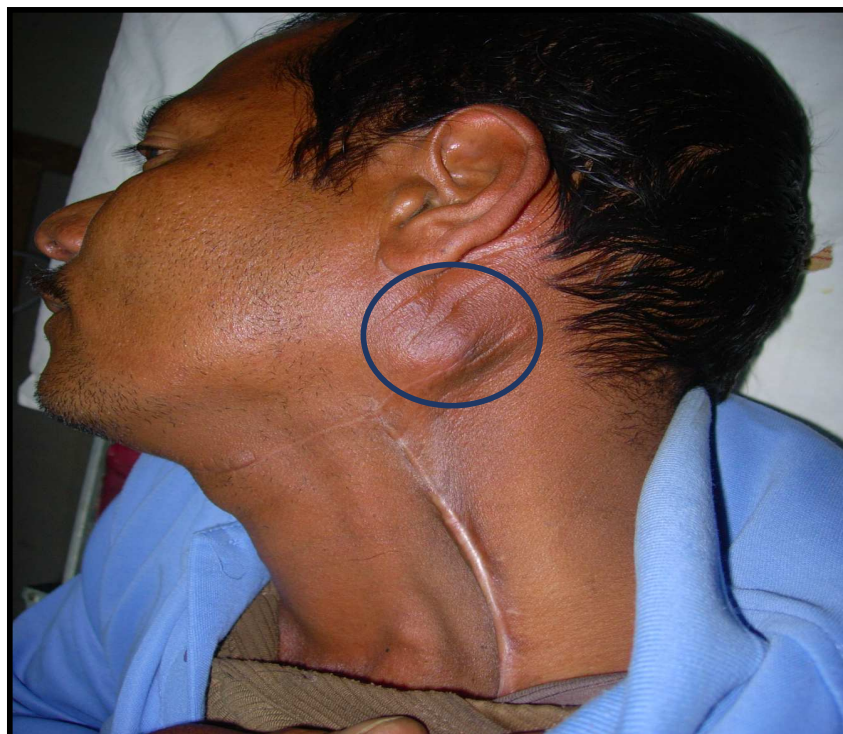22 B&C: ECS in IB node during grossing evident in histopathological section in patient MNO



**23:** Peri-neural Invasion



**24.** Well differentiated tumour with advancing front showing moderate differentiation



**25.** Failure at tail parotid region after therapy for GBC-SCC –such failures seen in our previous cases promoted us to include tail parotid nodes in this study

---

## RESULTS

There were 69 (53.1%) patients with age over 50 years and 61 (46.9%) patients with  $\leq 50$  years (**Table 4**). The majority of our study patients were males 106 (81.5%) and the number of female patients was 24 (18.5%). Sixty-six (50.8%) patients had right sided lesions and 64 (49.2%) patients presented with left sided lesions (**Table 5**). Tobacco and arecanut chewing habit were found in approximately 90% of our patients, followed by alcohol consumption in 41 (31.5%) patients and smoking in 23 (17.7%) patients. Ninety-nine (76.2%) patients practiced the habits for over 10 years and in 31 (23.8%) patients the duration of habits ranged from 5-10 years. Twenty-two (17%) patients had all four habits (**Table 6**).

When the clinical factors were studied in 130 patients, OSMF was a common PMD found in 41 (31.5%) patients followed by leukoplakia and /or leukoerythroplakia in 27 (20.8%) patients. Clinically, there was no evidence of PMDs in 62 (47.7%) patients. Clinico-radiological evidence of masticator space infiltration by the tumour was present in 57 (43.8%) patients and no such manifestation was seen in 73 (56.2%) patients. As per AJCC 2009 nodal staging for oral cancer, 48 (37%) patients which was a majority, were clinically N1 staged followed by 45 (35%) patients which were clinically N0 staged. In 37 (28.5%) patients the clinical nodal staging was N2 or N3. There was clinico-radiological evidence of bone infiltration by the tumour in 43 (33%) patients whereas bone infiltration by the tumour was absent in 87 (67%) patients. Clinically the tumour was found to infiltrate into the skin in 28 (21.5%) patients and in 102 (78.5%) cases skin was free of infiltration (**Table 7**).

When the tumour size was measured intra-operatively following resection of the tumour in 130 study patients, majority of our patients presented with T4 67,

(51.5%) and T3 28 (21.5%) stages as per AJCC 2009 staging for oral cancer. The number of patients with T1 and T2 staged tumors were comparatively less, amounting to approximately 13% cases in each category. The GTT measured intra-operatively was  $\leq 1$ cm in 80 (61.5%) patients and it was over 1cm in 50 (38.5%) patients (**Table 8**).

When the pathological factors were studied in 130 study patients, 80 (61.5%) patients were reported with well to moderate HD of tumour and 50 (38.5%) patients were reported with moderate to poor HD. ECS in the lymph-nodes was reported in 25 (19.2%) patients and it was negative in 105 (81%) patients. LVE and PNI was reported histologically in 15 (11.5%) and 28 (21.5%) patients respectively (**Table 9**). When the clinical nodal staging (cN staging) and pathological nodal staging (pN staging) were compared in 130 study subjects, among 45 patients that were clinically staged as negative for nodal metastasis, 36 patients were positive for nodal metastasis pathologically and only 9 patients were reported to be pathologically node-negative. Eighty three out of 85 patients that were clinically staged as node-positive were confirmed also to have pathological node-positive. Only two patients in clinical node-positive category were negative for nodal-metastasis on pathological examination (**Table 10**). When Chi-square test was used for studying patients with level of nodal metastasis, age was significantly associated with level of positive node ( $p < 0.005$ ). Approximately 60% of patients  $> 50$  years of age had multi-level lymph-node metastasis (**Table 11**). Laterality of the tumour was insignificantly associated with level of positive node on application of Chi-square test (**Table 12**). When Chi-square test was used to study the association of patient's habits and duration of habits with the level of lymph-node metastasis, smoking, alcohol consumption and duration of habits over 10 years showed strong evidence of association with level of lymph-node

metastasis ( $p < 0.05$ ) and were statistically significant. Fifty six percent of patients with multi-level lymph-node metastasis admitted to have practiced deleterious habits for over 10 years (**Table 13**). On studying the association of PMLs with multi-level nodal metastasis using Chi-square test, the results were statistically significant (**Table 14**).

When Chi-square test was used to study the association of clinical factors and level of positive nodes, Clinico-radiological bone erosion, skin infiltration by the tumour and infiltration into masticatory space showed strong evidence of association with multi-level nodal metastasis and were statistically significant ( $p < 0.001$ ). Eighty two percent of patients with multi-level lymph-node metastasis showed tumour infiltration into masticator spaces (**Table 15**). Chi-square test showed strong evidence of association of clinical nodal status and level of positive node, which was statistically significant with  $p < 0.001$ . Multi-level lymph-node metastasis was high in patients presenting with clinically N2 and N3 nodes (**Table 16**). Among the pathological factors studied, the three pathological factors namely HD on biopsy, LVE and PNI were significantly associated with the level of positive nodes ( $p < 0.05$ ) as shown in **Table 17**. Intra-operative T-size and Intra-operative GTT showed strong evidence of association with level of positive nodes (**Table 18**). There was a highly significant association with these factors and level of positive nodes ( $p < 0.05$ ). Multi-level lymph-node metastasis was common in patients with T3 and T4 staged tumors (59%) and tumors measuring over 1cm in thickness on gross measurement (88%). Out of 130 patients, modified radical neck dissections (Type II MRND) were done in 122 (94%) patients and radical neck dissections (RND) were done in 8 (6%) patients. In the former procedure internal jugular vein and spinal accessory nerve were preserved with sacrifice of sternocleidomastoid muscle whereas, in the latter, all three extra-lymphatic structures were sacrificed. Out of 130 patients, 91 (70%) underwent

composite resection, 24 (19%) underwent bite composite resection and in 15 (11%) marginal mandibulectomy was done (**Table 19**). When step-wise logistic regression was applied for studying the association of clinico-pathological factors (independent variables) and level of positive node (dependent variable), the gender, masticator space infiltration, clinical nodal status, biopsy (histological differentiation), intra-operative T-size and GTT which were found to be significantly associated. Other factors were insignificant (**Table 20**). When ROC test was applied, Masticator space infiltration, Intra-operative T-size and Intra-operative GTT were significant predictors of multi-level lymph-node metastasis. The Area under curve for masticator space infiltration, intra-operative T-size and GTT were 22.2%, 62 % and 78.6% respectively. Among these three factors, intra-operative GTT was found to have higher sensitivity and specificity for predicting multi-level nodal metastasis (**Table 21**).

The highest number of lymph-nodes were harvested from level IV, level IB and level III whereas level VB, level IIB and tail parotid yielded a smaller number of nodes (**Table 22**). In 71 (54.6%) patients tail parotid nodes were absent. Only in 15 (11.5%) patients they were positive for metastasis (**Table 23**).

In 130 patients a total of 3046 lymph-nodes were harvested and studied. The mean number of lymph-nodes harvested was  $23.61 \pm 5.15$  with a range of 14-37 (**Table 24**).

**Table 4:** Demographic details of patients.

<b>Variable</b>	<b>No. of Patients</b>	<b>Percentage (%)</b>
Age (Years)		
< or equal to 50	61	46.9
> 50 years	69	53.1
Gender		
Male	106	81.5
Female	24	18.5

**Table 5: Laterality of the tumor in 130 patients with primary mandibular GBC-SCC.**

<b>Variable</b>	<b>No. of Patients</b>	<b>Percentage (%)</b>
Side		
Right	66	50.8
Left	64	49.2

**Table 6: Details of Patient's deleterious habits.**

<b>Habits</b>	<b>No. of Patients</b>	<b>Percentage (%)</b>
Arecanut chewing		
Yes	123	94.6
No	7	5.4
Tobacco chewing		
Yes	112	86.2
No	18	13.8
Smoking		
Yes	23	17.7
No	107	82.3
Alcohol consumption		
Yes	41	31.5
No	89	68.5
Duration of Habits		
5-10 Years	31	23.8
> 10 years	99	76.2

**Table 7: Clinical factors of 130 study patients.**

<b>Clinical Factor</b>	<b>No. of Patients</b>	<b>Percentage (%)</b>
Potentially Malignant Disorders		
No PMDs	62	47.7
Leukoplakia / erythroplakia/ both	27	20.8
OSMF	41	31.5
Masticator Space Infiltration		
Present	57	43.8
Absent	73	56.2
Clinical Nodal Status		
cN0	45	34.61
cN1	48	36.92
cN2	16	12.30
cN3	21	16.15
Clinico-radiological Bone erosion		
Yes	43	33.1
No	87	66.9
Skin infiltration		
Present	28	21.5
Absent	102	78.5

**Table 8: Intra-operative factors measured during surgery in 130 study patients.**

<b>Intra-operative factor</b>	<b>No. of Patients</b>	<b>Percentage (%)</b>
T size		
T1	18	13.84
T2	17	13.07
T3	28	21.53
T4	67	51.53
Gross Tumour Thickness		
< or equal to 1 cm	80	61.5
> 1cm	50	38.5

**Table 9:** Pathological factors of 130 study patients.

Pathological factor	No. of patients	Percentage (%)
<b>Biopsy</b>		
Well to moderate differentiation	80	61.5
Moderate to poor differentiation	50	38.5
<b>Extracapsular spread</b>		
Present	25	19.2
Absent	105	80.8
<b>Lympho-vascular emboli</b>		
Present	15	11.5
Absent	115	88.5
<b>Perineural invasion</b>		
Present	28	21.5
Absent	102	78.5

**Table 10:** Clinical and pathological nodal status in 130 study subjects.

	pN0	pN+	Total
cN0	9	36	45
cN+	2	83	85
<b>Total</b>	<b>11</b>	<b>119</b>	<b>130</b>

**Table 11:** Demographic details and their association with level of positive nodes.

	Level of positive node		Total (n=130)	Chi-square value	p- value	df
	cases with N0 or level I metastasis (N1)	Cases with multilevel nodal metastasis				
<b>Age (Years)</b>						
<b>&lt; or equal to 50</b>	36 (59%)	25 (41%)	61 (100%)			
<b>&gt; 50 years</b>	28 (40.6%)	41(59.4%)	69 (100%)	4.40	0.027*	1
<b>Gender</b>						
<b>Male</b>	49 (46.2%)	57 (53.8%)	106 (100%)	2.07	0.112	1
<b>Female</b>	15 (62.5%)	9 (37.5%)	24 (100%)			

\* statistically significant (p<0.05)

**Table 12:** Laterality of the tumour and its association with level of positive node.

Laterality of the tumour	Level of positive node		Total (n=130)	Chi-square value	p- value	df
	cases with N0 or level I metastasis (N1)	Cases with multilevel nodal metastasis				
<b>Side</b>						
<b>Right</b>	32 (48.5%)	34 (51.5%)	66 (100%)			
<b>Left</b>	32 (50%)	32 (50%)	64 (100%)	0.030	0.501	1

**Table 13:** Habits and their association with level of positive nodes.

	Level of positive node		Total (n=130)	Chi-square value	p-value	df
	cases with N0 or level I metastasis (N1)	Cases with multilevel nodal metastasis				
<b>Areca nut Chewing</b>						
<b>Yes</b>	62 (50.4%)	61 (49.6%)	123(100%)	1.26	0.233	1
<b>No</b>	2 (28.6%)	5 (71.4%)	7 (100%)			
<b>Tobacco Chewing</b>						
<b>Yes</b>	54 (48.2%)	58 (51.8%)	112 (100%)	0.334	0.373	1
<b>No</b>	10 (55.6%)	8 (44.4%)	18 (100%)			
<b>Smoking</b>						
<b>Yes</b>	7 (30.4%)	16 (69.6%)	23 (100%)	3.95	0.038*	1
<b>No</b>	57 (53.3%)	50 (46.7%)	107 (100%)			
<b>Alcohol Consumption</b>						
<b>Yes</b>	14 (34.1%)	27 (65.9%)	41 (100%)	5.45	0.016*	1
<b>No</b>	50 (56.2%)	39 (43.8%)	89 (100%)			
<b>Duration of Habits</b>						
<b>5-10 Years</b>	21 (67.7%)	10 (32.3%)	31 (100%)	5.58	0.015*	1
<b>&gt;10 Years</b>	43 (43.4%)	56 (56.6%)	99 (100%)			

\* Statistically significant (p<0.05)

**Table 14:** Potentially Malignant Disorders and their association with level of positive nodes.

Potentially Malignant Disorders (PMLs)	Level of positive node		Total (n=130)	Chi-square value	p-value	df
	cases with N0 or level I metastasis (N1)	Cases with multilevel nodal metastasis				
<b>No PMLs</b>	23 (37.1%)	39 (62.9%)	62 (100%)	11.48	0.003*	2
	28 (40.6%)	41(59.4%)	69 (100%)			
<b>Leukoplakia/ Erythroplakia/Leuko- erythroplakia</b>	12 (44.4%)	15 (55.6%)	27(100%)			
	15 (62.5%)	9 (37.5%)	24 (100%)			
<b>Oral Submucous Fibrosis</b>	29 (70.7%)	12 (29.3%)	41 (100%)			

\* statistically significant (p<0.05)

**Table 15:** Clinical factors and their association with level of positive nodes.

Clinical factors	Level of positive node		Total (n=130)	Chi-square value	p-value	df
	cases with N0 or level I metastasis (N1)	Cases with multilevel nodal metastasis				
<b>Trismus</b>						
<b>Present</b>	33 (52.4%)	30 (47.6%)	63 (100%)			
<b>Absent</b>	31 (46.3%)	36 (53.7%)	67 (100%)	0.485	0.301	1
<b>Masticator Space Infiltration</b>						
<b>Present</b>	10 (17.5%)	47 (82.5%)	57 (100%)			
<b>Absent</b>	54 (74%)	19 (26%)	73 (100%)	40.77	0.000*	1
<b>Clinico-radiological bone erosion</b>						
<b>Present</b>	13 (30.2%)	30 (69.8%)	43(100%)			
<b>Absent</b>	51 (58.6%)	36 (41.4%)	87 (100%)	9.27	0.002*	1
<b>Skin Infiltration</b>						
<b>Present</b>	3 (10.7%)	25 (89.3%)	28 (100%)			
<b>Absent</b>	61 (59.8%)	41 (40.2%)	102 (100%)	21.1	0.000*	1

\* statistically significant (p<0.05)

**Table 16:** Clinical nodal status and level of positive nodes in N0, early and advanced CLNM

Clinical N status and levels of positive nodes	Level of positive node		Total (n=130)	Chi-square value	P-value	df
	cases with N0 or level I metastasis (N1)	Cases with multilevel nodal metastasis				
<b>cN0 and cN1</b>	62 (66.7%)	31 (33.3%)	93 (100%)			
<b>cN2 and cN3</b>	2 (5.4%)	35 (94.6%)	37 (100%)	39.7	0.000*	1

\* statistically significant (p<0.05)

**Table 17:** Pathological factors and their association with level of positive node.

Pathological factors	Level of positive node		Total (n=130)	Chi-square value	p-value	df
	cases with N0 or level I metastasis (N1)	Cases with multilevel nodal metastasis				
<b>Biopsy</b>						
<b>Well-Moderate</b>	48 (60%)	32 (40%)	80 (100%)			
<b>Moderate -Poor</b>	16 (32%)	34 (68%)	50 (100%)	9.65	0.002*	1
<b>Extra-capsular Spread</b>						
<b>Present</b>	0 (0%)	25 (100%)	25 (100%)			
<b>Absent</b>	64 (61%)	41 (39%)	105 (100%)	30.01	0.000*	1
<b>Lympho-Vascular</b>						
<b>Emboli</b>						
<b>Present</b>	4 (26.7%)	11 (73.3%)	15 (100%)			
<b>Absent</b>	60 (52.2%)	55 (47.8%)	105 (100%)	3.45	0.055	1
<b>Perineural Invasion</b>						
<b>Present</b>	5 (17.9%)	23 (82.1%)	28 (100%)			
<b>Absent</b>	59 (57.8%)	43 (42.2%)	102 (100%)	14.015	0.000*	1

\* statistically significant (p<0.05)

**Table 18:** Intra-operative factors and level of positive node.

Intra-operative Factors	Level of positive node		Total (n=130)	Chi-square value	p-value	df
	cases with N0 or level I metastasis (N1)	Cases with multilevel nodal metastasis				
<b>Intra-operative T size</b>						
<b>T1 and T2</b>	25 (71.4%)	10 (21.6%)	35 (100%)			
<b>T3 and T4</b>	39 (41.1%)	56 (58.9%)	95 (100%)	9.442	0.02*	1
<b>Intra-operative gross tumour thickness</b>						
<b>&lt; or equal to 1cm</b>	58 (72.5%)	22 (27.5%)	80 (100%)			
<b>&gt;1cm</b>	6 (12%)	44 (88%)	50 (100%)	45.06	0.000*	1

\* statistically significant (p<0.05)

**Table 19:** Details of surgery in 130 patients with primary mandibular GBC-SCC.

Surgical therapy in 130 study patients	No. of patients	Percentage
<b>Type of Neck Dissection</b>		
MND II*	122	94%
RND*	8	6%
<b>Type of Primary Resection</b>		
Composite resection	91	70%
Bite Composite resection	24	19%
Marginal Mandibulectomy	15	11%

**Table 20:** Results of step-wise logistic regression for studying the association of clinico- pathological factors (independent variables) and level of positive node (dependent variable).

Clinico-pathological factors	B	SE	Wald	df	Sig.	Exp (B)	95% C.I.for EXP(B)	
							Lower	Upper
Gender	2.766	1.387	3.977	1	0.046	15.902	1.049	241.161
Masticatory space Infiltration	-2.593	1.053	6.060	1	0.014	0.075	0.009	0.589
Clinical Nodal Status	4.054	1.329	9.299	1	0.002	57.635	4.256	780.415
Biopsy	1.396	0.737	3.591	1	0.058	4.040	0.953	17.119
Intra-operative Gross Tumour Thickness	2.361	0.894	6.972	1	.008	10.604	1.838	61.186
Intra-operative T size	1.723	0.343	25.182	1	0.019	5.600	0.523	0.716

B: Coefficient for the constant (Intercept)

SE: Standard error around the coefficient for the constant

Wald and Sig: Wald chi-square test for null hypothesis that constant is 0 and Sig is p-value

df: Degree of freedom for Wald chi-square

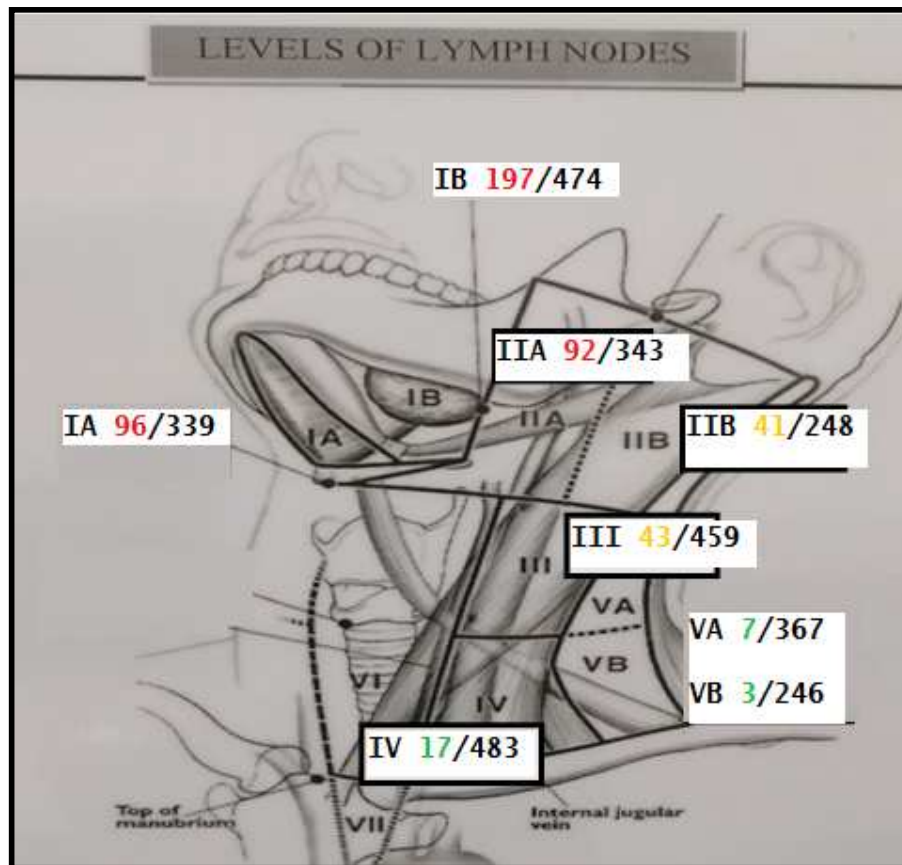
Exp (B): Exponentiation of the B coefficient (Odds ratio)

95% CI for Exp (B): Confidence Interval (95%) for Exp (B)

**Table 21:** Results of ROC test for studying the association of clinico-pathological factors (independent variables) and level of positive node (dependent variable).

Test Result Variable(s)	Area	Std. Error	Asymptotic Sig.	Asymptotic 95% Confidence Interval	
				Lower Bound	Upper Bound
Masticator space infiltration	.222	.042	.000	.139	.305
Intra-op T size final	.620	.049	.019	.523	.716
Intra op TT	.786	.042	.000	.705	.868

**Photograph 26:** The ratio of number of positive-nodes (coloured fonts) and number of nodes harvested from each nodal level (LNR) in 130 patients with primary mandibular GBC-SCC.



**Table 22:** Distribution and reference range of nodes at each level in 130 patients with primary mandibular GBC-SCC.

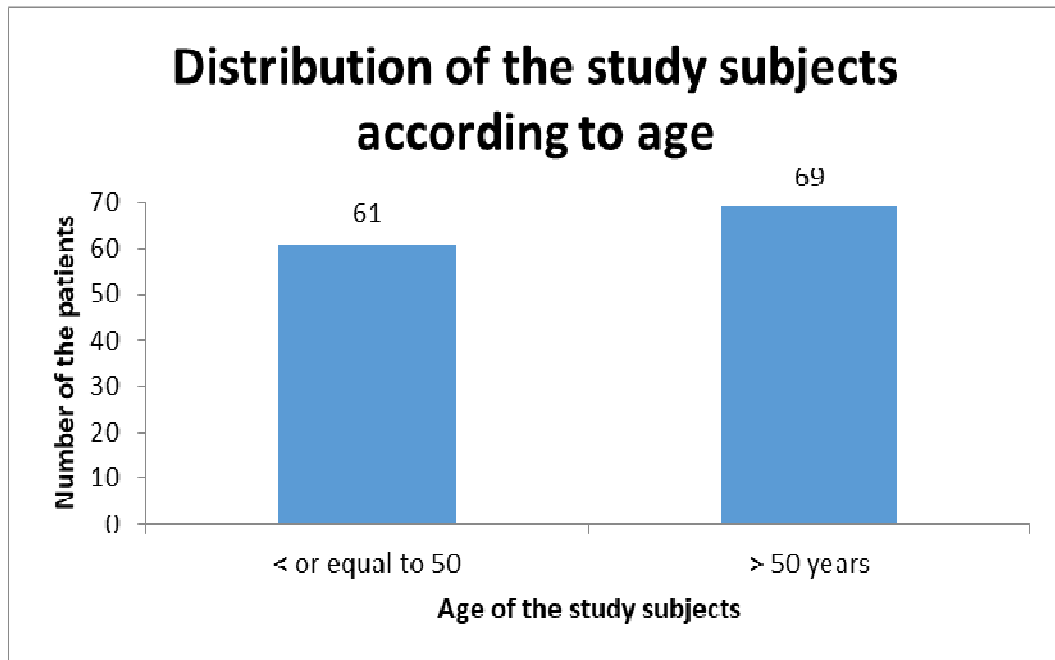
Nodal levels submitted	IA	IB	IIA	IIB	III	IV	VA	VB	Parotid Nodes
No. of nodes per level									
Total	339	474	343	248	459	483	367	246	81
Average	2.61	3.65	2.64	1.90	3.53	3.72	2.82	1.89	0.62
Median	3	3	3	2	4	4	3	2	0
Range	1-5	1-8	1-5	1-4	1-6	1-8	1-6	0-2	0-3
No. of positive nodes	96	187	92	41	43	17	7	3	15
ECS	0	25	0	0	0	0	0	0	0

**Table 23:** the status of tail parotid nodes in 130 patients with primary mandibular GBC-SCC

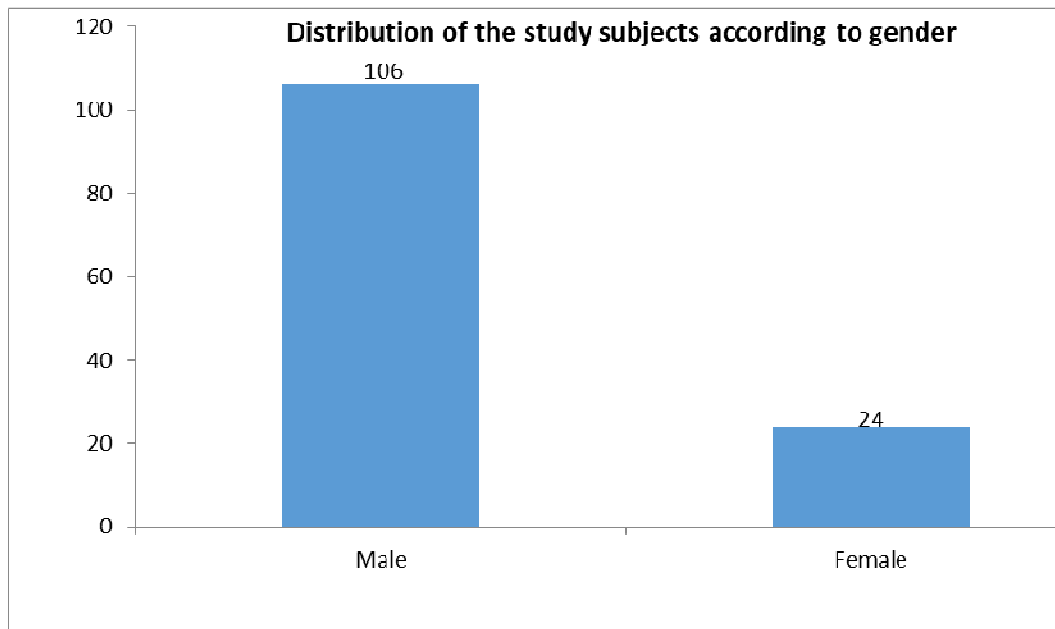
Parotid Nodes	Frequency	Percentage
Absent	71	54.6%
Negative	44	33.8%
Positive	15	11.5%

**Table 24:** Details of Lymph node yield (LNY) in 130 patients with primary mandibular GBC-SCC.

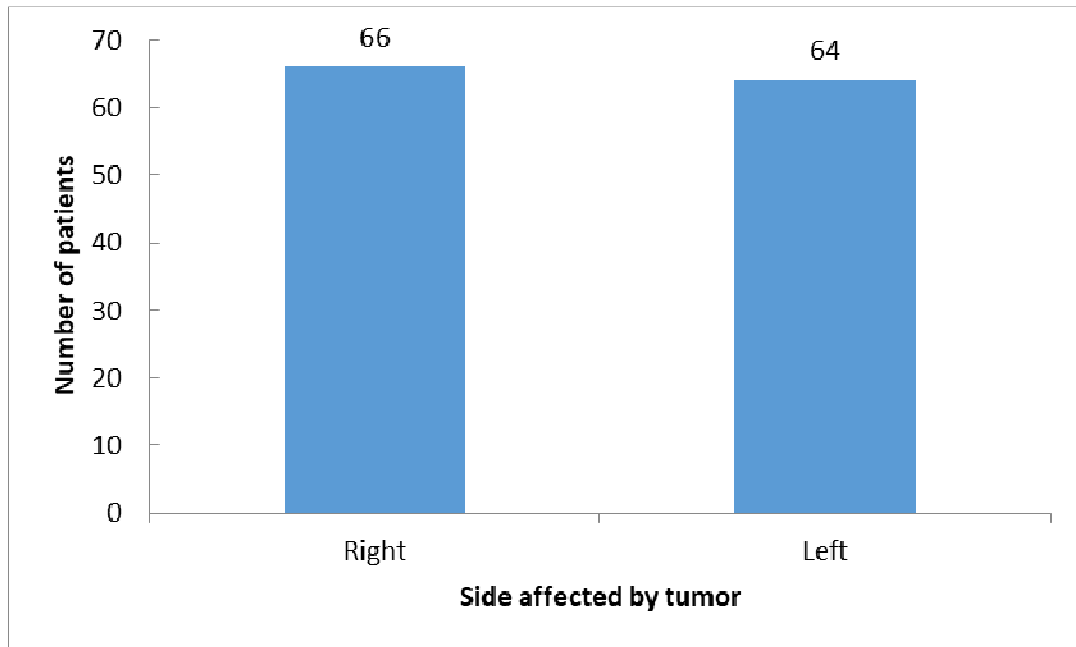
Descriptive statistics	Lymph node yield (LNY)
Total number of patients	130
Mean $\pm$ Std Dev	23.61 $\pm$ 5.15
Range	14-37
Median	23



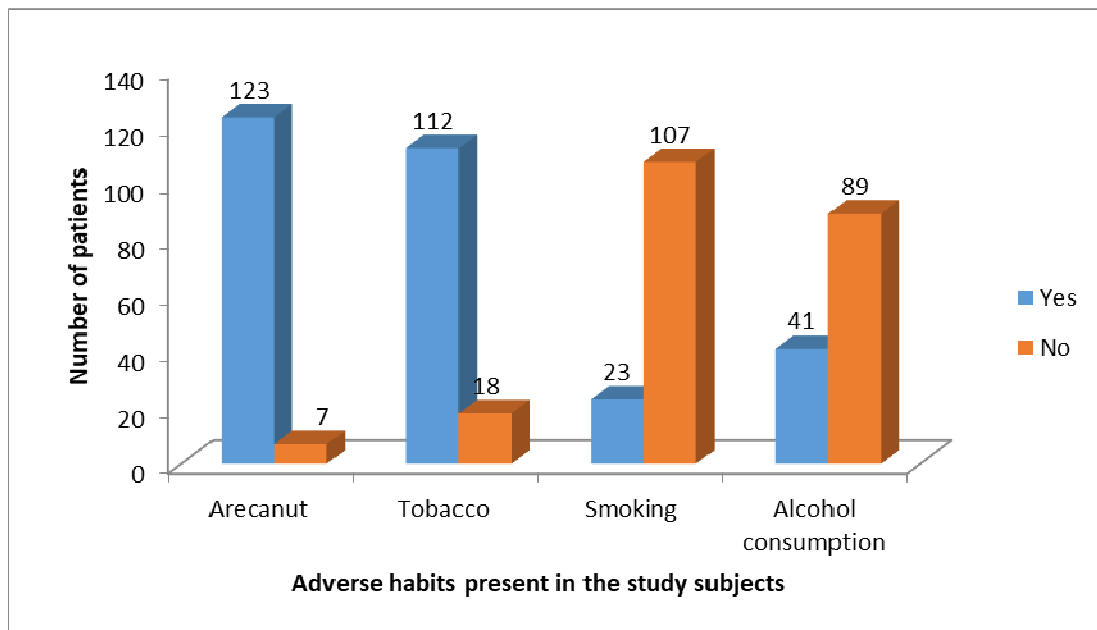
Graph 1



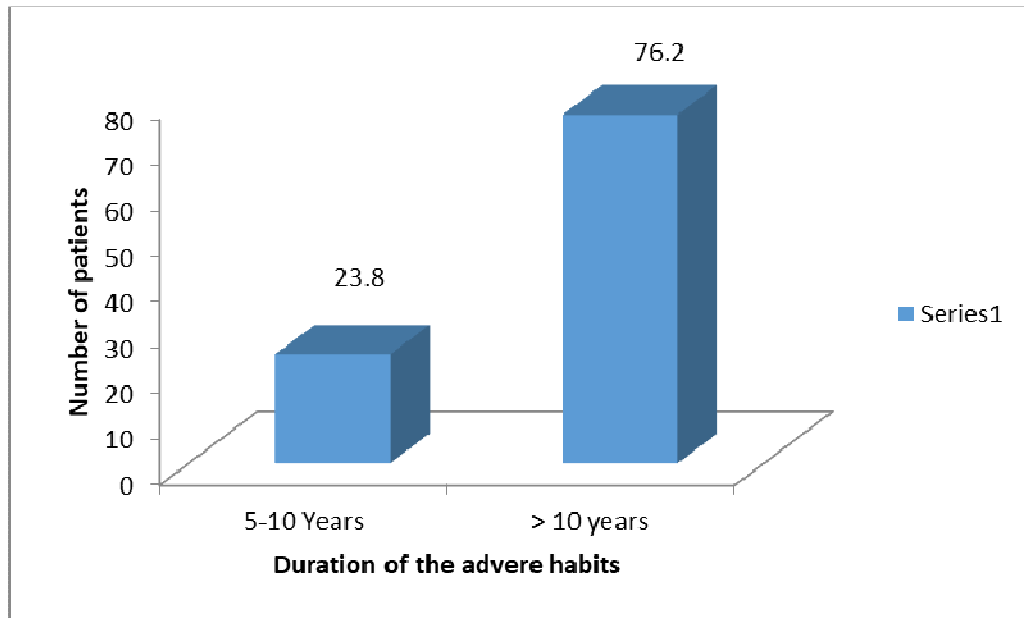
Graph 2



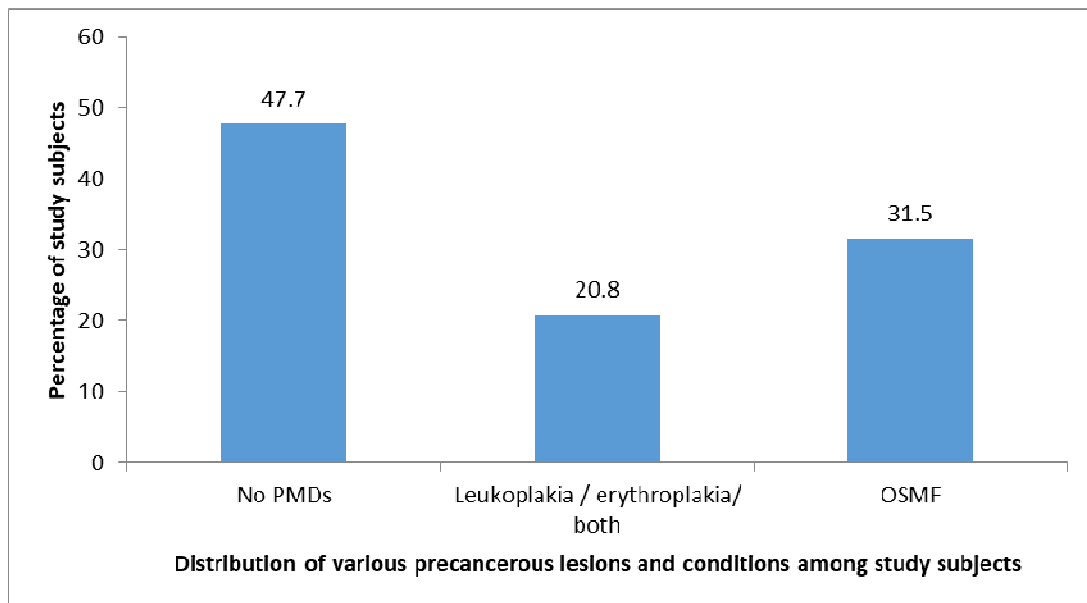
Graph 3



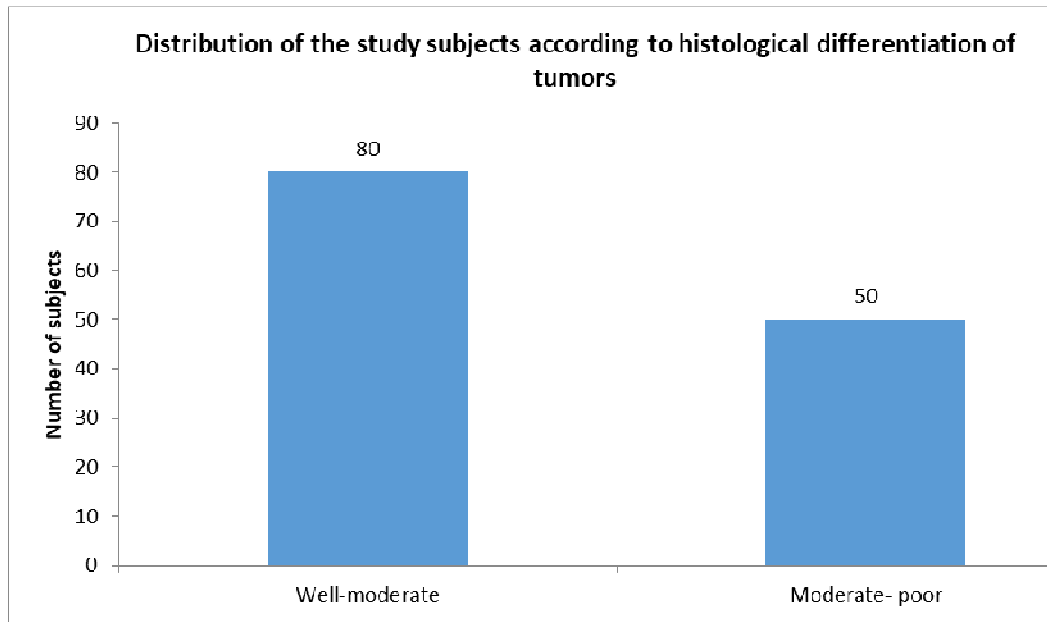
Graph 4



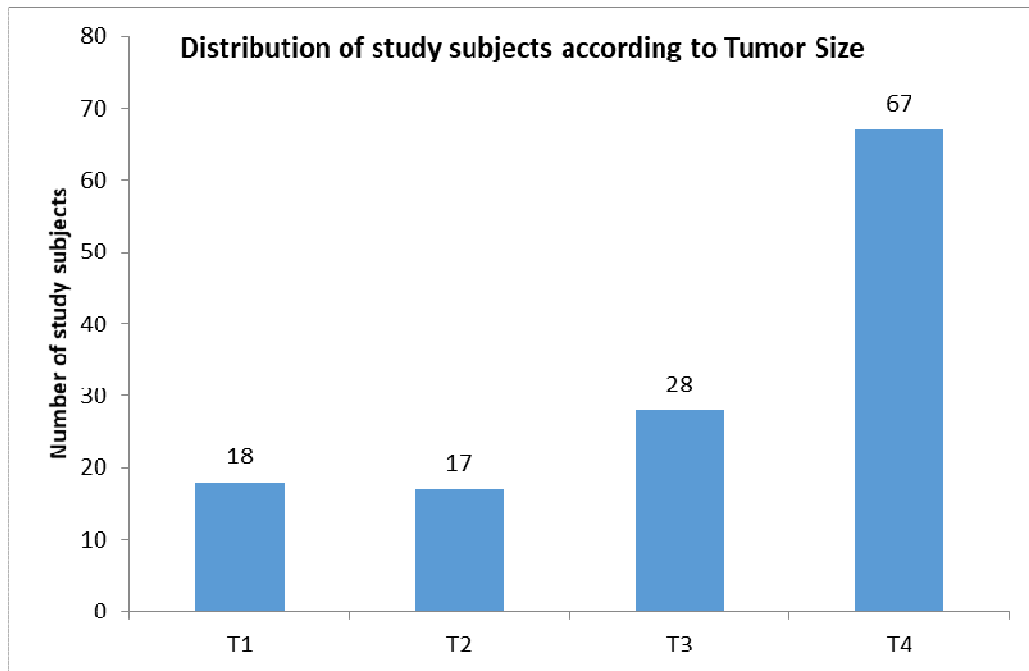
Graph 5



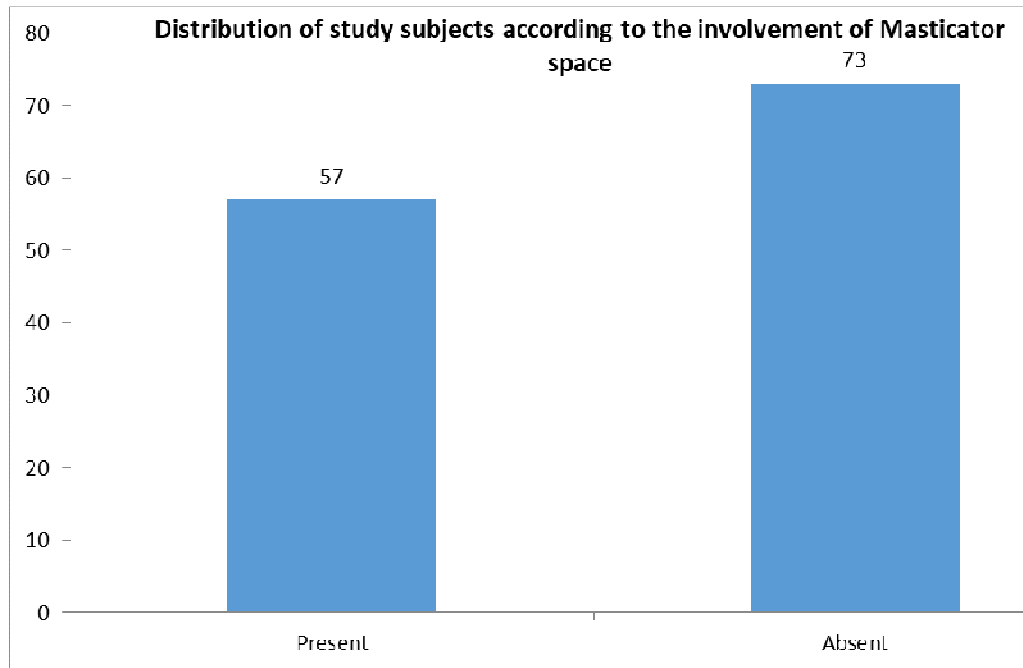
Graph 6



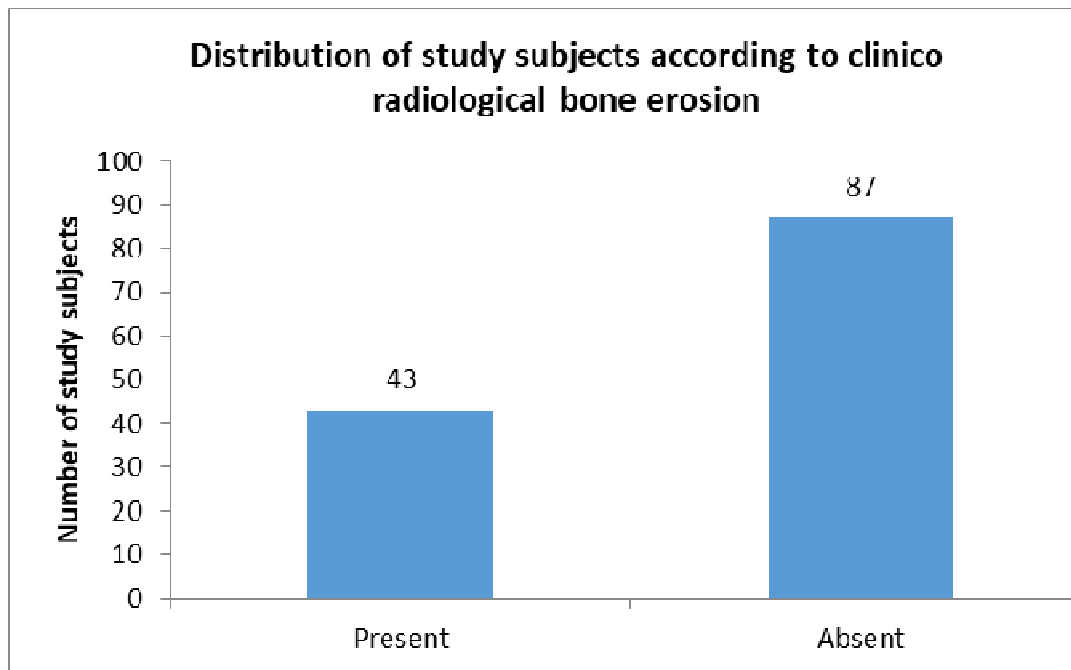
Graph 7



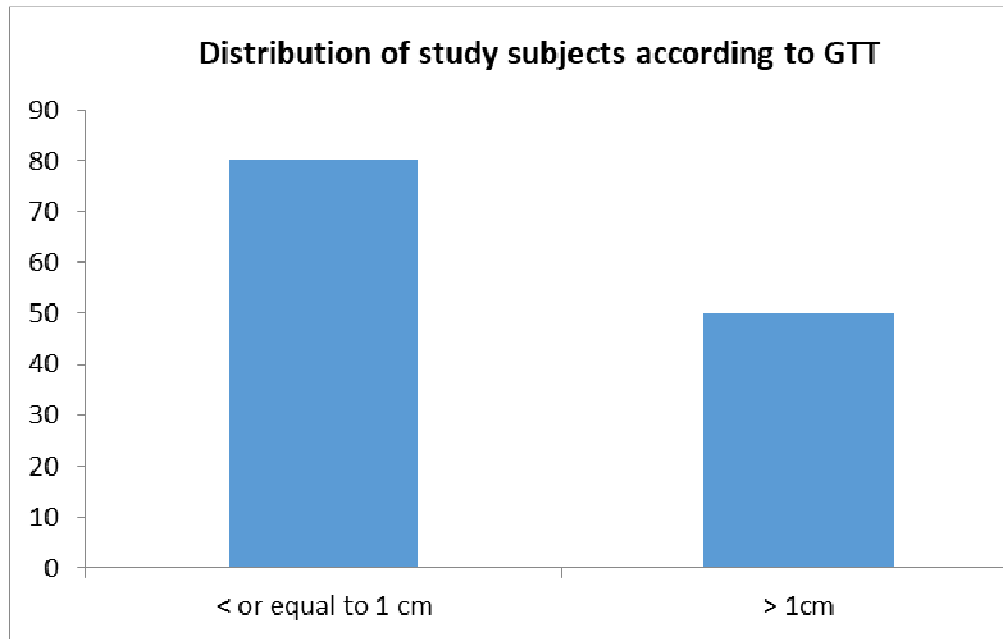
Graph 8



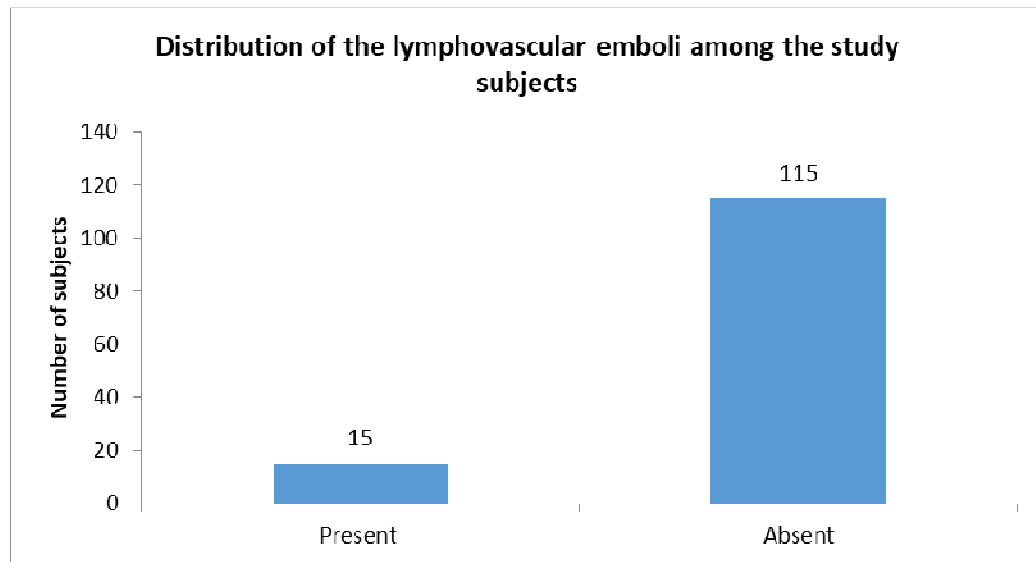
Graph 9



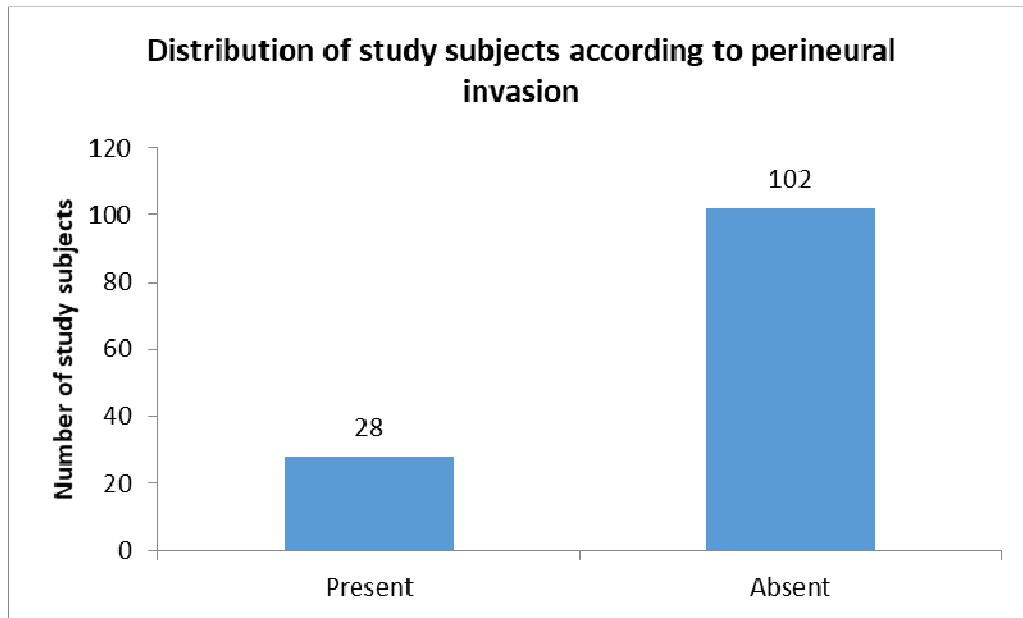
Graph 10



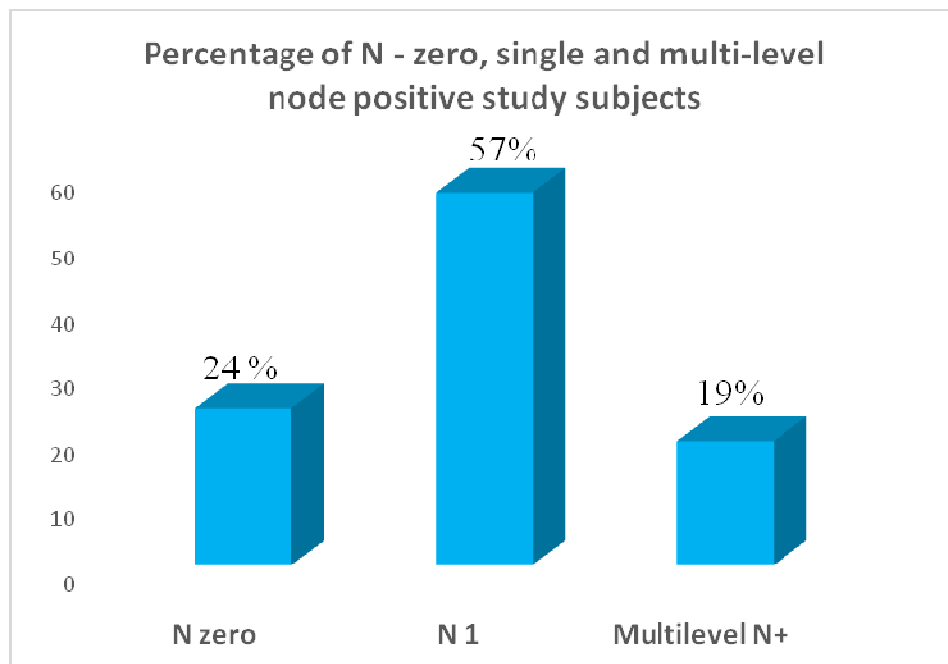
Graph 11 (GTT: Gross Tumour Thickness)



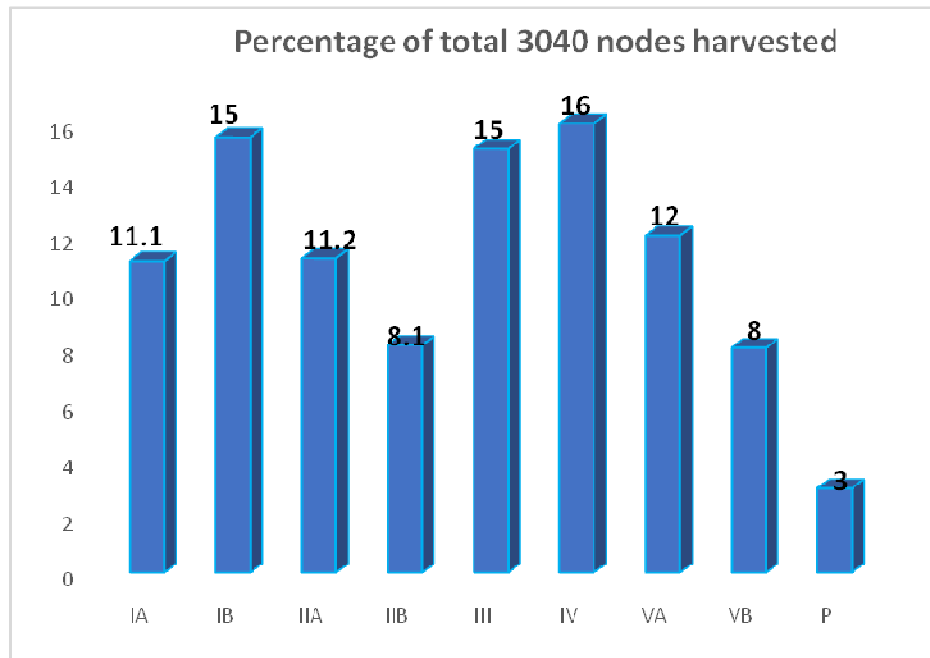
Graph 12



Graph 13



Graph 14



Graph 15

## DISCUSSION

Buccal mucosal SCC has been studied extensively in the last decade owing to its propensity to spread into adjacent anatomical structures, wide-gamut of clinical behavior and requirement for aggressive therapy to achieve loco-regional control and long-term disease-free survival.<sup>167, 168</sup> This malignancy is reported to have significant recurrence rates in spite of comprehensive therapy.<sup>167-169</sup> Also, the incidence of buccal SCC when compared to other subsites of oral SCC is found to increase.<sup>168, 169</sup>

The typical spread of buccal SCC into mandibular GBC is a common presentation in the Indian population given the high prevalence of tobacco and arecanut abuse.<sup>5,6</sup> More importantly, prolonged contact with the carcinogens present in tobacco and arecanut that are held in the gingivo-buccal sulcus (GBS) by abusers is known to bring about various genetic changes in the mucosa and promote this typical extent of the tumour.<sup>170-173</sup>

Buccal SCC is known to behave aggressively due to its proximity to adjacent soft and hard tissues, tendency to spread into these tissues and few anatomical barriers for the spread.<sup>172</sup> Once the tumour manifests in the GBS, it can spread into paramandibular space, lower border of mandible, along buccal mucosa to upper gingivo-buccal sulcus, posteriorly to retromolar trigone, masseter muscle and masticator space, and medially to involve mandibular bone and floor of mouth. Laterally the tumour can involve buccal space and infiltrate skin.<sup>172-173</sup>

The loco-regional control rates of buccal SCC depend on the stage at diagnosis, depth of infiltration, extent of CLNM and infiltration into the surrounding structures<sup>6, 7</sup>. Most of the cases of mandibular GBC-SCC are known to present in locally advanced stage in contrast to other subsites of oral SCC.<sup>7, 26</sup>

These factors also determine the need for aggressive therapy and reconstruction of the defects. However, despite aggressive therapy the mandibular GBC-SCC has shown poor loco-regional control rates.<sup>26</sup>

Studies on mandibular GBC-SCC with large sample size have shown that these malignancies are known to recur regionally, even after definitive therapy. The regional recurrence rates are 7.5% to 32%, and are reported at the upper-jugulodigastric, posterior triangle and parotid lymph-nodes.<sup>7, 30</sup> The results of previous studies and our own experience at tertiary referral center have shown that often the regional recurrences are non-salvageable and even if salvaged the disease-free survival is poor. With this background, we intended to study the pattern of CLNM in mandibular GBC-SCC and characteristics of primary tumour that contribute to type and extent of CLNM.

SCC of the mandibular GBC is found to occur in middle age patients in majority, although studies comprising of cases with younger age group have been reported.<sup>7, 26, 30</sup> The age of patients ranged from 22-80 years in our study which was similar to a study conducted on buccal mucosal carcinoma involving 100 patients.<sup>174</sup> In other studies, comprising of larger number of mandibular GBC-SCC patients, the age range was wider to include more of elderly patients with maximum age limit of 85 years, although the minimum age reported in these studies remained similar to our study.<sup>7, 26</sup> The age was again independent of the disease stage in the reported studies. Unlike studies that included mandibular GBC-SCC at all T-stages, in a study that included only locally advanced disease showed that the age remained in the range of 21-90 years. This shows that most of the studies including ours have considered all

the patients diagnosed with mandibular GBC-SCC that were operable and patients had good general condition, even though co-morbidities were present.

When we looked at the distribution of patients with a reference range of age, it was found in our study that there was approximately equal distribution of patients that were  $\leq 50$  years and patients that were  $> 50$  years. The number of patients over the age of 50 years was on a higher side in the reported studies on mandibular GBC-SCC.<sup>7,8, 26, 30</sup>

In contrast to tongue and other oral subsites of primary SCC, SCC of GBC is reported to occur at an advanced age.<sup>175, 176</sup> The highest number of cases of SCC of oral tongue have been reported to occur below the age of 45 years, in the western literature. Likewise, the age of first primary tumour involving mandibular GBC does not seem to be of a prognostic value in contrast to tongue SCC, in view of its reported occurrence in patients  $>65$  years of age as reported by SEER data.<sup>177</sup>

Although the association of age with survival has been broadly studied in the literature, the relationship of age with the CLNM has not been clearly elucidated. Most of the available studies in the literature have not shown any association of age of patients with oral SCC and CLNM.<sup>10, 11, 26, 27</sup> On the contrary, the results of our study showed that age was significantly associated with CLNM. The number of patients  $>50$  years old were on a higher side in 'multi-level node positive' category in our study. This must have contributed to the significant association of CLNM with the age. Similar results have been reported only in two studies.<sup>7, 178</sup> In the latter study it was seen that the risk of CLNM increased to approximately two folds with every 10 years increase in age in patients with buccal SCC.<sup>178</sup>

Gender:

The gender variation with regards to subsite of the oral SCC is a notable feature among various studies and is known to depend on geography, type of deleterious habits and nature of exposure to carcinogens.<sup>4, 5, 15, 17, 29</sup>

As per the GLOBOCAN-2018 data, oral SCC is second largest cancer affecting males.<sup>1, 2</sup> Overall, oral SCC is commonly seen in males and the number of female populations with oral SCC is known to vary. Although there is no variation in the male population with regards to subsite, the number of female patients in most of the studies diagnosed with tongue SCC were on higher side in contrast to buccal SCC.<sup>29, 55</sup>

In patients with mandibular GBC-SCC, the number of male patients were found to be three to four times higher compared to female patients. The male: female ratio in mandibular GBC-SCC was 4.4: 1 in our study in contrast to 7:3 and 2.4:1, found in other high- volume studies.<sup>7, 26</sup> There were only 24 (18.5%) female patients in our study and this has resulted in skewed male: female patient ratio in comparison to other studies. Abuse of chewable form of tobacco and arecanut were common practices in male populations in mandibular GBC-SCC which is highly prevalent in India and South-East Asia, in contrast to western population where smoking and alcohol-abuse are main carcinogens resulting in tongue and floor mouth SCC in female population.<sup>10-14</sup> With the exception of one study, in which male population was independent predictor of CLNM, no study including ours has shown any significant association of CLNM with gender.<sup>179</sup>

Risk factors for mandibular GBC-SCC:

Tobacco and arecanut chewing were a common practice in over 90% of our patients. It was observed that female patients were habitual chewers of arecanut without being aware of its carcinogenic effects. Our own previous study has highlighted the association of arecanut chewing habit and buccal SCC in Indian women.<sup>180</sup> In addition to tobacco and arecanut chewing, smoking and alcohol-abuse were notable risk factors in male patients. When compared to studies from other Asian countries like Taiwan and China where the major risk factors for mandibular GBC-SCC is betel nut chewing, the major risk factor in India is chewing of arecanut and tobacco combination.<sup>5, 15, 30, 115</sup> Abuse of alcohol and smoking has shown synergistic effects in carcinogenesis.<sup>3-5, 15</sup> Although, the contact time of carcinogenic stimulus to oral tissues was not studied in the present study, the duration of habits was significantly associated with positive CLNM. The duration of habits may not be directly related to nodal stage, this association might be due to higher number of patients presenting with advanced T- stage in our study, as most of these patients reported of deleterious habits for over 10 years. There were over 75% patients in our study who admitted of having exposed to the known risk factors for oral cancer for over 10 years. In previous studies, a significant association of oral SCC and PMDs with the duration of habits was found. Longer the duration of exposure, higher the probability of having either oral SCC or existing PMD transforming into oral SCC.<sup>5, 181</sup>

PMDs and mandibular GBC-SCC:

In view of higher number of patients reporting with prolonged exposure to risk factors the presentation of mandibular GBC-SCC with PMDs was a common finding

in our study. Over 50% of our patients presented with PMDs which was higher than the reports of previous studies. Oral submucous fibrosis was commonest PMD in our study which was similar to one study, whereas leukoplakia was a common PMD in another study.<sup>6, 174</sup> Habitual chewing of arecanut is well-established risk factor in the causation of OSMF and it was common in our patients.<sup>180</sup> This could be an important reason for high number of OSMF cases in our study. Although, PMDs have not shown to be directly associated with CLNM in oral SCC, their association with local recurrence of the tumour after definitive therapy is established.<sup>6, 180</sup> The patients with PMDs like leukoplakia or leuko-erythroplakia when associated with mandibular GBC-SCC can have variable degrees of dysplasia and can be a part of field cancerization.<sup>123</sup> This can show up as ‘dysplasia’ at the surgical margins following resection of the tumour. The presence of ‘severe dysplasia’ at the margins is found to be a strong determinant of local recurrence of the tumour following resection.<sup>183</sup> However, the presence PMDs in our study was insignificant on multivariate analysis for its contribution in the nodal metastasis.

Clinical presentation:

Trismus and associated swelling were most common presentations in our patients. In some patients the trismus was severe resulting in inability to completely examine the tumour clinically and locate its posterior extent. This was the reason for inaccurate clinical T- staging pre-operatively in these patients. OSMF was common reason for trismus in our patients owing to prolonged history of tobacco and arecanut chewing habit. The second common cause of trismus was infiltration of the tumour into masticatory spaces which was seen in 47% of patients, although some of the patients also had both of these causes. In view of trismus, we evaluated all our

patients with Multidetector Computed Tomographic (MDCT) imaging with puff cheek and 1mm cuts, which is an evidence-based method for assessing bone erosion, infiltration into masticator space, extent of tumour and nodal staging.<sup>68, 131</sup> With the clinical examination and imaging, we could identify these individual factors and assess its impact on CLNM.

The frequent complaints of the patients with mandibular GBC-SCC in other studies included oral ulceration which was not common in our study.<sup>6, 15</sup> In a study the clinical examination of patients was possible to ascertain the epicenter of the tumour which was not possible in over 40% of our patients due to trismus.<sup>6</sup> Besides ulceration of buccal mucosa, the presenting complaints of patients with mandibular GBC-SCC in other studies included burning sensation in the mouth, loose teeth and exophytic swelling.<sup>6, 7, 26</sup> The patients with locally- advanced disease presented with either oro-cutaneous fistula or infiltration into skin over the cheek which was identified by the bimanual palpation, pinch test and imaging.<sup>7, 26</sup> The results of other studies were commensurate with our findings. Most of the clinical presentations that have been described in the previous studies, especially from the western literature are based on patients that had early stage lesions (Stage I -II) whereas majority of our patients were in locally advanced stage (stage III and IV).<sup>7, 10-12, 26</sup> In view of this, we had patients with clinical features characteristic of advanced stage disease like trismus, infiltration of masticator space, clinico-radiological bone erosion, skin infiltration and malignant lymphadenopathy. In most of the Indian studies on mandibular GBC-SCC, the number of patients with locally-advanced disease was higher, the clinical findings often included bone erosion, skin infiltration and node positive necks as also observed in our study.<sup>6,7, 26, 182</sup> The occurrence of trismus either due to OSMF or due to infiltration into masticatory space is reported only in one

study, without correlation with the stage of the disease.<sup>6</sup> However, infiltration into masticator space, Clinico-radiological bone erosion and skin infiltration by mandibular GBC-SCC were significantly associated with multi-level CLNM in our study, which is likely due to higher number of patients with locally-advanced stage. Also, posteriorly-located lesions in oral cavity and involving retromolar trigone have been reported to show higher incidence of CLNM in addition to infiltration into masticatory space.<sup>6, 183</sup> In the lesions with locally advanced stage, the likelihood of infiltration into mandibular buccal or alveolar cortex and/ or infiltration into skin is higher owing to lack of barrier laterally, once the tumour infiltrates buccinator muscle.<sup>8-10</sup> The fat overlying buccinator muscle is a weak barrier to the tumour spread and often the skin is infiltrated by the tumour once it approaches closer to buccal fat.<sup>120</sup> This anatomical factor can contribute for high local recurrence rate of mandibular GBC-SCC even after radical surgery.<sup>120</sup> Contrarily, infiltration into surrounding structures by mandibular GBC-SCC corresponds to larger tumour volume, which includes tumour thickness and greatest dimension of the tumour.<sup>127</sup> This was evident from the results of our study that increase in tumour diameter, tumour thickness or both was associated with multi-level nodal metastasis. The previous TNM staging (AJCC 2009) that we followed during this study considered only greatest tumour dimension as an indicator of T-size which may not be accurate measure of CLNM, as it underestimates the volume of disease and at times the tumour may not be infiltrative or may be attenuated at the third dimension (thickness).<sup>158</sup> Failure to recognize aggressive behavior of a tumour with smaller dimension and larger thickness in contrast to larger tumour dimension with smaller thickness was a major shortcoming of AJCC 2009 TNM staging system, which we overcame by including gross tumour thickness in our study. The inclusion of tumour depth into

TNM staging system came to effect after realizing the importance of tumour thickness as a determinant of prognosis and CLNM in oral SCC in the recent studies.<sup>184</sup>

Pathological Factors:

The histological differentiation (HD), ECS, LVE and PNI were pathological factors that were considered in our study in view of previous reports on oral SCC that validated these factors to determine the prognosis and requirement of aggressive therapy following surgery.<sup>114-125</sup> We intended to study the influence of these pathological factors on CLNM in mandibular GBC-SCC. Histologic grade has been reported as an important marker of tumour behavior, especially with regards to regional and distant metastasis. Although, we used Broders grading system which has been used by several other studies, the interpretation of results using HD has shown poor correlation with outcome and response to treatment in an individual patient.<sup>35</sup>

However, studies have shown that HD is a valuable predictor of CLNM.<sup>114-116</sup> The varied results of HD in influencing CLNM are due to heterogenous tumors, inadequate or small sample during biopsy and dependence on cellular structure rather than the function and biological behavior.<sup>35</sup> It was observed in our study that the inclusion of invasive-front of the tumour in biopsy specimen improves the reliability of HD in predicting CLNM, as the HD was found to differ at the invasive-front from the superficial areas of the tumour.<sup>185</sup> Detection of poor HD at advancing front in the biopsy specimen was reliable predictor of multi-level CLNM. Inclusion of only the superficial areas of tumour in the biopsy specimen can result in erroneous interpretation of HD especially, when it shows well differentiated tumour on histologic examination.<sup>185, 186</sup> Multi-level CLNM were seen in tumors with moderate to poor HD in our patients and this was due to aggressive biological behavior of

tumors revealed by studying their invasive fronts. Therefore, we recommend that the decision on comprehensive neck dissection based on HD of tumour should be taken provided the invasive front in the biopsy specimen has shown poor differentiation. However, HD was insignificant predictor of CLNM in multivariate analysis in our study as the status of invasive front was not always determined in biopsy specimens.

Although the number of patients with locally-advanced SCC were higher in our study, patients with LVE and PNI were 11% and 21% respectively, which was lower than reported studies comprising of larger number of patients with buccal cancer.<sup>128</sup> LVE was never detected in the biopsy specimens and most of the positive reports of LVE was found during grossing of specimen in our study which was similar to previous studies.<sup>128</sup> The presence of PNI was suspected in patients with high volume disease, especially when mandibular canal was infiltrated by the tumour on clinical examination resulting in paresthesia and imaging modalities confirming the findings. However, it was confirmed only after histological examination of the specimens. Although, LVE and PNI were significantly associated with CLNM in our study, their role in contributing to CLNM is controversial.<sup>125, 126</sup> Some studies have reported these factors as determinants of loco-regional and distant metastasis whereas, another study has not reported any such role.<sup>187-189</sup> However, PNI was a significant predictor of CLNM in a comparative study involving buccal and tongue SCC wherein, patients presenting with PNI were less in comparison to those with tongue SCC.<sup>125</sup> It appears that both of these factors are associated with higher T-stage and locally advanced disease status rather than contributing as independent predictors of CLNM. Contrarily, the role of these factors in predicting local recurrence, distant metastasis and influence of disease-free survival is well established in the existing

literature.<sup>187-189</sup> The **Table 25** shows significance of various clinico-pathological factors in comparison with our study in causation of CLNM.

Author/ Year	Study Design	No. of patients	Outcome	Significant factors*
Vincent N et al <sup>130</sup> 2012	Retrospective	149	L/R RFS	Age, T-size, bone invasion
Jan JC et al <sup>117</sup> 2011	Retrospective	415	Prognostic factors in buccal SCC	ECS, advanced T-size
Walvekar RR et al <sup>26</sup> 2009	Retrospective	642	L/R control	CLNM, Invasion depth
Kane SV et al <sup>203</sup> 2006	Retrospective	48	CLNM	Invasion depth
Ghoshal S et al <sup>174</sup> 2006	Retrospective	100	Prognostic factors, DFS in buccal SCC	T3/T4 stage
Okada Y et al <sup>126</sup> 2003	Retrospective	38	CLNM	HD, Mode of invasion
Diaz EM et al <sup>11</sup> 2002	Retrospective	119	DFS in buccal SCC	Muscle invasion, ECS
Present study 2012-2017	Prospective	130	GBC	Masticator space infil, advanced T stage, GTT>1cm

**Table 25:** Comparison of clinico-pathological factors that are known to be associated with CLNM and survival, described in previous study and compared to present study Neck nodal metastasis from mandibular GBC-SCC:

Nodal metastasis on initial presentation of patient with oral SCC is a reliable prognostic factor. Studies report that presence of CLNM reduces the survival of patients to less than 50% after definitive therapy.<sup>19, 55, 56, 86, 90</sup> Although, mandibular

GBC-SCC often presents in locally advanced stage, the incidence of occult CLNM can range from 11%-50%.<sup>7, 26, 89, 116, 117, 128, 129, 174, 183</sup> In previous studies 62% of patients presented with clinically evident CLNM. Also, the regional recurrence rate in mandibular GBC-SCC can range from 7.5% to 32% which are often non-salvageable and even if salvageable, the mean disease-free survival is not reported to exceed more than 4 months.<sup>7, 26, 30, 183</sup> Therefore, ND is an integral part of comprehensive management of mandibular GBC-SCC which, if done upfront in patients with node negative neck can improve survival and is essentially done in patients with node positive necks to address CLNM.

However, the major drawbacks in the previous studies on mandibular GBC-SCC with regards to prevalence of occult metastasis have been inconsistency in the research methodology, variability of diagnostic modalities used to identify occult CLNM, non-uniform type and fields of neck dissection, difference in the methods of grossing and reporting of final histopathological findings.<sup>7, 26, 30, 117, 174, 183</sup> The reports on occult CLNM inferred by retrospective studies range from 11% to 33% whereas those from prospective studies range from 35% to 50%. On the other hand, the regional recurrence of over 50% has been reported in patients with clinically node-positive necks.<sup>7, 26, 183</sup>

Most of the studies on mandibular GBC-SCC highlight either single or multi-institutional data on loco-regional failure and survival, and lack consensus on the factors influencing CLNM and their effective management in mandibular GBC-SCC.<sup>7, 26, 117, 117, 129, 183</sup> Furthermore, the data on CLNM in mandibular GBC-SCC has been derived from the reports of western studies which are either deficient in number of mandibular GBC-SCC patients or are generalized to include all oral subsite SCC,

majority being of tongue or floor mouth SCC.<sup>10-14</sup> Also, mandibular GBC-SCC is commonly associated with chronic oral inflammation, OSMF, limited mouth opening resulting in poor oral hygiene, periodontitis which can contribute to clinically evident lymphadenopathy.<sup>6, 174</sup>

In addition to this if we consider the existing literature that is based on buccal SCC, it is precarious with regards to extent of tumour within buccal mucosa and little importance is given to distinguish the tumors extending to mandibular GBC which is a unique anatomical region in the oral cavity, bounded by bone and soft tissue.<sup>10-12</sup>

In view of the potential drawbacks in the existing literature and lack of uniformity in the methodology, we intended to study the pattern of lymph node metastasis, the LNY and factors that influence CLNM in patients with mandibular GBC-SCC, so as to guide a therapist in decision making with regards to the extent of neck dissection, to avoid regional failures .

Neck Dissection (ND) procedures have undergone a series of modifications from the time it was first described in early 19<sup>th</sup> century to present era of practice, based on the evidences obtained by years of research to optimize regional control of HNC and reduce the morbidity resulting from the procedures, which can adversely impact on the patients QoL.<sup>91-93, 112, 113</sup> Although, there are established guidelines for managing neck in cases of occult metastasis from oral SCC, there are no clear guidelines on extent of ND in node positive necks.<sup>110, 111</sup> Some surgeons advocate extended SND for node positive neck wherein they dissect level I to level IV lymph nodes and spare level V.<sup>88, 106</sup> Others practice either only SND followed by adjuvant radiotherapy or comprehensive neck dissection incorporating level-I to level-V in clinically node positive necks.<sup>190, 191</sup> In view of the variations in practices, there is

diversity in the reports related to factors that contribute to extent of CLNM in oral SCC in the current literature.<sup>192, 193</sup>

In order to overcome the bias in selection of uniform ND procedure, we included only the patients that require level-I to level-V comprehensive ND, either due to current guidelines suggesting it for node positive necks or due to large primary tumors for which pectoralis major myo-cutaneous (PMMC) flaps were planned for reconstruction at the tumour resection site. In the latter cases we sacrificed the sternocleidomastoid muscle to facilitate inset of PMMC flap and this method provided us with an opportunity of dissecting level-IV and level-V lymph-nodes and studying them for metastasis from mandibular GBC-SCC in our patients. Also, adherence to include only classical mandibular GBC-SCC patients with the tumour extent described as per the previous studies and following established specimen-grossing protocol ensured uniformity in our investigation.

When these methods were followed, we could harvest over 3000 CLNS in 130 patients with mandibular GBC-SCC. Among the various nodal levels, the highest number of CLNS were harvested from level I followed by level V and level II. The number of CLNS harvested from level III and level IV were approximately equal. When compared to a study by Friedman M et al that reported the distributions of CLNS per level in the neck by doing cadaveric neck dissection, the average number of CLNS found in our study were less.<sup>194</sup> The highest number of lymph-nodes in their study were harvested from levels IV and II followed by level III and V which was contrary to our results. The presence of disease at the draining area of the levels I and II resulting in the increased number of nodes at this level when compared to the number of nodes harvested in cadavers without oral cancer can possibly explain the

results obtained by our study. Also, the possibility of racial and ethnic factors that can contribute to variation in the CLNS should be considered in view of the previous studies that have shown significant difference in the lymph-nodes harvested in non-Asian and Asian gastric carcinoma patients.<sup>195</sup> So far there is paucity of the literature on reference range of CLNS in Indian patients and variability of CLNS in HNC patients.

As observed in the previous studies, the CLNM due to mandibular GBC-SCC occurred in foreseeable manner, involving level I, II and to lesser extent level III even though there were more of locally advanced cases in our study.<sup>55, 56, 147, 174, 179</sup> In contrast to previous studies, the incidence of occult CLNM in our study was found to be 24% and the common site of occult metastasis occurred at level I B.<sup>7, 26, 183, 190</sup> Also, level I B was the only site of solitary CLNM and other levels from Level-II to level-V never showed solitary CLNM (**Table 26**). Solitary CLNM bypassing level IB was seen in retrospective studies.<sup>7, 26</sup> These studies included only locally advanced mandibular GBC-SCC patients and possibly this might have been the reason for reporting skip metastasis in their studies. The occurrence and comparison of CLNM in our study with respect to other reported study is shown in **Table 26**.

**Table 26:** CLNM pattern in other studies in comparison with the present study

Author/year	Study design	No. of patients	Oral SCC Subsite	Type of ND	Pattern of CLNM (Levels)	Levels IV & V status	Remarks
Present study 2012-2017	Prospective	130	GBC	MRND I-V	I, II, III	Least	CLNM at IV & V in advanced stage only
Essig H et al <sup>190</sup> 2012	Prospective	60	Buccal	MRND	I, II, III	IV: 3% V: 1%	Least involved level V
Mishra et al <sup>127</sup> 2010	Retrospective	81	US	SOHD/ MRND	I, II, III, IV	IV/V nil	
Narendra H et al <sup>183</sup> 2010	Retrospective	127	Buccal	RND/ MRND	I, II, III	3-11% CLNM	
Woolgar JA <sup>28</sup> 2007	Retrospective	439	Tongue/ FOM	RND, MRND, SND	I, II, III	Not affected	Multilevel positive in T4 cases
Diaz EM <sup>11</sup> 2002	Retrospective	119	Buccal	Observe / SOHD	I, II, III	Nil	
Chone CT 2000 <sup>203</sup>	Retrospective	50	All Head Neck	SNDs	I-V	IV, V 37%	High larynx/ pharynx SCC

ECS has emerged as reliable predictor of regional and distant metastasis in HNC.<sup>18, 35, 153</sup> When compared to other subsites of oral SCC a higher incidence of ECS in tongue and floor mouth SCC has been reported.<sup>148, 149</sup> However, in a large-scale Indian study, no difference was observed in incidence of ECS in tongue versus buccal SCC.<sup>128</sup> The incidence of ECS reported in our study was 19% (25/130), which is comparable to 22% (141/618) found in a large-scale study.<sup>145</sup> The diagnosis of ECS

was done by clinical examination and imaging which was reliable. Only in three of our patients ECS was found on final histological reporting whereas in 22 patients it was detected before surgery by imaging and clinical examination. However, these three patients had node positive necks with central-necrosis on imaging. Our observations suggest that ECS can be identified by standard imaging techniques and can help in decision making regarding extent of CLN dissection. ECS was significantly associated with multi-level CLNM in our study. All the patients with metastasis at level-IV and level-V were found to have ECS that was detected at level IB node.

The importance of CLNM to level IV and Level V has been validated as a determinant of regional recurrence and distant metastasis. The reported studies highlight the factors that influence CLNM at level-IV and level-V.<sup>196, 197</sup> In a study the reported incidence of CLNM to level-IV and level-V was higher in the tongue in contrast to buccal SCC which was similar to our observations.<sup>196</sup> Metastasis to levels-IV and level-V was seen only in 15 (11%) of our patients which was lower than the reported study.<sup>196</sup> Majority of patients in study had wide variation in the subsite of oral SCC and included mostly SCC of tongue and floor mouth. SCC at these subsites have propensity for skip metastasis and this explains higher incidence of CLNM involving level IV and V in their study. It was noteworthy that the involvement of level IV and level V was 4% and 1.5% respectively in our study, in spite of including clinically node positive cases. On the contrary, when higher number of patients with only locally advanced cases of mandibular GBC-SCC were studied, there was 3-folds increase in CLNM to level-IV and level-V nodes.<sup>7</sup> In fifteen patients with level IV and Level V metastasis in our study, it was observed that ECS, multiple node positivity, tumour thickness over 1cm measured grossly and infiltration of skin by

primary tumour were common findings. In comparison to the available literature with unspecified subsite of oral SCC ECS, multiple node positivity and HD were found to be associated with metastasis at level IV and level V.<sup>7, 196</sup> The incidence of CLNM at level IV and level V in clinically node positive necks reported by our study were similar to a retrospective study which included only locally advanced cases of mandibular GBC-SCC.<sup>7, 127, 183</sup> This shows that even in cases of locally advanced mandibular GBC-SCC, preserving level IV or level V nodes is possible in selected cases and this can avoid morbidities or complications related to spinal accessory nerve and thoracic duct. Identification of these cases based on clinico-pathological risk factors can help in decision making regarding conservative versus radical ND. In addition to level IV and level V, we studied the involvement of tail parotid nodal (TPN) metastasis in mandibular GBC-SCC which has never been studied before, although these lymph nodes are dissected during comprehensive and radical neck dissection. In view of our previous experience with patients developing recurrence at parotid region following curative surgery for mandibular GBC-SCC (**Photograph 25**), which are often non-salvageable, we intended to include tail parotid nodes in our study. As recommended by previous studies, we dissected the tail parotid nodes that were found along the inferior pole of parotid gland, overlying posterior-belly of the digastric muscle, at the exit of retromandibular vein from inferior pole of parotid.<sup>159</sup> There were no lymph nodes found at the tail parotid region in 71 (54%) patients. In 59 (45%) patients we could harvest these nodes and send them separately for histopathologic examination. It was noteworthy that TPN were positive for metastatic disease from primary mandibular GBC-SCC whenever there were multi-level CLNM with ECS in at least one neck node and skin infiltration by the tumour at the primary site. The possibility of retrograde metastasis into parotid nodes in presence of

extensive metastatic disease in the neck nodes has been reported in a study. This can explain the observation of positive TPN in our study. Also, age changes in the parotid nodes resulting in their atrophy, loss of germinal centers and replacement by fatty tissue is reported.<sup>198</sup> This could have contributed to absence of lymph-nodes in tail parotid region in 54% of our patients.

For accurate N-staging, the minimum number of CLNs that are to be harvested from the neck dissection specimen has been standardized to avoid under-staging. In order to accurately estimate the ratio of positive nodes versus the number of nodes harvested (Lymph Node Ratio), the minimum number of nodes that are to be harvested from ND specimen has been validated.<sup>154, 155</sup> This concept has emerged after it was realized in prognostication of malignancies affecting other organs.<sup>31-34</sup> It has been estimated that any LNY >20 was associated with significant increase in the likelihood of finding metastatic node. When we followed the guidelines proposed by the Royal College of Pathologists (RCP)<sup>27</sup> the average LNY in our patients was 21, obtained by performing comprehensive neck dissection with preservation of spinal accessory nerve and internal jugular vein in most of the cases. As per RCP<sup>27</sup> guidelines the minimum number of nodes that were harvested by performing RND were 20. The comparison of LNY found in our study in contrast to the available literature is shown in **Table 27**.

**Table 27:** LNY in other studies in comparison with the present study.

Study/year	LNY	Type of ND
Agrama et al <sup>205</sup> 2003	13-20	RND
RCP <sup>27</sup> 2011	Minimum 20	RND
Norling et al <sup>*206</sup> 2013	19	SND I-III
	26	SND I-IV
	8-10	SND (Cadaver)
Marres CC et al <sup>154</sup> 2014	1-89	MRND
	Mean 34	
	3-52	SND I-III
	Mean 18	
SEER Data <sup>207</sup> 1973-1996	Mean 24.6	SND (277 NDs)
	Mean 30.2	MRND (1225 NDs)
	Mean 32.8	RND (1016 NDs)
Present study, 2012-2017	Mean 23.61	MRND II* 122 (94%)
	Range 14-37	RND 8 (6%)

MRND II<sup>\*</sup>: Level I-V ND with sacrifice of SCM muscle

The LNY is reported to change depending on the surgical field, expertise of pathologist, patient's body mass index (BMI), racial and ethnic factors.<sup>156, 157</sup> Although the data on reference range of LNY in Indian patients undergoing neck dissection is unavailable, when compared to the western literature on LNY we had lesser counts in spite of constant field of neck dissection and standard operating procedures for grossing of specimens and harvesting lymph-nodes.<sup>194, 199</sup> This could be attributed to racial factors and lower BMI in our patients possibly due to nutritional

deficiencies resulting from malignancy, OSMF, trismus and history of alcohol consumption.<sup>200, 201</sup>

TT is currently an independent-predictor of CLNM in oral SCC.<sup>35, 122, 123, 127</sup> On multivariate analysis intra-operative T-size, GTT over 1cm and masticator space infiltration by tumour were strong predictors of multi-level CLNM including level IV, level V and tail parotid nodes in our study. We considered measuring TT by gross method although microscopic TT measured using optical micro-meter is more accurate.<sup>132</sup> This was because gross measurement of TT is possible by operating surgeon and can be done intraoperatively when decision of dissecting level IV or level V nodes have to be taken whereas, the feasibility of carrying out microscopic measurements of TT intraoperatively is less. However, the TT measured grossly can overestimate the actual TT measured microscopically, as the former also takes into account the inflammation, oedema resulting from tumour and fibrosis whenever they are associated with the tumour. In view of this, the estimated values of TT by gross examination in our study was higher in contrast to reported studies. However, even when measured by gross examination the TT was a reliable predictor of multi-level CLNM as seen in other studies.<sup>127, 129, 132</sup>

The higher T-size of tumour is another major predictor of CLNM.<sup>35</sup> In contrast to other subsites of oral SCC the accurate measurement of T-size in mandibular GBC-SCC is at times difficult due to trismus. To overcome this, we emphasize on measuring T-size after resection of the tumour, intraoperatively. T-size was reliable determinant of CLNM in reported studies as seen in our study.<sup>35, 123, 146, 179</sup> The infiltration of masticator space by the tumour also predicted multi-level CLNM in our study, as it was found in locally advanced tumors. The presence of

masticator space infiltration points towards higher T-stage and locally advanced disease in mandibular GBC-SCC.

Although frozen section is a validated technique in detecting nodal metastasis intraoperatively, the drawbacks of this technique include lack of availability at all centers, requirement of advanced equipment and expertise and false-negative results in detecting CLNM in 8%-20% patients.<sup>37, 202</sup> Also, recent studies show that frozen examination has poor cost to benefit ratio, as it can incur additional expenses to patients undergoing surgery for HNC.<sup>37</sup> Therefore, decision making on extent of ND based on clinico-pathological factors can be a frugal alternative to frozen examination in low resource practice.

**Limitations:**

There were the following limitations in this study in spite of endeavors to minimize them and looking at the feasibility of conducting the study:

1. Sample size: the sample size was estimated with statistical recommendations and taking into account the available studies. At the end of the study the number of patients with specific details like poor HD, LVE, PNI, those with positive metastasis at level IV, level V and tail parotid nodes were less in number. Including a greater number of patients would improve the reliability of our results.
2. Inclusion of survival analysis: inclusion of survival analysis would validate the clinico-pathological factors in terms of disease-free survival and improvise the understanding of their role on long term outcome. Lack of data on survival analysis was a limitation of this study due to its non-feasibility.

3. The patients were selected as and when they met the inclusion criteria. Thus, equal distribution in each T-stage (from T1 to T4) was not possible and this was beyond our control.
4. Other factors like BMI, co-morbidities and inflammatory response resulting from tumour can influence the results of LNY obtained by our study.

**Strengths of study:**

1. Prospective design: the possibility of loss of relevant information with regards to specific aspect of disease is minimized due to prospective design. All the information and clinical findings that were relevant for predicting CLNM from primary mandibular GBC-SCC were obtained after selecting patients and clinico-radiological examination.
2. Subsite specificity: this study is based exclusively on mandibular GBC as subsite of SCC and clinico-pathological factors unique to this subsite were studied.
3. Constant field of neck dissection: the ND fields were similar in all operated cases. The outcomes in terms of LNY, nodes harvested per level, location of positive nodes and pathological features of the nodes were studied uniformly in all cases.
4. Grossing of resection specimens were based on established protocol to avoid errors of arbitrary methods.
5. Dependence on intra-operative features of tumors for decision making on extent of ND rather than final histological findings.
6. This study was first to report the adequacy of neck nodes for accurate nodal staging in Indian patients with mandibular GBC-SCC.

7. This study explores the efficacy of intraoperative measurements for decision making on extent of ND done by operating surgeon, using simple instruments like metric scale and survey dividers. This method can be a frugal alternative to intra-operative frozen examination and useful in low resource setting.

**Future scope:**

Further studies with larger sample size can be conducted to evaluate the validity of locally advanced stage and GTT in primary mandibular GBC-SCC with regards to decision making on the extent of ND.

Inclusion of survival analysis can help in improving reliability of these factors on long term loco-regional control in primary mandibular GBC-SCC.

In the centers where intraoperative frozen section is available, randomized control trials can be conducted to evaluate the efficacy of intraoperative measurements of GTT by surgeon compared with frozen examinations in patients with primary mandibular GBC-SCC in predicting the CLNM at level IV and level V nodes.

## CONCLUSION

The CLNM in primary mandibular GBC-SCC occurs in an orderly manner with the first station of metastatic deposit being level I lymph-nodes. Level I B or submandibular group of lymph-nodes are commonly involved by metastatic disease due to primary SCC of mandibular GBC. Level I B lymph-nodes are either involved in isolation or in combination with other group of lymph-nodes. The second common station of lymph-node metastasis in GBC-SCC is level II or upper jugulo-digastric lymph-nodes followed by mid-jugular or level III lymph-nodes. The prevalence of occult lymph-node metastasis in mandibular GBC-SCC is 24%. The prevalence of CLNM in mandibular GBC-SCC are Level I 76%, level II 51%, level III 22%, level IV and level V were 11% each, when 3046 lymph nodes were processed in 130 patients. Except for level I B no other nodal level was affected in isolation by metastasis from mandibular GBC-SCC. Even when clinically node positive necks were considered, the prevalence of metastasis to level IV and level V were 11%. Tail parotid nodes showed metastatic deposits from primary mandibular GBC-SCC in 10% of patients. These nodes were observed to be positive when primary mandibular GBC-SCC was associated with multi-level metastatic lymphadenopathy in the neck, extra-capsular spread in the neck nodes and locally advanced disease with skin infiltration. When RCP protocol of grossing was followed with fixed ND field, the mean number of lymph-nodes harvested in comprehensive ND were  $23.61 \pm 5.15$  in Indian patients with mandibular GBC-SCC. The LNY in 130 patients ranged from 14-37 with median of 23. Locally advanced stage identified by clinical and radiological methods and confirmed by pathological examination is a significant factor associated with multi-level CLNM. The clinical manifestations of locally advanced stage in mandibular GBC-SCC like infiltration of bone, masticator space and skin are also

significantly associated with multi-level CLNM. Intraoperatively measured GTT >1cm is a significant factor associated with multi-level CLNM. LVE and PNI found in patients with mandibular GBC-SCC during final histopathological reporting are significant predictors of multi-level CLNM. On multivariate analysis, locally advanced T-stage, GTT >1cm and infiltration of masticator space are significant predictors of multi-level CLNM. The possibility of metastasis to level IV, Level V and parotid nodes in primary mandibular GBC-SCC are high in patients with locally advanced disease presenting with infiltration of mandibular bone, skin and masticator space. Higher T-stage and GTT >1cm measured intraoperatively are associated with multi-level CLNM, including level IV and Level V. Extracapsular spread at level I B nodes in primary mandibular GBC-SCC is a valid predictor of metastasis at level IV, Level V and parotid nodes. In the absence of these clinico-pathological factors the ND in primary mandibular GBC-SCC can be limited to level I to level III even in node-positive necks. Further studies with larger sample size can be conducted to validate the findings of this study.

## SUMMARY

SCC of mandibular Gingivo-Buccal Complex (GBC) is a distinct cancer of the oral cavity in the Indian subcontinent. This malignancy popular as “Indian Oral Cancer,” affects mainly the male population and is a major cause of cancer related death in India. CLNM is a validated prognostic factor in mandibular GBC-SCC. The CLNM in mandibular GBC-SCC, like other subsites of oral SCC is known to occur in a foreseeable manner, involving mainly level I, level II and to lesser extent level III nodes unlike tongue or floor-mouth SCC wherein, the CLNM tends to be extensive. Neck dissection (ND) forms an essential aspect in comprehensive management of oral SCC. Although, the guidelines for ND in node-negative neck are established, there are no clear guidelines for ND in node-positive necks for primary mandibular GBC-SCC. The available guidelines for ND in node-positive necks are based on western studies, which comprise more of tongue and floor-mouth SCC and lack patients with mandibular GBC-SCC. Also, there is paucity of the literature with regards to adequacy of lymph-nodes to be harvested following ND, for accurate nodal staging in Indian patients with mandibular GBC-SCC. Furthermore, advanced CLNM in oral SCC is influenced by clinico-pathological factors that have to be identified for decision making regarding extent of ND in patients with mandibular GBC-SCC. This will help surgeons in practicing oncologically safe ND for patients with high risks of extensive CLNM and avoid morbidities related to ND in low risk patients.

The present study was designed to assess the metastatic involvement of cervical lymph-nodes (CLNs) at various levels in the neck from primary mandibular GBC-SCC and quantify the number of lymph-nodes harvested from comprehensive ND in this disease. The clinico-pathological factors that contribute to CLNM in

primary mandibular GBC-SCC were studied to evaluate their role in causation of extent of CLNM from primary mandibular GBC-SCC. These factors included: T size, histological differentiation (HD), infiltration of bone by the tumour, Lympho-vascular tumour Emboli (LVE) and Perineural Invasion (PNI). The study also intends to provide possible modifications in the extent of ND based on clinico-pathological factors in patients with node-positive necks from primary mandibular GBC-SCC.

This was a prospective observational study, conducted on 130 hospital-based patients with biopsy-confirmed, unilateral primary SCC of mandibular GBC. The patients presenting with operable, classical primary mandibular GBC-SCC requiring ipsilateral comprehensive ND with availability of level-I to level-V nodes for histopathologic examination were included. The patient's demographic details, details related to deleterious habits of patients, clinical and radiological findings of tumour and histological differentiation on biopsy (Broders) were noted. The staging of tumour was as per AJCC 2009 guidelines. Intraoperatively the linen suture ligatures with variable numbers of cut ends were tied to the fibro-fatty tissue containing CLNs after it was dissecting from its anatomical territory, with the number of cut ends of ligatures denoting each level of CLNs. The tail-parotid and level IA nodes were dissected separately during ND. Each level of CLNs was separated from main specimen by transecting between the ligatures after en-block resection of primary tumour. Also, the T-size, and gross tumour thickness (GTT) were measured intraoperatively, immediately after tumour resection. The specimens were grossed after 48 hours of formalin fixation, as per the established protocol by "The Royal College of Pathologists, Standards and datasets for reporting head and neck cancers (December 2011)".<sup>27</sup> The number of nodes per level, number of nodes positive for metastasis from primary mandibular GBC-SCC and the presence of Extra-capsular

spread in the nodes were noted. The presence of bone invasion, PNI, LVE and infiltration into surrounding structures were confirmed by histopathological findings.

Descriptive statistical analysis, Chi-square test, logistic regression and Receiver Operating Characteristic (ROC) curve were used for statistical analysis. For all the tests, the  $p < 0.05$  was considered statistically significant.

This study comprised of 130 patients with 106 (81.5%) males and 24 (18.5%) females with 69 (53.1%) patients with age over 50 years and 61 (46.9%) patients with  $\leq 50$  years. Sixty-six (50.8%) patients presented with right sided lesions and 64 (49.2%) patients presented with left sided lesions. Tobacco and arecanut chewing were found in 90% patients, alcohol consumption and smoking were less common. The duration of habits were over 10 years in 99 (76.2%) patients and less than 10 years in 31 (23.8%) patients. OSMF was most common potentially malignant disease in our patients and restricted mouth opening was a common complaint. The number of patients with T3 and T4 stage were 28 (21%) and 67 (52%) respectively and the number of patients with T1 and T2 stage were almost equal (13%). In 130 patients a total of 3046 lymph-nodes were harvested and studied. Forty-eight (37%) patients were clinically N1 staged followed by 45 (35%) patients that were clinically N0 staged. The incidence of occult CLNM was 24%. In 37 (28.5%) patients the clinical nodal staging was N2 or N3 with 19% (25/130) showing ECS at level IB. Infiltration into bone and skin was found in 43 (33%) and 28 (21.5%) patients respectively. On multivariate analysis, infiltration of masticator space, intra-operative T-size and gross tumour thickness over 1cm were significantly associated with multi-level CLNM. Involvement of level-IV and level-V by metastasis was seen in only 15 (11%) cases and that involving tail parotid nodes was seen in 13 (10%) cases. The mean number of

CLNs harvested by comprehensive ND in our patients with primary mandibular GbC-SCC was  $23.61 \pm 5.15$  and ranged from 14-37. Level IV, level I B and level III yielded over 450 lymph-nodes which was higher compared to other nodal levels. Extra-capsular spread was noted only in level IB nodes. Of the 474 lymph-nodes harvested from level I B, 187 were positive for metastasis from primary mandibular GBS-SCC. Level I B was the only nodal level involved by metastatic disease either in isolation or in combination with other levels. Isolated nodal metastasis was not found in other nodal levels.

This study concludes that CLNM in primary mandibular GBC-SCC occurs in an orderly manner with level IB most commonly involved, either in isolation or in combination with other nodal levels. CLNM to other nodal levels did not occur in isolation. On an average, 23 nodes can be harvested in Indian patients with primary mandibular GBC-SCC, by doing comprehensive level- I to level-V neck dissection with preservation of internal jugular vein and spinal accessory nerve. GTT of over 1cm, locally advanced T-stage and infiltration of masticator space were significant predictors of multi-level CLNM in patients with primary mandibular GBC-SCC. The incidence of nodal metastasis at level IV, level V and tail parotid nodes is approximately 11% even in clinically node-positive necks in primary mandibular GBC-SCC.

In the absence of locally advanced stage, ECS and GTT >1cm and no tumour infiltration into masticator space, the nodal levels IV and V may be spared during ND. Further studies with higher number of patients are essential to validate the findings of this study.

**BIBLIOGRAPHY**

1. Ferlay J, Colombet M, Soerjomataram I, Mathers C, Parkin DM, Piñeros M. Estimating the global cancer incidence and mortality in 2018: GLOBOCAN sources and methods. *Int J Cancer*. 2019 Apr 15;144(8):1941-1953. doi: 10.1002/ijc.31937. Epub 2018 Dec 6
2. Kristina SA<sup>1</sup>, Permitasari NPAL<sup>1</sup>, Krisnadewi KI<sup>2</sup>, Santoso KA<sup>2</sup>, Puspawati PR<sup>2</sup>, Masrida WO. Cancer Attributable to Tobacco Smoking in Member Countries of Association of Southeast Asian Nations (ASEAN) in Year 2018. *Asian Pac J Cancer Prev*. 2019 Oct 1;20(10):2909-2915.
3. Tandon P, Dadhich S, Saluja H, Bawane S, Sachdeva S. The prevalence of squamous cell carcinoma in different sites of the oral cavity at our Rural Health Care Centre in Loni, Maharashtra- a retrospective 10- year study. *Contemp Oncol (Pozn)*. 2017;21(2):178-183. doi: 10.5114/wo.2017.68628. Epub 2017 Jun 30
4. Alam MS, Siddiqui SA, Perween R. Epidemiological profile of head and neck cancer patients in Western Uttar Pradesh and analysis of distribution of risk factors in relation to site of tumour. *J Cancer Res Ther*. 2017 Jul-Sep;13(3):430-435. doi: 10.4103/0973-1482.180687
5. Datta S, Chaturvedi P, Mishra A, Pawar P. A review of Indian literature for association of smokeless tobacco with malignant and premalignant diseases of head and neck region. *Indian J Cancer*. 2014 July-September;51(3):200-208. doi: 10.4103/0019-509X.146713
6. Misra S, Chaturvedi A, Misra NC. Management of gingivobuccal complex cancer. *Ann R Coll Surg Engl*. 2008 Oct;90(7): 546-53.

7. Pathak KA, Gupta S, Talole S, Khanna V, Chaturvedi P, Deshpande MS et al. Advanced squamous cell carcinoma of lower gingivobuccal complex: patterns of spread and failure. *Head Neck*. 2005 Jul;27(7): 597-602.
8. Pathak KA, Agarwal R, Deshpande MS. Marginal mandibulectomy for lateral sulcus tumours. *Eur J Surg Oncol*. 2004 Sep;30(7):804-6.
9. Pai PS, Chaturvedi P, D'Cruz AK, Chaukar DA, Pathak KA, Deshpande MS et al. Reconstruction of early lower gingivobuccal complex lesions using floor of mouth advancement augmented with hyoglossus release. *J. Surg Oncol*. 2004 Apr 1;86(1):41-3.
10. Vegers JW, Snow GB, van der Waal I: Squamous cell carcinoma of the buccal mucosa. A review of 85 cases. *Arch Otolaryngol*. 1979 Apr;105(4):192-5.
11. Diaz EM Jr, Holsinger FC, Zuniga ER, Roberts DB, Sorensen DM. Squamous cell carcinoma of the buccal mucosa: one institution's experience with 119 previously untreated patients. *Head Neck*. 2003; Apr 25(4): 267-73.
12. Lin D, Bucci MK, Eisesle DW, Wang SJ. Squamous cell carcinoma of the buccal mucosa: a retrospective analysis of 22 cases. *Ear Nose Throat J*. 2008 Oct;87(10):582-6.
13. Paterson IC, Eveson JW, Prime SS (1996) Molecular changes in oral cancer may reflect aetiology and ethnic origin. *Eur J Cancer B Oral Oncol*. 1996 May;32B(3):150-3
14. Landis SH, Murray T, Bolden S, Wingo PA (1998) Cancer statistics, 1998. *CA Cancer J Clin*. 1998 Jan-Feb;48(1):6-29.
15. Guha N, Warnakulasuriya S, Vlaanderen J, Straif K. Betel quid chewing and the risk of oral and oropharyngeal cancers: a meta-analysis with implications for

- cancer control. *Int J Cancer*. 2014 Sep 15;135(6):1433-43. doi: 10.1002/ijc.28643. Epub 2014 May 14.
16. Swerdlow AJ, Marmot MG, Grulich AE, Head J. Cancer mortality in Indian and British ethnic immigrants from the Indian subcontinent to England and Wales. *Br J Cancer*. 1995;72(5):1312-19.
17. Petti S, Warnakulasuriya S. Betel quid chewing among adult male immigrants from the Indian subcontinent to Italy. *Oral Dis*. 2018;24(1-2):44-48.
18. Ferlito A, Rinaldo A, Devaney KO, MacLennan K, Meyers JN, Petruzzelli GJ et al. Prognostic significance of microscopic and macroscopic extracapsular spread from metastatic tumour in the cervical lymph nodes. *Oral Oncol*. 2002 Dec;38(8):747-51.
19. Magnano M, De Stefani A, Lerda W, Usai A, Ragona R, Bussi M, et al. Prognostic factors of cervical lymph node metastasis in head and neck squamous cell carcinoma. *Tumori*. 1997 Nov-Dec;83(6):922-6.
20. Kowalski LP, Sanabria A. Elective neck dissection in oral carcinoma: a critical review of the evidence. *Acta Otorhinolaryngol Ital*. 2007; Jun27(3):113-7.
21. Ferlito A, Silver CE, Rinaldo A. Elective management of the neck in oral cavity squamous cell carcinoma: current concepts supported by prospective studies. *Br J Oral Maxillofac. Surg*. 2009 Jan 47(1):5-9.
22. Ferlito A, Rinaldo A, Silver CE, Shah JP, Suarez C, Medina JE et al. Neck dissection: then and now. *Auris Nasus Larynx*. 2006 Dec;33(4):365-74.
23. Shah JP, Andersen PE. The impact of patterns of nodal metastasis on modifications of neck dissection. *Ann Surg Oncol*. 1994 Nov;1(6):521-32.

24. Shah JP, Candela FC, Poddar AK. The patterns of cervical lymph node metastasis from squamous cell carcinoma of the oral cavity. *Cancer*. 1990 Jul 1;66(1):109-13.
25. Robbins KT, Ferlito A, Shah JP, Hamoir M, Takes RP, Strojan P et al. The evolving role of selective neck dissection for head and neck squamous cell carcinoma. *Eur Arch Otorhinolaryngol*. 2013 Mar;270(4):1195-202.
26. Walvekar RR, Chaukar DA, Deshpande MS, Pai PS, Chaturvedi P, Kakade A et al. Squamous cell carcinoma of the gingivobuccal complex: predictors of locoregional failure in stage III-IV cancers. *Oral Oncol*. 2009 Feb;45(2):135-40.
27. Woolgar JA. Histological distribution of cervical lymph node metastases from intraoral/oropharyngeal squamous cell carcinomas. *Br J Oral Maxillofac Surg*. 1999 Jun;37(3):175-80.
28. Woolgar JA. The topography of cervical lymph node metastases revisited: the histological findings in 526 sides of neck dissection from 439 previously untreated patients. *Int J Oral Maxillofac Surg*. 2007 Mar;36(3): 219-25.
29. Liao CT, Huang SF, Chen IH, Kang CJ, Lin CY, Fan KH. Tongue and buccal mucosa carcinoma: is there a difference in outcome? *Ann Surg Oncol*. 2010 Nov;17(11):2984-91.
30. Lai TY, Hu YW, Liu YM, Chen YW, Shiao CY, Chu PY. The pattern of failure and predictors of locoregional control in lateralized buccogingival cancer after postoperative radiation therapy. *J Chin Med Assoc*. 2017 Sep;80(9):569-74.
31. Medina-Franco H, Cabrera-Mendoza F, Almaguer-Rosales S, Guillen F, Suarez-Bobadilla YL, Sanchez-Ramon A. Lymph node ratio as a predictor of survival in gastric carcinoma. *Am Surg*. 2013 Mar;79(3):284-9.

32. Hsu TW, Lu HJ, Wei CK, Yin WY, Chang CM, Chiou WY, *et al.* Clinical and pathologic factors affecting lymph node yields in colorectal cancer. *PLoS One*. 2013 Jul 16;8(7): e68526.
33. Ooki A, Yamashita K, Kobayashi N, Katada N, Sakuramoto S, Kikuchi S *et al.* Lymph node metastasis density and growth pattern as independent prognostic factors in advanced esophageal squamous cell carcinoma. *World J Surg*. 2007 Nov;31(11):2184-91. Epub 2007 Aug 24
34. Agarwal R, Philip A, Pavithran K, Rajanbabu A, Geol G, Vijaykumar DK. Prognostic significance of residual nodal burden using lymph node ratio in locally advanced breast cancer after neoadjuvant chemotherapy. *Indian J Cancer*. 2019 Jul-Sep;56(3): 228-235.
35. Woolgar JA. Histopathological prognosticators in oral and oropharyngeal squamous cell carcinoma. *Oral Oncol*. 2006;42(3):229-39.
36. Puri SK, Fan CY, Hanna E. Significance of extracapsular lymph node metastasis in patients with head and neck squamous cell carcinoma. *Curr Opin Otolaryngol Head Neck Surg*. 2003;11(2):119-123.
37. Datta S, Mishra A, Chaturvedi P, Bal M, Nair D, More Y *et al.* Frozen section is not cost beneficial for the assessment of margins in oral cancer. *Indian J Cancer*. 2019;56(1):19-23.
38. Bhaskar SN, Kumar GS. *Orban's Oral histology and embryology*, 14<sup>th</sup> edition, Elsevier, 2015 pp 267-79.
39. Ramsay AD. 30 years of lymph node pathology: biomarkers and other advances. *Appl Immunohistochem Mol Morphol*. 2013 Mar;21(2):103-9.

40. Borodin Iul, Trufakin VA, Triasuchey PM. Regional features of the cellular composition of different zones of lymph nodes in the adult human. *Arkh Anat Gistol Embriol.* 1985 Mar;88(3):76-8.
41. Turner VM, Mabbott NA. Influence of ageing on the microarchitecture of the spleen and lymph nodes. *Biogerontology.* 2017 Oct;18(5):723-38.
42. Warwick, Roger; Peter L. Williams (1973) [1858]. "Angiology (Chapter 6)" *Gray's anatomy*. illustrated by Richard E. M. Moore (Thirty-fifth ed.). London: Longman. pp. 588–785.
43. Kaldjian, Eric P.; J. Elizabeth Gretz, Arthur O. Anderson, Yinghui Shi, Stephen Shaw. Spatial and molecular organization of lymph node T cell cortex: a labyrinthine cavity bounded by an epithelium-like monolayer of fibroblastic reticular cells anchored to basement membrane-like extracellular matrix. *International Immunology (Oxford Journals)*; 2001: 13 (10): 1243–53.
44. Katakai, Tomoya; Takahiro Hara, Hiroyuki Gonda<sup>1</sup>, Manabu Sugai, Akira Shimizu. A novel reticular stromal structure in lymph node cortex: an immunopatform for interactions among dendritic cells, T cells and B cells. *International Immunology* 2004;16 (8): 1133–42.
45. Yoffey JM, Courtice FC. Structure and function of nodes. In: Yoffey JM, Courtice FC, editors. *Lymphatics, lymph and the lymphomyeloid complex*. London: Academic Press. 1970 p 517–619.
46. Be´lisle C, Sainte-Marie G. Tridimensional study of the deep cortex of the rat lymph node. II. Relation of deep cortex units to afferent lymphatic vessels. *Anat Rec.* 1981 Jan;199(1):61-72.
47. Aijima H, Horie K, Nagata H, Hoshi H. Cortical structure of bovine lymph nodes. *Acta Anat NipponKaibogaku Zasshi.* 1986 Jun;61(3):173-85

48. Hoshi H, Nataga H, Aijima H, Horie K. Functional compartmentalization of the lymph node architecture and afferent lymphatic vessels. In: Ohtani O, Kato S, Uchino S, editors. The lymphatics: morphology, function, development. Niigata:1997 Nisshimura.p 45–52.
49. Sainte-Marie G, Sin YM. Structures of the lymph node and their possible function during the immune response. In: Gordon AS, editor. Regulation of haematopoiesis. New York: Appleton-Century-Crofts.1970 Vol. II: p 1339–83.
50. Gutman GA, Weisman L. Lymphoid tissue architecture. Experimental analysis of the origin and distribution of T-cells and B-cells. Immunology. 1972 Oct;23(4):465-79.
51. Okada S, Albrecht RM, Aharinejad S, Schraufnagel DE. Structural aspects of the lymphocyte traffic in rat submandibular lymph node. Microsc Microanal. 2002 Apr;8(2):116-33.
52. Willard-Mack CL. Normal structure, function, and histology of lymph nodes. Toxicol Pathol. 2006;34(5):409-24
53. Elmore SA. Enhanced Histopathology Evaluation of Lymphoid Organs. Methods Mol Biol. 2018;1803:147-168. doi: 10.1007/978-1-4939-8549-4\_10.
54. Burwell R. Studies of the primary and the secondary immune responses of lymph nodes draining homografts of fresh cancellous bone (with particular reference to mechanisms of lymph node reactivity). Ann NY Acad Sci. 1962 Oct 24; 99: 821-60.
55. Shah JP. Patterns of cervical lymph node metastasis from squamous carcinomas of the upper aerodigestive tract. Am J. Surg.1990 Oct;160(4):405-9.
56. Shah JP, Patel SG. HEAD NECK SURGERY AND ONCOLOGY, 3<sup>rd</sup> Ed. Mosby 2003.

57. Rubatelli L, Khadivi Y, Tregnaghi A, Stramare R, Ferro F, Borsato Set al. Evaluation of Lymph Node Perfusion Using Continuous Mode Harmonic Ultrasonography with a Second-Generation Contrast Agent. *J Ultrasound Med.* 2004 Jun;23(6):829-36
58. Giovagnorio F. Color Doppler sonography in the evaluation of superficial lymphomatous lymph nodes. *J Ultrasound Med.* 2002 Apr;21(4):403-8.
59. Som P. Lymph nodes of the neck. *Radiology.* 1987 Dec;165(3):593-600.
60. Sinnatamby CS, Last RJ. *Anatomy regional and applied.* 6th ed. New York: Elsevier/Churchill Livingstone; 2006. p. 376-8.
61. Sathyanarayan V, Bharani SK. Enlarged lymph nodes in head and neck cancer: Analysis with triplex ultrasonography. *Ann Maxillofac Surg.* 2013 Jan;3(1):35-9.
62. Sureshkannan P; Vijayprabhu, John R. Role of ultrasound in detection of metastatic neck nodes in patients with oral cancer. *Indian J Dent Res.* 20 Jun;22(3):419-23
63. Imani Moghaddam M, Davachi B, Mostaan LV, Langaroodi AJ, Memar B, Azimi SA, Marouzi P. Evaluation of the sonographic features of metastatic cervical lymph nodes in patients with head and neck malignancy. *Craniofac Surg.* 2011 Nov;22(6):2179-84
64. Eida S, Sumi M, Yonetsu K, Kimura Y, Nakamura T. Combination of helical CT and Doppler sonography in the follow-up of patients with clinical N0 stage neck disease and oral cancer. *AJNR Am J Neuroradiol.* 2003 Mar;24(3):312-8.
65. Nieuwenhuis EJ, Colymph-nodeot DR, Pijpers HJ, Castelijns JA, van Diest PJ, Brakenhoff RH et al. Lymphoscintigraphy and ultrasound-guided fine needle aspiration cytology of sentinel lymph nodes in head and neck cancer patients. *Recent Results Cancer Res.* 2000; 157:206-17.

66. Van den Brekel MW, Castelijns JA, Stel HV, Luth WJ, Valk J, van der Waal I et al. Occult metastatic neck disease: detection with US and US-guided fine-needle aspiration cytology. *Radiology*. 1991 Aug;180(2):457-61.
67. Som PM. Detection of metastasis in cervical lymph nodes: CT and MR criteria and differential diagnosis. *AJR Am J Roentgenol*. 1992 May;158(5):961-9
68. Arya S, Chaukar D, Pai P. Imaging in oral cancers. *Indian J Radiol Imaging*. 2012 Jul;22(3):195-208.
69. Weissman JL, Carrau RL. "Puffed cheek" CT improves evaluation of the oral cavity. *AJNR Am J Neuroradiol*. 2001 Apr;22(4):741-4.
70. Curtin HD, Ishwaran H, Mancuso AA et al. Comparison of CT and MR imaging in staging of neck metastasis. *Radiology*. 1998 Apr;207(1):123-30.
71. Kimura Y, Sumi M, Sumi T, Ariji Y, Ariji E, Nakamura T. Deep extension of carcinoma arising from the gingiva: CT and MR imaging features. *AJNR Am J Neuroradiol*. 2002 Mar;23(3):468-72.
72. Henrot P, Blum A, Toussaint B, Troufleau P, Stines J, Roland J. Dynamic maneuvers in local staging of head and neck malignancies with current imaging techniques: Principles and clinical applications. *Radiographics*. 2003 Sep-Oct;23(5):1201-13.
73. Rao LP, Das SR, Mathews A, Naik BR, Chacko E, Pandey M. Mandibular invasion in oral squamous cell carcinoma: Investigation by clinical examination and orthopantomogram. *Int J Oral Maxillofac Surg*. 2004 Jul;33(5):454-7.
74. Close LG, Burns BK, Merkel M, Schaefer SD. Computed tomography and assessment of mandibular invasion by intraoral carcinoma. *Ann Otol Rhinol Laryngol*. 1986 Jul-Aug;95(4 Pt 1):383-8.

75. Brown JS, Griffith JF, Phelps PD, Browne RM. A comparison of different imaging modalities and direct inspection after periosteal stripping in predicting the invasion of the mandible by oral squamous cell carcinoma. *Br J Oral Maxillofac Surg.* 1994 Dec;32(6):347-59.
76. Van den Brekel MW, Runne RW, Smeele LE, Tiwari RM, Snow GB, Castelijns JA et al. Assessment of tumor invasion into the mandible: The value of different imaging techniques. *Eur Radiol.* 1998;8(9):1552-7.
77. Curran AJ, Toner M, Quinn A, Wilson G, Timon C. Mandibular invasion diagnosed by SPECT. *Clin Otolaryngol.* 1996 Dec;21(6):542-5.
78. Weissman RA, Kimmelman CP. Bone scanning in the assessment of mandibular invasion by oral cavity carcinomas. *Laryngoscope.* 1982 Jan;92(1):1-4.
79. Vadiri A, Guerrisi A, Pellini R, Manciooco V, Covello R, Mattioni O et al. Multi-detector row computed tomography (MDCT) and magnetic resonance imaging (MRI) in the evaluation of the mandibular invasion by squamous cell carcinoma (SCC) of the oral cavity. Correlation with pathological data. *J Exp Clin Cancer Res.* 2010 Jun 17; 29:73.
80. Handschel J, Nauioks C, Depprich RA, Kubler NR, Kropil P, Kuhlemann J et al. CT-scan is a valuable tool to detect mandibular involvement in oral cancer patients. *Oral Oncol.* 2012 Apr;48(4):361-6. doi: 10.1016/j.oraloncology.2011.11.009. Epub 2011 Dec 11.
81. de Bondt RB, Nelemans PJ, Hofman PA, Casselman JW, Kremer B, van Engelshoven JM et al. Detection of lymph node metastasis in head and neck cancer: A meta-analysis comparing US, USgFNAC, CT and MR imaging. *Eur J Radiol.* 2007 Nov;64(2):266-72. Epub 2007 Mar 27.

82. Sumi M, Sakihama N, Sumi T, Morikawa M, Uetani M, Kabasawa H et al. Discrimination of metastatic cervical lymph nodes with diffusion-weighted MR images in patients with head and neck cancer. *AJNR Am J Neuroradiol.*2003; 24:1627-34.
83. Yousem DM, Gad K, Tufano RP. Resectability issues with head and neck cancer. *AJNR Am J Neuroradiol.*2006 Nov-Dec;27(10):2024-36.
84. Mukherji SK, Bradford CR. Is there a role of PET –CT in the initial staging of head and neck squamous cell carcinoma? *AJNR Am J Neuroradiol.* 2006 Feb;27(2):243-5.
85. Yen TC, Chang JT, Ng SH, Chang YC, Chan SC, Wang HM et al. Staging of untreated squamous cell carcinoma of buccal mucosa with 18F-FDG PET: comparison with head and neck CT/MRI and histopathology. *J Nucl Med.* 2005 May;46(5):775-81.
86. Li-Jen Liao, Wu-Chia Lo, Wan-Lun Hsu, Chi-Te Wang, Mei-Shu Lai. Detection of cervical lymph node metastasis in head and neck cancer patients with clinically N0 neck—a meta- analysis comparing different imaging modalities. *BMC Cancer.* 2012 Jun 12;12:236. doi: 10.1186/1471-2407-12-236.
87. Karino M, Nakatani E, Hideshima K, Nariai Y, Tsunematsu K, Ohira K et al. Applicability of preoperative nuclear morphometry to evaluating risk for cervical lymph node metastasis in oral squamous cell carcinoma. *PloS One.* 2014 Dec 30;9(12):e116452 DOI: 10.1371/journal.pone.0116452 December 30, 2014, 1-15.
88. Ferlito A, Rinaldo A, Robbins KT, Leemans CR, Shah JP, Saha AR et al. Changing concepts in the surgical management of the cervical lymph node metastasis. *Oral Oncol.* 2003 Jul;39(5):429-35.

89. Woolgar JA, Triantafyllou A, Lewis Jr JS, Hunt J, Williams ND, Takes RP et al. Prognostic biological features in neck dissection specimens. *Eur Arch Otorhinolaryngol.* 2013 May;270(5):1581-92.
90. Hamoir M, Schmitz S, Gregoire V. The role of neck dissection in squamous cell carcinoma of the head and neck. *Curr Treat Options Oncol.* 2014 Dec;15(4):611-24.
91. Crile G. Excision of cancer of the head and neck with special reference to the plan of dissection based on 132 patients. *JAMA.* 1906;47: 1780-1786.
92. Martin HE, Del Valle B, Ehrlich H, Cahan WG. Neck Dissection. *Cancer.* 1951; 4:441-499.
93. Nahum AM, Mullally W, Marmor L. A syndrome resulting from radical neck dissection. *Arch Otolaryngol.* 1961 Oct; 74:424-8.
94. Ward GE, Robben JO. A composite operation for the radical neck dissection and removal of cancer of the mouth. *Cancer.* 1951 Jan;4(1):98-109.
95. Saunders Jr JR, Hirata RM, Jaques DA. Considering the spinal accessory nerve in head and neck surgery. *Am J Surg.* 1985; 150:491-94.
96. Magrin J, Kowalski LP. Bilateral radical neck dissection: results in 193 cases. *J Surg Oncol.* 2000; 75:232-40.
97. Suárez O. El problema de las metastasis linfáticas y alejadas del cáncer de laringe e hipofaringe. *Rev Otorrinolaringol.* 1963; 23:83—99.
98. Ballantyne AJ. Classical and functional neck dissection. In: Ariyan S, editor. *Cancer of the head and neck.* St Louis: C.V. Mosby Company; 1987.
99. Kuntz AL, Weymuller Jr EA. Impact of neck dissection on quality of life. *Laryngoscope.* 1999 Aug;109(8):1334-8.

100. Davidson BJ, Kulkarny V, Delacure MD, Shah JP. Posterior triangle metastasis of squamous cell carcinoma of the upper aerodigestive tract. *Am J Surg.* 1993 Oct;166(4):395-8.
101. León X, Quer M, Orús C, Sancho FJ, Bague S, Burgués J. Selective dissection of levels II-III with intraoperative control of the upper and middle jugular nodes: a therapeutic option for the N0 neck. *Head Neck.* 2001 Jun;23(6):441-6.
102. Pitman KT, Johnson JT, Myers EN. Effectiveness of selective neck dissection for management of the clinically negative neck. 1997 Sep;123(9):917-22.
103. Davidson J, Khan Y, Gilbert R, Birt BD, Balogh J, MacKenzie R. Is selective neck dissection sufficient treatment for the N0/Np+ neck? *J Otolaryngol* 1997 Aug;26(4):229-31.
104. Robbins KT, Clayman G, Levine PA, Medina J, Sessions R, Shaha A et al and the Committee for Head and Neck Surgery and Oncology. American Academy of Otolaryngology-Head and Neck Surgery. Neck dissection classification update. Revisions proposed by the American Head and Neck Society and the American Academy of Otolaryngology-Head and Neck Surgery. *Arch Otolaryngol Head Neck Surg.* 2002 Jul;128(7):751-8.
105. Andersen PE, Warren F, Spiro J, Burningham A, Wong R, Wax MK et al. Results of selective neck dissection in management of the node-positive neck. *Arch Otolaryngol Head Neck Surg.* 2002 Oct;128(10):1180-4.
106. Ambrosch P, Kron M, Pradier O, Steiner W. Efficacy of selective neck dissection: a review of 503 cases of elective and therapeutic treatment of the neck in squamous cell carcinoma of the upper aerodigestive tract. *Otolaryngol Head Neck Surg.* 2001 Feb;124(2):180-7.

107. Yuen AP, Wei WI, Wong YM, Tang KC. Elective neck dissection versus observation in the treatment of early oral tongue carcinoma. *Head Neck*. 1997 Oct;19(7):583-8.
108. Huang SF, Chang JT, Liao CT, Kang CJ, Lin CY, Fan KH et al. The role of elective neck dissection in early stage buccal cancer. *Laryngoscope* 2015 Jan;125(1):128-33.
109. Vandembrouck C, Sancho-Garnier H, Chassagne D, Saravane D, Cachin Y, Micheau C. Elective versus therapeutic radical neck dissection in epidermoid carcinoma of the oral cavity: results of a randomized clinical trial. *Cancer* 1980; Jul 15;46(2): 386-90.
110. D'Cruz AK, Vaish R, Kapre N, Dandekar M, Gupta S, Hawaldar R et al. Elective versus therapeutic neck dissection in node-negative oral cancer. *N Engl J Med*. 2015 Aug 6;373(6):521-9.
111. Dillon JK, Villing AS, Jones RS, Futran ND, Brockhoff HC 2<sup>nd</sup>, Carlson ER et al. What is the role of elective neck dissection in the management of patients with buccal squamous cell carcinoma and clinically negative neck? *J Oral Maxillofac Surg*. 2019 Mar;77(3): 641-47.
112. Kowalski LP, Sanabria A. Elective neck dissection in oral carcinoma: a critical review of the evidence. *Acta Otorhinolaryngol Ital*. 2007 Jun;27(3):113-7.
113. Kowalski LP, Magrin J, Waksman G, Santo GF, Lopes ME, De Paula RP, et al. Supraomohyoid neck dissection in the treatment of head and neck tumors. Survival results in 212 cases. *Arch Otolaryngol Head Neck Surg* 1993 Sep;119(9):958-63.

114. Platz H, Fries R, Hudec M, Tjoa AM, Wagner RR. The prognostic relevance of various factors at the time of first admission of the patient. *J Maxillofac Surg.* 1983 Feb;11(1):3-12.
115. Dayal PK, Mani NJ, Bhargava K. Prevalence of oral cancer and precancerous lesions in 'pan'/'supari' chewers. *Indian J Public Health* 1978 Jul-Sep;22(3):234-45.
116. Diaz EM Jr, Holsinger FC, Zuniga ER, Roberts DB, Sorensen DM. Squamous cell carcinoma of the buccal mucosa: one institution's experience with 119 previously untreated patients. *Head Neck* 2003 Apr;25(4):267-73.
117. Jan JC, Hsu WH, Liu SA, Wong YK, Poon CK, Jiang RS et al. Prognostic factors in patients with buccal squamous cell carcinoma: 10-year experience. *J Oral Maxillofac Surg.* 2011 Feb;69(2):396-404.
118. Huang CH, Chu ST, Ger LP, et al: Clinicopathologic evaluation of prognostic factors for squamous cell carcinoma of the buccal mucosa. *J Chin Med Assoc.* 2007 Apr;70(4):164-70.
119. Woolgar JA, Scott J, Vaughan ED, Brown JS, West CR, Rogers S. Survival, metastasis and recurrence of oral cancer in relation to pathological features. *Ann R Coll Surg Engl.* 1995 Sep;77(5):325-31.
120. Cariati P, Cabello Serrano A, Marin Fernandez A, Julia Martinez MA, Fernandez Solis J, Martinez Lara. Behaviour of buccal mucosal squamous cell carcinoma: A retrospective study of 53 carcinomas of this anatomical region. *Craniofacial Trauma Reconstr.* 2019 Mar;12(1):8-13.
121. Urist MM, O'Brien CJ, Soong SJ, Visscher DW, Maddox WA. Squamous cell carcinoma of the buccal mucosa: analysis of prognostic factors. *Am J Surg.* 1987 Oct;154(4):411-4.

122. Huang SH, Hwang D, Lockwood G, Goldstein DP, O'Sullivan B: Predictive value of tumour thickness for cervical lymph-node involvement in squamous cell carcinoma of the oral cavity: a meta-analysis of reported studies. *Cancer*2009, 115(7):1489-97
123. Jerjes W, Upile T, Petrie A, Riskalla A, Hamdoon Z, Vourvachis M et al. Clinicopathological parameters, recurrence, locoregional and distant metastasis in 115 T1-T2 oral squamous cell carcinoma patients. *Head Neck Oncol.*2010 Apr 20; 2:9.
124. Larsen SR, Johansen J, Sørensen JA, Krogdahl A: The prognostic significance of histological features in oral squamous cell carcinoma. *J Oral Pathol Med*2009, 38(8):657-62.
125. Kademani D, Bell RB, Bagheri S, Holmgren E, Dierks E, Potter B, Homer L: Prognostic factors in intraoral squamous cell carcinoma: the influence of histologic grade. *J Oral Maxillofac Surg*2005, 63(11): 1599-605.
126. Y. Okada, I. Mataga, M. Katagiri, K. Ishii: An analysis of cervical lymph nodesmetastasis in oral squamous cell carcinoma. Relationship between grade of histopathological malignancy and lymph nodes metastasis. *Int. J. Oral Maxillofac.Surg.* 2003 Jun;32(3):284-8.
127. Mishra RC, Parida G, Mishra TK, Mohanty S. Tumour thickness and relationship to locoregional failure in cancer of the buccal mucosa. *Eur J Surg Oncol*1999 Apr;25(2):186-9.
128. Nair S, Singh B, Pawar PV, Datta S, Nair D, Kane S et al. Squamous cell carcinoma of tongue and buccal mucosa: clinico-pathologically different entities. *Eur Arch Otorhinolaryngol.* 2016 Nov;273(11):3921-8.

129. Lai TY, Hu YW, LiuYM, Chen YW, Shiau CY, Chu PY. The pattern of failure and predictors of locoregional control in lateralized buccogingival cancer after postoperative radiation therapy. *J Chin Med Assoc.* 2017 Sep;80(9):569-574.
130. Vincent N, Dassonville O, Chamorey E, Poissonnet G, Pierre CS, Nao EE et al. Clinical and histological prognostic factors in locally advanced oral cavity cancers treated with primary surgery. *Eur Ann Otorhinolaryngol Head Neck Dis.* 2012 Dec;129(6):291-6.
131. Xu SS, Li D, Zhou Y, Sheng B, Zeng C, Zhong SX. Pathways involved in the spread of buccal carcinoma on contrast-enhanced multislice CT. *Dentomaxillofac Radiol.* 2015;44(2):20140111.
132. Moore C, Kuhns JG, Greenberg RA. Thickness as a prognostic aid in upper aerodigestive tract cancer. *Arch Surg.* 1986 Dec;121(12):1410-4.
133. Pollaers K, Hinton-Bayre A, Friedland PL, Farah CS. AJCC 8th Edition oral cavity squamous cell carcinoma staging - Is it an improvement on the AJCC 7th Edition? *Oral Oncol.* 2018 Jul; 82:23-28.
134. Liao CT, Huang SF, Chen IH, Chang JT, Wang HM, Ng SH et al. When does skin excision allow the achievement of an adequate local control rate in patients with squamous cell carcinoma involving the buccal mucosa? *Ann Surg Oncol.* 2008 Aug;15(8): 2187-94.
135. Mair M, Nair S, Thiagarajan SK, Agarwal J, Nair D, Chaturvedi P. Skin involvement and ipsilateral nodal metastasis as a predictor of contralateral nodal metastasis in buccal mucosa cancers. *Indian J Cancer.* 2016 Jul-Sep;53(3): 394-6.

136. Brown JS, Kalavrezos N, D'Souca J, Magennis P, Woolgar JA. Factors that influence the method of mandibular resection in the management of oral squamous cell carcinoma. *Br J Oral Maxillofac Surg.* 2002 Aug;40(4):275-84.
137. Shaw RJ, Brown JS, Woolgar JA, Lowe D, Rogers SN, Vaughan ED. The influence of the pattern of mandibular invasion on recurrence and survival in oral squamous cell carcinoma. *Head Neck.* 2004 Oct;26(10):861-9.
138. Kuk SK, Yoon HJ, Hong SP, Lee JI. Staging significance of bone invasion in small-sized (4 cm or less) oral squamous cell carcinoma as defined by the American Joint Committee on Cancer. *Oral Oncol.* 2016 Apr; 55:31-6.
139. Spiro RH, Huvos AG, Wong GY, Spiro JD, Gnecco CA, Strong EW. Predictive value of tumor thickness in squamous carcinoma confined to the tongue and floor of the mouth. *Am J Surg.* 1986 Oct; 152(4):345-50.
140. Gonzalez-Moles MA, Esteban F, Rodriguez-Archilla A, Ruiz Avila I, Gonzalez-Moles S. Importance of tumour thickness measurement in prognosis of tongue cancer. *Oral Oncol.* 2002 Jun; 38(4):394-7.
141. Fukano H, Matsuura H, Hasegawa Y, Nakamura S. Depth of invasion as a predictive factor for cervical lymph node metastasis in tongue carcinoma. *Head Neck.* 1997; May 19(3):205-10.
142. Pentenero M, Gandolfo S, Carrozzo M. Importance of tumor thickness and depth of invasion in nodal involvement and prognosis of oral squamous cell carcinoma: a review of the literature. *Head Neck.* 2005; Dec27(12):1080-91.
143. Mohiyuddin A, Padiyar V, Suresh TN, Mohammadi A, Merchant SS. Clinico-pathological study of surgical margins in squamous cell carcinoma of buccal mucosa. *World Journal of Otorhinolaryngology-Head and Neck Surgery* 2016 Mar 31; 2(1):17-21.

144. Kreppel M, Nazarli P, Grandoch A, Safi AF, Zirk M, Nickenig HJ et al. Clinical and histopathological staging in oral squamous cell carcinoma - Comparison of the prognostic significance. *Oral Oncol.* 2016 Sep;60:68-73
145. Tai SK, Li WY, Yang MH, Chu PY, Wang YF, Chang PM. Perineural invasion as a major determinant for the aggressiveness associated with increased tumour thickness in t1-2 oral tongue and buccal squamous cell carcinoma. *Ann Surg Oncol.* 2013 Oct;20(11):3568-74.
146. Manjula BV, Augustine S, Selvam S, Mohan AM. Prognostic and predictive factors in gingivo buccal complex squamous cell carcinoma: role of tumour budding and pattern of invasion. *Indian J Otolaryngol Head Neck Surg.* 2015 Mar;67(Suppl 1):98-104.
147. Woolgar JA, Rogers SN, Lowe D, Brown JS, Vaughan ED. Cervical lymph node metastasis in oral cancer: the importance of even microscopic extracapsular spread. *OralOncol* 2003 Feb; 39(2):130–7.
148. Kowalski LP, Bagietto R, Lara JR, Santos RL, Silva JF, Magrin M. Prognostic significance of the distribution of neck node metastasis from oral carcinoma. *Head Neck* 2000 May; 22(3):207–14.
149. Shah JP, Cendon RA, Farr HW, Strong EW. Carcinoma of the oral cavity. Factors affecting treatment failure at the primary site and neck. *Am J Surg* 1976 Oct; 132(4):504–7.
150. Arya S, Chaukar D, Pai P. Imaging in oral cancers. *Indian J Radiol Imaging.* 2012 Jul;22(3):195-208.
151. Carlton JA, Maxwell AW, Bauer LB, McElroy SM, Layfield LJ, Ahsan H et al. Computed tomography detection of extracapsular spread of squamous cell

- carcinoma of the head and neck in metastatic cervical lymph nodes. *Neuroradiol J.* 2017 Jun;30(3):222-9.
152. Url C, Schartinger VH, Riechelmann H, Gluckert R, Maier H, Trumpp M et al. Radiological detection of extracapsular spread in head and neck squamous cell carcinoma (HNSCC) cervical metastasis. *Eur J Radiol.* 2013 Oct;82(10):1783-7.
153. Wreesmann VB, Katabi N, Palmer FL, Montero PH, Migliacci JC, Gonen M et al. Influence of extracapsular nodal spread extent on prognosis of oral squamous cell carcinoma. *Head Neck.* 2016 Apr;38(Suppl 1):192-9.
154. Marres CC, de Ridder M, Hegger I, van Velthuysen ML, Hauptmann M, Navran A et al. The influence of nodal yield in neck dissection on lymph node ratio in head and neck cancer. *Oral Oncol.* 2014 Jan;50(1):59-64.
155. Patel SG, Amit M, Yen TC, Liao CT, Chaturvedi P, Agarwal JP et al. Lymph node density in oral cavity cancer: results of the international consortium for outcomes research. *Br J Cancer.* 2013 Oct 15;109(8):2087-95.
156. Lang BH, Yin PC, Shek TW, Wan KY, Wong KP, Lo CY. Factors affecting the adequacy of lymph node yield in prophylactic unilateral central neck dissection for papillary thyroid carcinoma. *J Surg Oncol.* 2012 Dec;106(8):966-71.
157. Kerawala CJ, Bisase B, Hopper A. Is total nodal yield in neck dissections influenced by the method of specimen presentation to the pathologist? *Br J Oral Maxillofac Surg.* 2009 Jul;47(5):360-2.
158. Cramer JD, Reddy A, Ferris RL, Duvvuri U, Samant S. Comparison of seventh and eighth edition American joint committee on cancer oral cavity staging system. *Laryngoscope.* 2018 Oct;128(10): 2351-60.

159. McKean ME, Lee K, McGregor IA. The distribution of lymph nodes in and around the parotid gland: an anatomical study. *Br J Plast Surg.*1985 Jan;38(1):1-5.
160. Helliwell T, Woolgar J. Dataset for Histopathology Reporting of Nodal Excisions and Neck Dissection Specimens Associated with Head and Neck Carcinomas. 7th December, 2011. Available from: <http://www.rcpath.org>. [Last accessed on 2016 Jan 16].
161. Barnes L, Eveson JW, Reichart P, Sidransky D. World Health Organization Classification of Tumours. Pathology and Genetics of Head and Neck Tumours. Volume 9. IARC, Lyon, 2005. Reproduced with permission
162. Barnes L, Eveson JW, Reichart P, Sidransky D. World Health Organization Classification of Tumours. Pathology and Genetics of Head and Neck Tumours. Volume 9. IARC, Lyon, 2005. Reproduced with permission.
163. Odell EW, Jani P, Sherriff M, Ahluwalia SM, Hibbert J, Levison DA *et al.* The prognostic value of individual grading parameters in small lingual squamous cell carcinomas. The importance of the pattern of invasion. *Cancer* 1994 Aug 1; 74(3):789–794.
164. Binmadi NO, Basile JR. Perineural invasion in oral squamous cell carcinoma: a discussion of significance and review of the literature. *Oral Oncol.* 2011 Nov;47(11):1005-10.
165. Müller S, Boy SC, Day TA, Magliocca KR, Richardson MS, Sloan P, Tilakaratne WM, Zain RB, Thompson LDR. Data Set for the Reporting of Oral Cavity Carcinomas: Explanations and Recommendations of the Guidelines from the International Collaboration of Cancer Reporting. *Arch Pathol Lab Med.* 2019 Apr;143(4):439-446.

166. Bobdey S, Sathwara J, Jain A, Saoba S, Balasubramaniam G. Squamous cell carcinoma of buccal mucosa: An analysis of prognostic factors. *South Asian J Cancer*. 2018 Jan -Mar;7(1):49-54.
167. Chhetri DK, Rawnsley JD, Calcaterra TC. Carcinoma of the buccal mucosa. *Otolaryngol Head Neck Surg*. 2000 Nov;123(5):566-71.
168. Zini A, Nasser N, Vered Y: Oral and pharyngeal cancer among the Arab population in Israel from 1970 to 2006. *Asian Pac J Cancer Prev* 2012, 13(2):585–589.
169. Lin TC, Tsou YA, Lin MH, Hua CH, Tseng HC, Bau DT, Tsai MH: Impact of neck dissection in early tongue and buccal cancer without neck extension. *B-ENT* 2011;7(2): 97–102.
170. Kuo MY, Jeng JH, Chiang CP, et al. Mutations of Ki-ras oncogene codon 12 in betel quid chewing-related human oral squamous cell carcinoma in Taiwan. *J Oral Pathol Med* 1994; Feb 23(2):70–74.
171. Chiba I, Muthumala M, Yamazaki Y, Uz Zaman A, Iizuka T, Amemiya A. Characteristics of mutations in the p53 gene of oral squamous-cell carcinomas associated with betel-quid chewing in Sri Lanka. *Int J Cancer* 1998 Sep 11; 77(6):839–842
172. Chen IH, Chang JT, Liao CT, et al. Prognostic significance of EGFR and Her-2 in oral cavity cancer in betel quid prevalent area cancer prognosis. *Br J Cancer* 2003 Aug 18; 89(4):681–686.
173. Lee JJ, Jeng JH, Wang HM, et al. Univariate and multivariate analysis of prognostic significance of betel quid chewing in squamous cell carcinoma of buccal mucosa in Taiwan. *J Surg Oncol* 2005 Jul 1; 91(1):41–47.

174. Ghoshal S, Mallick I, Panda N, Sharma SC. Carcinoma of the buccal mucosa: analysis of clinical presentation, outcome and prognostic factors. *Oral Oncol*. 2006 May;42(5): 533-9.
175. Garavello W, Spreafico R, Gaini RM: Oral tongue cancer in young patients: a matched analysis. *Oral Oncol*2007, 43(9):894-7.
176. Warnakulasuriya S, Mak V, Möller H: Oral cancer survival in young people in South East England. *Oral Oncol* 2007, 43(10):982-6.
177. Surveillance epidemiology and end results (SEER): SEER Cancer statistics review 1975-2004. [<http://seer.cancer.gov/statfacts/html/oralcav>]. National Cancer Institute
178. Ahmed SQ, Junaid M, Awan S, Choudhary MM, Kazi M, Masoom A et al. relationship of tumour thickness with neck node metastasis in buccal squamous cell carcinoma: An experience at a tertiary care hospital. *Int Arch Otorhinolaryngol*. 2017 Jul;21(3): 265-9.
179. Soni S, Soni TP, Patni N. Association between nodal metastasis and histopathological factors in postoperative gingivo-buccal complex squamous cell carcinoma: A retrospective study. *Gulf J Oncolog*. 2019 Jan;1(29):66-71.
180. Muttagi SS, Chaturvedi P, Gaikwad R, Singh B, Pawar P. Head and neck squamous cell carcinoma in chronic areca nut chewing Indian women: Case series and review of literature. *Indian J Med Paediatr Oncol* 2012 Jan;33(1):32-5.
181. Gupta S, Singh R, Gupta OP, Tripathi A. Prevalence of oral cancer and pre-cancerous lesions and the association with numerous risk factors in North India: A hospital-based study.

182. Weijers M, Snow GB, Bezemer PD, Wal JE van der, Waal I van der: The clinical relevance of epithelial dysplasia in the surgical margins of tongue and floor of mouth squamous cell carcinoma: an analysis of 37 patients. *J Oral Pathol Med* 2002, 31(1):11-5.
183. Narendra H, Tankshali RA. Prevalence and pattern of nodal metastasis in pT4 gingivobuccal cancers and its implications for treatment. *Indian J Cancer*. 2010 Jul-Sep;47(3):328-31.
184. Moeckelmann N, Ebrahimi A, Tou YK, Gupta R, Low TH, Ashford B. Prognostic implications of the 8th edition American Joint Committee on Cancer (AJCC) staging system in oral cavity squamous cell carcinoma. *Oral Oncol*. 2018 Oct;85:82-86.
185. Bankfalvi A, Piffko J. Prognostic and predictive factors in oral cancer: the role of invasive tumour front. *J. Oral Pathol Med*. 2000 Aug; 29(7):1-8
186. Bryne M, Koppang HS, Lilleng R, Kjaerheim A. Malignancy grading of deep invasive margins of oral squamous cell carcinoma has high prognostic value. *J Pathol*. 1992 Apr;166(4): 375-81.
187. Fagan JJ, Collins B, Barnes L, D'Amico F, Myers EN, Johnson JT (1998) Perineural invasion in squamous cell carcinoma of the head and neck. *Arch Otolaryngol Head Neck Surg* 124(6):637–640.
188. Rahima B, Shingaki S, Nagata M, Saito C Prognostic significance of perineural invasion in oral and oropharyngeal carcinoma. *Oral Surg Oral Med Oral Pathol Oral Radiol Endod* 2004 ;97(4):423–431.
189. Weijers M, Snow GB, Bezemer DP, van dr Wal JE, van der Waal I (2004) The status of the deep surgical margins in tongue and floor of mouth squamous cell

- carcinoma and risk of local recurrence; an analysis of 68 patients. *Int J Oral Maxillofac Surg* 33(2):146–149.
190. Essig H, Warraich R, Zulfiqar G, Rana M, Eckardt AM, Gellrich NC et al. Assessment of cervical lymph node metastasis for therapeutic decision-making in squamous cell carcinoma of buccal mucosa: a prospective clinical analysis. *World J Surg Oncol*. 2012 Nov 22; 10:253.
191. Schiff BA, Roberts DB, El-Naggar A, Garden AS, Myers JN. Selective vs modified radical neck dissection and postoperative radiotherapy vs observation in the treatment of squamous cell carcinoma of the oral tongue. *Arch Otolaryngol Head Neck Surg*. 2005 Oct;131(10):874-8.
192. Traynor SJ, Cohen JI, Gray J, Andersen PE, Everts EC. Selective neck dissection and the management of the node-positive neck. *Am J Surg*. 1996 Dec; 172(6):654-657.
193. Kowalski LP, Carvalho AL. Feasibility of supraomohyoid neck dissection in N1 and N2a oral cancer patients. *Head Neck*. 2002 Oct; 24(10):921-924.
194. Friedman M, Lim JW, Dickey W, Tanyeri H, Kirshenbaum GL, Phadke DM et al. Quantification of lymph nodes in selective neck dissection. *Laryngoscope*. 1999 Mar;109(3):368-70.
195. Theuer CP, Kurosaki T, Ziogas A, Butler J, Anton-Culver H. Asian patients with gastric carcinoma in the United States exhibit unique clinical features and superior overall and cancer specific survival rates. *Cancer* 2000 Nov (1); 89(9):1883
196. Hasegawa T, Yanamoto S, Otsuru M, Kakei Y, Okura M, Yamakawa N. Multicenter retrospective study of the prognosis and treatment outcomes of

- Japanese oral squamous cell carcinoma patients with level IV/ V metastasis. *Head Neck*. 2019 Jul;41(7):2256-63.
197. Hasegawa T, Shibuya Y, Takeda D, Iwata E, Saito I, Kakei Y et al. Prognosis of oral squamous cell carcinoma patients with level IV/V metastasis: An observational study. *Craniofacial Surg*. 2017 Jan;45(1): 145-9.
198. Luscieti, P., Hubschmid, T., Cottier, H., Hess, M. W. and Sobin, L. K. Human lymph node morphology as a function of age and site. *Journal of Clinical Pathology* 1980 May 33(5), 454.
199. Henick DH, Silver CE, Heller KS, Shaha AR, El GH, Wolk DP. Supraomohyoid neck dissection as a staging procedure for squamous cell carcinomas of the oral cavity and oropharynx. *Head Neck* 1995 Apr; 17(2):119-23.
200. Hashibe M, Sankaranarayanan R, Thomas G, Kuruvilla B, Mathew B, Somanathan T, *et al*. Body mass index, tobacco chewing, alcohol drinking and the risk of oral submucous fibrosis in Kerala, India. *Cancer CausesControl* 2002 Feb; 13(1):55-64.
201. Nieto A, Sanchez MJ, Martinez C, Castellsague X, Quintana MJ, Bosch X, *et al*. Lifetime body mass index and risk of oral cavity and oropharyngeal cancer by smoking and drinking habits. *Br J Cancer* 2003 Nov 3; 89(9):1667-71
202. Jaafar H. Intra-operative frozen section consultation: concepts, applications and limitations. *Malays J Med Sci*. 2006 Jan;13(1):4-12.
203. Kane SV, Gupta M, Kakade AC, D'Cruz AK. Depth of invasion is the most significant histological predictor of subclinical cervical lymph node metastasis in early squamous carcinomas of the oral cavity. *Eur J Surg Oncol*. Sep;32(7):795-803.

204. Chone CT, Crespo AN, Rezende AS. Neck lymph node metastases to the posterior triangle apex: evaluation of clinical and histopathological risk factors. *Head Neck*. 2000 Sep;22(6): 564–71.
205. Agrama MT, Reiter D, Topham AK, Kean WM. Node counts in neck dissection: are they useful in outcome research? *Otolaryngol Head Neck Surg* 2001 Apr; 124(4):433-5.
206. Norling R, Therkildsen MH, Bradley PJ, Nielsen MB, von Buchwald C. Nodal yield in selective neck dissection. *Acta Otolaryngol*. 2013 Sep;133(9):965-71.
207. Surveillance, Epidemiology, and End Results (SEER) Program public use CD-ROM (1973-96), National Cancer Institute, DCPC, Surveillance Program, Cancer Statistics Branch, April 1999.

## ANNEXURE – I - ETHICAL CLEARANCE



## KLE UNIVERSITY

(Formerly known as KLE Academy of Higher Education & Research, Belgaum)  
 [Declared as Deemed-to-be-University u/s 3 of the UGC Act, 1956 vide Government of India Notification No.F.9-19/2000-U.3(A)]

'Accredited 'A' Grade by NAAC

Office of the Registrar, KLE University,

JNMC Campus, Nehru Nagar, Belgaum-590 010, Karnataka State, India

☎: 0831-2444444/2493779 FAX: 0831-2493777 Web: <http://www.kleuniversity.edu.in> E-mail: [info@kleuniversity.edu.in](mailto:info@kleuniversity.edu.in)

Ref.No.KLEU/Ethic/14-15/ D-74

26<sup>th</sup> May 2014

To,  
 Dr. Sidramesh Muttagi  
 Ph.D.Scholar,2012-13  
 K.L.E. University,  
 Belgaum.

Dear Research Scholar

The KLE University Ethics Committee on Human Subjects for Ph. D Research Project met on 29<sup>th</sup> April 2014 to consider your application for approval of the research project "PATTERN OF LYMPH NODE METASTASIS AND ITS ASSOCIATION WITH CLINICO-PATHOLOGICAL VARIABLES IN SQUAMOUS CELL CARCINOMA OF MANDIBULAR GINGIVO-BUCCAL SULCUS"

As there are no ethical issues involved in your proposed research project, the committee has provided approval for this research project.

You are requested to report to Ethical Committee of the following:

1. Any deviation from or change of the protocol.
2. Any changes in study documents.

(Dr. Hema Dhumale)  
 Member Secretary,  
 Ph.D. Ethical Committee(Human),  
 K.L.E. University, Belgaum



(Dr. Sudha A. Raddi)  
 Chairman  
 Ph.D. Ethical Committee(Human),  
 K.L.E. University, Belgaum

CC to: - The Director Academic Affairs, KLE University  
 - The Director Research Foundation, KLE University  
 - The Registrar, KLE University  
 - Special Officer to Hon. Vice Chancellor, KLE University, Belgaum

## ANNEXURE –II – PUBLICATIONS

[Downloaded free from <http://www.indianjancancer.com> on Saturday, October 27, 2018, IP: 106.193.111.118]Original  
ArticleClinico-pathological factors affecting lymph node yield  
in Indian patients with locally advanced squamous cell  
carcinoma of mandibular Gingivo-Buccal sulcusMuttagi SS<sup>1,2</sup>, Patil BR<sup>3</sup>, Godhi AS<sup>4</sup>, Arora DK<sup>1</sup>, Hallikerimath SR<sup>5</sup>, Kale AD<sup>5</sup>Departments of <sup>1</sup>Oral and Maxillofacial Surgery and <sup>2</sup>Pathology, KLE VK Institute of Dental Sciences, KLE University, <sup>3</sup>Department of Surgery, Jawaharlal Nehru Medical College, KLE University, Belgaum, <sup>4</sup>Department of Surgical Oncology (Head and Neck), <sup>5</sup>Department of Surgical Oncology, Kamataka Cancer Therapy and Research Institute, Hubli, Karnataka, India  
Correspondence to: Dr. Muttagi SS, E-mail: [siddu7376@gmail.com](mailto:siddu7376@gmail.com)

## Abstract

**AIM:** Lymph node yield (LNY) is a valid marker of prognosis in oral cancer. Precise estimation of LNY in Indian patients with T3/T4 gingivobuccal sulcus squamous cell carcinoma (GBS-SCC) has not been well documented. Hence, the primary objective of the study was to determine the LNY in patients with T3/T4 SCC of mandibular GBS, and the secondary objective was to study the association of LNY with clinicopathological factors such as tumor thickness, histological differentiation, number of positive nodes, and extracapsular spread (ECS). **MATERIALS AND METHODS:** Study patients comprised biopsy proven T3/T4 SCC of mandibular GBS that underwent unilateral surgery (composite or bite composite resection with level I to level V-neck dissection and pectoralis major flap reconstruction) at our center between January 2012 and October 2014. Grossing of surgical specimens was done as per the guidelines established by the Royal College of Pathologists (December 2009). The data were analyzed using SPSS software (22<sup>nd</sup> version) and Chi-square test. **RESULTS:** The surgical specimens of 106 patients yielded 2329 lymph nodes with the mean LNY of  $21.97 \pm 5.57$ . Higher mean LNY of over 21 was significantly associated with ECS, number of positive nodes, delay in surgery over 15 days, skin involvement by the tumor, and presence of oral potentially malignant disorders. **CONCLUSION:** With the single surgeon, pathologist and same surgical procedure, the mean LNY in Indian patients with T3/T4 SCC of mandibular GBS is  $21.97 \pm 5.57$ . Although clinicopathological factors affect the estimation of LNY, further studies are needed to validate the findings of this study.

**Key Words:** Factors, gingivobuccal sulcus, lymph node yield, squamous cell carcinoma

## Introduction

Gingivobuccal sulcus (GBS) is a major subsite for oral squamous cell carcinoma (SCC) in the Indian subcontinent, and these tumors are known to recur locoregionally the following treatment.<sup>[1,2]</sup> Accurate pathological staging is a critical factor in determining the prognosis in these patients. Like SCC of any other oral subsite, lymph node metastasis is a single most important independent prognostic factor in patients with GBS-SCC.<sup>[2]</sup> Apart from tumor node metastasis (TNM) staging, recent studies have shown the importance of other lymph node associated factors such as the exact number of positive nodes, total number of harvested nodes in the neck dissection, and the presence of extracapsular spread (ECS) as determinants of prognosis in oral SCC.<sup>[3]</sup>

Lymph node ratio (LNR) has emerged not only as a marker of prognosis<sup>[4,5]</sup> but as a reliable tool in determining the extent of cancer spread, extent of clearance, and the need for adjuvant therapy following surgery for cancers of the stomach, esophagus, bladder, and colorectum, in addition to head and neck cancer.<sup>[5-10]</sup> The LNR has been successfully validated as a strong predictor of survival in oral cancer.<sup>[4]</sup> However, accurate estimation of LNR depends on the lymph node yield (LNY) which has been shown to vary depending on anatomical, surgical, and pathological factors.<sup>[4,5,11]</sup>

Although previous studies have thoroughly evaluated the efficacy of LNR and LNY as prognostic markers in oral SCC, there is a lack of uniformity in these studies with regard to

specific oral subsite of SCC, TNM stage-specific distribution of cases, neck dissection procedure, and standardization of harvesting lymph nodes from the neck dissection specimens.<sup>[4,5,11,12]</sup> To date, there is a lack of specific data regarding LNY and LNR in advanced GBS-SCC.

Locally advanced GBS-SCC is the most common malignancy at our center and bite composite resection with comprehensive neck dissection, and pectoralis major myocutaneous flap reconstruction has remained as a surgical procedure of choice for this type of cancer due to the workload, nonavailability of microvascular expertise, and socioeconomic reasons. Thus, removal of sternocleidomastoid muscle to facilitate inset of pectoralis major myocutaneous flap and clearance of level I to level V cervical lymph nodes is commonly done at our center for most of the node-positive necks. This enables us to assess the LNY in locally advanced GBS-SCC. The primary objective of this prospective study was to determine the LNY in T3/T4 GBS-SCC. The secondary objectives were to study the association of LNY with age, tumor thickness, histological differentiation, number of positive nodes, and ECS.

## Materials and Methods

The ethical clearance was obtained, and the patients with biopsy proven, T<sub>3</sub>/T<sub>4</sub> SCC that have classical extension into the mandibular GBS as defined by the previous studies<sup>[1,2]</sup> were included. These patients were operated at our center between January 2012 and October 2014 and had undergone *en bloc*

This is an open access article distributed under the terms of the Creative Commons Attribution-NonCommercial-ShareAlike 3.0 License, which allows others to remix, tweak, and build upon the work non-commercially, as long as the author is credited and the new creations are licensed under the identical terms.

For reprints contact: [reprints@medknow.com](mailto:reprints@medknow.com)

**How to cite this article:** Muttagi SS, Patil BR, Godhi AS, Arora DK, Hallikerimath SR, Kale AD. Clinico-pathological factors affecting lymph node yield in Indian patients with locally advanced squamous cell carcinoma of mandibular Gingivo-Buccal sulcus. Indian J Cancer 2016;53:239-43.

## Access this article online

Quick Response Code:	Website: <a href="http://www.indianjancancer.com">www.indianjancancer.com</a>
	DOI: 10.4103/0019-509X.197724

composite or bite composite resection, modified comprehensive neck dissection with clearance of level V to level I neck nodes as per the decision of tumor board. The modifications in neck dissection included preservation of the internal jugular vein and/or spinal accessory nerve whenever it was oncologically safe. The patients with recurrence, previous therapy, tuberculosis or chronic inflammatory diseases of head and neck and those with non-SCC were excluded from the study.

The clinical details included were demographic characteristics, clinical extent of the tumor, cTNM (AJCC 2009), findings in the high-resolution contrast computed tomography scan, and comorbidities. The pathological details obtained were pT<sub>3</sub> or pT<sub>4</sub> status, histological differentiation, gross tumor thickness, skin infiltration by the tumor, total number of lymph nodes harvested per specimen, and number of positive nodes and nodes with ECS.

The surgical specimens were oriented by the operating surgeon, and nodal levels were identified as defined by their anatomical extent. Following dissection of each nodal level, suture ligatures bearing labels marked with nonwashable ink were tied around each dissected group of lymph nodes to demarcate the individual levels. After completion of *en bloc* dissection, the specimens were washed in flowing water to remove blood clots and loose tissues. The individual levels were transected, and the lymph nodes from each level were harvested by a senior pathologist. These nodes were transferred to separate labeled bottles denoting individual nodal level, completely immersed in 10% of buffered formalin solution.

The grossing of the specimens was performed as per the modified standard protocol established by the Royal College of Pathologists, Standards and Datasets for reporting head and neck cancers (December 2009).<sup>[1,3]</sup> The specimens were sectioned after 48 h of fixation, and all the lymph nodes in the specimens were processed. The lymph nodes >2 mm in size were sectioned along the long axis and those with <2 mm in size, transverse sections were made. Four µm sections of all the lesional and lymph node sections were stained by routine cosin and Hematoxylin and Eosin staining.

#### Methods of statistical analysis

The data were entered in Microsoft Excel sheet and analyzed using IBM SPSS software (22<sup>nd</sup> version, IBM Corp., 2013, Armonk, New York, USA). The difference in LNY in different groups of clinicopathological variables was analyzed using Chi-square test. The  $P \leq 0.05$  was considered statistically significant.

#### Results

The patient and surgical variables studied are mentioned in Table 1. This study included 106 subjects with T<sub>3</sub> and T<sub>4</sub> SCC of mandibular GBS. The mean age of the patients was 51.95 ± 11.72 years and ranged between 22 and 90 years. Overall, 76.41% of the patients were males and 23.58% were females. There were 64.15% (68 patients) in T<sub>4a</sub> stage and 35.84% (38 patients) in T<sub>3</sub> stage, with 54.71% (58 patients) showing skin involvement. The mean tumor size was 4.1 cm × 3.6 cm (14.8 cm<sup>2</sup>). Overall, 2329 lymph nodes were harvested from 106 patients that underwent unilateral neck dissections, and the mean LNY

**Table 1: Patient and surgical variables**

Variables	All patients n=106, (%)
Age (years)	
Range	22-90
Mean	51.95
Males	81 (76.41)
Females	25 (23.58)
Duration* (days)	
<15	51 (48.11)
>15	55 (50.14)
Side of disease	
Right	59 (55.66)
Left	47 (44.33)
Premalignant disorders	
Absent	32 (30.18)
Oral submucous fibrosis	50 (47.16)
Leukoplakia	16 (15.09)
Erythroplakia	8 (7.54)
Neck dissection type	
Modified neck dissection**	87 (82.07)
Radical neck dissection	19 (17.92)
Total positive nodes	306
SD	29.8
Mean	2.89
LNY	
Mean	21.94
SD	5.57
Total	2329
LNR	0.0-0.43
Mean	0.12
SD	0.122

\*Time between the patient's first visit to the hospital and surgery;

\*\*Preservation of spinal accessory nerve and/or internal jugular vein.

LNY=Lymph node yield; LNR=Lymph node ratio; SD=Standard deviation

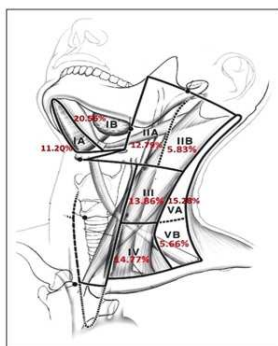
was 21.97 ± 5.57. The percentage distribution of LNY at various nodal levels in the neck is shown in Figure 1.

The pathological variables are shown in Table 2. The mean tumor thickness was 1.2 cm and in 36.79% of the patients, the tumor thickness ranged from 0.4 to 0.9 cm whereas in 63.20% of patients, the tumor thickness was over 1 cm. ECS of the tumor in the lymph nodes was seen in 41.50% of patients.

In 71.7% of patients, only level I nodes were positive; in 37.74% of patients, level I and level II nodes were positive; in 29.25% of patients, level I, level II, and level III were positive; in 16.98% of patients, all the nodal levels from level I to level IV were positive; whereas, in 9.43% of patients, all the nodal levels from level I to level V were positive.

Overall in 106 patients, the total number of patients with pN+ status was 70.75% (75 patients) whereas the number of patients with pN0 status were 29.25% (31 patients). The mean LNR was 0.12.

When Chi-square test was used to see the association of clinicopathological variables and LNY, ECS, number of positive nodes, delay in surgical treatment for more than



**Figure 1:** Percentage distribution of lymph nodes in the neck in 106 patients with T3/T4 squamous cell carcinoma of the mandibular gingivobuccal sulcus. Image modified with permission from Som PM, Curtin HD, Mancuso AA. An imaging-based classification for the cervical nodes designed as an adjunct to recent clinically based nodal classifications. *Arch Otolaryngol Head Neck Surg.* 1999 Apr; 125(4):388-96

**Table 2: Pathological variables and their association with lymph node yield**

Variables	All patients n=106 (%)	Mean LNY	SD
Differentiation			
Well	52 (49.05)	21.33	5.88
Moderate	47 (44.33)	22.85	5.38
Poor	7 (6.60)	20.86	3.89
Tumor thickness (cm)			
0.4-0.9	39 (36.79)	21.84	5.52
1.0-1.9	48 (45.28)	22.04	5.64
>2.0	19 (17.92)	20.07	5.48
Pathological T stage (S)			
pT3 cases	38 (35.84)	20.63*	4.75
pT4 cases	68 (64.15)	22.72*	5.88
Skin involvement (S)			
Present	58 (54.71)	24.14**	5.75
Absent	48 (45.28)	19.35**	4.05
Extracapsular spread (S)			
Present	44 (41.50)	23.68**	5.03
Absent	62 (58.49)	20.76**	5.65
Number of positive nodes (S)			
None, pN0	31 (29.24)	18.45***	4.38
1-4	48 (45.28)	23.02***	6.00
>5	27 (25.47)	21.97***	5.57
Delay in treatment (S)			
1-15	51 (48.11)	18.94***	3.76
16-30	55 (51.88)	24.78***	5.52
OPMD* (S)			
Absent (n=32)	32 (30.18)	17.44***	2.74
OSF* (n=50)	50 (47.16)	25.56***	5.05
Leukoplakia (n=16)	16 (15.09)	18.56	3.42
Leuko erythroplakia (n=8)	8 (7.54)	24.50	2.97

\*P<0.05; \*\*P<0.01; \*\*\*P<0.001. OPMD=Oral potentially malignant disorders; OSF=Oral submucous fibrosis; S=Significant; SD=Standard deviation; LNY=Lymph node yield

15 days after diagnosis, skin involvement by the tumor, and presence of oral potentially malignant disorder (OPMD) were significant factors that contributed to higher LNY [Tables 1 and 2].

Indian Journal of Cancer | April-June 2016 | Volume 53 | Issue 2

## Discussion

When the protocol for grossing the specimen proposed by the Royal College of Pathologists<sup>[23]</sup> was followed, the mean LNY in our patients was 21.94 (range 10-42). Whereas, as per the Royal College of Pathologists,<sup>[23]</sup> in the absence of previous chemotherapy, radiotherapy or neck dissection, and radical neck dissection yields 20 lymph nodes (range 10-30) on an average. The range of lymph nodes retrieved in our study was comparable to that proposed by the Royal College of Pathologists<sup>[23]</sup> although the surgical procedure in our study, in the majority of cases, was modified neck dissection.

The role of pathologists, surgeons, pathology technicians, method of handling the surgical specimen and the extent of training of these specialists have shown to influence the harvest of lymph nodes from the surgical specimens, thereby affecting the overall LNY.<sup>[14-16]</sup> The surgical technique is yet another factor contributing to the variability of LNY.<sup>[11,12]</sup> Thus, a wide variation exists in the reports on the LNY and LNR in the current literature. However, in our study, the lymph node dissection and their retrieval from surgical specimens were done by the most experienced single surgeon and single pathologist, to prevent the bias in most of the studies. Despite specific consensus-based definitions of various neck dissection procedures in the current literature,<sup>[17]</sup> there is still a possibility of variation in the neck dissection fields by the surgeons, depending on the individual judgment, expertise, and decision-making. Comparing the LNYs obtained by a uniform, standard neck dissection procedure among different centers can help in determining the factors responsible for varied reports.

Nevertheless, on multivariate analysis, a significant variation in the rate of lymph node metastasis among Asian and non-Asian gastric carcinoma patients was found in a study;<sup>[23]</sup> the literature is sparse with regard to the contribution of racial and ethnic factors in the variability of cervical lymph node metastasis in head and neck cancer. Furthermore, data on the reference range of cervical lymph nodes, based on cadaveric studies, are derived from the non-Asian population,<sup>[21]</sup> and to date, the literature is sparse with regard to the reference range of cervical lymph node counts in Indian population. When compared to the available western data on the cervical lymph node counts,<sup>[11,15]</sup> we had slightly lower counts which could be attributed to racial factors and possibly low body mass index (BMI) in our patients, in view of their high alcohol consumption, smoking, and tobacco chewing habits. The previous studies have reported low BMI in oral cancers patients, which were associated with alcohol consumption and tobacco use.<sup>[19,20]</sup>

The number of locally advanced GBS-SCC patients with pN0 status in our study was 29.2% which was lower than that reported by Walvekar *et al.*<sup>[11]</sup> However, the mean LNY increased significantly with the increase in the number of positive nodes. The immunological response that has been shown by the previous studies<sup>[21]</sup> could have contributed to the overall increase in the LNY. The ECS of tumor in the lymph nodes was associated with increase in the LNY. Although the contribution of ECS in increasing the LNY in head and neck cancer has not been clearly elucidated, the association of ECS with increase in the number of positive

nodes has been shown in patients with breast cancer following axillary clearance, especially in large-sized tumors.<sup>[22]</sup> The presence of ECS in a lymph node can channelize the passage of tumor cells into surrounding lymphatic vessels, thereby increasing the number of positive nodes and overall LNY.

The delay in surgical treatment over 16 days to 30 days after the diagnosis of oral SCC was associated with an increase in the mean LNY compared to the patients that were treated within 15 days of diagnosis. The possibility of disease progression during the waiting period can be considered as a leading cause of metastatic lymphadenopathy, although it was not confirmed in this study by a second imaging to document a definitive disease progression during waiting period before surgery, as reported by Waaijer *et al.*<sup>[23]</sup>

The age, sex, and tumor differentiation were not significantly associated with increase in the mean LNY as the distribution of patients with respect to these factors was not uniform. In addition to this, the lack of larger sample size was a drawback of this study. We did not include the BMI as a parameter that can contribute to the variability of LNY. The mean LNY was slightly higher in patients with tumor thickness >1 cm, the differences were not statistically significant, and the mean LNY remained above 20 in both cases. However, the involvement of skin by the infiltration of tumor and patients with locally advanced SCC of lower GBS presenting with orocutaneous fistula showed a higher LNY. Apart from the locally advanced primary tumor, the inflammatory response resulting from secondary infections in a chronic nonhealing oral ulcer could have triggered the increased LNY. Furthermore, the role of inflammatory response has been shown by studies as key feature in the pathogenesis of oral submucous fibrosis (OSF) that was seen in a majority of our patients presenting with SCC of mandibular GBS.<sup>[24]</sup> This condition is often associated with trismus, poor oral hygiene, and multiple ulcerations in the oral mucosa. The mean LNY in these patients was significantly higher than the patients with SCC of mandibular GBS presenting without a clinical evidence of OPMD. Thus, the role of inflammatory response in oral tissues secondary to OSF and its associated conditions leading to increased mean LNY cannot be ruled out.

### Conclusion

In patients with locally advanced SCC of mandibular GBS, the mean LNY was 21.94. The presence of ECS, positive nodes for metastasis of SCC, delay in treatment of more than 15 days following diagnosis of SCC, skin infiltration by the tumor or presence of orocutaneous fistula and association of OPMD, especially OSF were significant factors that contributed to higher LNY. Further studies with larger sample size, incorporating multivariate statistical analysis, are required to validate the findings of this study.

### Acknowledgments

We would like to thank Dr. Naresh Kumar Tyagi, Department of Biostatistics, Jawaharlal Nehru Medical College, Belgaum, Karnataka, India for providing us with valuable guidelines in arranging the data and helping us with the statistical analysis.

### Financial support and sponsorship

Nil.

### Conflicts of interest

There are no conflicts of interest.

### References

- Walvekar RR, Chaukar DA, Deshpande MS, Pai PS, Chaturvedi P, Kakade A, *et al.* Squamous cell carcinoma of the gingivobuccal complex: Predictors of locoregional failure in stage III-IV cancers. *Oral Oncol* 2009;45:135-40.
- Pathak KA, Gupta S, Talole S, Khanna V, Chaturvedi P, Deshpande MS, *et al.* Advanced squamous cell carcinoma of lower gingivobuccal complex: Patterns of spread and failure. *Head Neck* 2005;27:597-602.
- Ebrahimi A, Zhang WJ, Gao K, Clark JR. Nodal yield and survival in oral squamous cancer: Defining the standard of care. *Cancer* 2011;117:2917-25.
- Patel SG, Amit M, Yen TC, Liao CT, Chaturvedi P, Agarwal JP, *et al.* Lymph node density in oral cavity cancer: Results of the International Consortium for Outcomes Research. *Br J Cancer* 2013;109:2087-95.
- Marres CC, de Ridder M, Hegger I, van Velthuysen ML, Hauptmann M, Navran A, *et al.* The influence of nodal yield in neck dissections on lymph node ratio in head and neck cancer. *Oral Oncol* 2014;50:59-64.
- Medina-Franco H, Cabrera-Mendoza F, Almaguer-Rosales S, Guillén F, Suárez-Bobadilla YL, Sánchez-Ramón A. Lymph node ratio as a predictor of survival in gastric carcinoma. *Am Surg* 2013;79:284-9.
- Hsu TW, Lu HJ, Wei CK, Yin WY, Chang CM, Chiou WY, *et al.* Clinical and pathologic factors affecting lymph node yields in colorectal cancer. *PLoS One* 2013;8:e68526.
- Kassouf W, Agarwal PK, Herr HW, Munsell MF, Spiess PE, Brown GA, *et al.* Lymph node density is superior to TNM nodal status in predicting disease-specific survival after radical cystectomy for bladder cancer: Analysis of pooled data from MDACC and MSKCC. *J Clin Oncol* 2008;26:121-6.
- Ooki A, Yamashita K, Kobayashi N, Katada N, Sakuramoto S, Kikuchi S, *et al.* Lymph node metastasis density and growth pattern as independent prognostic factors in advanced esophageal squamous cell carcinoma. *World J Surg* 2007;31:2184-91.
- Vas Nunes JH, Clark JR, Gao K, Chua E, Campbell P, Niles N, *et al.* Prognostic implications of lymph node yield and lymph node ratio in papillary thyroid carcinoma. *Thyroid* 2013;23:811-6.
- Friedman M, Lim JW, Dickey W, Tanyeri H, Kirshenbaum GL, Phadke DM, *et al.* Quantification of lymph nodes in selective neck dissection. *Laryngoscope* 1999;109:368-70.
- Norling R, Therkildsen MH, Bradley PJ, Nielsen MB, von Buchwald C. Nodal yield in selective neck dissection. *Acta Otolaryngol* 2013;133:965-71.
- Helliwell T, Woolgar J. Dataset for Histopathology Reporting of Nodal Excisions and Neck Dissection Specimens Associated with Head and Neck Carcinomas. 7<sup>th</sup> December, 2011. Available from: <http://www.rcpath.org>. [Last accessed on 2016 Jan 16].
- Kerawala CJ, Bisase B, Hopper A. Is total nodal yield in neck dissections influenced by the method of specimen presentation to the pathologist? *Br J Oral Maxillofac Surg* 2009;47:360-2.
- Henick DH, Silver CE, Heller KS, Shaha AR, El GH, Wolk DP. Supraomohyoid neck dissection as a staging procedure for squamous cell carcinomas of the oral cavity and oropharynx. *Head Neck* 1995;17:119-23.
- Storli K, Lindboe CF, Kristoffersen C, Kleiven K, Søndena K. Lymph node harvest in colon cancer specimens depends on tumour factors, patients and doctors, but foremost on specimen handling. *APMIS* 2011;119:127-34.
- Robbins KT, Shaha AR, Medina JE, Califano JA, Wolf GT, Ferlito A, *et al.* Consensus statement on the classification and terminology of neck dissection. *Arch Otolaryngol Head Neck Surg* 2008;134:536-8.
- Theuer CP, Kurosaki T, Ziogas A, Butler J, Anton-Culver H. Asian patients with gastric carcinoma in the United States exhibit unique clinical features and superior overall and cancer specific survival rates. *Cancer* 2000;89:1883-92.
- Hashibe M, Sankaranarayanan R, Thomas G, Kuruvilla B, Mathew B, Somanathan T, *et al.* Body mass index, tobacco chewing, alcohol drinking and the risk of oral submucous fibrosis in Kerala, India. *Cancer Causes Control* 2002;13:55-64.
- Nieto A, Sánchez MJ, Martínez C, Castellsagué X, Quintana MJ, Bosch X, *et al.* Lifetime body mass index and risk of oral cavity and oropharyngeal cancer by smoking and drinking habits. *Br J Cancer* 2003;89:1667-71.
- Nakamura K, Ninomiya I, Oyama K, Inokuchi M, Kinami S, Fushida S,

[Downloaded free from <http://www.indiancancer.com> on Saturday, October 27, 2018, IP: 106.193.111.118]  
Muttagi, *et al.*: Lymph node yield in T3/T4 gingivobuccal carcinoma

- et al.* Evaluation of immune response according to the metastatic status in the regional lymph nodes in patients with gastric carcinoma. *Oncol Rep* 2010;24:1433-41.
22. Gooch J, King TA, Eaton A, Dengel L, Stempel M, Corben AD, *et al.* The extent of extracapsular extension may influence the need for axillary lymph node dissection in patients with T1-T2 breast cancer. *Ann Surg Oncol* 2014;21:2897-903.
23. Waaijer A, Terhaard CH, Dehnad H, Hordijk GJ, van Leeuwen MS, Raaymakers CP, *et al.* Waiting times for radiotherapy: Consequences of volume increase for the TCP in oropharyngeal carcinoma. *Radiother Oncol* 2003;66:271-6.
24. Pillai R, Balaram P, Reddiar KS. Pathogenesis of oral submucous fibrosis. Relationship to risk factors associated with oral cancer. *Cancer* 1992;69:2011-20.
-

## Original Article

## Clinicopathological Predictors of Extent of Cervical Lymph Node Metastases in Locally Advanced Squamous Cell Carcinoma of Mandibular Gingivobuccal Sulcus

### Abstract

**Introduction:** Locally advanced mandibular gingivobuccal sulcus (GBS) squamous cell carcinoma (SCC) has variable extent of cervical lymph node metastasis. Tumor thickness reliably predicts cervical lymph node metastases in early oral SCC, its reliability in predicting the extent of neck-node positivity in locally advanced GBS SCC is poorly studied. **Objectives:** The objective of this study is to study the association of extent of neck-node metastases with gross tumor thickness (GTT), preoperative histological differentiation (HD), and presence of clinical skin infiltration (CSI) in locally advanced SCC of mandibular GBS. **Methodology:** Biopsy-proven patients with locally advanced SCC of mandibular GBS, underwent composite resection with neck dissection from Level V to Level I, from January 2012 to February 2016 were included in this study. The intraoperative GTT was measured, the HD of primary tumor and presence of CSI were noted. Specimens were grossed as per guidelines established by the Royal College of Pathologists. The data were analyzed using SPSS version 22, Chi-square test, and Spearman's Rank correlation test. **Results:** In 130 patients, with gross tumor thickness >1 cm in 64 (49%) and <1 cm in 66 (51%), a statistically significant association ( $P = 0.0001$ ) between the levels of neck-node positivity and HD, GTT, and presence of CSI was found. Preoperative HD showed a negative correlation whereas GTT and CSI showed a positive correlation with levels of positive node. **Conclusion:** Intraoperative GTT >1 cm, moderate-poor HD on biopsy, and presence of CSI were associated with extensive ipsilateral cervical lymph node metastases including Levels IV and V. These factors can help in predicting the extent of the neck dissection.

**Keywords:** Gingivobuccal, gross tumor thickness, histologic differentiation, intraoperative, locally advanced, neck-node metastasis, skin infiltration, squamous cell carcinoma

### Introduction

Mandibular gingivobuccal sulcus (GBS) is a common subsite of oral squamous cell carcinoma (SCC) in the Indian subcontinent, owing to high prevalence of tobacco and areca nut chewing habit.<sup>[1]</sup> Early GBS-SCC is often asymptomatic and remains unnoticed by the patients. Most of the patients, therefore, present to a clinician in locally advanced stage.<sup>[2]</sup> Locally advanced mandibular GBS SCC are often associated with bone and soft-tissue destruction of the maxillofacial region, cervical lymph node metastasis, and distant metastasis.<sup>[1,2]</sup> This disease requires aggressive surgical management regarding extensive resection and reconstruction of the defects followed by adjuvant therapy for adequate locoregional control.

As applicable to any other oral subsite of SCC, lymph node metastases is the single most important independent prognostic factor in this disease.<sup>[2,3]</sup> The current evidence suggests that tumor thickness is a predominant factor in determining lymph node metastases and a tumor thickness of 4 mm in early oral cancer was strongly associated cervical lymph node metastases.<sup>[4]</sup> Most of the current literature highlights the importance of tumor thickness and need for neck dissection in early oral cancer.<sup>[5,6]</sup> However, the literature is sparse about the extent of cervical lymph node metastases in locally advanced oral cancer.<sup>[7]</sup>

This study was aimed to determine the extent of cervical lymph node metastases in locally advanced GBS-SCC and to study its association with clinicopathological

This is an open access journal, and articles are distributed under the terms of the Creative Commons Attribution-NonCommercial-ShareAlike 4.0 license, which allows others to remix, tweak, and build upon the work non-commercially, as long as appropriate credit is given and the new creations are licensed under the identical terms.

For reprints contact: [reprints@medknow.com](mailto:reprints@medknow.com)

**How to cite this article:** Muttagi SS, Godhi AS, Patil BR, Javali SB, Kale AD. Clinicopathological predictors of extent of cervical lymph node metastases in locally advanced squamous cell carcinoma of mandibular gingivobuccal sulcus. *J Sci Soc* 2018;45:53-6.

**Sidramesh Shivanand Muttagi, Ashok S Godhi<sup>1</sup>, Basavaraj R Patil<sup>2</sup>, Shilvingappa B Javali<sup>3</sup>, Alka D Kale<sup>4</sup>**

*Departments of Oral and Maxillofacial Surgery and <sup>4</sup>Maxillofacial Pathology, KLE VK Institute of Dental Sciences, <sup>1</sup>Department of General Surgery, Jawaharlal Nehru Medical College, <sup>3</sup>Department of Biostatistics, University SAINS Malaysia, Belagavi, <sup>2</sup>Department of Surgical Oncology, Karnataka Cancer Therapy and Research Institute, Hubballi, Karnataka, India*

**Address for correspondence:**  
Dr. Sidramesh Shivanand Muttagi,  
Staff Qtrs No. A-14/11  
JNMC Campus, Nehrunagar,  
Belagavi, Karnataka, India.  
E-mail: [siddu7376@gmail.com](mailto:siddu7376@gmail.com)

### Access this article online

Website: [www.jscisociety.com](http://www.jscisociety.com)

DOI: 10.4103/jss.JSS\_37\_18

### Quick Response Code:



[Downloaded free from <http://www.jscisociety.com> on Monday, December 10, 2018, IP: 106.193.104.6]

Muttagi, et al.: Extent of cervical lymph node metastasis in advanced buccal mucosa cancer

factors such as demographic characteristics, intraoperative gross tumor thickness (GTT), and histological differentiation (HD) on preoperative biopsy and clinical skin infiltration (CSI).

### Methodology

The data of 161 patients operated for biopsy-proven SCC of buccal mucosa from January 2012 to February 2016, at our centers, were analyzed. Of these patients, 130 presented with locally advanced SCC (T3/T4 tumors) as per AJCC 2009 staging guidelines,<sup>[8]</sup> with classical extension into mandibular GBS as described by the previous studies<sup>[1]</sup> were included in this study. These patients underwent composite or bite composite resection with comprehensive *en bloc* neck dissection and clearance of Level V to Level I neck nodes on the side of the disease. The grossing of specimens was performed as per the modified standard protocol established by the Royal College of Pathologists, Standards and Datasets for reporting head and neck cancers (December 2009).<sup>[9]</sup> The lymph nodes of each level were separated by the operating surgeon after dissecting the fibro-fatty tissue from the anatomical extent described for each level. The harvested lymph nodes from each level were transferred to labeled bottles containing 10% buffered formalin. The primary tumor was sectioned longitudinally after complete resection, and GTT was measured intraoperatively using calipers and metric scale as per the guidelines described by Huang *et al.*,<sup>[10]</sup> as shown in Figures 1 and 2. The lymph node specimens were sectioned after 48 h of formalin fixation and all the lymph nodes obtained during neck dissection were processed. The lymph nodes >2 mm in size were sectioned along the long axis, and those <2 mm were sectioned transversely. Four  $\mu$ m sections of the lesion and all the lymph nodes were stained by routine eosin and hematoxylin. The patient's demographic details, HD, intraoperative GTT, and CSI during grossing of the specimen were noted.

### Statistical analysis

The data were entered in the Microsoft Excel sheet, and statistical analysis was done using IBM SPSS software

version 22 (IBM Corp. 2013, Armonk, New York, USA). Chi-square test was used to study the association between level of positive nodes and age, gender, side of lesion, HD, tumor thickness, and skin infiltration.  $P < 0.05$  was considered statistically significant. Correlation between all the variables with levels of the positive node was assessed using Spearman's Rank correlation test.

### Results

Clinicopathological characteristics of the patients in the study group are presented in Table 1. Among 130 patients, five patients were negative for ipsilateral neck node metastasis, on final histopathological examination. There was a statistically significant association between levels of neck-node positivity and HD of tumor on biopsy. There was

**Table 1: Clinico-pathological characteristics of the patients in the study group**

Patient and Tumour Characteristics	Total Patients 130
Age, Average	51 (22-78)
Sex	
Male	103 (79%)
Female	27 (21%)
Side	
Right	68 (52%)
Left	62 (48%)
Clinical T classification (AJCC 2009)	
T3	56 (43%)
T4	74 (57%)
Tumour Type;	
Ulceroproiferative	79 (60%)
Ulceroinfiltrative	51 (40%)
Histological Differentiation (HD)*	
Well to moderate	69 (53%)
Moderate to poor	61 (47%)
Gross tumour thickness (GTT)	
<1 cm	66 (51%)
>1 cm	64 (49%)
Clinical Skin Infiltration (CSI)	
Present	47 (36%)
Absent	83 (64%)

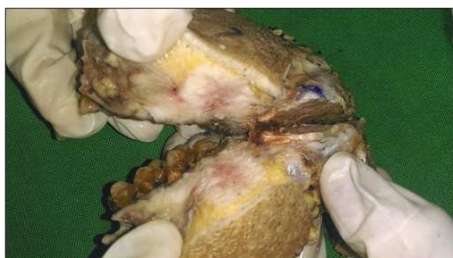

Figure 1: Longitudinal sectioning of the tumor

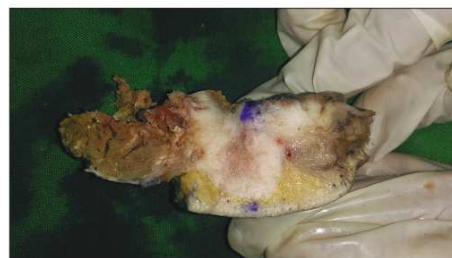

Figure 2: Gross tumor thickness was measured as vertical distance between marked points using blue ink

a higher possibility of metastasis to Levels IV and Level V (lymph nodes of the lower jugular and posterior triangle of the neck) in moderate to poorly differentiated SCC. The association between levels of positive node and GTT was statistically significant. The tumors with gross thickness over 1 cm had a higher rate of metastasis to Levels IV and Level V. CSI was found in 47 (36%) of our patients with GTT over 1 cm. Gross CSI was found to be significantly associated with levels of positive nodes at Level IV and V. When the correlation of levels of positive nodes and other clinicopathological factors was studied, there was a negative correlation with HD of tumors and positive correlation with GTT and CSI [Table 2]. This means that as the HD shifts from well to moderate or poor, the likelihood of metastasis to Level IV and Level V increased. The correlation results showed that GTT (>1 cm) and presence of CSI had higher likelihood to involve lymph nodes at Levels IV and V in the neck.

### Discussion

HD of tumor has been shown to be a reliable marker of prognosis in most of the malignant tumors.<sup>[11]</sup> However, the reliability of HD in predicting the extent of neck node involvement depends on the adequacy of size of the biopsy specimen, to include the deep invasive front of the tumor. The HD may vary at the invasive front from that at the superficial areas of the tumor. Previous studies have shown that HD in larger surgical specimens has given better prognostic indications than that examined in smaller diagnostic biopsy specimens.<sup>[12,13]</sup> In our own study, in 15 patients (11%), although the initial biopsy showed well differentiation, the final HD in resected specimens was found to be moderate to poor, possibly due to lack of invasive front in the biopsy specimens. We, therefore, recommend that in an event of well-differentiated tumor on biopsy, the inclusion of invasive front in the biopsy specimen should be confirmed with the pathologist examining the slide, to rely on HD as a predictor of extent of the neck nodal metastasis. If the HD at invasive front is unknown in case of a well-differentiated tumor on biopsy, the reliability of HD as a predictor of neck nodal metastasis is questionable. In this study, moderate-to-poor HD showed higher possibility of metastases to Level IV and Level V neck nodes as this represent a histologically aggressive tumor.

The previous TNM staging that was used in this study (AJCC 2009) lacked the inclusion of tumor thickness and HD in staging of head-and-neck cancers.<sup>[8]</sup> As the "T" staging of the tumor is only a two-dimensional measurement of the tumor, this has resulted in inclusion of thinner tumors with favorable prognosis in locally advanced category. In addition, due to lesser tumor thickness in five of our patients, the cervical nodes were found to be negative for metastasis.

With the increasing evidence regarding the impact of tumor thickness on cervical lymph node metastases and its inclusion in the recently modified TNM classification (AJCC 8<sup>th</sup> edition.), there is an improvement in the accuracy of disease staging and determination of prognosis.<sup>[14]</sup> Although most of the studies have shown that microscopic tumor thickness as an accurate predictor of lymph node metastasis, we considered GTT after resection of the tumor as an intraoperative measure to predict the extent of cervical lymph node metastases, even though it is less accurate compared to microscopic tumor thickness.<sup>[10]</sup> The measurement of GTT can be easily done with metric scale and calipers in the operating room without the need of pathologist and microscope. The results of our study were comparable with the current literature that uses microscopic tumor thickness in predicting the extent of cervical lymph node metastasis.

Although intraoperative frozen section can greatly help in determining both tumor thickness and cervical lymph node positivity intraoperatively, this facility and expertise may not be widely available, and therefore, reliability of clinical parameters of a tumor becomes important in deciding the extent of cervical node dissection, especially in a patient with locally advanced SCC. As shown by the current literature the tumor thickness >1 cm had higher chances to metastasize regionally which is in concurrence of our findings.<sup>[10]</sup>

Infiltration of the skin of cheek region by SCC of mandibular GBS is clinically detected by presence of induration, fixity of overlying skin and oro-cutaneous fistula. Forty-seven patients (36%) with GTT over 1 cm showed skin infiltration and had higher possibility of extensive neck node metastasis. Previous studies have shown that skin infiltration in oral cancer was associated

Table 2: Association of clinic-pathological factors with levels of positive node

Clinico-pathological factors	Association with levels of positive node (Chi-Square)	Correlation		
		Spearman R	t	P-level
Age	7.9, P=0.927	0.0305	0.3452	0.7305
Sex	1.65, P=0.894	-0.0124	-0.1403	0.8886
Side	3.80, P=0.577	0.0233	0.2634	0.7927
Histological Differentiation	29.13, P=0.0001 (S)*	-0.4646	-5.9353	0.0001
Tumour thickness	45.94, P=0.0001 (S)*	0.5910	8.2881	0.0001
Skin infiltration	33.021, P=0.0001 (S)*	0.5016	6.5605	0.0001

\*S: Statistically Significant

[Downloaded free from <http://www.jscisociety.com> on Monday, December 10, 2018, IP: 106.193.104.6]

Muttagi, *et al.*: Extent of cervical lymph node metastasis in advanced buccal mucosa cancer

with poor prognosis and higher possibility of locoregional recurrence.<sup>[13]</sup> Thicker tumors tend to infiltrate deeper into connective tissue and once they infiltrate skin there is a higher possibility of spread through subdermal lymphatic plexus into regional lymph nodes.<sup>[19]</sup> This might have contributed to extensive ipsilateral lymph node metastases at various nodal levels.

With an intent to study the reliability of HD on preoperative biopsy, intraoperative GTT and presence of CSI, in predicting the extent of cervical lymph node metastasis, we did complete Level I to Level V neck dissection in all the patients included in this study. With our findings, we recommend the completion of Level IV and Level V clearance on the ipsilateral side of the neck, if biopsy suggests moderate-to-poor HD, GTT over 1 cm, and presence of CSI.

### Conclusion

Moderate-to-poor HD on biopsy, intraoperative GTT of over 1 cm, and presence of CSI from GBS SCC are associated with higher rate of ipsilateral cervical lymph node metastasis to various levels of neck nodes, including Level IV and Level V. The clearance of these groups of lymph nodes during surgery is essential for comprehensive management of locally advanced GBS SCC. Further studies with larger sample size are needed to validate the findings of this study.

### Financial support and sponsorship

Nil.

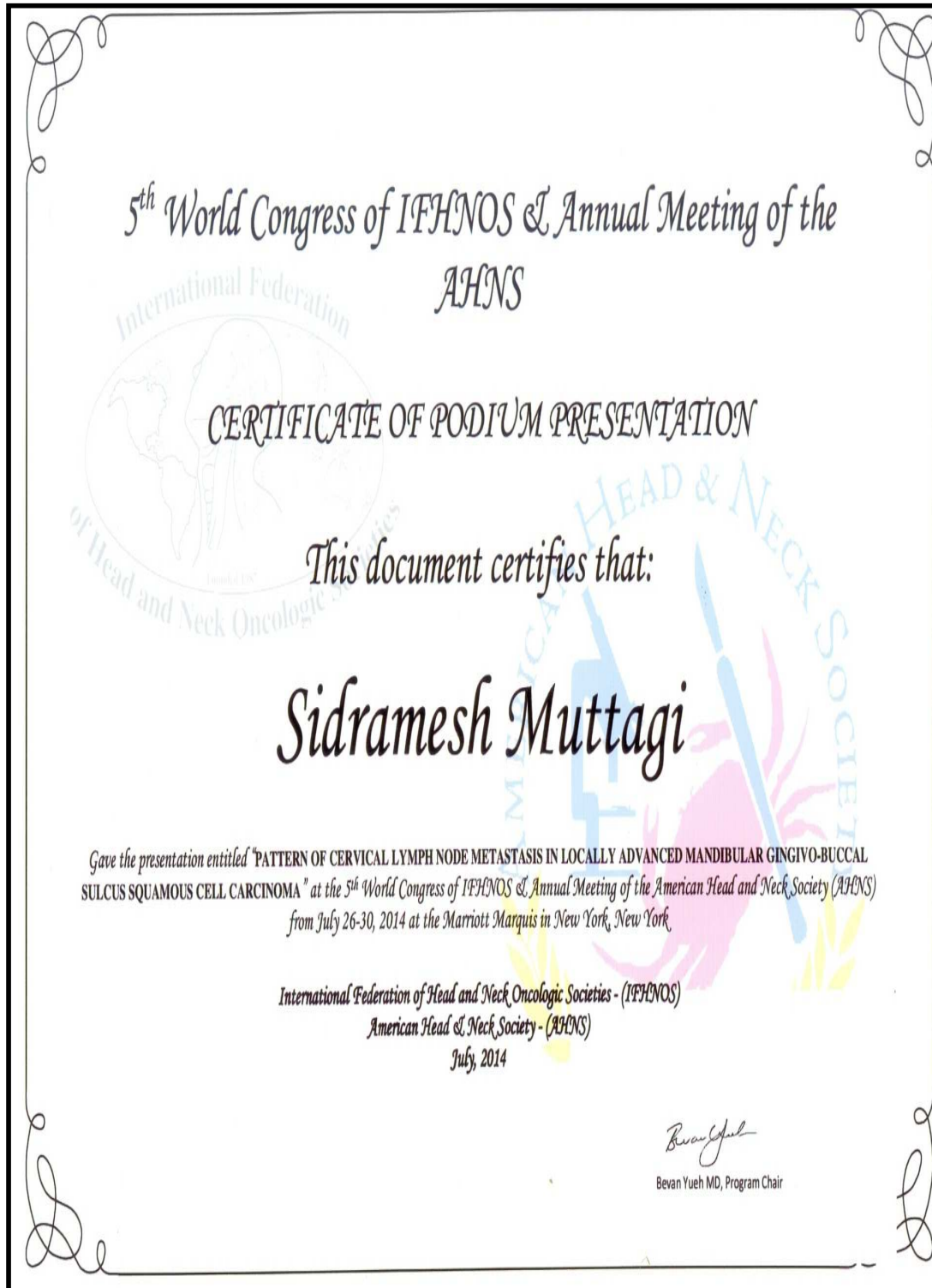
### Conflicts of interest

There are no conflicts of interest.

### References

- Walvekar RR, Chaukar DA, Deshpande MS, Pai PS, Chaturvedi P, Kakade A, *et al.* Squamous cell carcinoma of the gingivobuccal complex: Predictors of locoregional failure in stage III-IV cancers. *Oral Oncol* 2009;45:135-40.
- Pathak KA, Gupta S, Talole S, Khanna V, Chaturvedi P, Deshpande MS, *et al.* Advanced squamous cell carcinoma of lower gingivobuccal complex: Patterns of spread and failure. *Head Neck* 2005;27:597-602.
- Noguti J, De Moura CF, De Jesus GP, Da Silva VH, Hossaka TA, Oshima CT, *et al.* Metastasis from oral cancer: An overview. *Cancer Genomics Proteomics* 2012;9:329-35.
- Pentenero M, Gandolfo S, Carozzo M. Importance of tumor thickness and depth of invasion in nodal involvement and prognosis of oral squamous cell carcinoma: A review of the literature. *Head Neck* 2005;27:1080-91.
- Hubert Low TH, Gao K, Elliott M, Clark JR. Tumor classification for early oral cancer: Re-evaluate the current TNM classification. *Head Neck* 2015;37:223-8.
- D'Cruz AK, Vaish R, Kapre N, Dandekar M, Gupta S, Hawaldar R, *et al.* Elective versus therapeutic neck dissection in node-negative oral cancer. *N Engl J Med* 2015;373:521-9.
- Jones AS, Roland NJ, Field JK, Phillips DE. The level of cervical lymph node metastases: Their prognostic relevance and relationship with head and neck squamous carcinoma primary sites. *Clin Otolaryngol Allied Sci* 1994;19:63-9.
- Union for International Cancer Control. TNM. 7<sup>th</sup> edition; December, 2009. Available from: [https://www.uicc.org/sites/main/files/private/TNM\\_Classification\\_of\\_Malignant\\_Tumours\\_Website\\_15%20May2011.pdf](https://www.uicc.org/sites/main/files/private/TNM_Classification_of_Malignant_Tumours_Website_15%20May2011.pdf). [Last accessed on 2018 Aug 24].
- Heliwell T, Woolgar J. Dataset for Histopathology Reporting of nodal Excisions and Neck Dissection Specimens Associated with Head and Neck Carcinomas; 7<sup>th</sup> December, 2011. Available from: <http://www.rpath.org>. [Last accessed on 2016 Jan 16].
- Huang SH, Hwang D, Lockwood G, Goldstein DP, O'Sullivan B. Predictive value of tumor thickness for cervical lymph-node involvement in squamous cell carcinoma of the oral cavity: A meta-analysis of reported studies. *Cancer* 2009;115:1489-97.
- Woolgar JA. Histopathological prognosticators in oral and oropharyngeal squamous cell carcinoma. *Oral Oncol* 2006;42:229-39.
- Bánkfalvi A, Piffkó J. Prognostic and predictive factors in oral cancer: The role of the invasive tumour front. *J Oral Pathol Med* 2000;29:291-8.
- Bryne M, Koppang HS, Lilleng R, Kjaerheim A. Malignancy grading of the deep invasive margins of oral squamous cell carcinomas has high prognostic value. *J Pathol* 1992;166:375-81.
- Kano S, Sakashita T, Tsushima N, Mizunachi T, Nakazono A, Suzuki T, *et al.* Validation of the 8<sup>th</sup> edition of the AJCC/UICC TNM staging system for tongue squamous cell carcinoma. *Int J Clin Oncol* 2018. Available from: <https://doi.org/10.1007/s10147-018-1276-5>.
- Mair M, Nair S, Thiagarajan SK, Agrawal J, Nair D, Chaturvedi P, *et al.* Skin involvement and ipsilateral nodal metastasis as a predictor of contralateral nodal metastasis in buccal mucosa cancers. *Indian J Cancer* 2016;53:394-6.
- Shah JP, Candela FC, Poddar AK. The patterns of cervical lymph node metastases from squamous carcinoma of the oral cavity. *Cancer* 1990;66:109-13.

ANNEXURE – III - PAPER PRESENTATION



**ANNEXURE – IV - CONSENT FORMS**

**(ENGLISH, KANNADA, MARATHI)**

**INFORMED CONSENT FORM:**

**Title of the study:** Pattern of cervical lymph node metastasis and its association with clinico-pathological variables in primary mandibular gingivo-buccal sulcus squamous cell carcinoma

**Objective / purpose of the study:** You are being invited to participate in this study. This study is being conducted to know the extent of spread of oral cancer in the lymph nodes of neck and the factors that are responsible for the spread.

**Procedures:** As a part of study we would like to collect some information about you, like: Name, age, occupation, personal information related to tobacco chewing or smoking if any and clinical details of oral tumor. This information will be kept confidential and will be coded without your name or any other identifying information about you. You will undergo the surgery as per the recommendations of your consulting surgical oncologist and no modifications will be done in the treatment plan or procedure for the purpose of study. The study will be conducted on the tissue specimen obtained following surgery. The specimen will be processed as per the study protocol without altering the necessary information that is mandatory for further treatment of your ailment.

**Withdrawal:** Participation in this study is voluntary. If you don't wish to participate in this study, you will not lose any benefits to which you are entitled. You are free to withdraw your consent and to discontinue participation in this study any time.

**Risks and benefits:** There are no physical risks involved to the participants in this study. The investigator will not promise or guarantee that you will receive any direct benefit for being a part of this study.

**Privacy and confidentiality:** Your identity will not be revealed. All the information collected will be coded so that your identity will not be known to others.

**Financial Incentives for participation:** The cost of the study will be borne by the researcher. There will be no payment to you for participation in the study.

**Authorization to publish the results:** The results of the study will be used for teaching and medical publications. However, the participant's identity will be kept confidential.

**Questions:** If you have any questions about this study, please call Dr Sidramesh Muttagi, principal investigator and surgeon at 9880491209 or Dr A. S Godhi, Principal, J. N. Medical College, KLE University Belgaum 0831-2471350 or Dr.Sudha Raddi, Chairman, Human Ethical Committee, KLE University Belgaum 0831-2444444.

**Consent Statement:** I am making a voluntary decision whether or not to participate in this study. My signature below indicates that I have decided to participate and I have read (or been read) the information provided above and I was given the opportunity to ask questions and that they have been answered to my satisfaction and that I have received a copy of this signed consent form.

.....

.....

Participant's signature/thumb

.....

.....

Research Scholar's Name & Signature

.....

.....

Witness Name & Signature

Date

## ಸಮ್ಮತಿ ಪತ್ರ

1. ಶಿರೋನಾಮೆ: ಪ್ಯಾಟರ್ನ್ ಆಫ್ ಸರ್ವೈಕಲ್ ಆಂಫ್ ನೋಡ್ ಮೆಟಾಸ್ಟಾಸಿಸ್ ಆಂಡ್ ಇಟು ಅನೋಸಿಯೆಲೆಶನ್ ವಿತ್ ಕ್ಲಿನಿಕಲ್ ಪ್ಯಾಥಾಲೊಜಿಕ್ ವೆಲಿಯೆಬಲ್ಸ್ ಇನ್ ಪ್ರೈಮರಿ ಮ್ಯಾಂಗ್ನಿಟುಡ್ ಜಂಪ್ರಿವೊಬಕ್ಟ್ ಸಲ್ಟನ್ ಕ್ಲೇಮನ್ ಸೆಲ್ ಕಾಲ್ಸಿನೋಮಾ.
2. ಸಂಶೋಧನೆಯ ಉದ್ದೇಶ: ನಿಮ್ಮನ್ನು ಈ ಸಂಶೋಧನೆಯಲ್ಲಿ ಭಾಗವಹಿಸಲು ಆಮಂತ್ರಿಸುತ್ತೇವೆ. ಈ ಸಂಶೋಧನೆಯ ಉದ್ದೇಶವೇನೆಂದರೆ ಬಾಂಜಿಯ ಆರೈಕೆ ರೋಗವು ( ಕ್ಯಾನ್ಸರ್) ಕುತ್ತಿಗೆ ದುರ್ದರಸರಂಥಿಗೇ ಹೇಗೆ ಹೆಚ್ಚುವದು ಎಂಬದನ್ನು ತಿಳಿಯುವದು.
3. ಪ್ರಕ್ರಿಯೆಯ ವಿವರಗಳು: ಕ್ಯಾನ್ಸರ್ ಇರುವ ರೋಗಿಗಳನ್ನು ಸಂಶೋಧನೆಯಲ್ಲಿ ಆಮಂತ್ರಿಸಲಾಗುವದು. ರೋಗಿಗಳ ಹೆಸರು, ವಯಸ್ಸು, ಉದ್ಯೋಗ, ತಂಪಾಕು, ಜೀವನ ಮತ್ತು ಸರಾಸರಿ ಜೀವನ ಮಾಹಿತಿ ತೆಗೆದು ಕೊಳ್ಳಲಾಗುವದು. ನಿಮ್ಮ ರೋಗಕ್ಕೆ ಸೂಕ್ತವಾದ ಶಸ್ತ್ರ ಚಿಕಿತ್ಸೆ ಮಾಡಲಾಗುವದು. ನಿಮ್ಮ ಕ್ಯಾನ್ಸರ್ ಗೆಡೆಯ ತಪಾಸಣೆ ಮಾಡಲಾಗುವದು. ಇದರಿಂದ ನಿಮ್ಮ ಬೇರೆ ಯಾವ ಚಿಕಿತ್ಸೆಯು ಬದಲಾವಣೆಯಾಗುವದಿಲ್ಲ.
4. ಹಿಂತೆಗೆದುಕೊಳ್ಳುವದು: ಈ ಸಂಶೋಧನೆಯಲ್ಲಿ ಭಾಗವಹಿಸುವದು ಸ್ವಇಚ್ಛೆ ಈ ಸಂಶೋಧನೆಯಿಂದ ಯಾವಾಗಾದರೂ, ಯಾವದೇ ಕಾರಣ ನೀಡದೆ, ಹಿಂತೆಗೆದುಕೊಳ್ಳಬಹುದು.
5. ಲಾಭ ಮತ್ತು ಅಪಾಯಗಳು: ನಿಮಗೆ ಈ ಸಂಶೋಧನೆಯಲ್ಲಿ ಭಾಗವಹಿಸಿದ್ದಕ್ಕೆ ಏನು ಲಾಭವಾಗಬಹುದು. ಮತ್ತು ಭಾಗವಹಿಸಿದರೆ ಯಾವದೇ ಭೌತಿಕ ಹಾನಿಯಿಲ್ಲ.
6. ಗೌಪ್ಯ ಮತ್ತು ರಹಸ್ಯತೆ: ನಿಮ್ಮ ಹಾಗೂ ನಿಮ್ಮ ಕಾಂಪ್ಯೂಟರ್ ಮಾಹಿತಿಯನ್ನು ಗುಪ್ತವಾಗಿಡಲಾಗುವದು.
7. ಸಂಶೋಧನೆಯಲ್ಲಿ ಭಾಗವಹಿಸಲು ಹಣಕಾಸಿನ ಸಹಾಯ: ಈ ಸಂಶೋಧನೆಗೆ ಬೇಕಾಗುವ ವೆಚ್ಚವನ್ನು ಸಂಶೋಧಕರೇ ಕೊಡುತ್ತಾರೆ. ಭಾಗವಹಿಸುವಲಿಗೆ ಚಿಕಿತ್ಸೆ ಚೆಲ್ಲು ಬೇರೆ ಯಾವದೇ ತರಹದ ಹಣಕಾಸಿನ ಸಹಾಯ ಮಾಡುವದಿಲ್ಲ.
8. ಸಂಶೋಧನೆಯ ಫಲಿತಾಂಶವನ್ನು ಪ್ರಕಟಿಸಲು ಅನುಮತಿ: ಈ ಸಂಶೋಧನೆಯ ಫಲಿತಾಂಶವು ಕೇವಲ ವೈದ್ಯಕೀಯ ಶಿಕ್ಷಣ ಮತ್ತು ಅಧ್ಯಯನ ಸಲುವಾಗಿ ಉಪಯೋಗಿಸಲಾಗುವದು. ಅದರ ಭಾಗವಹಿಸುವರ ಗುರುತನ್ನು ಗುಪ್ತವಾಗಿ ಇಡಲಾಗುವದು.
9. ಪ್ರಶ್ನೆಗಳು: ಈ ಸಂಶೋಧನೆಯ ಬಗ್ಗೆ ನಿಮಗೆ ಹೆಚ್ಚಿನ ವಿವರ ಮತ್ತು ಪ್ರಶ್ನೆ ಇದ್ದಲ್ಲಿ ಕೆಳಗಿನ ವಿಳಾಸಕ್ಕೆ ಸಂಪರ್ಕಿಸಬಹುದು .

ಡಾ: ಸಿದ್ದರಾಮೇಶ ಮುತ್ತಣ, ಪ್ರಮುಖ ಸಂಶೋಧಕರು ಮತ್ತು ಶಸ್ತ್ರಚಿಕಿತ್ಸಕರು, ಮೊ.ನಂಬರ್-9880491209 ಅಥವಾ

ಡಾ: ಎ.ಎನ್.ರೋಥಿ (0831-2444444) ಅಥವಾ

ಡಾ: ಸುಧಾ ರೆಡ್ಡಿ ಜೇರಮನ್ ಹುಮನ್ ಎತ್ತಿಕಲ್ ಕಮೀಷ ಕೆ.ಎಲ್.ಇ ವಿಶ್ವ ವಿದ್ಯಾಲಯ  
ಬೆಳಗಾವಿ.(0831-2444444)

ನಾನು ಈ ಸಂಶೋಧನೆಯಲ್ಲಿ ಭಾಗವಹಿಸಲು ನನ್ನ ಸಮ್ಮತಿಯನ್ನು ಕೊಡುತ್ತೇನೆ. ಈ ಮೇಲಿನ ಎಲ್ಲ ಮಾಹಿತಿಯನ್ನು ಓದಿ ತಿಳಿದು ಕೊಂಡಿರುತ್ತೇನೆ. ಈ ಸಂಶೋಧನೆಯಲ್ಲಿ ಭಾಗವಹಿಸಲು ನನ್ನ ಸಂಪೂರ್ಣ ಒಪ್ಪಿಗೆ ಇರುತ್ತದೆ.

ರೋಗಿಯ ಸಹಿ ಮತ್ತು ಹೆಚ್ಚಿನ ಗುರುತು

ಸಂಶೋಧಕರ ಸಹಿ

ಸಾಕ್ಷಿಯ ಸಹಿ

ಏನಾಂಕ :

### माहितीपूर्ण संमती फॉर्म

- **अभ्यास प्रकल्पाचे शिर्षक :**

पॉर्टन ऑफ सर्विकल लिम्प नोड मेटास्टाटीस अँड ईट्रूस असोसिएशन वित क्लिनिको- पॉथोलॉजीकल वेरीएबल्स इन प्रायमरी मॉनडीबुलर जिगिहोबुक्ल सल्कस स्क्वॅमस सेल कार्सिनोमा.

- **अभ्यास प्रकल्पाचे उद्देश :**

आपणासर्वांना या विषयाशी संबंधित अभ्यासात सहभागी होण्याचे आमंत्रण दिले जात आहे. ह्या अभ्यासमागचा उद्देश मुख कर्क रोग हा मानेवरील लसिका ग्रंथीपर्यंत पोहोचण्याचे कारणे शोधणे आहे.

- **विधी :**

ह्या अभ्यासाचा भाग म्हणून आम्ही आपणाकडून काही माहिती गोळा करू इच्छितो, जसे की नाव, वय, नोकरी, व्यवसाय, वैयक्तिक माहिती जसे तंबाखू खाता की धुम्रपान करता की नाही?, आपणास तोंडात काही गाठी आहेत का? इत्यादी.

वरील सर्व माहिती गोपनीय राखली जाऊन आपल्या वैयक्तिक शल्यविशारद तज्ञांच्या सल्यानुसारच शस्त्रक्रिया करण्यात येईल आणि त्यांनी सुचवलेल्या उपचार पद्धतीत आम्ही करीत असलेल्या अभ्यासात काहीएक बदल करण्यात येणार नाही. वरील अभ्यास हा खालील पद्धतीच्या शस्त्रक्रिया द्वारे घेण्यात येणाऱ्या नमुन्याद्वारे करण्यात येईल. आपल्याकडून घेण्यात आलेल्या नमुनांवर ठरलेल्या अभ्यास पद्धतीनुसारच (काही बदल न करता) पुढील उपचाराकरीता आवश्यक असलेली माहिती नोंदविण्यात येईल.

- **माघार :**

ह्या अभ्यासात भाग घेणे हे पूर्णतः ऐच्छिक आहे. जर आपणा ह्या अभ्यासात भाग होऊ इच्छित नसलात तरी देखील आपण आपणास मिळू शकणाऱ्या सोयीसुविधा, उपचारांपासून वंचित राहणार नाही. ह्या अभ्यासातून कधीही बाहेर पाडण्यास आपण मुक्त आहात. त्याकरीता आपल्यावर कोणत्याही प्रकारचे बंधन नाही.

- **जोखीम आणि फायदे :**

ह्या अभ्यासप्रकल्पात सहभागी होणाऱ्यांना कोणत्याही प्रकारची शारीरिक ईजा होण्याचा संभव नाही. ह्या अभ्यासप्रकल्पात सहभागी होणाऱ्यांना कोणत्याही प्रकारे प्रत्यक्ष फायदा मिळण्याची हमी देण्यात येत नाही.

- **गोपनीयता :**

आपली ओळख / माहिती याविषयी संपूर्णपणे गुप्तता पाळली जाईल. जमा करण्यात आलेली माहिती कोड करण्यात येईल की, जेणे करून कोणत्याही प्रकारे आपली ओळख उघडतीस येणार नाही.

- **सहभागा संदर्भातील आर्थिक बाबी :**

संबंधित अभ्यासप्रकल्पाला येणाऱ्या खर्च संपूर्णपणे संशोधकातर्फे / अभ्यासकातर्फे करण्यात येईल आणि ह्या अभ्यासप्रकल्पात भाग घेण्याबद्दल सहभागींना कोणत्याही प्रकारे आर्थिक मोबदला दिला जाणार नाही.

- **निष्कर्ष प्रकाशित करण्याबाबतची अधिकृतता :**

ह्या अभ्यासप्रकल्पातून समोर येणारे निष्कर्ष हे वैद्यकीय शिक्षणाकरीता आणि अभ्यासाकरीता प्रकाशित करण्यात येतील परंतु यात सहभागकर्त्यांची ओळख कोणत्याही प्रकारे उघडतीस येणार नाही.

● प्रश्न :

आपणासंबंधित विषयासंदर्भात कोणत्याही प्रकारचे प्रश्न असल्यास आपण डॉ. सिद्रमेश मुतंगी प्राचार्य, संशोधक आणि शल्यचिकित्सक यांना -९८८०४९१२०९, ह्या भ्रमणध्वनीवर किंवा डॉ. ए.एस.गोधी प्राचार्य J.N. Medical Collage, KLE University Belgaum येथे ०८३१ -२४७९३५० किंवा डॉ. सुधा रेड्डी अध्यक्षा मानवी नैतिकता समिती KLE University Belgaum येथे ०८३१ - २४४ ४४४४ संपर्क करू शकता.

● संमतीपत्र :

मी ह्या अभ्यासप्रकल्पात स्वेच्छेने सहभागी होत आहे. माझी खालील स्वाक्षरी "ह्या प्रकल्पात माझ्या सहभागाविषयी आणि त्यासंदर्भात माहिती मी वाचली असून मला ती समजली आहे" असे दर्शविते ह्या अभ्यासा प्रकल्पाशी संबंधित माझ्या सर्व शंकांचे योग्य प्रकारे निरसन करण्यात आले असून, मला संबंधित समंती पत्राची साक्षांकित प्रत मिळाली असल्याचे मी नमुद करते / करतो.

-----  
स्वाक्षरी / डाव्याहाताचा अंगडा

सहभागकर्ता

-----  
अभ्यासकर्त्याची नाव व स्वाक्षरी

संशोधक

-----  
स्वाक्षरी

-----  
साक्षीदाराचे नाव व स्वाक्षरी

दिनांक : / /

## **ANNEXURE – V - STUDY PROFORMA**

**Pattern of cervical lymph node metastasis and its association with clínico-pathological variables in primary mandibular gingivo-buccal sulcus squamous cell carcinoma**

Proforma of Pathological details obtained after grossing of surgical specimens

**Name:**

**Age:**

**Sex: Male / Female**

**OP No:**

**Address & Contact Details:**

- pT size (cm)
- Histological grade: well/moderate/poor
- Involvement of bone
- Perineural invasion
- Lymphovascular emboli

Nodal levels submitted	IA	IB	IIA	IIB	III	IV	VA	VB	PAROTID NODES
No. of nodes per level									
No. of positive nodes									
ECS *									
Total									

**Pattern of cervical lymph node metástasis and its association with clínico-  
pathological variables in primary mandibular gingivo-buccal sulcus squamous  
cell carcinoma**

**Proforma of clinical details:**

**Name:**

**Age:**

**Sex: Male / Female**

**OP No:**

**Address & Contact Details:**

Chief complaint:

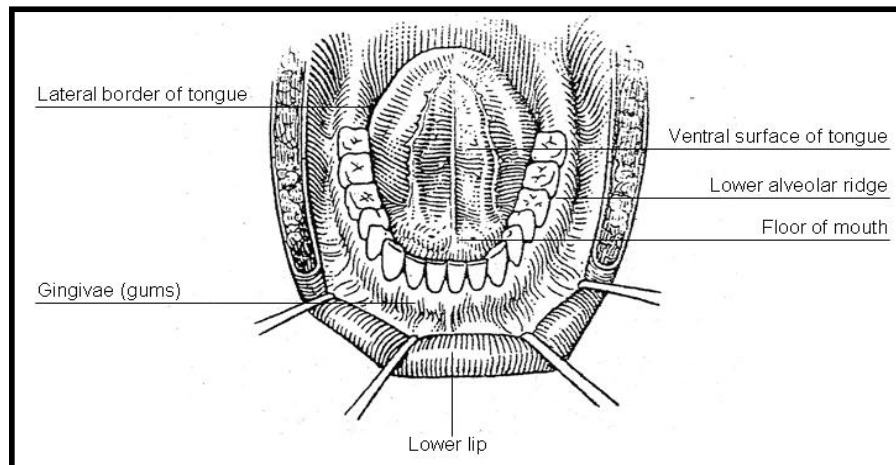
History of present illness:

Habit history: arecanut/ tobacco use/ smoking/ alcohol consumption

Frequency:

Duration:

Clinical tumor extent:



Involvement of adjacent structures: skin/ bone/muscles/ nerve

cTNM (AJCC 2009):

REMARKS: