
**“ASSESSMENT OF TRANSMUCOSAL PATCH
AS AN ALTERNATIVE TO INFILTRATION
ANESTHESIA IN ORTHODONTIC
EXTRACTION: A SPLIT MOUTH STUDY”**

By

**Dr. CHAITRALI. SANT
REG.NO.-IF0219005**

Dissertation

*Submitted to the
KLE Academy of Higher Education & Research Belagavi, Karnataka
In partial fulfillment of the requirements for the degree of*

**MASTER OF DENTAL SURGERY
In
ORAL AND MAXILLOFACIAL SURGERY
(BRANCH III)**

**Under the Guidance of
Dr. SANJAY RAO, MDS Professor**

**DEPARTMENT OF ORAL AND MAXILLOFACIAL SURGERY
KAHER'S V K INSTITUTE OF DENTAL SCIENCES
BELAGAVI, KARNATAKA**

2019 – 2022

KLE ACADEMY OF HIGHER EDUCATION & RESEARCH

BELAGAVI, KARNATAKA

DECLARATION BY THE CANDIDATE

I hereby declare that this dissertation/thesis “**ASSESSMENT OF TRANSMUCOSAL PATCH AS AN ALTERNATIVE TO INFILTRATION ANESTHESIA IN ORTHODONTIC EXTRACTION :A SPLIT MOUTH STUDY**” is a bonafide and genuine research work carried out by me under the guidance of **Dr. Sanjay Rao MDS**, Professor, Department of Oral and Maxillofacial Surgery, K.L.E. Vishwanath Katti Institute of Dental Sciences, Belagavi.

Date: 31/12/21

Place: Belagavi


Dr. CHAITRALI.SANT.

REG.NO.-IF0219005

KLE ACADEMY OF HIGHER EDUCATION & RESEARCH

BELAGAVI, KARNATAKA

CERTIFICATE BY THE GUIDE

This is to certify that the dissertation “ASSESSMENT OF TRANSMUCOSAL PATCH AS AN ALTERNATIVE TO INFILTRATION ANESTHESIA IN ORTHODONTIC EXTRACTION :A SPLIT MOUTH STUDY” is a bonafide research work done by **Dr.CHAITRALI.SANT**, postgraduate student, in partial fulfillment of the requirement for the degree of **MASTER OF DENTAL SURGERY (MDS)** in Oral and Maxillofacial Surgery.

Date: 31/12/2021.

Place:Belagavi

Dr. SANJAY RAO_{MDS},

Professor

Department of Oral and Maxillofacial Surgery,

K.L.E VK Institute of Dental Sciences,

Belagavi – 590010

Dr. Sanjay S. Rao
Consultant : Regd.No. 10,875 - A
Oral & Maxillofacial Surgery
KLE VK IDS, Belgaum

KLE ACADEMY OF HIGHER EDUCATION & RESEARCH

BELAGAVI, KARNATAKA

ENDORSEMENT BY THE HEAD OF THE DEPARTMENT AND
PRINCIPAL/HEAD OF THE INSTITUTION

This is to certify that the dissertation “ASSESSMENT OF TRANSMUCOSAL PATCH AS AN ALTERNATIVE TO INFILTRATION ANESTHESIA IN ORTHODONTIC EXTRACTION :A SPLIT MOUTH STUDY” is a bonafide research work done by **Dr. CHAITRALI SANT**, post graduate student under the guidance of **Dr. SANJAY RAO_{MDS}**, K.L.E. Vishwanath Katti Institute of Dental Sciences, Belagavi.

Head of Department


Dr. SHRIDHAR D. BALIGA M.D.S

Professor & Head,
Department of Oral & Maxillofacial Surgery,
KAHER's V K Institute of Dental Sciences,

Professor and Head
Belagavi-590010
Department of Oral & Maxillofacial Surgery
KLE V. K. Institute of Dental Sciences,
Belagavi

Date: 3/12/21

Place: Belagavi


Principal

PRINCIPAL
KLE V. K. Institute of Dental Sciences,
Nehru Nagar, Belagavi
Dr. ALKA KALE M.D.S.

Principal,
KAHER's V K Institute of
Dental Sciences, Nehru Nagar,
Belagavi-590010.

Date: 4/1/22

Place: Belagavi

KLE ACADEMY OF HIGHER EDUCATION & RESEARCH

BELAGAVI, KARNATAKA

COPYRIGHT

DECLARATION BY THE CANDIDATE

I hereby declare that **KLE ACADEMY OF HIGHER EDUCATION & RESEARCH**, Belagavi, Karnataka shall have the rights to preserve, use and disseminate this dissertation entitled “**ASSESSMENT OF TRANSMUCOSAL PATCH AS AN ALTERNATIVE TO INFILTRATION ANESTHESIA IN ORTHODONTIC EXTRACTION :A SPLIT MOUTH STUDY**” in print or electronic format for academic/research purpose.

Date: 31/12/21


Dr. CHAITRALI.SANT

Place: Belagavi

REG.NO.-IF0219005

**KLE Academy of Higher Education and Research, Belagavi, Karnataka
Established under section 3 of UGC Act, 1956 vide, GOI, Notification
No. F. 9-19/2000-V.3 (A)**

UNDERTAKING

I, **Dr. CHAITRALI SANT**, hereby declare that the information and the data mentioned in my thesis entitled “**ASSESSMENT OF TRANSMUCOSAL PATCH AS AN ALTERNATIVE TO INFILTRATION ANESTHESIA IN ORTHODONTIC EXTRACTION :A SPLIT MOUTH STUDY**” belongs to me and is original.

I am aware of the definition of plagiarism as detailed below:

- An act or instance of using or closely imitating the language and thoughts of another author without authorization and the representation of that author's work as one's own, as by not crediting the original author.
- A piece of writing or other work reflecting such unauthorized use or imitation.
- The deliberate or reckless representation of another's words, thoughts or ideas as one's own without attribution in connection with submission of academic work, whether graded or otherwise.

I hereby declare that the thesis prepared by me is an original one and does not involve plagiarism anywhere. In case at a later stage it is found that I have indulged in plagiarism, then I am solely responsible for the same and the institution is at liberty to take any disciplinary action against me including cancellation of dissertation or any other penalties imposed by the university.

Date: 31/12/21

Place : Belagavi

Dr. CHAITRALI SANT

ACKNOWLEDGEMENT

“Alone we can do so little; together we can do so much”

-Helen Keller

The entire work accomplished in this journey was made possible because of contribution of many people and I take this precious opportunity to express my gratitude towards them. Without their active guidance and encouragement I could not have made headway in my thesis.

*Foremost, I am grateful and honoured to work with my respected teacher and Guide **Dr. Sanjay Rao**_{MDS}, Professor, Department of Oral and Maxillofacial surgery for providing his expertise, generous guidance which helped me not only during the preparation of this dissertation but throughout my post-graduation course.*

I am indeed indebted with his valuable assistance and encouragement in regard to research. Without his guidance and persistent help this dissertation would not have been possible.

*With gratitude and humbleness, I sincerely thank **Dr. Shridhar D. Baliga**_{MDS}, Professor and Head, Department of Oral and Maxillofacial surgery, for their kind consideration, patience, and for their untiring support throughout the course. His dynamism, motivation and immense knowledge has deeply inspired me.*

*I take this opportunity to express my heartfelt gratitude to **Dr. Alka Kale**_{MDS}, Principal, KLE Vishwanath Katti Institute of Dental sciences, Belgaum, for providing me with facilities and infrastructure to carry out this study.*

*A special thanks to **Dr. Bhaskar. Kurangi**, Assistant Professor, Department of Pharmaceutics for his invaluable support and guidance in making this study a success.*

*I wish to express my sincere gratitude to my teachers, **Dr. S. M. Kotrashetti** and **Dr. Tejraj. P. Kale** for their moral support and insights they had shared regarding our academic course.*

*I would like to thank **Dr. Siddharamesh Mutaggi**, **Dr. Arati. Neeli**, **Dr. Vijaylakshmi**, **Dr. Abhishek**, **Dr. Poorvi** and **Dr. Snehalata** for their professional guidance and whole hearted support throughout my postgraduate course.*

A debt of gratitude is also owed to the staff of BSRC who supported me and provided me with the best guidance in the completion of my thesis

*I would also like to thank **Dr. Punya. Rao** , HOD and Professor of Department of Oral and Maxillofacial Pathology for her efficacious guidance and motivation during the preparation of my thesis.*

*I would like to express my immense gratitude towards my seniors **Dr. Srishti**, **Dr. Abhishek**, **Dr. Noureen**, **Dr. Soumyasnata**, **Dr. Krishna**, **Dr. Yash** **Dr. Mehershah** **Dr. Prashasti**, **Dr. Rishabh** and **Dr. Abhishek** for all their help and support.*

*My batchmates and my friends **Dr. Radhika**, **Dr. Harshini**, **Dr. Ajit**, **Dr. Mohan** and **Dr. Sanjyot** who have always given me a familial support at all times without whom the study wouldn't have been an easy journey. My junior colleagues **Dr. Kritika**, **Dr. Faheem**, **Dr. Ninad**, **Dr. Akansha**, **Dr. Chetan** and **Dr. Sanjiti** for being by my side and being there at the need of hour.*

*I thank **Mr. Arun, Mr. Anand and Mr. Manoj** of **Vighneshwara Associates**,
for formatting, printing and binding of my thesis.*

*It is impossible to extend enough thanks to my beloved family **Mr.Suhas**,
Mrs.Sushila, Ms. Nikita and Mr.Param for their unconditional love and unwavering
support I needed throughout this process.*

*Last but not the least, I thank my **patients** who have been the subject of this
study without whom this task was impossible.*

Dr. CHAITRALI.SANT.

LIST OF ABBREVIATIONS

OTC	:	Over the counter
AIDS	:	Acquired immune deficiency syndrome
VAS	:	Visual analogue scale
PVP	:	Poly vinyl pyrrolidone
PVA	:	Poly vinyl alcohol
SEM	:	Sound, Eyes, Motor scale

ABSTRACT

Introduction:

Managing pain and anxiety during extraction has always been an essential part of oral surgery. Anxiety usually induces stress and fright due to which there is decrease in tolerance to pain. To prevent pain, administration of local anaesthesia via needle injection is done. The increasing risk of AIDS and hepatitis B caused due to utilization of contaminated syringes has resulted in exploration for different options in parenteral administration of drugs.¹ To minimize the excruciating impact during conventional method of local anaesthesia, alternative techniques can be considered, for instance like topical anaesthetics , transmucosal patch ,etc. Transmucosal patch is a local drug delivery method that evidently boost the effect of drug which diffuses into a specific local mucosal site and reduces the pain related with needle injections.

Aim:

To compare anesthetic efficacy of transmucosal patch containing 2% lignocaine hydrochloride and 2% lignocaine hydrochloride infiltration with adrenaline during bilateral orthodontic extractions.

Materials and Methods

18 patients who were advised orthodontic extraction of bilateral upper premolars in Department of Oral and Maxillofacial Surgery, KLE's V.K. Institute of Dental Sciences, Belagavi and were willing for application of patch were considered for the study. Allotment of patients for extraction were done at two separate clinical sessions (one side at a time) and were randomised by computer generated randomization list .For study group: Transmucosal patch was applied measuring 2cm² both on buccal

side and palatal side of the tooth planned for extraction. After application of patch, onset of action, duration of anaesthesia was assessed. For Control group: Local infiltration was given both on buccal and palatal aspect of the upper premolar. Postoperatively using visual analogue scale pain perception was assessed.

Results:

A total of 18 patients with bilateral orthodontic extraction of upper first premolar were selected in the study. The age range which was present in the study was 10-20 yrs with 44.4% of patients present in 10-15 years of age and 55.56% present in 15-20 years of age. There were 6 male and 12 female patients in the study. Onset of action of transmucosal lignocaine patch in 7 patients was 2-2.9mins (38.89%) while in 11 patients it was 3-3.9 mins(61.11%) with the mean onset of 2.76 ± 0.43 . Duration of patch in 6 patients was 15-20 mins (33.33%) while in majority of patients i.e in 12 patients it was 20-30 mins (66.67%). In the study it was found that patient with transmucosal lignocaine patch had more pain after extraction as compared to infiltration anaesthesia.

Conclusion:

From the study it was concluded that the gingival anaesthesia is sufficiently achieved by transmucosal lignocaine patch and hence can be used as an adjuvant. For its use in invasive procedures more diffusion studies need to be carried out.

Keywords: 'Transmucosal lignocaine patch 'orthodontic extraction' 'mucoadhesive patch'

TABLE OF CONTENTS

SL. NO	CONTENTS	PG. NO.
1	INTRODUCTION	1-2
2	AIMS AND OBJECTIVES	3
3	REVIEW OF LITERATURE	4-9
4	MATERIAL AND METHODS	10-16
5	RESULTS	17-24
6	DISCUSSION	25-29
7	CONCLUSION	30
8	BIBLIOGRAPHY	31-33
9	ANNEXURES	34-40

LIST OF TABLES

SL. NO	TABLE	PG. NO.
1	Case details	17
2	Age-wise distribution of patients	19
3	Gender wise distribution of patients	20
4	Onset (in min) of patch wise distribution of patients	21
5	Application of patch (in min) wise distribution of patients	22
6	Duration of patch (in min) wise distribution of patients	23
7	Comparison of extraction with patch and extraction with infiltration with VAS scores by Mann-Whitney U test	24

LIST OF GRAPHS

SL. NO	FIGURE	PG. NO.
1	Age-wise distribution of patients selected in the study	19
2	Gender wise distribution of patients	20
3	Onset (in min) of patch wise distribution of patients	21
4	Application of patch (in min) wise distribution of patients	22
5	Duration of patch (in min) wise distribution of patients	23
6	Comparison of extraction with patch and extraction with infiltration with VAS scores by Mann-Whitney U test	24

LIST OF FIGURES

PICTURE SL.NO	TITLE OF PICTURES	PG. NO.
1	Patch preparation	15
2	Armamentarium	16
3	Clinical pictures	16

INTRODUCTION:

Pain control is an essential part in dentistry. Dental procedures for prevention and treatment of dental diseases for eg: deep root scaling, root canal treatment, tooth extraction, etc. usually require anaesthesia preoperatively and postoperative analgesics.² Providing effective and safe anaesthesia becomes the important skill. Administrating local anaesthetic agents by injection is still the routine method. A wide variety of local anesthetic agents of ester and amide group are available. Compared to esters, amides have low incidence of causing allergic reactions. Lignocaine hydrochloride is the most common anaesthetic agent used in dentistry. It is used in injection form but it provokes anxiety in most of the patients especially children also cause pain due to needle penetration³. Hence to avert this distress induced by needle injection there is constant search of newer methods for comfortable and pleasing way to produce local anaesthesia.⁴

One such method is buccal mucoadhesive drug. Buccal mucosa has been scrutinized as a capable site for local delivery of drug. It has gained considerable attention as an alternative form. It contains different polymers so as to improve the properties of patch such as it's flexibility, adhesion to oral mucosa , diffusion , etc.⁵ Application on buccal mucosa has following advantages:

Compared to transdermal, transbuccal delivery has higher permeability so less dose can provide same therapeutic effect.

As Buccal mucosa has property of rapid cell turnover it is more resistant to tissue damage and irritation.

Minimize systemic involvement

Rapid onset of action because of high blood levels.⁶

Since 1948, Lidocaine hydrochloride is widely used in dentistry as local anaesthetic agent. Lidocaine has the benefit of an anesthetic as well as an analgesic agent both systemically and topically and is within each reach commercially in prescription and over the counter (OTC) preparation including sprays, creams and gels, ointments and patches . When applied topically as gel it has short retention time as it leaches out in the oral cavity.⁵ When applied as a patch the absorption rate apart from vascularity depends upon surface area , thickness of stratum corneum , duration of application. Hence absorption is higher in oral mucosa than skin. Studies have shown maximum penetration depth of 8-10mm of lidocaine when applied topically.⁷

Further transmucosal patch has added advantages such as site specific delivery, control of drug release, accuracy of dosage, local delivery for prolonged time, unidirectional release of drug due to backing layer and painless application, etc.

² In dentistry, few studies have been done using transmucosal patch including extraction of deciduous teeth, extraction of periodontally compromised teeth, to reduce pain during infiltration anesthesia, aphthous ulcers ,etc. The dosage of drug used was same which is used in infiltration i.e 2 ml of 2% lignocaine hydrochloride.

Hence the purpose of our study was to compare infiltration anesthesia with transmucosal patch in orthodontic extraction.

In our study, we found that the patch containing lignocaine hydrochloride achieved the anaesthesia but depth of penetration of drug was less. Hence the patch was not effective in all the cases to proceed with the orthodontic extraction.

AIM & OBJECTIVES

AIM

- To compare anesthetic efficacy of transmucosal patch containing 2% lignocaine hydrochloride and 2% lignocaine hydrochloride infiltration during bilateral orthodontic extractions.

OBJECTIVES

- To assess the post-operative pain
- To assess the onset of anesthesia
- To assess the duration of action

REVIEW OF LITERATURE:

Topical anaesthesia has been used in dentistry since a long time and numerous modifications are available in drug delivery system. Routinely used drug delivery to achieve anaesthesia is through needle penetration for infiltration or nerve block which is associated with pain. Hence newer advances in topical agents like buccal drug delivery system in the form of patch, wafer, bioadhesive microparticles, etc have gained attention to increase patient compliance and minimize discomfort.

Before transmucosal patch was developed transdermal patch had gain popularity in treatment of superficial skin disease as it produce local anti-inflammatory and anaesthetic effect. Earliest contribution of transdermal patches was given by Dale Wurster.

Mcmillan et.al in 1964 were first to introduce scopolamine patch for motion sickness and made it commercially available. Further development introduced nitroglycerine patches for angina, clonidine transdermal patch for hypertension, Fentanyl for pain reduction and Nicotine for smoking cessation.⁸

After the advancement of drug delivery system transbuccal patch was developed. Taware et.al in 1997 in their study used “saliva activated bioadhesive drug delivery system” holding 20 mg of lidocaine hydrochloride for extraction of firm as well as mobile teeth in both the jaws. 49 teeth in 41 patients were extracted with overall efficacy of 86%. The time of onset of the patch was 15-20 mins which was more comparitevely to the infiltration.¹

In 1989, I.M.Brook et.al conducted a study on clinical pharmacology of 50 mg of lidocaine patch on oral mucosa of 9 patients which brought about soft tissue anaesthesia with diffusion and extent similar to infiltration anaesthesia and they noticed loss of proprioception while biting and there was pulpal analgesia as tested by electric stimulation. The threat of systemic toxicity was less as lignocaine concentrations in plasma were very low (7-94 ng/ml).⁹

There are multiple studies on transbuccal patch but clinical effectiveness is still doubtful. In 2000 work has been carried out for the availability of drug diltiazem hydrochloride in buccal patches and chlorpheniramine maleate. It was observed bioavailability of chlorpheniramine buccal patch was 1.46 times more than that of oral dosage. In 2008 experiment was carried out of glipizide containing patches .¹⁰

In 2001 study carried out by Shelly et.al compared Dentipatch containing 20% lidocaine with topical benzocaine gel for rubber dam clamp placement. Assessment of the patch was done by visual analogue scale. 28 patients were selected with age group of 6-17 yrs and were randomized in two groups for application of dentipatch and topical gel before rubber dam placement. It was observed that Dentipatch was effective compared to gel. Disadvantage of patch being time needed for application and onset of patch and poor adherence to oral mucosa.¹¹

In 2008 study conducted by Kazuyo et.al , clinical as well as in vitro evaluation was done of Indomethacin patch. The effectiveness of film was gauged in subjects experiencing oral pain. 0.5% and 1% concentration of Indomethacin was compared and it was observed that both provided favorable analgesic effects and it was highest in 1% group and so the authors concluded that these preparations could provide benefit as a localized analgesic drug.¹²

In 2008 Avner Shemer et.al evaluated the significance of a mucoadhesive patch containing citrus oil and magnesium salts in terms of potency and tolerability compared with oral solution containing benzocaine and compound benzoin tincture as a treatment of aphthous stomatitis. 48 patients were selected and divided into groups where on 26 patients patch was applied once a day and 22 patients used oral solution thrice a day. The mucoadhesive patch in this study proved beneficial in the treatment of aphthous ulcer in terms of pain intensity, healing and adverse reaction.¹³

In 2010 a study conducted on effectiveness of dexamethasone transmucosal patch for the treatment of oral submucous fibrosis. In control group subjects were treated with intralesional injection of steroids and in study group dexamethasone steroid patch was placed. No significant difference was noted in reduction of burning sensation in both the groups but the study group had significant improvement in mouth opening. In the same year study was conducted on Levofloxacin gingival patch for periodontitis and it was found that at the end of tenth day drug released was 99.74%. It was concluded, for the treatment of periodontitis, Levofloxacin could be incorporated in a “slow release device”.¹⁰

In 2011 study was carried out to gauge the wound healing property of Curcumin and Centella asiatica extract in comparison with human recombinant Epidermal growth Factor. 15 systemically healthy patients with 30 sites were selected. The mucosal patches were applied on various oral lesions ranging from 0.3- 0.5 mm in size. It was also noticed that on application of patch over lesions of buccal mucosa the healing takes place better in curcumin and centella asiatica.¹⁴

In 2013, Ladan Eslamian et.al conducted a study of benzocaine 20% patch on pain caused due to orthodontic elastomeric separators. Benzocaine patch and placebo patch were placed randomly for right or left first permanent mandibular/maxillary molars for 20 min and procedure was repeated after 6 hrs. VAS was used for evaluating pain perception and it was recorded immediately after placement of separator and after 2, 6, 12, 18, 24, 48 and 72 h. The mean of pain perception for the placebo and benzocaine groups were 2.28 and 1.63 respectively. The pain perception was not different in terms of gender and jaws. Hence it was proved application of benzocaine patch reduced discomfort or orthodontic pain after application of separators.¹⁵

Lidocaine patches are also used as an adjuvant in conventional method of anaesthesia. Multiples studies are done on achieving gingival anaesthesia by mucoadhesive patch before infiltration. In the study by Elliot v. Hersh et.al, Dentipatch lidocaine transoral system was evaluated which is approved by “U.S. Food and Drug Administration” and are commercially available before administering local anesthesia with 25 gauge needle. Better analgesic effect was produced by dentipatch compared to placebo within 2 to 5 minutes of placement. Drug related complication were negligible and lidocaine blood level was low, averaging 10-14 times less than that of conventional method. Hence the author came to the conclusion that the lidocaine patches used in this study are fruitful and safe in minimizing the pain due to needle insertion.¹⁶ In another study by S.H.Lee the bioadhesive patch was used before infiltration and compared with conventional method. The outcome was evaluated by SEM scale and the authors concluded that patch as an adjuvant to infiltration decreases discomfort and reduce anxiety in children. No difference was observed in patch and conventional technique in terms of gender and jaws.¹¹

In 2014 Kavita Rai et.al conducted a study to appraise clinical competence of lignocaine and benzocaine patch in various dental treatments. Onset of drug was recorded for each group once the anesthetic effect was achieved ,subjective and objective pain assessment was evaluated by the visual analogue scale and the SEM scale. In each group, extraction were performed on 25 patients and firm to grade 3 mobile teeth were extracted after onset was checked. For grade 3 mobile extractions were uneventful but for firm to grade 2 teeth conventional method had to implement adjuvant to patch. The extraction of grade 3 mobile teeth, pulp therapy of non-vital tooth and band adaptation procedure were evidently painless as assessed by VAS and SEM scale.. Authors concluded that, Only in minimally invasive dental procedures mucoadhesive patches can be considered as an alternative over infiltration anesthesia and also could be used as an adjuvant in minimizing pain of nerve block which is usually administered in the case of more invasive procedures like pulp therapy, extraction of firm teeth and minor surgical procedures.¹⁷

In 2017, Gina.S.El-Fecky investigated the effectiveness of polymeric wafer containing ketorolac and lidocaine. 20 patients were selected from the age between 17-30 yrs who required gingivectomy in maxillary anterior region. In group A Coe-Pack was placed after gingivectomy while in group B polymeric wafer containing ketorolac and lidocaine were placed. Pain was assessed by VAS and wound healing was assessed by wound healing index. There was statistically significant difference between both the groups and polymeric wafer showed better healing and less discomfort. Hence polymeric wafer containing ketorolac and lidocaine can be used as an alternative to coe-pack in gingivectomy procedures.¹⁸

In 2021, study was published by Amith Adyanthaya evaluated the efficacy of lidocaine bioadhesive patch for extraction in paediatric patients. Total of 35 patients with age group 8-12 yrs were included in the study and evaluation of patch was done on the basis of onset, duration and pain by visual analogue scale and SEM scale. Age group in higher range irrespective of genders demonstrated less discomfort during extraction using lidocaine patch.

In extraction of firm teeth and Grade I mobility teeth, girls experienced less tolerance to pain. Less pain was perceived with all the extraction of teeth in maxillary arch. Regardless of age, gender and arches, teeth with Grade 2 and Grade 3 mobility were extracted with minimal VAS and SEM score. Hence bioadhesive patch is newer alternative to conventional mode to decrease needle phobia and increase patient comfort.¹⁹

MATERIALS AND METHODS

Study Design:

Prospective, split mouth randomized control trial.

Study Population:

18 patients who were advised orthodontic extraction of bilateral upper premolars in Department of Oral and Maxillofacial Surgery, KLE's V.K. Institute of Dental Sciences, Belagavi and were willing for application of patch were considered for the study.

Inclusion Criteria:

Patients who require bilateral orthodontic extractions of upper premolars

Patients with ASA status I and having normal bleeding & clotting time.

Exclusion Criteria:

Patients unwilling to participate in the study.

Patients who have known history of allergy to the drugs or anesthetics used in the surgical protocol.

Patients on analgesics in the preceding 2 weeks.

Patients with infection or inflammation with upper premolar tooth

CONSENT

After obtaining ethical clearance from the Ethical Committee of the University (Annexure-I), the procedure with its advantages, disadvantages and possible complication were explained to the patients. Written informed consent was obtained from the patients or their close relatives. (Annexure II).

Investigations:

Haemoglobin level

Bleeding time

Clotting time

Orthopantogram

Armamentarium:

Mouth mirror

Moon's probe

Tweezer

2ml Disposable Syringe

Periosteal elevator

Gauze piece

2% Lignocaine hydrochloride infiltration

Transmucosal patch containing 2% lignocaine hydrochloride approximately
2cm²

Extraction forceps

Gloves

Mouth Masks

METHODOLOGY:

Materials: Lidocaine hydrochloride drug was procured from Sigma-Aldrich. PVA, PVP and Polyethylene glycol-400 was obtained from Basic Science Research Centre, KLE University, Belagavi. Distilled water was used throughout the study. All the materials used were biocompatible.

Formulation on transmucosal patch-

The transmucosal patch was prepared by solvent casting technique using glass petri dish having radius of 26 cm². The polymers PVA and PVP were used with concentration of 1.2 gms. The polymers were accurately weighed and dissolved in 10 ml of distilled water. PVA was dissolved in boiled water, while PVP was dissolved in hot water. The solution was then kept on magnetic stirrer for 1 hr. Once the uniformity was obtained, both were added to get a homogenous solution. The polymeric solution was kept on magnetic stirrer for 1 hr at the rate of 300 rpm. Further 10 ml of PEG-400 used as plasticizer. The lidocaine drug was incorporated while mixing the penetration enhancer. After stirring the solution it was poured in the petri dish and covered with funnel for controlled evaporation at room temperature. After drying the patch it was then easily removed from the petri dish and patch used for clinical evaluations. Before the use of patch each time it was sterilized in U.V sterilizer.

Procedure:

Patients who reported to the Department of Oral and Maxillofacial Surgery, KLE V.K. Institute of Dental Sciences, Belagavi, with the need for bilateral

orthodontic extraction of upper premolars and also gave consent to participate in the study were selected

Patients were scheduled for extraction at two separate clinical sessions (one side at a time) and were randomised by computer generated randomization list.

For Study Group:

Transmucosal patch was applied measuring 2cm² both on buccal side and palatal side of the tooth to be extracted. Patch was applied for 5-8 mins according to onset. After application of patch, onset of action, duration of anaesthesia was assessed.

For Control group:

Local infiltration was given both on buccal and palatal aspect of the upper premolar.

Evaluation criteria for the patch:

ONSET OF ANAESTHESIA

Superficial probing: On application of patch or after infiltration if there is loss of sensation of touch is checked with a probe after every 30 sec till anaesthetic effect is achieved.

PAIN ASSESSMENT:

Deep probing: The feeling of the pressure after application of patch or infiltration is checked with a moon's probe, no pain should be present.

Gingival detachment: No pain should be experienced after separation of gums.

Duration: Duration of action will be evaluated till there is disappearance of numbness and will be checked with the Moon's probe

Once the anaesthesia was achieved extraction was carried out.

Postoperatively both the groups were prescribed plain paracetamol s.o.s and VAS was determined

Pain was gauged by Visual Analogue Scale to evaluate postoperative pain as follows:

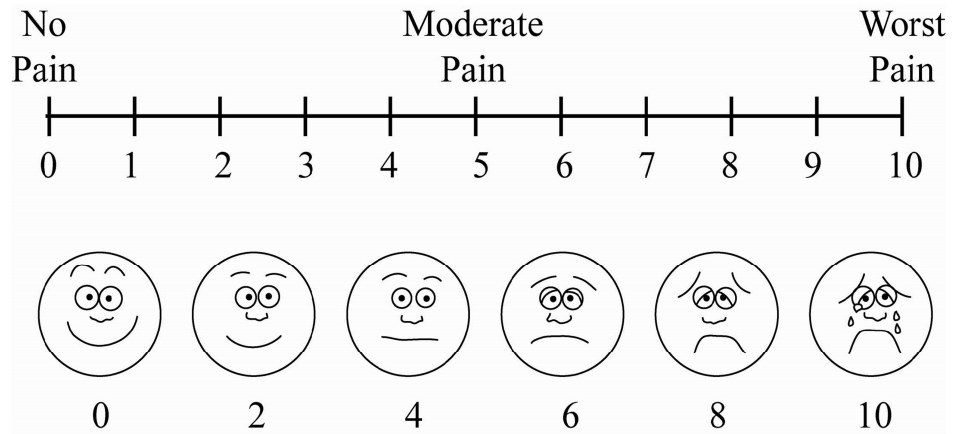





Figure 1. Formulation of Patch



Weighing of the polymer or drug



Uniformity obtained by magnetic stirrer



Lignocaine hydrochloride patch after drying

Figure 2. Armamentarium

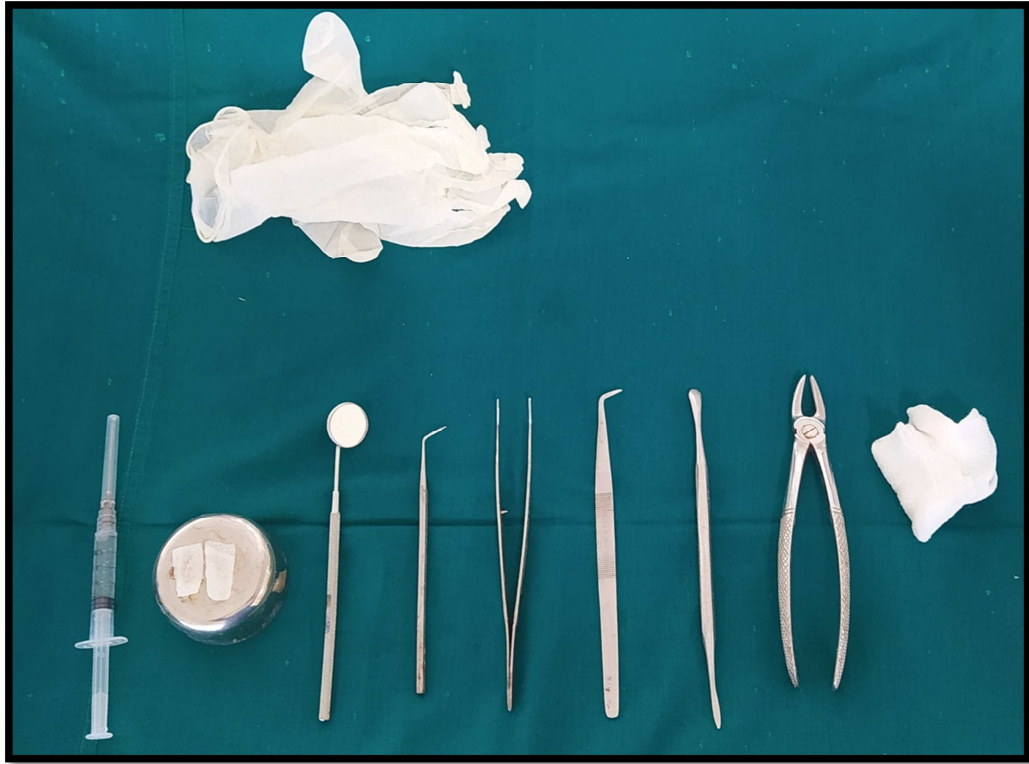
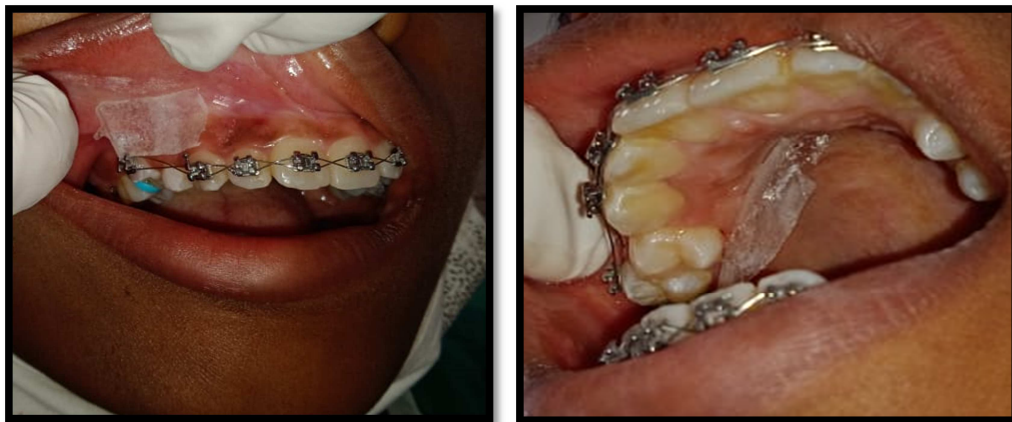

Figure 3: Clinical application:



RESULTS:

To compare the anaesthetic effect of lignocaine infiltration with lignocaine patch, total of 18 patients with bilateral sites were selected, randomization was done by computer generated randomization list. On one side transmucosal lignocaine patch was applied while on other side infiltration with 2% lignocaine was given.

Table No:1- Case Deatils

Sr.no	Age	Sex	onset (min)	application of patch (min)	duration of patch (min)	extraction with patch(tooth number)	VAS	extraction with infiltration (tooth number)	VAS
1	20	F	2.3	5	20	14	0	24	0
2	15	M	2	5	15.3	14	5	24	2
3	15	F	3	5	15	24	3	14	0
4	18	M	3.3	8	25	14	0	24	0
5	12	F	3	5	15	14	3	24	1
6	16	F	3	5	20	14	3	24	0
7	19	F	2.3	5	15	14	3	24	0
8	17	F	2.3	5	20	24	1	14	1
9	17	M	2.3	5	20	14	1	24	0
10	14	M	3	5	20	14	3	24	1
11	15	F	3.3	8	25	24	1	14	0
12	16	F	3	5	20	14	3	24	0
13	14	F	2.3	5	20	14	5	24	1
14	16	F	3.3	8	25	14	0	24	0
15	14	F	3	5	20	14	3	24	0
16	16	M	3	5	15.3	24	5	14	1
17	16	F	2.3	5	20	14	6	24	0
18	15	F	3	5	15	14	0	24	0

The age range which was present in the study was 10-20 yrs with 44.4% of patients present in 10-15 years of age and 55.56% present in 15-20 years of age. There were 6 male and 12 female patients in the study.

Extraction with transmucosal lignocaine patch and infiltration of lignocaine were done in two separate appointments and evaluation of onset, duration of action , anxiety level and pain score were assessed.

Table2: Age wise distribution of patients

Age groups	No of Patients	% of Patients
10-15yrs	8	44.44
16-20yrs	10	55.56
Total	18	100.00
Mean±SD	15.83±1.92	

Figure 1: Age wise distribution of patients

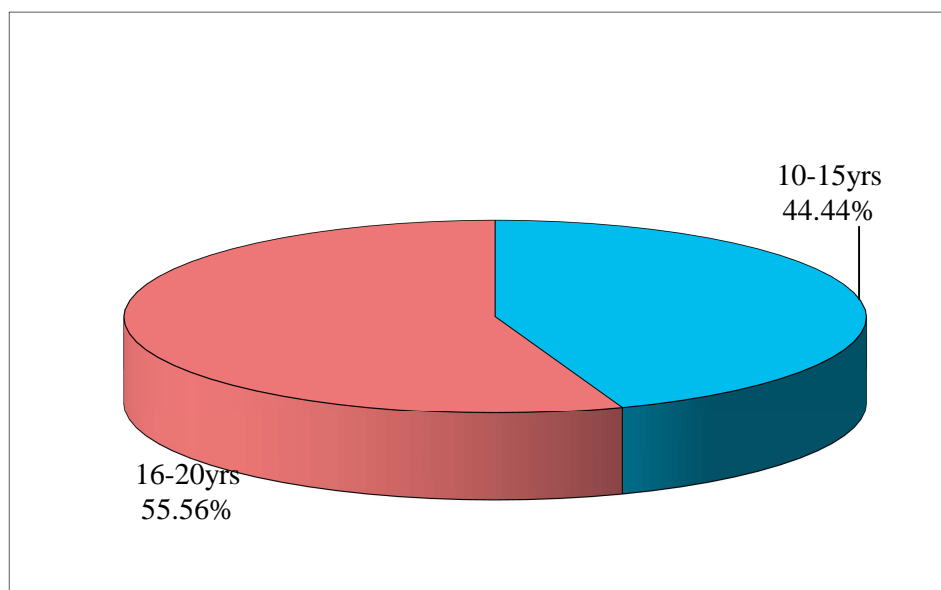


Table 3: Gender wise distribution of patients

Gender	No of Patients	% of Patients
Male	6	33.33
Female	12	66.67
Total	18	100.00

Figure 2: Gender wise distribution of patients

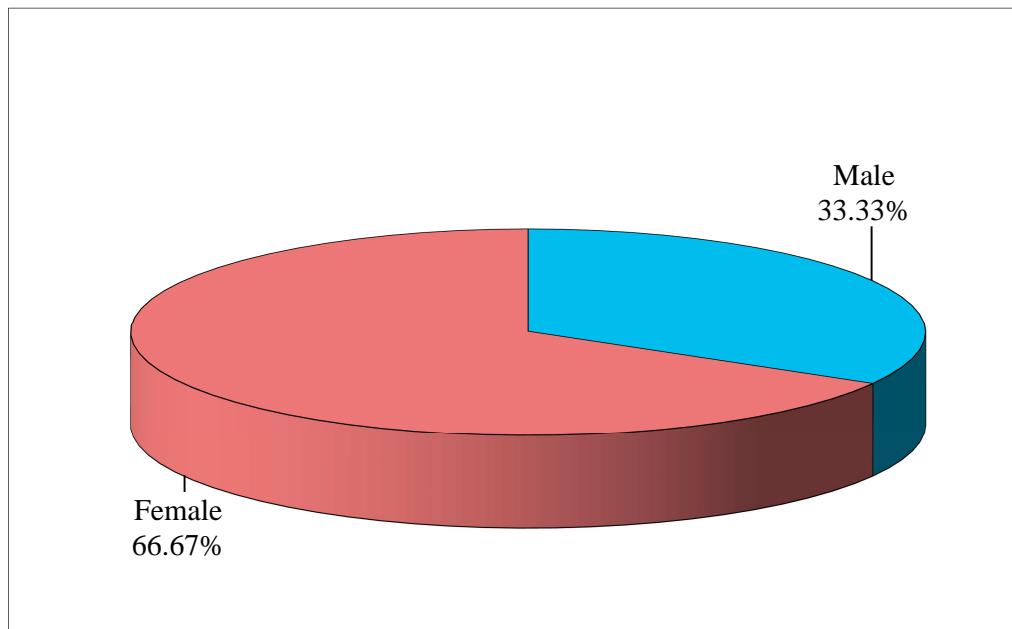
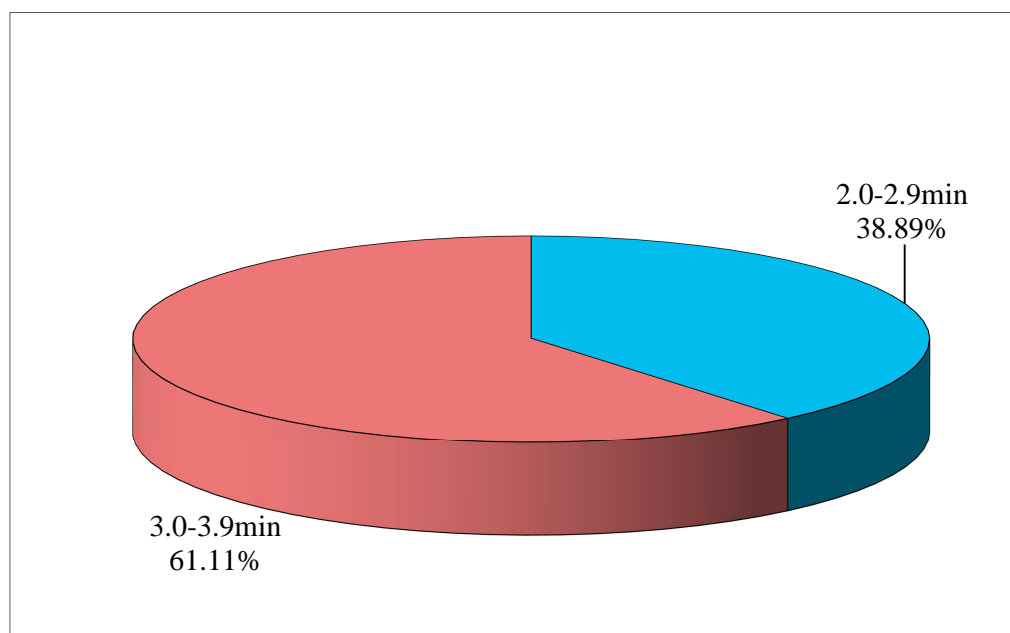


Table 4: Onset (in min) wise distribution of patients

Onset (n min)	No of Patients	% of Patients
2.0-2.9min	7	38.89
3.0-3.9min	11	61.11
Total	18	100.00
Mean±SD	2.76±0.43	

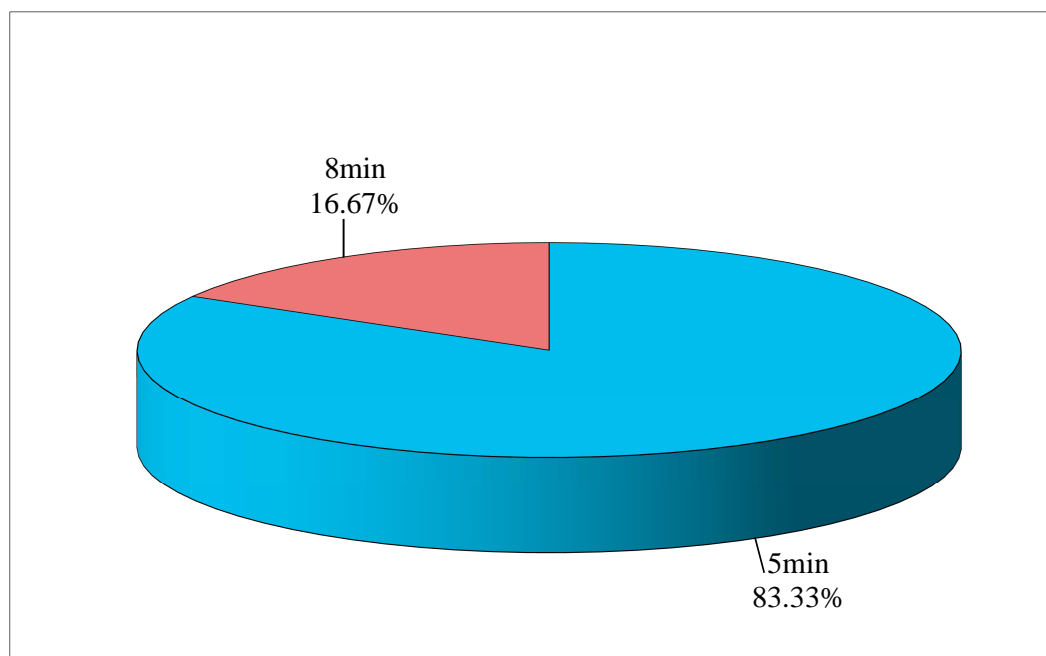
Figure 3: Onset (in min) wise distribution of patients

Onset of action was evaluated on superficial probing i.e after application of patch or after infiltration if there is loss of sensation of touch is checked with a probe after every 30 sec till anaesthetic effect is achieved.

In this study the onset of action in 7 patients was 2-2.9mins (38.89%) while in 11 patients it was 3-3.9 mins(61.11%) with the mean onset of 2.76±0.43.

Table 5: Application of patch (in min) wise distribution of patients

Application of patch (min)	No of patients	% of patients
5min	15	83.33
8min	3	16.67
Total	18	100.00
Mean±SD	5.50±1.15	

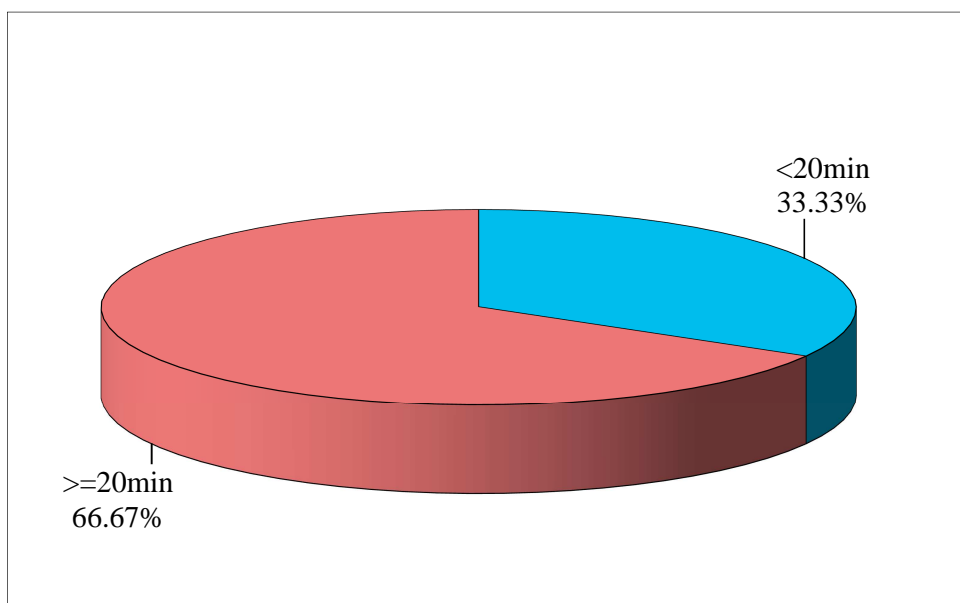
Figure 4: Application of patch (in min) wise distribution of patients

Application of patch was kept for 5 mins in 15 patients while in 3 patients patch was applied for 8 mins as the patients were having pain during deep probing.

Table 6: Duration of patch (in min) wise distribution of patients

Duration of patch	No of patients	% of patients
<20min	6	33.33
>=20min	12	66.67
Total	18	100.00
Mean±SD	19.20±3.50	

Figure 5: Duration of patch (in min) wise distribution of patients



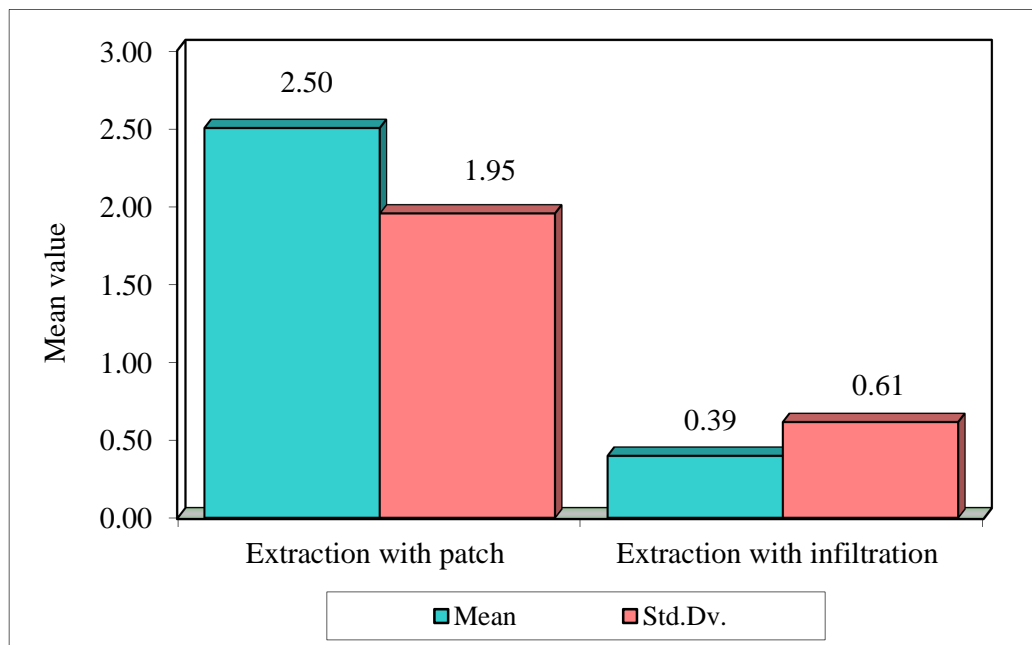
Duration of patch in 6 patients was 15-20 mins (33.33%) while in majority of patients i.e in 12 patients it was 20-30 mins (66.67%).

Table 7: Comparison of extraction with patch and extraction with infiltration with VAS scores by Mann-Whitney U test

Groups	Mean	Std.Dv.	Mean rank	U-value	Z-value	p-value
Extraction with patch	2.50	1.95	24.25			
Extraction with infiltration	0.39	0.61	12.75	58.50	3.2588	0.0011*

*p<0.05

Figure 6: Comparison of extraction with patch and extraction with infiltration with VAS scores



The evaluation for comparison of transmucosal lignocaine patch with infiltration of lignocaine was determined by VAS. From the table 7 it is evident that patient with transmucosal lignocaine patch had more pain after extraction as compared to infiltration anaesthesia.

DISCUSSION:

Control of pain is a clinical challenge faced by all the health care professionals. Management of the pain include various pharmacological therapy and these drugs can be administrated orally, parenterally via different routes and each of the routes has it own advantages and disadvantages. One such method in management of pain in oral surgical procedures include infiltration of local anaesthetic agent before the procedure. However the needle penetration while giving infiltration is itself cause discomfort and uneasy stimuli.¹⁷ Other need for replacing infiltration method is the higher risk of transmission of hepatitis B and HIV due to needle prick injuries. Hence newer methods of drug delivery are attempted in various procedures such as use of topical gels, spray tansmucosal patch with or without the infiltration.¹ The development of transmucosal patch is itself an advancement in drug delivery system.

These patches have been used in various fields of dentistry for multitude purpose such as for extraction procedure, as an anti-inflammatory in wound healing, for pulpectomy or application of sealants, gingevectomy procedures ,root planning, etc.¹⁷ Advantages of the patch being adjustment of the drug dose lessen the systemic side effects and extended retention in oral cavity.

For anesthetic effect in various dental procedures, lignocaine is most commonly used drug. The studies conducted on lignocaine patch has shown good results in procedures like extraction of mobile teeth, gingevectomy, root planning procedures, etc.¹⁷ But the usage of transbuccal lignocaine patch in extraction of firm teeth has shown varied results. Hence in our study we have compared the infiltration of lignocaine with transbuccal lignocaine patch. The patch had similar content of

lignocaine as that of infiltration i.e 2% of 2ml lignocaine (2cm² of patch content approximately 46mg of drug). All the polymers used for preparation of drug were biocompatible.

Several studies are conducted on transbuccal patch containing lidocaine. In USA lignocaine containing patch i.e Denipatch is commercially available since 1996 developed by Novel Pharmaceuticals and used for numerous purpose. Study conducted using dentipatch by Shelly.S et.al for gingival anaesthesia comparing with topical gel showed no significant difference in anesthetic effect and Dentipatch comparatively took longer time to act while adherence to buccal mucosa was also poor.¹¹ Further studies by Elliot et.al and Kathryn et.al showed significant reduction of pain during needle penetration for nerve block with Dentipatch compared to topical gel.^{20, 16} Further studies have developed bioadhesive transbuccal patch so as to increase retention and diffusion of drug at desired site. In our study the patch prepared was mucoadhesive hence was not displaced by saliva.

The transmucosal lignocaine patch was applied both to buccal and palatal surface of the tooth. It was made sure that patch was not displaced from the site of application. After every 30 seconds with the moons probe the anaesthetic effect was checked by superficial probing. Once anaesthesia was achieved patient had numbness over the same region and there was absence of pain on superficial probing. After the onset, the patch still was kept in place and deep probing was done followed by gingival tissue retraction. In our study the mean onset of time of the patch was: 2.76±0.43 and patch was applied for 5-8mins till patient had no pain on deep probing. Once gingival tissue was reflected the patch was removed and extraction of the upper premolar teeth was attempted. In our study all the patient experienced no discomfort

on superficial, deep probing and gingival reflection. But out of 18 patients, 6 patients experienced pain which was determined by visual analogue scale. Comparatively to infiltration 4 patients had mild discomfort. Intra and Post-operatively patient did not have any adverse reaction pertaining to the patch. In the study conducted by Taware et.al the saliva activated bioadhesive system showed onset of anesthesia at 1.5 to 3 minutes while duration of action was about 45 to 50 min and the subjects did have bitter taste due to patch but there was no hypersensitivity reaction noted.¹ I.M.Brook et.al in their study evaluated onset, duration as well as blood lignocaine levels. Patch was applied for 30 mins, onset was 7.4 +/- 3.4 (S.D), peak level were attained at mean of 11+/-3.7 min and duration of action was 26.4+/- 2 8.9 min. Plasma lignocaine concentrations were very low i.e 7-94ng/ml, hence negligible systemic effect.⁹

Pain perception was assessed on the basis of visual analogue scale. This scale is frequently used for assessing pain postoperatively and the point is marked by patient themselves that they feel represents their pain perception of their current state. In our study, patient with application of patch had no pain with superficial, deep probing and gingival detachment but had pain after extraction as compared to infiltration. Comparison of VAS score was done using a Mann Whitney U test, p value 0.0011 was considered statistically significant. In the study by Amith Adyanthaya et.al extraction of pediatric patients were done by lidocaine transbuccal patch and evaluation was done by SEM and VAS. In their study pain perception was experienced more in extraction of firm and grade 1 mobile teeth as compared to grade 2 and 3 mobile teeth.¹⁹ In the study by Kavita.Rai et.al extraction of tooth were done in pediatric age group using lignocaine and benzocaine transmucosal patch. For both the patches extraction was painless in grade 3 mobile teeth. The assessment was done by VAS and SEM scale. With both the scales it was concluded that patients

experienced less discomfort with lignocaine patch compared to benzocaine and VAS score was less for the same. But patients had pain while extracting grade 1 and grade 2 mobile teeth. Hence the authors infer that the patch should be used in minimally invasive procedures and as an adjunctive method in invasive procedure to reduce pain perception and discomfort cause by needle during infiltration.¹⁷

There are numerous studies on the lignocaine patch used as an adjuvant to infiltration anaesthesia to decrease the pain perception. These patches however can be used in grade 3 mobile teeth. In our study we selected maxillary arch for extraction as it is more porous and cancellous and hence have better diffusion. But the patients still had pain in our study hence more studies should be conducted on diffusion of lignocaine from the patch. More in vitro studies should be carried out about characterization of the patch and its use in minor oral surgical procedures. Although the studies showed effectiveness in grade 3 mobility teeth, the patch can be used in geriatric population as the tolerance for pain due to needle injection is less. Also the patch can be used in procedures like biopsies, or treatment of ulcers.

There is major correlation between anxiety and dental treatment pain. Anxiety aggravates the pain perception resulting in decreased patient compliance. In the study by Santosh et.al , there was positive correlation between anxiety and pain during dental extraction.²¹In our study, the selected patients who underwent orthodontic extractions were in the age group from 10-20 yrs and were less anxious and tolerating infiltration anaesthesia well. The modified dental anxiety scale showed score between 1-2 for all the patients hence the anxiety level cannot be assessed in the study properly.

The short comings of this study was not determining pharmacokinetics of the patch and in vitro assessment hence proper anaesthesia was not achieved resulting in pain postoperatively. Further studies should be conducted about characterization and diffusion of drug from patch so it can be useful in minor procedures and health care professionals can avoid the chance of needle prick injuries leading to fatal diseases. The study should have been conducted on patients who were anxious and fearful of injection. Also, further this study will be continued for its in-vitro assessment, finally to make it more feasible for our patients undergoing non-invasive minor surgical procedures.

CONCLUSION

Lidocaine mucoadhesive patches have an key role in minimizing fear due to needle injection and avoidance of needle prick injury. However studies have shown less diffusion of drug for multiple use in invasive procedures. In our study too maxillary arch was selected so diffusion of drug can achieve proper anaesthesia. Even the drug concentration at the site was more diffusion was less hence patient perceived discomfort postoperatively.

As the development of mucoadhesive patches has diminish the pain perception of soft tissue they can be used in treatment of oral lesions and during biopsy procedures as the concentration of drug can also be controlled. Also usage of patches as an adjuvant to infiltration has also alleviate the pain perception intra and postoperatively. Further studies should be concluded on patients who are anxious and fearful of needle injection so as to properly assess and correlate the anxiety scale and visual analogue scale. Also studies should be conducted on patch characterization so it will diffuse properly and have same depth of effect such as conventional method. Studies should also be conducted to differentiate pain perception due to needle injection or pressure of injecting solution in tissue spaces. Newer advances in drug delivery system has really assisted health care professionals in comforting the patient and avoiding needle prick injuries.

REFERENCES:

1. Taware CP, Mazumdar S, Pendharkar M, Adani MH, Devarajan P V. A bioadhesive delivery system as an alternative to infiltration anesthesia. *Oral Surg Oral Med Oral Pathol Oral Radiol Endod.* 1997;84(6):609–15.
2. Nidhi M, Patro MN, Kusumvalli S, Kusumdevi V. Development of transmucosal patch loaded with anesthetic and analgesic for dental procedures and in vivo evaluation. *Int J Nanomedicine.* 2016;11:2901–20.
3. Bhalla J, Meechan JG, Lawrence HP, Grad HA, Haas DA. Effect of time on clinical efficacy of topical anesthesia. *Anesth Prog.* 2009;56(2):36–41.
4. Ram D, Peretz B. Administering local anaesthesia to paediatric dental patients - Current status and prospects for the future. *Int J Paediatr Dent.* 2002;12(2):80–9.
5. Jaipakdee N, Pongjanyakul T, Limpongsa E. Preparation and characterization of poly (vinyl alcohol)-poly (vinyl pyrrolidone) mucoadhesive buccal patches for delivery of lidocaine HCL. *Int J Appl Pharm.* 2018;10(1):115–23.
6. Abu-Huwaij R, Assaf S, Salem M, Sallam A. Potential mucoadhesive dosage form of lidocaine hydrochloride: II. In vitro and in vivo evaluation. *Drug Dev Ind Pharm.* 2007;33(4):437–48.
7. Gudin J, Nalamachu S. Utility of lidocaine as a topical analgesic and improvements in patch delivery systems. *Postgrad Med [Internet].* 2020;132(1):28–36. Available from: <https://doi.org/10.1080/00325481.2019.1702296>

8. Pastore MN, Kalia YN, Horstmann M, Roberts MS. Transdermal patches: History, development and pharmacology. *Br J Pharmacol*. 2015;172(9):2179–209.
9. Brook IM, Tucker GT, Tuckley EG, Boyes RN. A lignocaine patch for dental analgesia safety and early pharmacology. *J Control Release*. 1989;10(2):183–8.
10. Annigeri RG, Article R. *Research And Reviews : Journal Of Pharmacy And Mucoadhesive Patch : A Novel Drug Delivery* . 2014;3(2):56–62.
11. Stecker SS, Swift JQ, Hodges JS, Erickson PR. Should a mucoadhesive patch (DentiPatch) be used for gingival anesthesia in children? *Anesth Prog*. 2002;49(1):3–8.
12. Takeuchi K, Watanabe M, Yanagi M, Murakami I, Hosono H, Nishizawa S, et al. In vitro and clinical evaluation of an oral mucosal adhesive film containing indomethacin. *Yakugaku Zasshi*. 2008;128(12):1791–5.
13. Shemer A, Amichai B, Trau H, Nathansohn N, Mizrahi B, Domb AJ. Efficacy of a mucoadhesive patch compared with an oral solution for treatment of aphthous stomatitis. *Drugs R D*. 2008;9(1):29–35.
14. Das R. Effective mucoadhesive buccal patches: Wound healing activity of curcumin & Centella asiatica extract compared to rhEGF. *Int J Pharm Pharm Sci*. 2011;3(1):97–100.
15. Eslamian L, Borzabadi-Farahani A, Edini HZ, Badiie MR, Lynch E, Mortazavi A. The analgesic effect of benzocaine mucoadhesive patches on orthodontic pain caused by elastomeric separators, a preliminary study. *Acta Odontol Scand*. 2013;71(5):1168–73.

16. Hersh E V., Houpt MI, Cooper SA, Feldman RS, Wolff MS, Levin LM. Analgesic efficacy and safety of an: Intraoral lidocaine patch. *J Am Dent Assoc* [Internet]. 1996;127(11):1626–34. Available from: <http://dx.doi.org/10.14219/jada.archive.1996.0098>
17. Rai K, Hegde AM, Jacob M, Charyulu RN. Comparative Evaluation of the Efficacy of Lignocaine and Benzocaine Patches for Various Dental Treatments in Children. *J Heal Allied Sci NU*. 2014;04(01):028–34.
18. El-Feky GS, Abdulmaguid RF, Zayed GM, Kamel R. Mucosal co-delivery of ketorolac and lidocaine using polymeric wafers for dental application. *Drug Deliv* [Internet]. 2018;25(1):35–42. Available from: <https://doi.org/10.1080/10717544.2017.1413445>
19. Adyanthaya A, K R, Sivaraman A, A GG, K. NA, Aloysious R, et al. Evaluation of Efficacy of Customized Lidocaine Bioadhesive Anaesthetic Patch for Extraction of Primary Tooth - An Invitro Study. *J Evol Med Dent Sci*. 2021;10(24):1830–4.
20. Kreider KA, Stratmann RG, Milano M, Agostini FG, Munsell M. Reducing children’s injection pain: Lidocaine patches versus topical benzocaine gel. *Pediatr Dent*. 2001;23(1):19–23.
21. Santhosh Kumar MP. Relationship between dental anxiety and pain experience during dental extractions. *Asian J Pharm Clin Res*. 2017;10(3):458–61.

ANNEXURE - I

ETHICAL CLEARANCE



Research and Ethics Committee
KLE V K INSTITUTE OF DENTAL SCIENCES
KLE University



Accredited 'A' Grade by NAAC

Placed in Category 'A' by MHRD (GoI)

Nehru Nagar, Belagavi - 590 010, Karnataka State

☎: 0831-2470362

Web: <http://www.kledental-bgm.edu.in>

FAX: 0831-2470640

E-mail: principal@kledental-bgm.edu.inSI. No. : **1343****CERTIFICATE***This is to Certify that the synopsis titled*

*Assessment of transmucosal patch as an alternative
 to infiltration anesthesia in orthodontic extraction*

A split mouth study. Submitted by

Dr. Chaitrali S. Sant P. G. Student /

Staff, Guided by Dr. Sanjay Rao from Department of

Oral and Maxillofacial surgery has been critically evaluated by

committee members and granted ethical clearance to conduct the above

mentioned study

Date :

Member Secretary
 Research and Ethical Committee
 KLEVK Institute of Dental Sciences
 Belagavi
 Research and Ethical Committee
 KLEVK Institute of Dental Sciences
 BELAGAVI

Chairman
 Research and Ethical Committee
 KLEVK Institute of Dental Sciences
 Belagavi
 Research and Ethical Committee
 KLEVK Institute of Dental Sciences
 Belagavi

ANNEXURE-II

KLE'S V.K. INSTITUTE OF DENTAL SCIENCES, BELALAVI - 10.

DEPARTMENT OF ORAL & MAXILLOFACIAL SURGERY

CONSENT FORM

**ASSESSMENT OF TRANSMUCOSAL PATCH AS AN ALTERNATIVE TO
INFILTRATION ANESTHESIA IN ORTHODONTIC EXTRACTION :A SPLIT
MOUTH STUDY**

Time :a.m / p.m

I, _____ aged _____ years have been informed about my involvement in the study.

I agree to give my personal details like Name Age, Sex, Address, Past dental and any other details required for the study to the best of my knowledge.

I will cooperate with the surgeon for examination and also for various investigations.

I permit the operator to utilize the information given by me and the results obtained from this study for presentation and publication.

I permit the surgeon to take my photographs to utilize it for the study and presentation purpose.

I am participating in this study with my own wish and will and the dentist has explained the nature and the effect of the surgical procedure in my vernacular language.

I have read and understood the above information given by surgeon about the study.

Name :

Date:

Signature:

Mob. No:

Name of doctor with signature

KLE'S V.K. INSTITUTE OF DENTAL SCIENCES, BELALAVI - 10.

DEPARTMENT OF ORAL & MAXILLOFACIAL SURGERY

CONSENT FORM

ASSESSMENT OF TRANSMUCOSAL PATCH AS AN ALTERNATIVE TO
INFILTRATION ANESTHESIA IN ORTHODONTIC EXTRACTION :A SPLIT
MOUTH STUDY

मी वय सहभागी
होत असलेल्या वरील संशोधना बद्दल मला समजत असलेल्या भाषेत सर्व माहिती दिली
आहे

1. मी माझी माहिती जसे की नांव , वय , लिंग, पुर्व दंत उपचार महिती आणि इतर
लागणारी माहिती देण्यास तयार आहे.
2. माझी दंत वैद्याकीय तपासणी करणार असल्याची मला कल्पना आहे आणि
दिलेली माहिती मला समजली आहे.
3. मी या संशोधना बद्दल माहिती विचारू शकतो/शकते.
4. मी परिक्षणा वेळी दंत वैद्याकानी दिलेल्या सुचना पाळेंन.
5. मी दिलेली माहिती आणि येणारा निकल वापरण्यास, मांडण्यास आणि प्रकाशीत
करण्यास पुर्ण सम्मती देत आहे.
6. जरी एखाद्या एजेन्सीने मी दिलेली माहिती वापरली तरी मी कोणतीही फर मागणी
करणार नाही.
7. मी या संशोधनात स्वइच्छेने भाग घेण्याची परवानगी देत आहे .
8. कोणत्याही कारणास्तव माझा सहभाग मी माघारी घेऊ शकतो/ शकते.
9. दंतवैद्यकाने दिलेली वरील महिती मी वाचली आहे आणि ती मला समजली आहे.
म्हणुन मी या अर्जावर नोंदणी व स्वाक्षरी केली आहे.

दंतवैद्यकाचे नांव : पालकांची सही :

दंतवैद्यकाची स्वाक्षरी : स्थळ :

तारीख :

KLE'S V.K. INSTITUTE OF DENTAL SCIENCES, BELALAVI - 10.

DEPARTMENT OF ORAL & MAXILLOFACIAL SURGERY

CONSENT FORM

ASSESSMENT OF TRANSMUCOSAL PATCH AS AN ALTERNATIVE TO
INFILTRATION ANESTHESIA IN ORTHODONTIC EXTRACTION :A SPLIT
MOUTH STUDY

ನಾನು..... ವಯಸ್ಸಿನ ವ್ಯಕ್ತಿಯಾಗಿದ್ದು ನನಗೆ ತಿಳಿದಿರುವ ಭಾಷೆಯಲ್ಲಿ, ಈ ಸಂಶೋಧನೆಯಲ್ಲಿ ನನ್ನ ಭಾಗವಹಿಸುವುದರ ಬಗ್ಗೆ ನನಗೆ ತಿಳಿಸಲಾಗಿದೆ

೧. ನಾನು ಕೆಲವು ಖಾಸಗಿ ಮಾಹಿತಿಗಳಾದ ಹೆಸರು, ವಯಸ್ಸು, ಲಿಂಗ, ವಿಳಾಸ, ಹಲ್ಲಿನ ತಪಾಸಣೆಯ/ ಚಿಕಿತ್ಸೆಯ ಮಾಹಿತಿಯನ್ನು ಮತ್ತು ಈ ಅಧ್ಯಯನಕ್ಕಾಗಿ ಬೇಕಾದ ಎಲ್ಲ ವಿವರಗಳನ್ನು ಕೊಡಲು ಒಪ್ಪಿಕೊಳ್ಳುತ್ತೇನೆ.

೨. ನನ್ನ ರೋಗದ ಪರಿಷ್ಕಿತಿಗೆ ಬೇಕಾದ ಚಿಕಿತ್ಸೆಯ ವಿಧಾನಗಳನ್ನು ನನಗೆ ಸಂಪೂರ್ಣವಾಗಿ ತಿಳಿಸಲಾಗಿದೆ.

೩. ನನಗೆ ನೀಡುವ ಚಿಕಿತ್ಸೆ, ಅದರಿಂದ ಉಂಟಾಗುವ ತೊಂದರೆ ಹಾಗೂ ಅದಕ್ಕಾಗಿ ಬೇಕಾಗುವ ಚಿಕಿತ್ಸೆಗಳ ಬಗ್ಗೆ ವೈದ್ಯರನ್ನು ಪ್ರಶ್ನಿಸಲು ಸಾಕಷ್ಟು ಅವಕಾಶಗಳನ್ನು ನೀಡಲಾಗಿರುತ್ತದೆ.

೪. ಈ ಅಧ್ಯಯನಕ್ಕಾಗಿ ನನ್ನ ದಂತ ವೈದ್ಯರು ನನ್ನನ್ನು ಕರಡಾಗಲೆಲ್ಲ, ನಾನು ಬರುವನೆಂದು ಒಪ್ಪಿಕೊಂಡಿರುತ್ತೇನೆ.

೫. ನಾನು ನನ್ನ ದಂತ ವೈದ್ಯರಿಗೆ ನನ್ನ ಬಗ್ಗೆ ನೀಡಿರುವ ಮಾಹಿತಿಯನ್ನು, ಈ ಅಧ್ಯಯನದ ಫಲಿತಾಂಶದಲ್ಲಿ ಅಳವಡಿಸಿ ಪ್ರಸ್ತುತಿಸಲು ಮನವಿ ನೀಡಿರುತ್ತೇನೆ.

೬. ನಾನು ನನ್ನ ದಂತ ವೈದ್ಯರು ನನಗೆ ಈ ಅಧ್ಯಯನದಲ್ಲಿ ನೀಡುವ ಸೂಚನೆಗಳನ್ನು ತಪ್ಪದೆ ಪಾಲಿಸುತ್ತೇನೆ.

೭. ಯಾವುದೇ ಕಾರಣದಿಂದಾಗಿ, ನಾನು ಈ ಅಧ್ಯಯನದಲ್ಲಿ ಭಾಗವಹಿಸಲು ಅಸಫಲನಾದರೆ/ ಅಸಫಲನಾದರೆ, ಈ ಅಧ್ಯಯನದಿಂದ ಹೊರಬರಲು ನನಗೆ ಅನುಮತಿ ನೀಡಲಾಗಿದೆ.

ಈ ಮೇಲ್ಕಂಡ ಮಾಹಿತಿಯನ್ನು ನಾನು ಓದಿ ತಿಳಿದುಕೊಂಡಿದ್ದೇನೆ ಹಾಗೂ ನಾನು ಈ ಅರ್ಜಿಯಲ್ಲಿ ಸಹಿ ಮಾಡಿದ್ದೇನೆ.

ದಂತ ವೈದ್ಯ ರಹೆಸರು:

ಅಭ್ಯರ್ಥಿಯ ಹೆಸರು ಮತ್ತು ಸಹಿ

ವಿಳಾಸ:

ದೂರವಾಣಿ ಸಂಖ್ಯೆ:

ದಂತ ವೈದ್ಯರ ಸಹಿ:

ANNEXURE – III

PLAGIARISM CHECK

Scientific Correspondence and Review Committee



KLE VK Institute of Dental Sciences

A Constituent Unit of KLE Academy of Higher Education and Research
(Deemed-to-be-University u/s 3 of the UGC Act, 1956)
Nehru Nagar, Belagavi - 590 010, Karnataka State

Accredited 'A' Grade by NAAC (2nd Cycle)

Placed in Category 'A' by MHRD (GoI)

☎: 0831-2470362

Web: <http://www.kledental-bgm.edu.in>

FAX: 0831-2470640

E-mail: principal@kledental-bgm.edu.in

Date : 30.12.2021

Serial No. : 078

PLAGIARISM CHECK REPORT

Name of the Applicant : DR. CHAITRALI SANTI
UG / PG / Ph.D / Staff : POSTGRADUATE
Batch & Year : 2019-22
Department : ORAL AND MAXILLOFACIAL SURGERY

The soft copy of Research Work / Manuscript by DR. CHAITRALI SANTI entitled
" ASSESSMENT OF TRANSMUCOSAL PATCH AS AN ALTERNATIVE
TO INFILTRATION ANESTHESIA IN ORTHODONTIC EXTRACTION: ASPKIT"
MOUTH STUDY
under the guidance of DR. SANJAY S. P.A.O. has been submitted for
Anti-Plagiarism check to the Scientific Correspondence & Review Committee of KLE VK
Institute of Dental Sciences using "Turn-it-in" software.

The scan has been carried out and the scanned output reveals a Similarity Index of
..... 0%, which is within / not within the acceptable limits of 10% as per
the UGC guidelines.

Member Secretary
Scientific Correspondence and Review Committee
KLEVK Institute of Dental Sciences
KAHER-Belagavi

Chairman
Scientific Correspondence and Review Committee
KLEVK Institute of Dental Sciences
KAHER - Belagavi

ANNEXURE – IV

BIostatISTICS CERTIFICATE



KLE V.K. Institute of Dental Sciences

(A Constituent unit of KLE Academy of Higher Education & Research
Deemed-to-be-University u/s 3 of the UGC Act, 1956)
Nehru Nagar, Belagavi-590 010 INDIA

Re-Accredited 'A' grade by NAAC (2nd Cycle) & Placed in Category 'A' by MHRD (GoI)

Phone : 0831-2470362
FAX: 0831-2470640

Web: <http://www.kledental-bgm.edu.in>
E-mail: principal@kledental-bgm.edu.in



Biostatistics Clearance Certificate

This is to certify that the Biostatistics aspect of the Dissertation / Research work of **Dr. CHAITRALI SANT**, Post Graduate Student, under the guidance of **Dr. SANJAY RAO M.D.S**, Professor, Department of Oral and Maxillofacial Surgery, entitled “Assessment of transmucosal patch as an alternative to infiltration anaesthesia in orthodontic extraction: A Split-Mouth Study” has been done under my guidance and considered satisfactory.

Place: Belagavi

Date: 06/12/2021

Name & Signature of Biostatistician

(Dr. S. B. Javali)

ANNEXURE – V

MAIN CHART

Sr.no	Age	Sex	onset (min)	application of patch (min)	duration of patch (min)	extraction with patch(tooth number)	VAS	extraction with infiltration (tooth number)	VAS
1	20	F	2.3	5	20	14	0	24	0
2	15	M	2	5	15.3	14	5	24	2
3	15	F	3	5	15	24	3	14	0
4	18	M	3.3	8	25	14	0	24	0
5	12	F	3	5	15	14	3	24	1
6	16	F	3	5	20	14	3	24	0
7	19	F	2.3	5	15	14	3	24	0
8	17	F	2.3	5	20	24	1	14	1
9	17	M	2.3	5	20	14	1	24	0
10	14	M	3	5	20	14	3	24	1
11	15	F	3.3	8	25	24	1	14	0
12	16	F	3	5	20	14	3	24	0
13	14	F	2.3	5	20	14	5	24	1
14	16	F	3.3	8	25	14	0	24	0
15	14	F	3	5	20	14	3	24	0
16	16	M	3	5	15.3	24	5	14	1
17	16	F	2.3	5	20	14	6	24	0
18	15	F	3	5	15	14	0	24	0