
**“A COMPARATIVE ANALYSIS OF EFFICACY OF
INTRALESIONAL MUMPS MEASLES RUBELLA
VACCINE VERSUS 5-FLUOROURACIL IN THE
TREATMENT OF PALMOPLANTAR WARTS – A
RANDOMISED CONTROL TRIAL.”**

By

REG NO: BT0119002

Dissertation

*Submitted to the
KAHER, Belagavi, Karnataka
In partial fulfillment
of the requirements for the degree of*

M.D.

in

**DEPARTMENT OF DERMATOLOGY,
VENERELOGY AND LEPROSY**

**DEPARTMENT OF DERMATOLOGY,
VENERELOGY AND LEPROSY,
JAWAHARLAL NEHRU MEDICAL COLLEGE,
BELAGAVI, KARNATAKA.**

APRIL – 2022

**KLE ACADEMY OF HIGHER EDUCATION AND RESEARCH,
BELAGAVI, KARNATAKA**

**Endorsement By The Hod, Principal/Head Of
The Institution**

This is to certify that the dissertation entitled “A COMPARATIVE ANALYSIS OF EFFICACY OF INTRALESIONAL MUMPS MEASLES RUBELLA VACCINE VERSUS 5-FLUOROURACIL IN THE TREATMENT OF PALMOPLANTAR WARTS – A RANDOMISED CONTROL TRIAL.” is a bonafide research work done by **REG NO: BT0119002.**

Dr. A. M. PANDIT MD
Professor & Head
Department of Dermatology,
Venereology and Leprosy
J.N. Medical College
Nehru Nagar, Belagavi- 590010

Dr. N. S. Mahantshetti MD
Principal
J.N. Medical College
Nehru Nagar,
Belagavi- 590010

Date:
Place: Belagavi

Date:
Place: Belagavi

PLAGIARISM ACCEPTED LETTER


KLE **JAWAHARLAL NEHRU MEDICAL COLLEGE** 
(Recognized by Medical Council of India, New Delhi)
Accredited 'A' Grade by NAAC (2nd Cycle) Placed in Category 'A' by MHRD (Govt)
Nehru Nagar, Belagavi- 590 010, Karnataka, INDIA
☎ 0831 - 2471350 📠 0831 - 2470759 🌐 www.jnmc.edu ✉ principal@jnmc.edu
Ref No: MDC/PG/ Date: 11-11-2021.

ACCEPTANCE LETTER

The softcopy of thesis entitled: "A COMPARATIVE ANALYSIS OF EFFICACY OF INTRALESIONAL MUMPS, MEASLES, RUBELLA (MMR) VACCINE VERSUS 5-FLUOROURACIL (5-FU) IN THE TREATMENT OF PALMOPLANTAR WARTS – A RANDOMIZED CONTROL TRIAL" has been submitted for Anti-Plagiarism check through Turnitin software. The scan has been carried out and the scanned output reveals a match percentage of 03% which is within the acceptable limits of 10% as per the guidelines given by UGC.

Guide.




Dr. (Mrs.) N.S. Mahantashetti,
Chairperson-Antiplagiarism Committee &
Principal,
J. N. Medical College, Belagavi.

To,
Reg. No. **BT0119002**.
Postgraduate Student,
2019-20 Batch,
Department of Skin & VD,
J. N. Medical College, Belagavi.

LIST OF ABBREVIATIONS USED

Sl. No.	Abbreviation	Expansion
1	CMI	Cell mediated immunity
2	HPV	Human Papilloma Virus
3	5-FU	5-Fluorouracil
4	MMR	Mumps Measles Rubella
5	PPD	Purified Protein Derivative
6	BCG	Bacillus-Calmette-Guerin
7	HIV	Human Immunodeficiency Virus
8	PCR	Polymerase Chain Reaction
9	Er:YAG	Erbium:yttrium aluminium garnet
10	Nd:YAG	Neodymium doped: yttrium aluminium garnet
11	MAL-PDT	Methyl amino levunilate photodynamic therapy
12	DPC	Diphencyprone
13	UV	Ultraviolet
14	DPCP	Diphenylcyclopropenone
15	DNCB	Dinitrochlorobenzene
16	SADBE	Squaric acid dibutylester
17	VAS	Visual Analogue Scale
18	PWA	Physician's Wart Assessment

ABSTRACT

INTRODUCTON: Viral warts are cutaneous and sometimes mucosal lesions caused by various strains of Human Papilloma Viruses which may occur as cutaneous as well as mucosal lesions.¹ Palmoplantar warts are quite resistant to treatment because of their endophytic growth pattern, increased viral load and very thick cornified layer.² Treating multiple palmoplantar warts is a challenge as the results of the current ablative treatment modalities leads to pain, temporary immobility, secondary infections and scarring.³

It has been found that cell-mediated immunity (CMI) plays a major role in wart resolution which highlights the need for immune protection against Human Papilloma Virus (HPV) infection and has directed attention towards stimulation of the patient's immune system, particularly CMI to eradicate viruses. So, treatment modalities using immunotherapeutic methods are being increasingly used to overcome drawbacks in treatment of warts.⁴

5-floururacil (5FU) is an antimetabolite drug that inhibits DNA and RNA synthesis and may also function as an immunomodulatory drug. 5FU suppresses cell division and cause cell cycle arrest.² This mechanism of action allows intralesional 5FU to be utilized in the treatment of viral warts caused by Human Papilloma Virus (HPV).²

Intralesional injection of 5FU permits higher drug concentrations throughout the lesion².

Intralesional Mumps Measles Rubella (MMR) vaccine immunotherapy employs the ability of the immune system to recognize viral antigens that induces a delayed type hypersensitivity reaction not only to the antigen, but also against the Human

Papilloma virus, thereby increasing the ability of the immune system to recognize and clear HPV. Consequent to this, the stimulated immune response clears all the lesions on other body sites along with locally treated lesions. Immunotherapy using intralesional MMR vaccine has been found useful in treating common warts especially in children.⁵

AIMS AND OBJECTIVES: To evaluate the efficacy of intralesional Mumps Measles Rubella (MMR) Vaccine versus 5-Flourouracil(5-FU) in the treatment of palmoplantar warts.

MATERIALS AND METHODS: This was a one-year hospital based randomized control trial on 36 patients who were clinically diagnosed to have palmoplantar warts. Patients were divided into groups MMR and 5-FU group respectively, using a randomization chart. Patients in the MMR group were given 0.25ml of MMR vaccine which was injected intralesionally and was repeated at 2 weekly intervals until complete clearance or maximum 6doses. Patients in 5FU group was given a solution of 5FU+Lidocaine+Epinephrine up to maximum 6 injections intralesionally which was given at 2 weekly intervals until complete clearance or maximum 6 doses. On each visit the lesions were photographed and measured using Vernier caliper.

RESULTS: Out of 18 patients in 5FU group,1(5.56%) patient had complete resolution in 6th week,4(22.22%) patients in the 8th week, but 11(61.11%) patients had residual warts at the end of the treatment period. Out of 18 patients in MMR group,7(38.89%) patients had complete resolution of warts by 4thweek, 6(33.33%) patients by 6thweek and 5(27.78%) patients by 8thweek. All (100%) patients had complete resolution of warts by the end of the study period in the MMR group.

CONCLUSION: Our study included a total of 36 patients who were clinically diagnosed as having palmoplantar warts. These 36 patients were divided into two groups of 18 each using a randomization chart. The male to female ratio in our study was 2:1. The age of the subjects ranged from 14 to 56 years, mean age being 26.58 +/- 9.47 years.

In our study (n=36) only patients with palmoplantar warts were included. A total of 18 (50%) patients had palmar warts, of which 11(61.11%) patients belonged to 5-FU group (n=18) and 7(38.89%) patients belonged to MMR group (n=18).

A total of 17(47.22%) patients had plantar warts, out of which 7(38.89%) patients belonged to 5-FU group (n=18) and 10(55.56%) patients belonged to MMR group (n=18).

Only one (2.78%) patient had both palmar and plantar warts.

In our study (n=36), pain during injection was seen in all patients (100%) belonging to both MMR(n=18) and 5-FU groups (n=18). Hyperpigmentation around the lesions was seen in 4(22.22%) patients belonging to the 5-FU group. No other adverse effects were noted in our study.

In our study, it was found that MMR vaccine is a better treatment modality than 5-FU.

5-FU is an antimetabolite drug that causes cell cycle arrest, whereas MMR is an immunotherapeutic drug that induces the body's own immune response against HPV, thus helping in clearing HPV laden cells. 5-FU has a very localised, cytotoxic effect on the HPV laden cells whereas MMR vaccine induces a delayed type of hypersensitivity which helps in clearing the HPV laden cells. We have postulated that

because of this difference in the mechanism of action, MMR vaccine showed better efficacy than 5-FU in this study.

When comparing immunotherapeutic methods with cytotoxic methods, it is found that scarring is seen in 30%¹⁴⁵ subjects, recurrence of warts in 30%¹⁴⁵ and pain leading to morbidity is seen in 64%¹⁴⁵ patients while using ablative methods to treat warts, whereas these adverse effects are not seen while using immunotherapy to treat warts.

The debilitation caused due to treatment of palmoplantar warts with ablative methods can lead to difficulty in doing daily activities. Hence, the need for treatment modalities that cause less pain. With the advent of immunotherapy treatment of warts and the outcome has improved significantly.

Hence, we can conclude that immunotherapy is a safe, effective and cheap option for treatment of warts, especially palmoplantar warts.

The limitation of our study was that the sample size was small (n=36) and follow up of the patients beyond 12 weeks of study period was not done, so the rate of recurrence of warts in the MMR and 5-FU groups could not be compared and also, only palmoplantar warts were included in our study, so the effects of these therapeutic options on other types of warts could not be evaluated. Hence, trials with larger sample size and ones which include different variants of warts are required to further evaluate the effects of MMR vs 5-FU in the treatment of warts.

TABLE OF CONTENTS

Sl. No.	Particulars	Page No.
1.	INTRODUCTION	1-2
2.	AIMS AND OBJECTIVES	3
3.	REVIEW OF LITERATURE	4-33
4.	METHODOLOGY	34-37
5.	RESULTS	38-50
6.	DISCUSSION	51-60
7.	CONCLUSION	61
8.	SUMMARY	62
9.	BIBLIOGRAPHY	63-79
10.	ANNEXURES	80-96
	ANNEXURE I- Ethical Clearance Certificate	80
	ANNEXURE II- Informed Consent	81-85
	ANNEXURE III - Proforma	86-90
	ANNEXURE IV - Photographs	91-93
	ANNEXURE V -Master Chart	94-95
	ANNEXURE VI -Key To Master Chart	96

LIST OF TABLES

Table No.	Particulars	Page No.
1.	Age Distribution	39
2.	Gender distribution	40
3.	Distribution of type warts	41
4.	Duration of warts	42
5.	Adverse effects	43
6.	Physician's Wart Assessment	44
7.	Visual Analogue Scale	47

LIST OF CHARTS

Chart No.	Particulars	Page No.
1.	Age distribution	39
2.	Gender distribution	40
3.	Distribution of type of warts	41
4.	Distribution of duration of warts	42
5.	Distribution of adverse effects	43
6.	Distribution of physician's warts assessment At Different Time Points in 5-FU group	46
7.	Distribution of physician's wart assessment Different Time Points in 5-FU group in MMR group	46
8.	Distribution of VAS score at different time points in 5-FU group	50
9.	Distribution of of VAS score at different time points in MMR group	50

LIST OF PHOTOGRAPH

Figure No.	Particulars	Page No.
1.	Clinical Pictures Of A Patient In The MMR Group In A Case Of Plantar Warts.	91
2.	Clinical picture of a patients in the MMR group in a case of plantar warts.	91
3.	Clinical pictures of a patient in the MMR group in a case of palmar warts.	92
4.	Clinical Pictures Of A Patient In The 5-FU Group In A Case Of Subungual Wart.	92
5.	Clinical Picture Of A Patient In The 5-FU Group In A Case Of Mosaic Warts.	93
6.	Clinical Picture Of A Patient In The 5-FU Group In A Case Of Palmar Wart.	93

INTRODUCTION

Viral warts are cutaneous and sometimes mucosal lesions caused by various strains of Human Papilloma Viruses which may occur as cutaneous as well as mucosal lesions.¹ Palmoplantar warts are quite resistant to treatment because of their endophytic growth pattern, increased viral load and very thick cornified layer.² Treating multiple palmoplantar warts is a challenge as the results of the current ablative treatment modalities leads to pain, temporary immobility, secondary infections and scarring.³

It has been found that cell-mediated immunity (CMI) plays a major role in wart resolution which highlights the need for immune protection against Human Papilloma Virus (HPV) infection and has directed attention towards stimulation of the patient's immune system, particularly CMI to eradicate viruses. So, treatment modalities using immunotherapeutic methods are being increasingly used to overcome drawbacks in treatment of warts.⁴

5-fluoruracil (5-FU) is an antimetabolite drug that inhibits DNA and RNA synthesis and may also function as an immunomodulatory drug. 5-FU suppresses cell division and cause cell cycle arrest.² This mechanism of action allows intralesional 5FU to be utilized in the treatment of viral warts caused by Human Papilloma Virus (HPV).²

Intralesional injection of 5-FU permits higher drug concentrations throughout the lesion.²

Intralesional Mumps Measles Rubella (MMR) vaccine immunotherapy employs the ability of the immune system to recognize viral antigens that induces a delayed type hypersensitivity reaction not only to the antigen, but also against the Human Papilloma virus, thereby increasing the ability of the immune system to recognize and clear HPV. Consequent to this, the stimulated immune response clears all the lesions on other body sites along with locally treated lesions. Immunotherapy using intralesional MMR vaccine has been found useful in treating common warts especially in children.⁵

Literature lacks comparison between the efficacy and time taken for resolution of warts with intralesional 5-Flourouracil and MMR vaccine.

Previous studies done for treatment of warts on extremities include treatment with antigens like *Candida albicans*, MMR vaccine, trichophyton; and tuberculin antigens such as purified protein derivative (PPD), mycobacterium w vaccine, and Bacillus-Calmette-Guerin (BCG).⁶

However, there is no comparative evaluation done so far between 5-FU and MMR in the treatment of warts. So, our intention was to evaluate which modality is more efficacious and faster in terms of resolution.

AIMS AND OBJECTIVES

To evaluate the efficacy of intralesional Mumps Measles Rubella (MMR) vaccine versus 5-Fluorouracil (5-FU) in the treatment of palmoplantar warts.

REVIEW OF LITERATURE

Warts, or verrucae, are cutaneous and sometimes mucosal lesions which occurs due to the infection of keratinocytes with the human papillomavirus (HPV)¹.

Till now around 150 different types of HPV were found. HPV are often designated as cutaneous (non-genital) and includes HPV-1, 2, 3 AND 4 whereas HPV-6, 11, 16 and 18 cause genital and mucosal infections.²

HPVs which have similar DNA sequences are found to induce similar lesions. Examples include highly related types such as 10 and 3, which induce flat warts, type 11 and 6 cause genital-mucosal warts (condyloma acuminata).²

HPV 1,2,4,27 or 57 are the most common types of HPV causing plantar warts. Deep myrmecia is due to HPV1.²

For every 9 patients seen with non-genital warts in India, there is 1 patient with genital-warts. In India, the prevalence of non-genital warts on the basis of clinical types were, common warts (42%), palmoplantar warts (20%), plane warts (18%), mosaic warts (6%), and filiform warts (4%).¹

PATHOPHYSIOLOGY

Palmoplantar warts are more commonly observed in children along with young adults. Immunocompromised individuals, are more prone to acquire warts which tends to be very extensive in nature.² Breaks in the epithelial barrier acts as points of entry for the HPV. The main predisposing factors is maceration of the skin.² In the stratum Basale, stem cells are infected by the virus, but the multiplication of virus takes place only in differentiated keratinocytes, that is, cells of upper stratum

spinosum and stratum granulosum.² After entry into a stem cell, viral genome replicas of HPV are sustained as an extrachromosomal plasmid or episome inside the nucleus of the infected epithelial basal cell. When these infected cells divide, the genome of the virus also gets replicated and partitions to the daughter cell, which carries over the viral infection into differentiating epithelial layers.² Commonly, plantar warts are obtained from wet floors of community baths, whose irregular surfaces cause minor trauma to the damp keratin and help to inoculate virus into the moistened skin of other uninfected people. Common hand warts extend around the nails in people who habitually bite their nails or the periungual skin or in those who suck fingers, and it can also spread to the lips and adjoining skin in these cases. Shaving over the beard area causes extension of warts over this area. Occupational handlers of meat have increased chances of getting warts on the hands, due to minor trauma and contact with wet flesh and water for prolonged period of time.²

Iatrogenic transmission³

Human papillomavirus DNA has been discovered on instruments used for the examination of women with clinical or subclinical HPV infection.⁸ Human papillomavirus DNA is detected in the smoke plume from warts which are treated by using laser or electrocautery.⁹ Immersing cotton swabs into the same flask of liquid nitrogen for multiple patients, could cause spreading of HPV between patients.⁸

HISTOPATHOLOGY

Viral warts manifest acanthosis and hyperkeratosis, with the hallmark feature of koilocytosis of upper keratinocytes. Majority of warts also show papillomatosis. In koilocytes and other granular layer cells, there can be presence of basophilic nuclear

inclusion bodies, which are an assembly of viral particles. The upper epidermal cells have eosinophilic inclusions which appear as, irregular clumped keratohyaline granules.⁹

PRESENTATION

Cutaneous warts can present in numerous morphological forms, which depends on the strain of the HPV, the anatomical location, immunity of the patient and environmental factors.¹⁰

DTYPES OF WARTS

a) Common Warts

Presentation of common warts are as papules consisting of irregular horny surface. Their size ranges from less than 1 mm to a little over 1 cm in diameter, but two or more lesions can coalesce to form larger plaques.² These warts most commonly occur on the dorsal aspect of the hands and fingers, and, on the knees in younger population, but can be seen at any location on the skin.²

At sites of injury new warts can come, which is a Koebner-like isomorphic phenomenon.²

Patients with common warts do not exhibit any symptoms, but they can be painful on the palms, when there is fissuring or when they are growing under the nail plate. Warts on the eyelids can cause conjunctivitis or keratitis.²

Common warts account for only 1 or 2% of genital warts in adults; in the male, they are most often seen on shaft of the penis.³

In children, HPVs causing common warts add up to two- thirds of ano-genital warts.¹¹

HISTOPATHOLOGY OF COMMON WARTS

Common warts show hyperplasia of all layers of the epidermis. There will be hyperkeratosis with interspersing parakeratosis and papillomatous projections will be present. Both spinous and granular layers will be thickened. Elongated and flattened rete ridges will be bent inwards to the verruca centre. The granular layer may contain foci of koilocytes. They are vacuolated cells which have a dark nucleus which looks either levelled or distorted. Vacuolated cells or abnormal keratohyaline granules may be seen within the parakeratotic stratum corneum.⁹

On the face, limbs or around mucous membranes, common warts, usually show exophytic pattern of growth and a varying quantity of hyperkeratosis.⁹

b) Periungual warts

Growth of the nail is hindered because of the extension of common warts beneath the nail plate. This can also lead to pain which causes distress to the patient.² Habitual nail biting causes minor injury in and around the nails, which may increase the likelihood of acquiring warts at this particular site.²

c) Plantar warts

Initially when plantar warts appear, it presents as a tiny gleaming ‘sago-grain’ papule, but soon it becomes a well-marked lesion, with irregular, keratotic exterior encircled by a ring of condensed horn.²

The delineation connecting the wart tissue and the defensive horny collar becomes very clear when we pare the wart by using a scalpel. If paring is continued, pin point bleeding points start appearing from the papillary capillaries at the tips of the elongated dermal papillae.²

Plantar warts usually occur on pressure points of the plantar aspect of the feet, like the heel or the metatarsal heads. At times, a constellation of tiny satellite warts, may fuse to form a fully developed large wart.²

Mosaic warts are seen a plaque of closely placed small warts.²

Pain is appreciated differently in different individuals. Sometimes it can be very tender, causing a lot of anguish to the patient, but many a times pain may be absent and warts are identified only on routine examination.²

Plantar wart duration is a fluctuating entity. There are cases where warts regress spontaneously, but resolution occurs faster in children than in adults. Clearance of warts can be delayed when hyperhidrosis or orthopaedic defects exist. Even if there are numerous warts, it usually does not have a bearing on the prognosis. Mosaic warts are found to be especially persistent.²

PLANTAR WART HISTOPATHOLOGY

Warts on the plantar aspect of the sole will have hyperplasia of all the epidermal layers. There will be gross hyperkeratosis.with.areas.of.parakeratosis, mainly. above. the papillomatous. projections, and both. spinous. and. granular layers are thickened. Lengthened and levelled rete ridges are bent inwards towards the centre of the wart. The stratum granulosum may be disordered with foci of koilocytes.⁹

In myrmecia, caused by HPV-1, the pathological cell changes are more characteristic and are observed in the bottom part of stratum spinosum. Plantar warts have a more endophytic pattern of growth and has an extremely thickened cornified layer.⁹

d)Plane warts (verruca plana)

Plane warts often have the same colour of the skin or are greyish yellow or pigmented and they may be at the level of the skin, or can be moderately raised. They usually measure around 1 to 5mm in diameter and are round or polygonal in shape. The common sites of predilection of plane warts are found to be the face, the dorsal aspect of hands and the shins. Sometimes, many small plane warts may coalesce and form bigger lesions.²

PLANE WART HISTOPATHOLOGY

Hyperkeratosis is of a loose and lamellar type and acanthosis is seen without papillomatosis. Epidermal cells which are vacuolated are seen and they often contain great many viral particles.¹²

II) OTHER CLINICAL VARIANTS

e) Digitate warts and filiform warts

Digitate warts and filiform warts are usually arranged in clusters and they are seen most commonly on neck and face area. Digitate warts may be seen over the scalp in males and females. Warts over the extremities usually assume a filiform shape.²

f) Gigantic hyperkeratotic warts

Occasionally, viral warts may be very extensive and unusually thick with extended horny projections. Individuals with underlying immunocompromise can present with this class of warts and they are found to be impervious to treatment and long-term treatment and follow up is necessary in such cases.^{13,14}

g) Butchers' warts

Individuals handling meat, poultry or fish as part of their occupation have higher incidence of warts on hands, because the skin is in continuously exposed to wet animal flesh. These lesions appear bigger than common warts and they have an increased recurrence rate despite successful treatment. HPV-2 usually causes butchers' warts, but HPV-7 is also a causative agent in a lesser number of cases.^{15,16}

h) Epidermoid plantar cysts

Many Japanese patients are reported to have epidermoid cysts on weight bearing areas of the sole where the causative agent is implicated to be HPV 60, but less commonly by HPV 57.¹⁷ These cysts are believed to occur due to implantation or involvement of the eccrine duct.¹⁸

i) Pigmented warts

In many Japanese patients pigmented warts were reported, most often seen on the palmar aspect of the hands and the plantar aspect of the feet.¹⁹ Within these pigmented warts the melanosome number is increased. These pigmented warts are caused by HPV-65 (64%), HPV 4 (23%) and HPV 60 (13%).

j) ano-genitalwarts

Ano-genital warts cause pain, discharge or overt bleeding, but often, they are asymptomatic in nature.² These warts commonly present as soft, pink, elongated and less commonly as filiform or pedunculated warts.² These warts can suddenly flourish in pregnancy²⁰ or in the presence of any co-existing local infections.²¹ On the vulvar and perianal skin, large masses of warts emanating bad odour can appear. About two-thirds of ano-genital warts are condyloma acumianata.²

The frenulum, corona and glans penis in males, and the posterior fourchette in women which are the likely sites of coital friction are the areas of common occurrence of genital warts.²

k) Oral warts

Oral warts are spread form one person to another by sexual contact²²or otherwise. Oral warts due to HPV-6 or -11are usually sexually transmitted and less commonly caused by HPV-2, HPV-57 or HPV-16.¹⁶ Individuals with HIV disease can have these oral warts.³ These warts can worsen after starting antiretroviral treatment.²³

Around 80% of cases of oral leucoplakia and 50% cases of oropharyngeal carcinoma are due to high-risk genital HPVs.²⁴

l) Laryngeal papillomatosis

Laryngeal papillomata are caused most commonly by HPV 11 and less commonly by HPV 6 and HPV 16.²⁵ Mother to child transmission occurs when infected mothers give birth to a child through the vaginal route.² Laryngeal papillomatosis is prone for recurrences, due to the presence of subclinical and latent

infections.²⁶ These warts can spread from one person to another by sexual contact.²⁶ Treatment includes debulking of lesions as an when required. Only very rarely, malignant transformation occurs in these warts which is usually caused by HPV-11.²⁷

m) Conjunctival papillomas

Only low risk variants of HPVs are detected in conjunctival papillomas.²⁸

n) Nasal inverting papillomas (inverted papilloma, Schneiderian papilloma)

Nasal inverting papillomas are caused by HPV-6/11, -16/18 and -57. Squamous cell carcinoma may develop in these warts.²⁹

Disease course and prognosis

In few cases of warts, spontaneous resolution might occur. In children, warts may clear faster maybe because of better immunity. On the contrary, warts may last for many years in adults. Spontaneous resolution may occur in 65% of warts in about 2 years and 95% within 4 years approximatley.³⁰ Inflammation precedes the resolution of plane warts, which present as itching, redness and oedema.³¹ Appearance of depigmented or hypopigmented rings surrounding the lesions are common.² Plantar warts, once it regresses may end up with black/bluish pigmentation due to thrombosed blood.³²

Warts which are caused by high-risk HPV variants like HPV-16 are the ones that frequently turn malignant.^{33,34}

Investigations commonly done in viral warts

Warts are diagnosed clinically in majority of the cases. Atypical, dysplastic or subclinical variants of warts at times may require laboratory confirmation of HPV infection.²

Common diagnostic methods available for warts are :

1. Histopathology²
2. Immunohistochemistry or immunocytochemistry using type- common or type-specific antibodies.²
3. DNA in situ hybridization.²
4. PCR for HPV DNA.²

MANAGEMENT

As small warts are not usually inconvenient to the patients and may resolve on its own, treatment may not be required.² In large number of cases treatment has to be started and patients should be counselled to stick with long-term use of daily application of topical medications and should also be made aware of therapies like cryotherapy or electrocautery and also their potential disadvantages.² Advice needs to be given to patients regarding general precautions to be taken, to limit the spread of the infection. Plantar warts need to be covered using a plaster especially while using a community bath or a swimming pool, to avoid spreading it to other people.² Biting of nails or periungual skin must be discouraged, to prevent the extension of periungual and perioral warts.² Patients should be advised not to share towels.² Ablative modalities are the popular treatment option used, where the epidermis that is laden

with HPV is destroyed.² There are other treatment options targeted at altering the epidermal growth or to induce immune response by using either topical or systemic approach.²

Combining different therapies is an option opted by a lot of clinicians. Reinstatement of the normal texture of the epidermis is the best clinical clue for complete cure of the warts.²

D)FIRST LINE TREATMENT

These topical treatment modalities may be regarded as first line.

These include:

- a) Salicylic acid²
- b) Glutaraldehyde²
- c) Formalin²
- d) Occlusion²
- e) Caustics²
- f) Retinoic acid²

a)Salicylic acid

The wart thickness can be reduced by the keratolytic property of salicylic acid and this might induce an inflammatory response.² 12–26% concentration of salicylic acid with lactic acid, in a collodion or acrylate base, is the first treatment of choice for verruca vulgaris and plantar warts.² A precise applicator such as a sharp toothpick or a matchstick will help in the precise application of the therapeutic agent on to the wart tissue.² A whitish deposit is seen after the salicylic acid dries. If the application is

supplemented with occlusion, percolation into thick keratin can be increased.² Salicylic acid preparations, may have to be used for a period 3 months or even longer, for optimal results.²

Glutaraldehyde.

10% glutaraldehyde in aqueous ethanol³⁵ or in a gel formulation can be utilized in wart therapy. The colour of the treated skin changes to brown and the skin becomes hard. A preparation of 20% glutaraldehyde in aqueous solution produced a 72% cure rate for different cutaneous warts in 25 individuals.³⁵ The unwanted effects of glutaraldehyde are allergic contact dermatitis and cutaneous necrosis.³⁵

b)Formalin.

2–3% concentration of formalin in water applied as compresses has an efficacy of 80% in children as per few reports.² A known complication is irritant dermatitis of the adjacent skin. The area affected by viral warts should be immersed in formalin containing solution for a time period of about 15–20 minutes every day and the adjoining skin should be protected by applying white soft paraffin. Formalin causes drying and hardening of the hyperkeratotic wart tissue thus helping with paring and also has virucidal properties.²

c)Occlusion.

Occluding common warts with the help of duct tape for a time period of approximately 2 months have shown to have favourable effects on warts in children.³⁶ If occlusion is used in union with any topical medications, the results are found to be better.

d)Caustics.

Monochloroacetic acid³⁷, trichloroacetic acid³⁸, silver nitrate³⁹, cantharidin⁴⁰, phenol⁴¹, formic acid⁴² and other irritant chemical substances are reported to provide good response in verruca, but these therapies can result in cutaneous adverse effects like irritant contact dermatitis. The peeling agents such as pyruvic acid⁴³ and glycolic acid⁴⁴ can be utilized as a therapeutic modality for plane warts.

e)Retinoic acid

Topical retinoic acid is utilised as a treatment modality for plane warts. This therapy is found to be efficacious in immunosuppressed patients.⁴⁵

II) SECOND LINE TREATMENT

The therapeutic modalities that are administered by a physician in the clinic which requires more time or are costly are considered to be second line treatment.²

a)Cryotherapy

Thermal damage to the skin to extreme cold can be caused by CO₂ snow, liquid nitrogen and dimethyl ether spray. The maximum cold thermal damage to the skin is produced by liquid nitrogen and can be applied either by a cotton bud or from a cryospray.⁴⁶ Any condensed keratin has to be pared down and the exterior should be dry, before commencing cryotherapy. Cryotherapy has to be carried on with until a lip of iced tissue of about 1 mm width is formed in the adjacent normal tissue. Conditional to the size and the location of the verruca, the freezing time is maintained for 5-30 seconds. Conditional to the dimensions and thickness of the wart an unbroken or pulsed spray between 5 and 20 seconds is usually required.⁴⁶

Every 3 weeks this treatment has to be repeated.⁴⁶

Pain is the most commonly experienced side effect of cryotherapy.²

Other adverse effects are, impairment to the underlying tissues. Prolonged freezing time has to be circumvented over nerves. In dark skinned patients, depigmentation can be a very disturbing cosmetic adverse effect .²

b)Laser

As a therapeutic option in warts, pulsed dye laser can be used. A resolution rate of around 32–75% has been shown to be achieved by using two treatment sessions.⁴⁷

Other lasers like, erbium:yttrium aluminium garnet (Er : YAG) and the neodymium : aluminium garnet (Nd : YAG) can be utilised in the treatment of warts.⁴⁸

Carbon dioxide laser therapy is well tolerated, but can cause postoperative pain, scarring and short-term loss of function.⁴⁹ HPV can be discovered in the smoke while using CO₂ laser on viral warts⁵⁰, so an operator mask and a good exhaust system are necessary.

c)Hyperthermia

Localized heat application for about 30 minutes at 44°Celsius can speed up wart resolution, with 54% clearance rate.⁵¹ Infrared coagulator can be utilized for the treatment of warts, which is also a destructive method.⁵²

d)Surgery

Excision is to be avoided because scarring is inevitable and the warts can recur on the scar.² But, curettage can be done for filiform warts.² Cautery/electrocoagulation and curettage, in combination, can be utilized for painful, resistant warts, but can result in scarring.²

e)Photodynamic therapy.

Topical as well as systemic aminolaevulinic acid is absorbed by proliferating cells which is then converted to protoporphyrin and it is then photoactivated, which produce destructive outcome on the cells. Resolution rates of around 75–90% for hand and foot warts⁵³, plane warts⁵⁴ and periungual warts⁵⁵ have been reported. Methyl amino levulinate photodynamic therapy (MAL-PDT) in union with a pulsed dye laser has a reported rate of resolution of 53%.⁵⁶ This treatment has to be performed again for two or three times but it can be hindered by pain.²

III)THIRD LINE TREATEMENT

Third line treatments are those treatments that is considered as an option in situations of critical and intractable HPV infection and also when those treatments which were considered as first- and second-line treatments have failed.²

a)Podophyllin and podophyllotoxin

Podophyllin and purified podophyllotoxin are antimitotic agents which throws into disorder the formation of the spindle on which chromosomes line up at mitosis. They are utilized primarily for the treatment of ano-genital warts, however it may also be utilized in cutaneous warts, but it's percolation into keratinized skin may be

meagre. They should be used with utmost caution , especially under occlusion.⁵⁷ Acute pain and fierce inflammation limited to the site of application of the drug are the most common side effects. Podophyllin and podophyllotoxin are absolutely contraindicated in pregnancy and are not recommended in children.²

b)Oral retinoids

Oral retinoids help to debulk warts, but there are chances that the infection might remain causing relapse. Isotretinoin and acitretin can be utilized in cases of expansive and very thick warts in those with an immunocompromised status.^{58,59} They can also be utilised in the treatment of thick warts in healthy patients in other respects.⁶⁰ This modality of treatment is temporarily useful as it helps in relieving agony and dysfunction due to extremely hyperkeratotic warts. Plane warts are found to clear promptly with isotretinoin at a dose of 0.5 milligram per kilogram per day for about 2 months or with low-dose acitretin administration.⁶¹

c)Cidofovir

This is a nucleoside analogue which incorporates itself into proliferating DNA, thus damaging dividing cells. It can be utilised in extremely severe warts, which can be injected intralesionally, diluted from 375 milligram per millilitre to 15 milligram per millilitre and has to be injected every month⁶² or is available as a cream of 1% concentration .⁶³ It is found to be useful in immunosuppressed patients.⁶⁴

d)Immunotherapy

Immunotherapy is defined as a type of biological therapy that utilises substances to stimulate or suppress the immune system to help the body fight cancer, infection, and other diseases. Some varieties of immunotherapies target

specific cells of the immune system. Other types act on the immune system as a whole. Different modalities of immunotherapy are cytokines, vaccines, and few monoclonal antibodies. It could be an activation immunotherapy, where immunity is induced or enhanced (used in infections, cancers), or a suppression immunotherapy, where immunity is suppressed (used in autoimmune diseases). The role of immunotherapy in malignancies is well studied and has now found a new role in infections also.⁶⁵

When should immunotherapy be instituted in viral warts?

A fixed consensus on when immunotherapy should be started in a patient who has warts does not exist currently, however the current indications are:

1. Recalcitrant warts
2. Recurrent warts
3. Extensive warts
4. Hard to treat areas like periungual and palmoplantar sites⁶⁵

Various agents used for immunotherapy are:

D)TOPICAL IMMUNOTHERAPY

Various topical immunomodulators are currently used for treating warts.

a)Diphencyprone

Diphencyprone (DPC) is easily degraded by ultraviolet (UV) radiation, it is diluted in acetone and stored in opaque bottles. It is used as a treatment option for impervious to treatment plantar warts.⁶⁶ Once the warts are pared down, DPC a concentration of 0.1% (2% to the soles of the feet) is applied.⁶⁷

It requires multiple hospital visits.⁶⁸

The adverse effect of DPC treatment is blistering at the application site of the drug. Extensive eczema like rash may occur, due to the non-resistant conveyance of DPC or due to auto eczematisation. Other adverse consequences of DPC are local lymphadenopathy, urticarial rash, lesions which resemble erythema multiforme, and vitiligo.⁶⁹

It is not recommended in pregnant women. DPC is not recommended for warts in the genital area or for warts on the face. Treatment using DPC is acceptable for warts on palms, soles, periungual warts, and warts on the digits.⁷⁰

The calculated assumptions regarding the effect of DPC include changes in the level of cytokine, inflammation which causes the wart to retreat, and attachment of DPC to wart protein, which induces an immune response.⁷⁰

b)Diphenylcyclopropenone

Diphenylcyclopropenone(DPCP) is a strong contact allergen and has to be kept in UV opaque bottles.⁷¹ DPCP has to be applied on the verruca after paring, at a strength of 0.1% on digits, warts around the nail aperture, around the toes and in the heel area and 2% strength on the volar side of the feet. After application of DPCP the warts have to be concealed with occlusive bandage for a time period of at least 48 hours to limit the acquiescent movement of DPCP.⁷²

Treatment has to be repeated at interludes of 1 to 4 weeks. Treatment is put to a stop once the wart has completely resolved.⁷³

Discolouration and blister formation at the site of application of DPCP are the commonly seen side effects.⁷⁴

The mode of activity of DPCP for viral warts has not been completely elucidated. Calculated assumptions are changes in the level of cytokines, inflammation which causes the warts to retreat, and coherence of DPCP to wart protein which induces an immune response.⁷⁴

c)Dinitrochlorobenzene

DNCB is a strong contact allergen.⁷⁵ In the treatment of verruca, DNCB is applied on the wart after paring. According to various reports, treating warts with DNCB is not an effective treatment.⁷⁶

d)Squaric acid dibutylester or SADBE

Squaric acid dibutylester (SADBE) is a very strong contact allergen. Topical application of SADBE constitutes an efficacious therapy in managing numerous warts on the sole and verruca vulgaris. SADBE use is not advised in the genital area, because it causes notable amount of irritation.⁷⁷

As per numerous reports, SADBE exerts its action by bringing about a delayed type of hypersensitivity reaction in an HPV-infested wart tissue, causing the clearance of the wart.⁷⁸

Thick warts need to be pared down before application of SADBE. 2% SADBE is applied on all non-facial warts; subsequently adhesive dressing is applied for at least 4-hours, followed by taking away the dressing. The area of application of SADBE is then cleaned using soap and water. This treatment is to be repeated each two to three weeks with application of 0.2% SADBE to the remnant warts.⁷⁹

No noteworthy adverse reactions to topical application of SADBE other than mild contact dermatitis that is reported.^{80,81}

e)5-Fluorouracil (5-FU)

5-Fluorouracil (5-FU) is an antineoplastic agent which blocks DNA and RNA production and causes cell cycle arrest.^{82,83}

5-FU is available as a cream formulation at a strength between 1 percent and 5 percent for topical application or it is available as injections which can be given intravesically.^{84,85} The antiproliferative and cytotoxic properties of 5-FU that hinder DNA and RNA production are postulated as the effect that causes cell cycle arrest and causes the warts to stop proliferating.^{84,85}

The unwanted effects of 5-FU include nail detachment, blister formation, pain, erythema, oedema, scarring and necrosis.^{86,87}

f)Bacillus Calmette-Guérin

Topical BCG application resulted in clearance of warts in the genital area in a time period 6 weeks 10 patients in a follow-up study done for 9.2 months. Even though the mechanism of action is not fully understood, it is postulated that topical BCG causes increased cellular activity and subsequent eradication of HPV.^{88,89} BCG turns on CD4+ lymphocytes thus resulting in an elevated cytokine level such as interleukin-1, interleukin-2 and Tumour Necrosis Factor- α . Interleukin-1 and Tumour Necrosis Factor- α has antiviral activity on HPV.^{90,91}

g) Imiquimod

Imiquimod has action against viruses and also acts against tumours and it also has immunotherapeutic action. It was approved by the FDA for treatment of warts in the genital area and warts around the anal region. It is a better treatment modality for damp nonkeratinized warts. It can also be used in treating resistant warts on the palms (Palmar warts), soles (plantar), around the nails (periungual), and warts beneath the nail plate (subungual).⁹²

Imiquimod is found to be a toll-like receptor (TLR) upholder. It attaches to TLR7 thus activating the macrophages, dendritic cells and monocytes that invigorates an elaborate cascade of responses in the cell cytoplasm which triggers Nuclear Factor kappa B (NF- κ B), and subsequently result in formation of cytokines. The most important cytokines and chemokines are interferon-alpha, interferon-gamma, interleukins 6, 8, 10, 11, 12 and TNF- α .^{93,94}

For anogenital warts, it is administered topically thrice weekly at bedtime then 4 days of gap is required or it can be applied on alternate days. It has to be cleansed using soap and water 6 to 10 hours after the application. Adverse reactions confined to the application site, such as erythema occurs frequently. Fever, flu-like symptoms, diarrhoeas, fatigue, blistering, excoriation, flaking, erosion, oedema, paraesthesia, burning, tenderness, pruritus are the other common adverse effects.⁹⁵

h) Vitamin D analogues

Maxacalcitol is known to be a vitamin D3 analogue. Vitamin D3 analogues for topical application are found to be effective in viral warts. The effect of vitamin D3 analogues in verrucae is assumed to be due to their ability to balance epidermal cell

multiplication and maturation and to coordinate cytokine production.^{96,97} An occlusive bandage of vitamin D3 analogue was used effectively in treating recalcitrant warts.^{98,99}

i)Sin catechins

The very first botanical formulation approved by FDA for treating anogenital warts is sin catechin ointment at a strength of 15%. Sin catechins are extracted from green tea leaves (*Camellia sinensis*) which contains polyphenols, especially catechins which constitute more than 85%. The active ingredient in sin catechin ointment formulation is a compound called epigallocatechin gallate.¹⁰⁰

Catechins employ antioxidant action by impeding transcription factors and also impedes the effect of the enzymes which causes elevation of oxidative stress. Moreover, catechins prompt an immune-stimulating outcome by enabling Langerhans cells, macrophages, lymphocytes, and also induces cytokines like interleukin-1b, Tumour Necrosis Factor-alpha, interferon-gamma, whereby bringing out CMI which is averse to HPV.^{101,102}

Sin catechins ointment is recommended to be applied thrice daily on all extra genital warts. Treatment must be continued until all extra genital warts get resolved, but the maximum time span of treatment should not exceed 16 weeks. Local adverse reactions over the skin like erythema, tenderness, pruritus, stinging and oedema are the most frequently noted side effects.¹⁰⁴

II) INTRAESIONAL IMMUNOTHERAPY

The capacity of our own immune system to induce type IV hypersensitivity like immune reaction to viral warts is being utilized by using intralesional immunotherapy. T helper 1 cytokines which activate killer cells which eventually eliminate HPV is seen to be produced when intralesional immunotherapy is utilized, thus causing clearance of warts. This clears the warts on which the intralesional injection is being injected as well as warts which are far away, dissimilar to cytotoxic therapeutic modalities.¹⁰⁵

Great many numbers of academic works have been undertaken to study multiple antigens like, *Candida* antigen, mumps antigen, trichophyton Ag, Bacillus Calmette Guerin vaccine, mumps, measles and rubella (MMR) vaccine, Mycobacterium w(Mw) vaccine, interferon alpha and interferon gamma injection.¹⁰⁶

There are mainly two methods of intralesional immunotherapy used by different clinicians. In the initial method, an injection of the desired antigen is given intradermally on the palmar side of the forearm of the subject and redness and induration is measured 48 to 72 hours later, which is a marker of delayed type of hypersensitivity response. The subjects who respond with redness and induration of 5 millimetre in diameter can be administered this therapy.¹⁰⁷

In the second method, the desired antigen was directly administered via injection into the biggest wart without doing an intradermal test in the beginning. Injection into the warts with the desired antigen is done with the aid of an insulin syringe, where the insulin syringe is held collateral with the skin surface with the bevel of the needle facing upward.¹⁰⁸

a)Bleomycin

Resolution rates in the range of 14 to 99% has been found while using intralesional bleomycin, mainly while treating very extensive and resistant warts. Many reports on the use of intralesional bleomycin in successfully treating, warts near the nail aperture (periungual) and warts on the palms and soles (palmoplantar warts) exist.¹⁰⁹

Bleomycin injection is marketed in vials which contain 15 milligram powder. It is first diluted in 5 millilitres of distilled water to make the stock solution, then two parts of lignocaine in the concentration of 2% and one part of the bleomycin stock solution are taken in an insulin syringe, so that the terminal strength becomes 1 milligram/millilitre and then the solution is injected into the lesion till the lesion is seen to blanch.^{110,111}

Because the intralesional dose is only 1 mg/ml, which is a minute dose, unwanted systemic effects were not observed. But, local adverse effects such as pain at the site of injection, necrosis, scarring, hypo/hyperpigmentation, Raynaud's phenomenon, and dystrophy of nails were seen in few cases. Bleomycin should not be given in pregnancy, children and patients who suffer from peripheral vascular disease.^{112,113}

b)Interferon (alpha and gamma)

Intralesional IFN which is FDA approved treating warts in the genital area is IFN- α -2b. It requires to be injected every two weeks for a time period of three weeks for best results.¹¹⁴

The side effects associated with intralesional interferon includes fever, tiredness, loose stools, headache, vomiting and flu-like symptoms.¹¹⁵

c) *Candida albicans* antigen

With injection of candida albicans antigen, cent percent resolution of warts was reported in 74% subjects in one study. Intralesional injection of candida antigen was given in children with intractable warts and a resolution rate of 47% for the warts which received the injection and 34% for distant warts was noted.¹¹⁶ Unwanted effects that have been noted with candida antigen immunotherapy are fever like symptoms, muscle pain, redness, and swelling in the injection site, and purple digit syndrome.¹¹⁷

d) Mumps, measles and rubella vaccine (MMR vaccine)

Intralesional injection utilizing MMR vaccine has the advantage of clearing warts which received injection and distant warts without scarring, decreased recurrence rate, and the high safety profile. The mode of action of intralesional MMR vaccine therapy is not completely understood, but inflammatory reaction to the antigens is the main mechanism of immunotherapy.¹¹⁸

MMR vaccine has been utilized and studied for treating warts in multiple studies. Nofal and Nofal¹¹⁹ reported cent percent clearance of warts in 81.4% of patients in the group where MMR vaccine was given as opposed to 27.5% of patients who were in the placebo group. Pain in site of injection and flu-like symptoms were the sole adverse effects reported.¹²⁰

e) *Mycobacterium w antigen*

Killed *Mycobacterium w antigen* vaccine was developed from a non-pathogenic, fast-growing, atypical *Mycobacterium* included in Runyon class IV. It is highly antigenic and produces cytokine and T-cell responses.¹²¹

This vaccine comes in a multidose vial of 0.5 ml which contains 500 million heat-killed bacilli in a buffer solution. In sensitized patients, 0.1 ml of the vaccine is injected into the epidermis in two to four warts. Bigger warts are selected for injection. The injections are given on a 2 weekly basis, until all the warts are completely cleared or a maximum of 10 injections are given, whichever occurs early.¹²²

III) SYSTEMIC IMMUNOTHERAPY

Body's immune system can be activated by systemic treatment which could be achieved through different treatment methods. Oral therapies that induce our immune system in order to eliminate HPV are zinc sulphate, cimetidine and levamisole. Other routes of administration are auto-inoculation, acupuncture and intradermal injection.¹²³

a) Cimetidine

Cimetidine which is a H₂ receptor antagonist¹²⁴ has immunomodulatory effects as well.¹²⁴ Cimetidine can be utilized for treating warts in children, and recurring warts in adults. It can be utilized in the treating periungual, genital and multiple warts as well.¹²⁴ But, the results obtained from various studies are not very encouraging, stating that cimetidine is not any better when compared to placebo.¹²⁵

b)Levamisole

Levamisole is an anthelmintic drug.¹²⁶ Using levamisole in treating verrucae is not found to be an efficacious modality in any of the studies that have already been conducted. Levamisole, given at a dose of 150 mg daily for 3 consecutive days every second week did not prove to be much efficacious in treating viral warts in a study by Saul et al.¹²⁷

Thus, the part of levamisole in the treating warts is not yet strongly proved.¹²⁷

c)Zinc sulphate

Systemic and cutaneous forms of zinc may be utilized for treating warts and has been demonstrated in multiple studies. In a study done by Sharquie *et al.*¹²⁸ it was found that zinc sulphate topical therapy is efficacious in treating viral warts. Zinc sulphate solution in a concentration of 10% when applied thrice daily for around 4 weeks is reported to lead to complete clearance of viral warts in around 80% patients.¹²⁸In the study done by, Al-Gurairi *et al*¹²⁹ where zinc sulphate was given orally at a dose of 10 mg/kg/day up to a maximum dose of 600 mg/day, total resolution of verrucae was seen in 86.9% subjects after giving oral zinc for two months, but 13.3% patients didn't show any response to this modality.¹³⁰

d)Acupuncture

Ning *et al.*¹³¹ in a study that involved 60 subjects with verruca plana, used the technique of acupuncture to treat these patients. Patients were out into two different groups; In the first group subjects were treated with auricular acupuncture every week, and the subjects in the second group were treated with 0.1% tretinoin ointment. The group that received acupuncture showed total resolution of verrucae in 53.33% of

patients whereas only 3.33% of the patients who were treated with tretinoin ointment showed total clearance.^{131,132}

e) Purified protein derivative (PPD)

Eassa *et al.*¹³³ described treating anogenital warts in pregnant women with the aid of intradermal injection of PPD. 47.5% patients showed complete improvement, 37.5% showed partial/satisfactory improvement, and 7.5% subjects had only mild/unsatisfactory response. 7.5% patients had absolutely no reaction to this treatment modality at all.^{134,135}

f) Auto wart injection

Srivastava and Bajaj¹³⁶ have tried auto wart injection for treating warts involving larger body surface areas and for recurrent warts. The method they used was by removing 3-4 millimetres of the wart tissue by electrocautery and placing this tissue on a sterile gauze. Then this tissue was squashed in mortar and pestle and distilled water was added to get a fine suspension and was taken in a sterile syringe and was injected in the gluteal region. A response rate up to 89% (66.03% with complete clearance of warts and 22.64% with partial improvement), was seen in the group injected with auto wart suspension, whereas 11.32% showed no response at all.¹³⁶

By using another modification of this technique, Nischal *et al.*¹³⁷ used the pared tissue of the warts for auto implantation in subcutaneous tissue and they also reported improvement. The results obtained implicate that auto wart injection is an efficacious therapeutic modality in treating viral warts.¹³⁷

In our study, we are comparing the efficacy of intralesional Mumps, Measles Rubella vaccine with intralesional 5-Flourouracil in the treatment of palmoplantar warts. The mumps-measles-rubella (MMR) vaccine is a live attenuated vaccine used in the prevention of mumps, measles and rubella.¹³⁸ The use of three antigens- mumps, measles and rubella together help in eliciting a strong immune response against HPV via the production of various cytokines like interleukin (IL) IL-2, IL-4, IL-5, and Tumour necrosis factor alpha.¹³⁹ MMR vaccine also turns on Th1 response which treats not only the injected warts but distant warts as well.¹³⁹

In most of the studies using MMR vaccine for treatment of warts, studies, 0.5 ml of MMR vaccine was reconstituted with distilled water and then was injected at a dose of 0.1ml into the largest wart. Injections were repeated every two weeks for a maximum of 5 sittings or till complete clearance of warts, whichever occurred earlier.¹³⁹ Pain during injection and flu like symptoms were the most common side effects.

So, immunotherapy with MMR intralesional injection has potential as a safe and effective modality for viral warts. It is a simple, cost-effective and non-destructive method that shows good efficacy and tolerability. With less side effects and a lower relapse rate compared to other treatment modalities; MMR immunotherapy can potentially be used as a first-line treatment for warts.¹³⁹

5-Flourouracil is an antimetabolite and cytotoxic drug that inhibits the synthesis of DNA and RNA and may also function as an immunomodulatory drug. 5-FU suppresses cell division and cause cell cycle arrest.^{82,83} Use of topical 5-flourouracil in the treatment of warts, now seems to be only of historical interest. Evidence provided by the trials that were undertaken in 1970s and 1980s was limited

by the heterogeneity of the methods and designs. Overall, this treatment was not considered to be an efficacious treatment modality.^{84,85} Intralesional injection of 5-flourouracil, lignocaine, and epinephrine (5-FU+LE) has several advantages over topical 5-flourouracil cream or intralesional injection alone. Intralesional injection of 5-flourouracil permits higher drug concentration throughout the lesion. The addition of lignocaine makes the injection less painful. The dose of intralesional 5-fluorouracil administered for the treating warts is in the range of 2 to 6 milligrams, which is, less than 1/150th the dose used for systemic therapy. Hence, unwanted systemic effects of 5-fluoruracil are eliminated.^{86,87}

In most of the studies using intralesional 5-FU in the treatment of warts, intralesional injection of 5- fluorouracil was given into the warts every 2 weekly for a maximum of 5 sittings or until complete clearance of warts, whichever happened earlier. Black echymosed eschar used to form after each injection which was pared before giving the next injection. The safety of this drug has to be assessed in paediatric population.

Intralesional 5-fluorouracil is highly effective, safe and cheap alternative for treating palmoplantar warts according to other studies.^{86,87}

MATERIALS AND METHODS

STUDY SOURCE: This study took place in Department of Dermatology, Venereology and Leprosy in a tertiary care hospital, Belgaum as a part of MD academic curriculum.

STUDY DURATION: One year: January 2020 to December 2020

ETHICAL CLEARANCE: Ethical clearance was obtained from the Ethical committee of the institute.

STUDY DESIGN: Randomized Control Trial

SAMPLE SIZE: 36, 18 in MMR group and 18 in 5-FU group.

The formula used for sample size:

$$n = 2 \times \bar{p}(1 - \bar{p}) \times (Z_{\alpha} + Z_{\beta})^2 \div (p_1 - p_2)^2$$

Where n is the sample required, p_1, p_2 are the percentage occurrence of a state or condition (proportion or prevalence), \bar{p} is the average of p_1, p_2 and Z_{α} is the value corresponding to level of confidence required, Z_{β} is the power required.

At the 6th injection we assumed that, 80% of MMR and 40% of 5-FU subjects will have complete resolution of warts. This prevalence was used to calculate sample size. With 80% power and 95% level of significance, sample size obtained is as below:

$$n = 2 \times (0.6 \times (1 - 0.6)) \times (0.84 + 1.65)^2 \div (0.8 - 0.4)^2$$

$n = 18.54 \approx 18$

Thus, a sample size of total 36, 18 in each group was reached.

Patients were assigned to each group randomly using a random number table derived from R software.

Group	Patient number
MMR	1,4,6,11,12,14,16,18,19,21,26,27,28,29,31,32,34,36
5-FU	2,3,5,7,8,9,10,13,15,17,20,22,23,24,25,30,33,35

STUDY PROTOCOL

- The study included all patients with palmoplantar warts at KLE's Dr Prabhakar Kore Hospital and Medical Research Centre in Belagavi who were above 12 years old, non-pregnant, non-lactating, and did not have any local dermatological conditions.
- All patients who took part in the trial gave their informed consent.
- All of the patients in the study had a thorough medical history taken, as well as a general physical exam, as well as a systemic and dermatologic evaluation.

INCLUSION CRITERIA

- All patients over the age of 12.
- Warts on the palms and soles of the feet.
- Patients who have never had a reaction to 5FU, lidocaine, or epinephrine.

EXCLUSION CRITERIA

- Expecting or planning to become pregnant during the next three months.
- Women who are lactating
- Patients who've had wart therapy in the last month.
- Patients with any other local dermatological condition.
- Patients who have an infection, are immunocompromised or are on immunosuppressive drugs, asthmatic, allergic skin problems, meningitis, or seizures.

PROCEDURE

Patients in the MMR group were injected with 0.2ml of freeze dried MMR vaccine after reconstitution with 0.5ml of the provided diluent, in the base of each wart and the injections were resumed every 2 weeks through total elimination or a maximum of 6 injections.

Patients in the 5-FU group were injected with a solution of 250mg/ml of 5-FU, Lidocaine and epinephrine in a 4:1 ratio at the bottom of each wart and the injections were resumed every 2 weeks through total elimination or a maximum of 6 injections.

On each visit the lesions were photographed and measured using Vernier calliper. On each visit ie baseline, week2, week4, week6, week8 and week12, pictures and measurements were taken for comparison and analysis.

Records were maintained and analysed systematically.

The possible outcomes of the study were analysed using Physician's Wart Assessment (PWA)¹⁴⁰ and Visual Analogue Scale (VAS)¹⁴¹.

Physician's warts assessment:¹⁴⁰

Grade 0: clear – no visible wart. No further treatment required.

Grade 1: near clear – a visible wart less than 3mm in maximal diameter (length)

Grade 2: A visible wart more than or equal to 3mm and less than 6mm in maximal diameter (or length)

Grade 3: A visible wart of more than 6mm in maximal diameter (length).

VAS SCORE¹⁴¹

VAS 100 %: Complete disappearance of lesions and appearance of normal skin

VAS 75-99%: Partial clearance ie.. reduction in number and size of warts, few residual warts are still visible.

VAS 50-75%: some reduction in size, but no decrease in number of warts.

VAS less than 50%: no change in number and size of warts

Analysis was done by:

Data was analysed using R software and excel. Chi square/Fischer test was used to check the association between categorical variables.

t-test/Mann-Whitney test/Kruskal-Wallis test was used to compare continuous variables.

RESULTS

Data was analysed using R software version 4.0.4 and Excel. Categorical variables are given in the form of frequency table. Continuous variables are given in Mean \pm SD/ Median (Min, Max) form. Two-sample t test/Mann Whitney U test was used to compare the means/distributions of variables over the groups. Chi square test was used to check the association of attributes. Friedman test was used to compare the distributions of PWA grade and VAS score at different time points. Friedman-Conover test was used as post hoc analysis. P-value less than or equal to 0.05 is statistically significant.

A total of 36 patients were included in our study over a period of one year from 1st January to 31st December 2020.

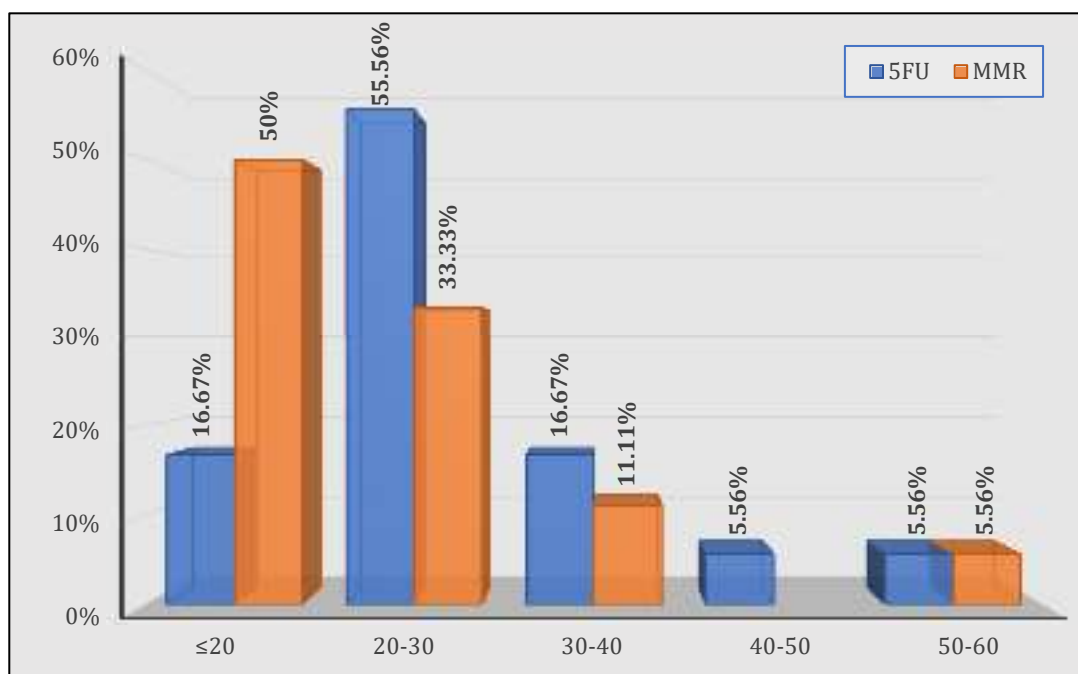
AGE DISTRIBUTION

A total of 36 subjects were included who were randomly assigned into 2 groups , 5FU and MMR group consisting of 18 subjects each. Age of the subjects ranged from 14 to 56 years with a mean age 26.58 ± 9.47 years.

Table 1: Distribution of age with group.

Age (years)	5FU	MMR	Total	p-value
≤20	3 (16.67%)	9 (50%)	12 (33.33%)	0.2539 ^{MC}
20-30	10 (55.56%)	6 (33.33%)	16 (44.44%)	
30-40	3 (16.67%)	2 (11.11%)	5 (13.89%)	
40-50	1 (5.56%)	0	1 (2.78%)	
50-60	1 (5.56%)	1 (5.56%)	2 (5.56%)	
Mean ± SD	29.17 ± 8.28	24 ± 10.09	26.58 ± 9.47	0.1023 ^t
Median (Min, Max)	27 (20, 51)	20.5 (14, 56)	25.5 (14, 56)	

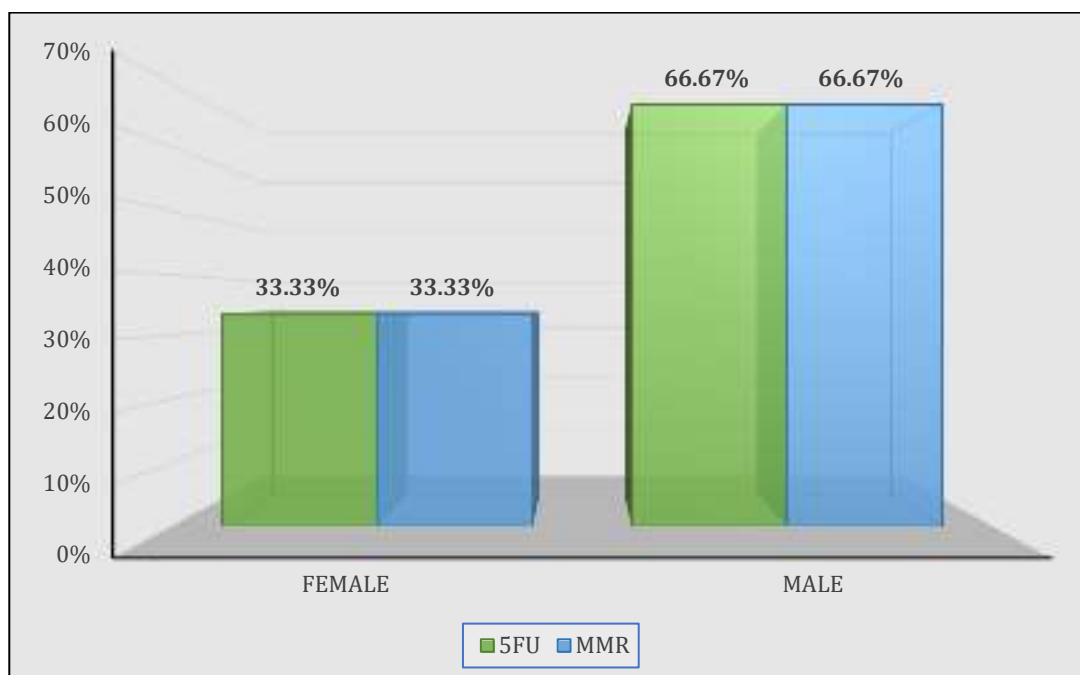
Abbreviation: MC – Chi square test with Monte Carlo simulation, t – Two sample t test.

Chart 1: Distribution of age with respect to the groups.

GENDER DISTRIBUTION**Table 2: Distribution of gender with respect to groups.**

Gender	5FU	MMR	Total	p-value
Female	6 (33.33%)	6 (33.33%)	12 (33.33%)	1 ^C
Male	12 (66.67%)	12 (66.67%)	24 (66.67%)	

Abbreviation: C – Chi square test.

Chart 2: Distribution of gender with respect to the groups.

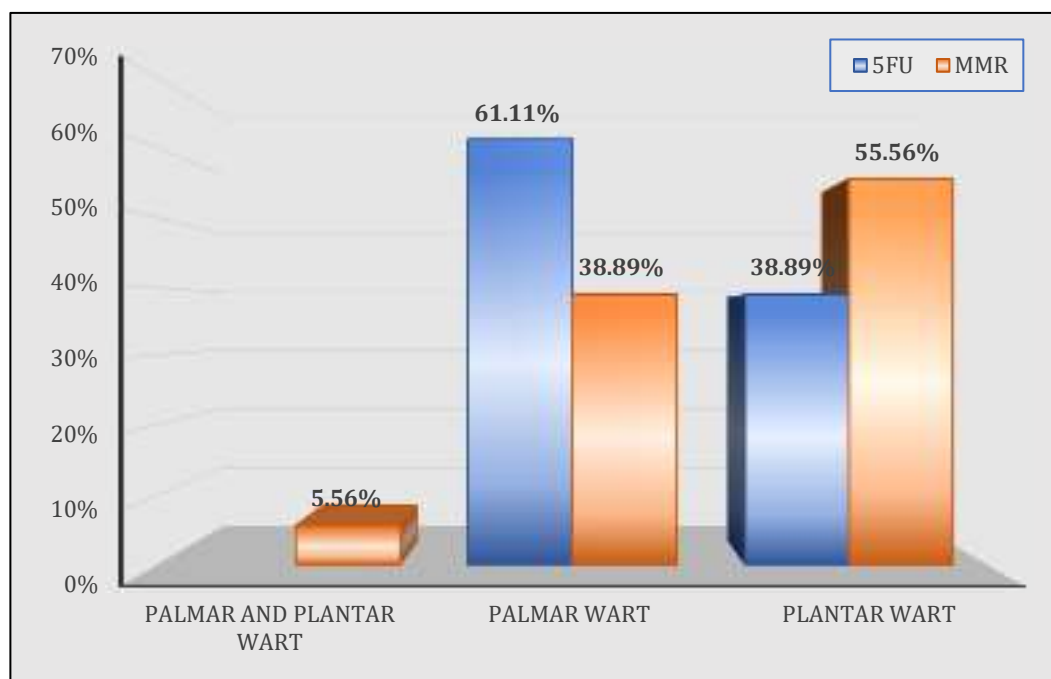
DISTRIBUTION OF TYPE OF WARTS

Table 3: Distribution of type of warts with respect to groups.

Type of Warts	5FU	MMR	Total	p-value
Palmar and plantar wart	0	1 (5.56%)	1 (2.78%)	0.3143 ^{MC}
Palmar wart	11 (61.11%)	7 (38.89%)	18 (50%)	
Plantar wart	7 (38.89%)	10 (55.56%)	17 (47.22%)	

Abbreviation: MC – Chi square test with Monte Carlo simulation.

Chart 3: Distribution of type of warts with respect to the groups.



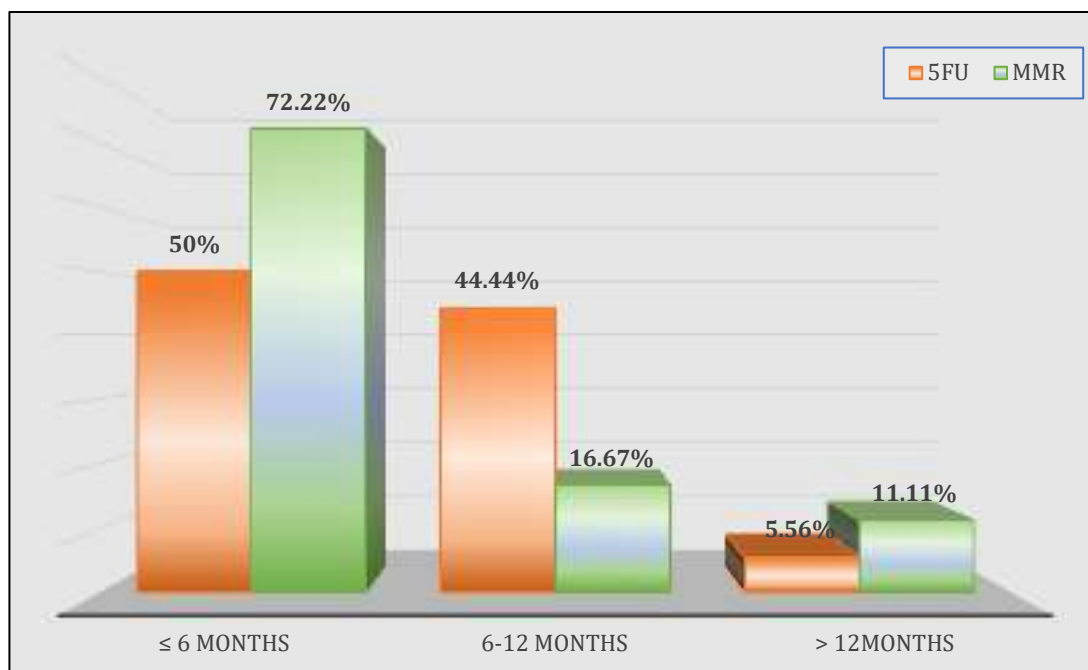
DURATION OF WARTS

Table 4: Distribution of duration of warts with respect to groups.

Duration of Warts	5FU	MMR	Total	p-value
≤ 6month	9 (50%)	13 (72.22%)	22 (61.11%)	0.2909 ^{MC}
6-12months	8 (44.44%)	3 (16.67%)	11 (30.56%)	
>12months	1 (5.56%)	2 (11.11%)	3 (8.33%)	
Mean ± SD	7.44 ± 5.93	7.17 ± 6.96	7.31 ± 6.37	0.8982 ^t
Median (Min, Max)	7 (1, 24)	6 (1, 24)	6 (1, 24)	

Abbreviation: MC – Chi square test with Monte Carlo simulation, t – Two sample t test.

Chart 4: Distribution of duration of warts with respect to the groups.



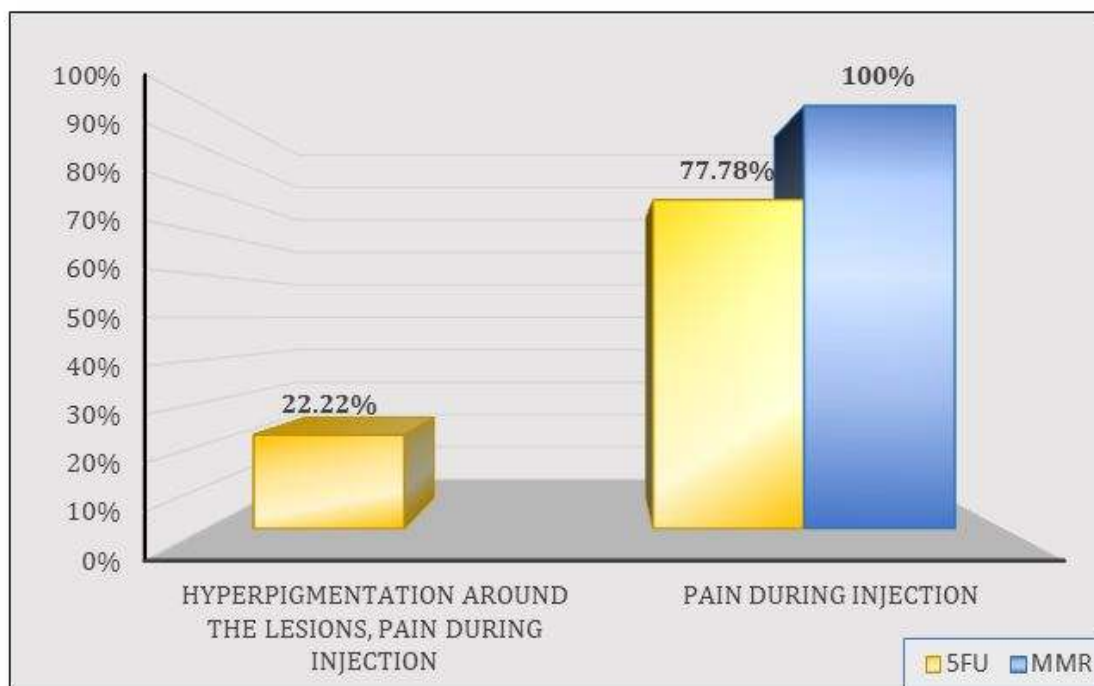
ADVERSE EFFECTS

Table 5: Distribution of adverse effects with respect to groups.

Adverse Effects	5FU	MMR	Total	p-value
Hyperpigmentation around the lesions, pain during injection	4 (22.22%)	0	4 (11.11%)	0.1174 ^{MC}
Pain during injection	14 (77.78%)	18 (100%)	32 (88.89%)	

Abbreviation: MC – Chi square test with Monte Carlo simulation.

Chart 5: Distribution of adverse effects with respect to the groups.



PHYSICIAN'S WART ASSESSMENT¹⁴⁰**Table 6: Distribution of physician's warts assessment grades at different time points in the groups.**

Groups	Grade	Time Period						p-value
		Baseline	Week 2	Week 4	Week 6	Week 8	Week 12	
5FU	0	0	0	0	1 (5.56%)	5 (27.78%)	7 (38.89%)	< 0.001^{F*}
	1	0	0	5 (27.78%)	5 (27.78%)	2 (11.11%)	3 (16.67%)	
	2	11 (61.11%)	12 (66.67%)	8 (44.44%)	9 (50%)	8 (44.44%)	7 (38.89%)	
	3	7 (38.89%)	6 (33.33%)	5 (27.78%)	3 (16.67%)	3 (16.67%)	1 (5.56%)	
MMR	0	0	0	7 (38.89%)	15 (83.33%)	18 (100%)	18 (100%)	< 0.001^{F*}
	1	1 (5.56%)	3 (16.67%)	3 (16.67%)	2 (11.11%)	0	0	
	2	8 (44.44%)	6 (33.33%)	3 (16.67%)	1 (5.56%)	0	0	
	3	9 (50%)	9 (50%)	5 (27.78%)	0	0	0	
p-value		0.5017 ^{MC}	0.07296 ^{MC}	0.0235^{MC*}	< 0.001^{MC*}	< 0.001^{MC*}	< 0.001^{MC*}	-

Abbreviation: F-Friedman test, MC – Chi square test with Monte Carlo simulation, * indicates statistical significance.

From Chi square test, we observed that, there is no significant difference in the distribution of PWA grades between the groups at baseline and 2nd week. There was significant difference in the distribution of PWA grades between the groups at 4th, 6th and 8th week.

It was found that in MMR group by 4th week, 7(38.89%) patients had grade 0 PWA, 3 (16.67%) patients had grade 1 PWA, 3(16.67%) patients had grade 2 PWA

and 5 (27.78%) patients had grade 3 PWA where as in the 5-FU group, by 4th week no patients had grade 0 PWA, 5 (27.78%) patients had grade 1 PWA, 8 (44.44%) patients had **grade 2** PWA and 5 (27.78%) patients had grade 3 PWA.

It was found that in MMR group by 6th week, 15 (83.33%) patients had grade 0 PWA, 2 (11.11%) patients had grade 1 PWA, 1 (5.56%) patient had grade 2 PWA and no patients had grade 3 PWA where as in 5-FU group by 6th week, 1 (5.56%) patient had grade 0 PWA,

5(27.78%) patients had grade 1 PWA, 9(50%) patients had grade 2 PWA and 3 (16.67%) patients had grade 3 PWA.

It was found in MMR group by 8th week, 18(100%) patients had grade 0 PWA, where as in 5-FU group, 5 (27.78%) patients had grade 0 PWA, 2 (11.11%) patients had grade 1 PWA, 8 (44.44%) patients had grade 2 PWA and 3 (16.67%) patients had grade 3 PWA.

From, the observations we made from PWA we can infer that, patients in the MMR group had faster resolution of their warts (that is by 8th week all the patients had complete resolution of warts in MMR group), where as in the 5-FU group, only 6 (33.33%) patients had complete clearance of warts by 8th week.

From Friedman test, we observed that there was significant difference in the distribution of PWA grades at different time points in both the groups. From post hoc analysis, we observed that, there was significant difference in PWA grades at different time points in both the groups (p -values < 0.05) except for baseline & 2nd week (p -value = 0.4147) in 5FU group.

Below graph (figure 6, figure 7) depicts the same.

Chart 6: Distribution of physician’s warts assessment grades over time points in 5FU.

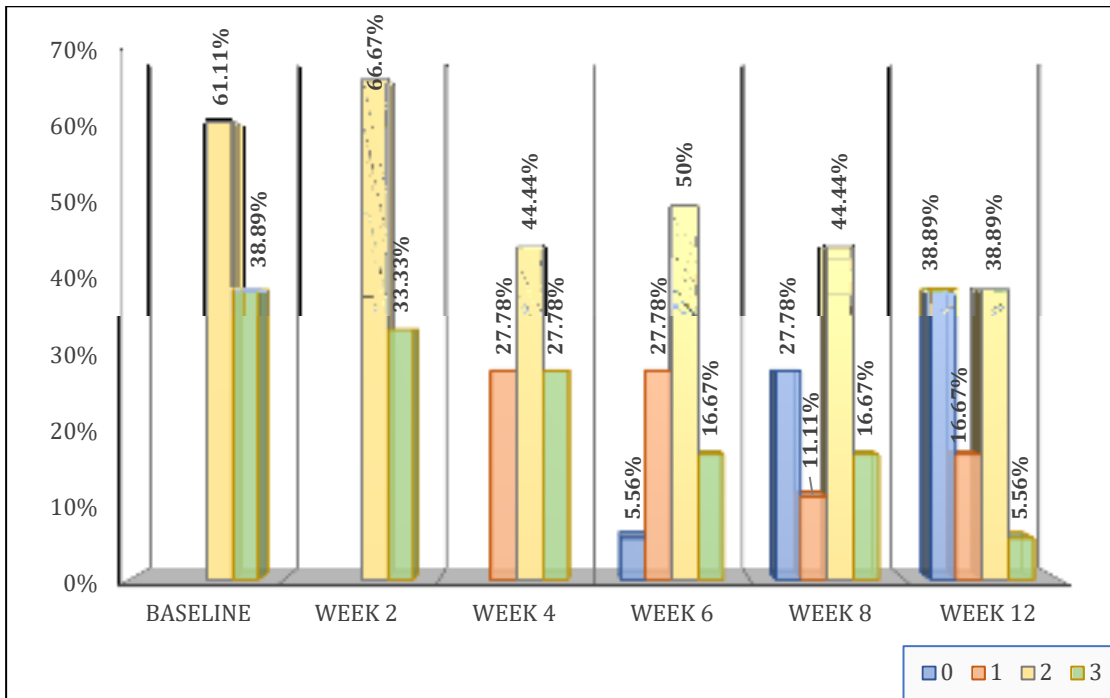
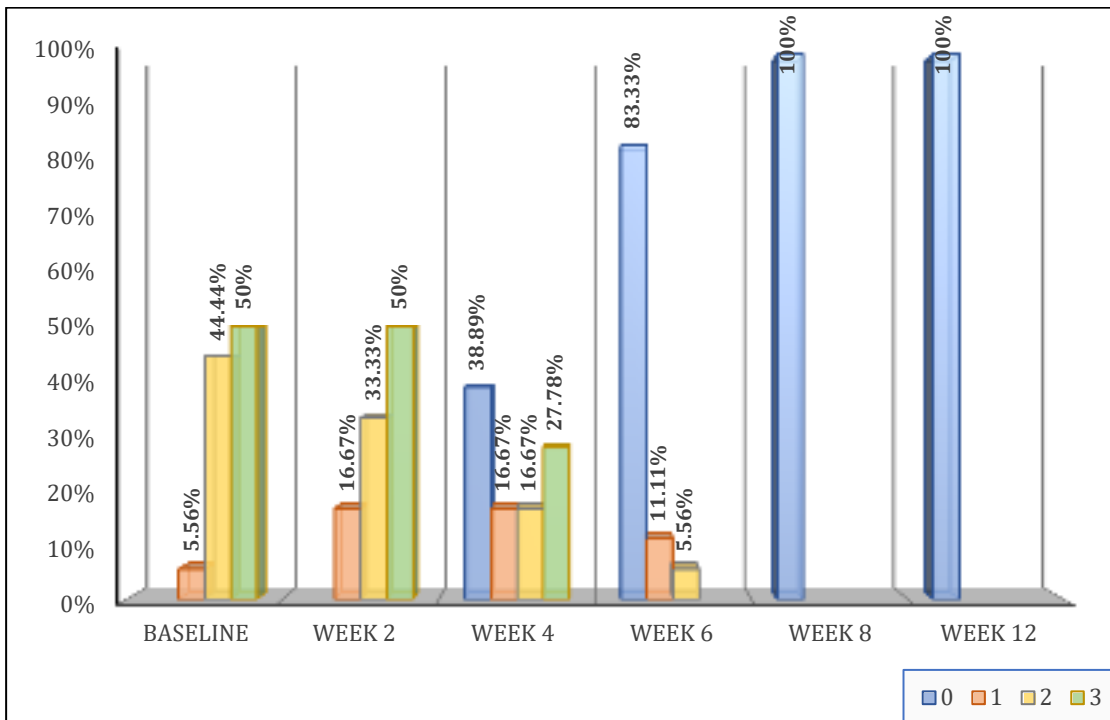


Chart 7: Distribution of physician’s warts assessment grades over time points in MMR.



VISUAL ANALOGUE SCALE¹⁴¹**Table 7: Distribution of VAS score at different time points in both the groups.**

Groups	VAS score	Time Period						p-value
		Baseline	Week 2	Week 4	Week 6	Week 8	Week 12	
5FU	< 50%	18 (100%)	8 (44.44%)	3 (16.67%)	3 (16.67%)	1 (5.56%)	1 (5.56%)	<0.001^{F*}
	50-75%	0	10 (55.56%)	15 (83.33%)	14 (77.78%)	11 (61.11%)	7 (38.89%)	
	75-99%	0	0	0	0	1 (5.56%)	3 (16.67%)	
	100%	0	0	0	1 (5.56%)	5 (27.78%)	7 (38.89%)	
MMR	< 50%	18 (100%)	7 (38.89%)	0	0	0	0	<0.001^{F*}
	50-75%	0	11 (61.11%)	9 (50%)	2 (11.11%)	0	0	
	75-99%	0	0	2 (11.11%)	3 (16.67%)	0	0	
	100%	0	0	7 (38.89%)	13 (72.22%)	18 (100%)	18 (100%)	
p-value		1 ^C	1 ^C	0.0015^{MC*}	< 0.001^{MC*}	< 0.001^{MC*}	< 0.001^{MC*}	-

Abbreviation: F-Friedman test, C-Chi square test, MC – Chi square test with Monte Carlo simulation, * indicates statistical significance.

From Chi square test, we observed that, there was no significant difference in the distribution of VAS scores between the groups at baseline and 2nd week. There was significant difference in the distribution of VAS score between the groups at 4th, 6th and 8th week.

At 4 weeks from the first dose in the MMR group, VAS score 100% was seen in 7(38.39%) patients, VAS score 75-99% was seen in 2(11.11%) patients, VAS score 50-75% was seen in 9(50%) patients and VAS score less than 50% was seen in 0 patients, where as in 5 FU group, at 4 weeks from the first dose, VAS score 100% was seen in 0 patients, VAS score 75-99% was seen in 0 patients, VAS score 50-75% was seen in 15(83.33%) patients and VAS score less than 50% was seen in 3(16.67%) patients.

At 6 weeks from the first dose, in the MMR group, VAS score 100% was seen in 6(33.33%) patients, VAS score 75-99% was seen in 3(16.67%) patients, VAS score 50-75% was seen in 2(11.11%) patients and VAS score less than 50% was seen in 0 patients, where as in 5-FU group, at 6 weeks from the first dose, VAS score 100% was seen in 1(5.56%) patient, VAS score 75-99% was seen in 0 patients, VAS score 50-75% was seen in 14(77.78%) patients and VAS score less than 50% was seen in 3(16.67%) patients.

At 8 weeks from the first dose, in the MMR group, VAS score 100% was seen in 5(27.78%) patients, VAS score 75-99%, VAS 50-75% and VAS score less than 50% was seen in 0 patients ie.. by 8th week all 18 patients (100%) had complete clearance of warts, where as in 5-FU group, at 8 weeks from the first dose, VAS score 100% was seen in 4(22.22%) patients, VAS score 75-99% was seen in 1(5.56%) patient, VAS score 50-75% was seen in 7(38.89%) patients and VAS score less than 50% was seen in 1(5.56%) patient.

From, the observations we made from VAS score, we can infer that, patients in the MMR group had faster resolution of their warts (that is by 8th week all the

patients had complete resolution of warts in MMR group-VAS 100%), where as in the 5-FU group, only 6 (33.33%) patients had complete clearance of warts by 8th week.

From Friedman test, we observed that there was significant difference in the distribution of VAS scores at different time points in both the groups. From post hoc analysis, we observed that, there is significant difference in VAS score at all the time points (p-values < 0.05) except for 4th & 6th week (p-value = 0.46) in 5FU group.

Below graph (figure 8, figure 9) depicts the same.

Chart 8: Distribution of VAS score over time points in 5FU.

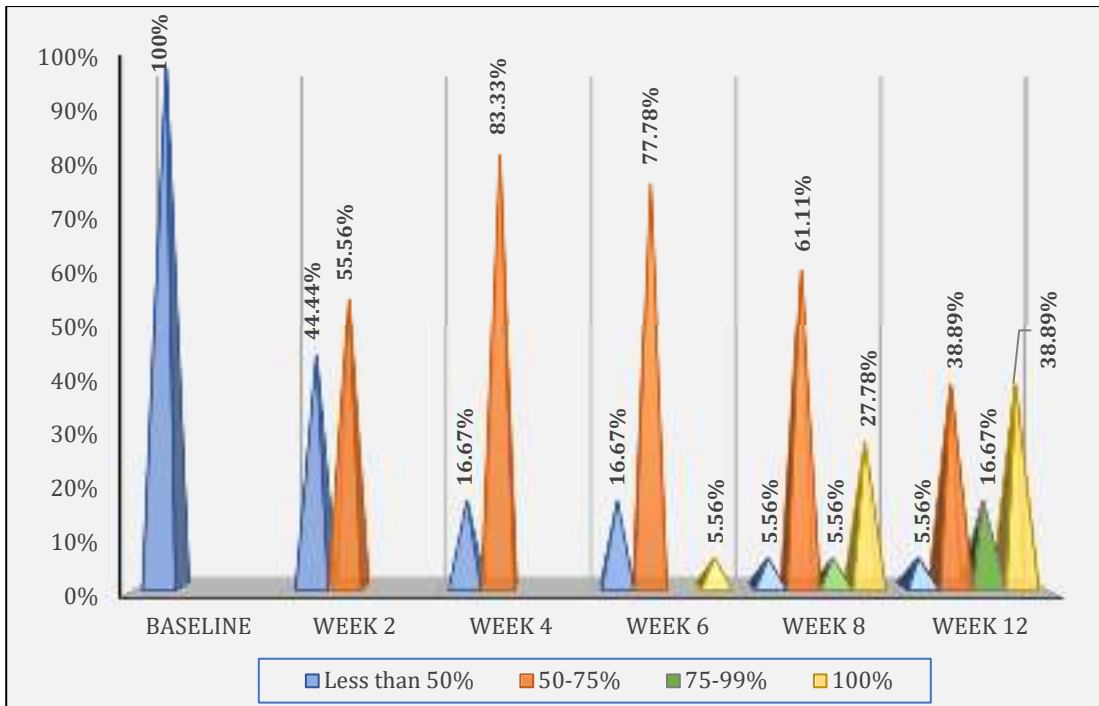
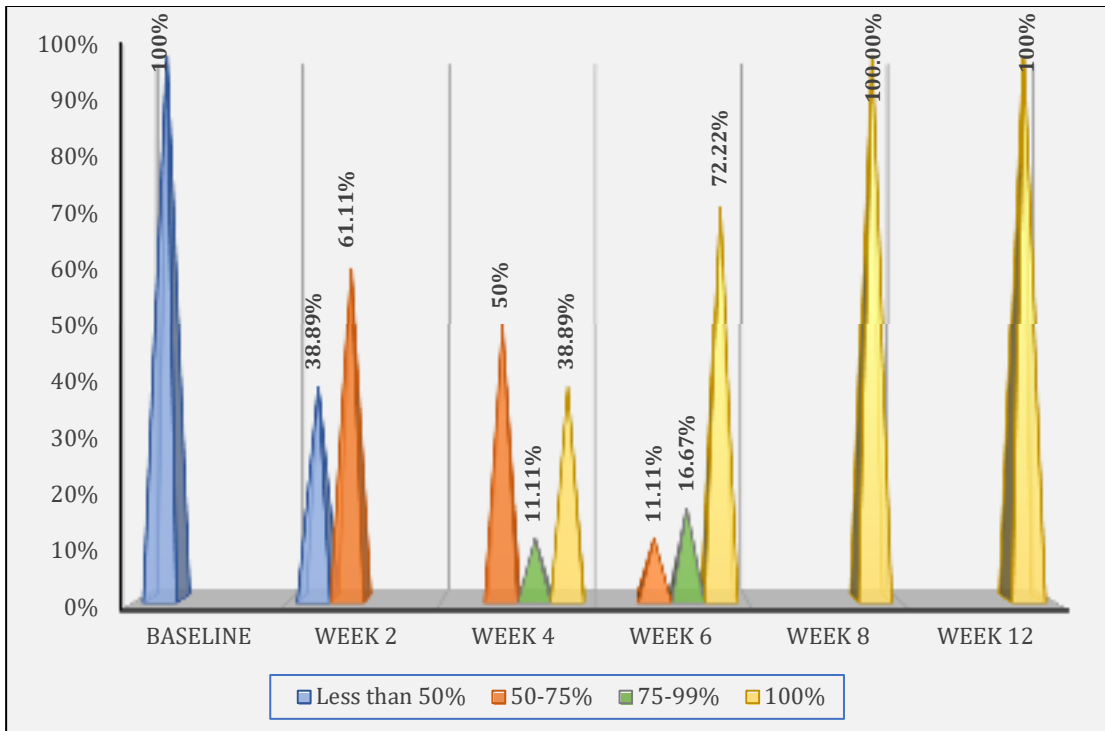


Chart 9: Distribution of VAS score over time points in MMR



DISCUSSION

Viral warts may present as cutaneous as well as mucosal lesions which are caused by various strains of human papilloma viruses. They are benign proliferations that can grow anywhere on the body.² Previous studies done for treatment of warts on extremities include comparison between antigens like *Candida albicans*, MMR vaccine, trichophyton; and tuberculin antigens such as purified protein derivative (PPD), mycobacterium w vaccine, and Bacillus-Calmette-Guerin (BCG).⁶ Literature lacks comparison between the safety and efficacy of cytotoxic therapy and immunotherapy.

This study was undertaken to do comparative evaluation between 5-FU (cytotoxic) and MMR (immunotherapy) and to study which modality is more efficacious and faster in terms of resolution.

36 patients with palmoplantar warts were included in this study, 18 subjects in MMR group and 18 subjects in 5-FU group.

In our study, in the MMR group (n=36, MMR group = 18), the mean age was 20.5 (range = 24+/-10.09), 14 years being the minimum age and 56 years being the maximum age. In the study done by Pushpinder et al¹⁴² in treatment of warts with intralesional MMR (n = 110), the mean age of the subjects included was 31.3+/-11.5 years (range = 19-62), 19 years being the minimum age and 62 years being the maximum age. When comparing our study with Pushpinder et al¹⁴² study, it was observed that the maximum number of patients fell in the age group of 21-40 years in their study, where as in our study the maximum number of patients were less than 20 years, but more than 12 years of age. In the study done by Shishira et al¹⁴¹ in the

treatment of warts by intralesional MMR vs Vitamin D3 (n=66), mean age of the subjects included was 27 +/-5.8. Both in Shirisha et al study and our study we have excluded patients of less than 12 years of age. In the study done by Amnesh Yazdanfar¹⁴³ et al in treatment of warts by intralesional 5-FU (n=40) the mean age of subjects included was 19+/-4.5 years (range =15 to 38 years). In the study done by Tahir Kamal et al¹⁴⁴ in treatment of warts with intralesional 5-FU (n=40) the mean age of the subjects included was 39.55+/-11.26 years (range =20 to 60 years).

In our study, in the 5-FU group (n=18), 6(33.33%) patients were females and 12(66.67%) patients were males. In the MMR group (n=18) also, 6(33.33%) patients were females and 12(66.67%) patients were males. Thus, a total (n=36) of 12(33.33%) patients were females and 24(66.67%) subjects were males in our study. So, the male to female ration in our study was 2:1 (M: F = 2:1). In the study done by Pushpinder et al¹⁴² (n=110), 61 men (59.8%) and 49 women (40.19%) were recruited and the male to female ratio was 1.2:1 (M: F = 1.2:1). In the study done by Amenesh Yazdanfar et al¹⁴³, (n = 40), 22 (64.7%) male patients and 12(35.2%) female patients were recruited. The male to female ratio here was 1.8:1(M: F = 1.8:1). In the study done by Tahir Kamal et al¹⁴⁴ (n=40), 16 (40%) male patients and 24(60%) female patients were recruited. The male to female ratio here was 2:3 (M: F = 2:3).

In our study (n = 36) we have included patients with only palmoplantar warts. Only 1(2.78%) patient in our study had both palmar and plantar warts. A total of 18(50%) patients had palmar warts, of which 11(61.11%) patients belonged to 5-FU group and 7(38.89%) patients belonged to MMR group. A total of 17(47.22%) patients had plantar warts, out of which 7(38.89%) patients belonged to 5-FU group and 10(55.56%) patients belonged to MMR group. 2 (5.55%) patients with plantar

warts had the subtype of mosaic warts and 4 (11.11%) patients with palmar warts had the subtype of subungual warts. In the study by Pushpinder et al¹⁴² (n=110) in the efficacy and safety of intralesional MMR in warts, 74(67.2%) patients had warts on dorsum of hands and feet, 29(26.4%) had palmoplantar warts, 1(0.9%) patient had periungual wart and 6(5.5%) patients had warts on multiple sites. In the study done by Shishira et al¹⁴¹ (n=66), the most common location of wart was palmoplantar location. The most common type of wart was verruca vulgaris followed by filiform warts and verruca plana. In a study by Amenesh Yazdanfar et al¹⁴³ (n=40), plantar and periungual warts were excluded. Verruca vulgaris was the only type of wart included in this study. In a study by Tahir Kamal et al¹⁴⁴ (n=40), 13(32.5%) patients had warts on hands, 19(47.5%) patients had warts on feet and 6(15%) patients had genital warts. In our study, only palmoplantar warts were included, where as in the other studies mentioned here different types of warts which were present on different locations on the body were included.

In our study (n=36), a total of 22(61.11%) patients had warts for only less than 6 months duration. A total of 11(30.56%) patients, had warts for a duration that ranged between 6 to 12 months. A total of 3(8.33%) patients had warts for a duration of warts for more than 12 months. The mean duration of warts in the 5-FU group was 7.44 +/- 5.93 months and the mean duration of warts in the MMR group was 7.17 +/- 6.96 months, which was almost similar in both the groups at baseline. In the study done by Pushpinder Singh Chauhan et al¹⁴² (n=110), 52(47.3%) patients had warts for a duration ranging between 1 to 12 months, 25(22.7%) patients between 13 to 24 months, 9(8.2%) patients between 25 to 36 months, 7(6.4%) patients between 37-48 months, 3(2.7%) patients between 49-60 months and 14(12.7%) patients had warts for

a duration of more than 60 months. In the study done by Shishira et al¹⁴¹ (n=66), the duration of warts ranged from 2 months to 6.5years.

In our study (n=36), in the MMR group (n=18),18(100%) patients showed complete clearance of warts at the end of 12 weeks. By 4th week (that is, 3 injections), 7(38.89%) patients had complete clearance of warts. By 6th week (that is, 4 injections), 13(72.22%) patients had complete clearance of warts and by 8th week (that is, 5 injections), 18(100%) patients had complete clearance of warts. By the end of 8 weeks itself, none of the patients in the MMR group had residual warts. All patients were followed up for two more weeks, that is till 12 weeks. In our study (n=36), in the 5-FU group out of 18 patients only 7(38.89%) patients had complete resolution of warts by the end of 12 weeks of intervention (that is, a total of 6 injections). By week 6 (that is, 4 injections), 1(5.56%) patient had complete clearance of warts. By week 8 (that is, 5 injections), 5(27.78%) patients had complete clearance of warts. By the end of 12 weeks (that is 6 injections), 11(61.11%) patients had residual warts. In the study done by Pushpinder et al¹⁴² a total of 110 subjects were included in the beginning of the study, of which, 51 subjects completed the study. Overall, 42(82.4%) subjects showed complete resolution of warts by the end of the 16 weeks, i.e. 8 weeks of intervention (5 doses of injection), followed by which patients were followed up every 4 weeks for another 8weeks. 9(17.6%) patients showed partial clearance of warts. 48% patients showed complete clearance of warts after 5 doses of injection, 15% patients showed clearance of warts by the end of 3 doses of injection. In 7.8% patient's warts subsided after giving just one dose of MMR injection. In the study by Shirisha et al¹⁴¹ in the treatment of warts with intralesional MMR a total of 66 subjects were included. The subjects were assigned randomly into two groups each consisting of 33 subjects. In the MMR group, (n=33), complete clearance of warts

was seen in 23(70%) patients at the end of 6 weeks of intervention and 3 months of follow up. Good response was seen in 2(6.1%) patients and minimal response was seen in 1(3.1%) patient. In the study done by Amenesh Yazdanfar et al¹⁴³ in the treatment of warts with intralesional 5-FU, a total of 40 subjects were included in the beginning, but only 34 subjects finished the study and complete resolution of warts was seen in 22(64.7%) patients at the end of 4 weeks of intervention with 5-FU intralesional injection and follow up at 1 month and 6 months. Partial resolution was seen in 6(17.6%) patients and no resolution of warts was seen in 6(17.6%) patients at the end of the study period. In the study done by Tahir Kamal et al¹⁴⁴ (n=40) with two weekly treatment regime with 5-FU, complete resolution of warts was seen in 30(75%) patients after 6 doses of intralesional 5-FU. 3 patients attained complete resolution warts after 3rd injection, 10 (25%) patients showed complete clearance of warts after 4th injection and 5 (12.5%) patients showed complete resolution after 5th injection.

In our study, the period of intervention and the total period of the study was the same, that is 12 weeks and no follow up was done afterwards, where as in Pushpinder et al¹⁴² study, the total period of intervention was 8 weeks followed by which the patients were followed up every 4 weeks for another 8 weeks. In the study done by Shirisha et al¹⁴¹, period of intervention was 6 weeks and patients were followed up for 3 months. In the study done by Amenesh Yazdanfar et al¹⁴³ period of intervention was 4 weeks and patients were followed up at 1 month and 6 months. In the study done by Tahir Kamal et al¹⁴⁴ period of intervention was 12 weeks followed by fortnightly follow ups for the next 2 months.

In our study, in the MMR group (n=18), the efficacy of intralesional MMR vaccine injection in treatment of warts was seen to be 100%, where as in Pushpinder et al¹⁴² study and Shirisha et al¹⁴¹ study, the efficacy of intralesional MMR vaccine therapy in treatment of warts was found to be 82.4% and 70% respectively. In our study, in the 5-FU group (n=18), the efficacy of intralesional 5-FU injection in treatment of warts was found to be 38.89%, where as in Tahir Kamal et al¹⁴⁴ study and Amenesh Yazdanfar et al¹⁴³ study the efficacy of intralesional 5-FU in the treatment of warts was found to be 75% and 64.7% respectively.

In our study, in the MMR group, at baseline, that is, the first visit (in the first visit patient received the first dose of injection), VAS score 100% was shown by 0 patients, VAS score 75-99% by 0 patients, VAS score 50-75% by 0 patients and VAS score less than 50% was seen in 18(100%) patients. At 2 weeks from baseline (2nd injection), VAS score 100% was seen in 0 patients, VAS score 75-99% was seen in 0 patients, VAS score 50-75% was seen in 11(61.11%) patients and VAS score less than 50% was seen in 7(38.89%) patients. At 4 weeks from baseline (3rd injection), VAS score 100% was seen in 7(38.39%) patients, VAS score 75-99% was seen in 2(11.11%) patients, VAS score 50-75% was seen in 9(50%) patients and VAS score less than 50% was seen in 0 patients. At 6 weeks from the first dose (4th injection), VAS score 100% was seen in 13(72.22%) patients, VAS score 75-99% was seen in 3(16.67%) patients, VAS score 50-75% was seen in 2(11.11%) patients and VAS score less than 50% was seen in 0 patients. At 8 weeks from the first dose (5th injection), VAS score 100% was seen in 18 (100%) patients, VAS score 75-99%, VAS 50-75% and VAS score less than 50% was seen in 0 patients. By the end of the study period that is 12 weeks, VAS score 100% was seen in all 18 patients.

In the study conducted by Pushpinder Singh Chauhan et al¹⁴², 51 patients completed the study and 42 (82.4%) showed complete clearance of warts and 9 (17.6%) patients showed partial response. 5 doses of MMR vaccine were given intralesionally with a 2-week interval between each dose. In this study at the 2nd dose, VAS score 100% was seen in 4(3.6%) patients, VAS score 75-99% was seen in 2(1.8%) patients, VAS score 50-74% was seen in 5(4.5%) patients, VAS score less than 50% was seen in 99(90%) patients, where the total number of subjects were 110. At 3rd dose, VAS score 100% was seen in 6(6.5%) patients, VAS score 75-99% was seen in 4(4.3%) patients, VAS score 50-74% was seen in 20(21.7%) patients, VAS score less than 50% was seen in 62(67.4%) patients, where the total number of subjects were 92. At 4th dose, VAS score 100% was seen in 11(15%) patients, VAS score 75-99% was seen in 7(9.6%) patients, VAS score 50-74% was seen in 22(30.1%) patients, VAS score less than 50% was seen in 33 patients (45.2%) patients, where the total number of subjects included was 73. At 5th dose, VAS score 100% was seen 5(9.3%) patients, VAS score 75-99% was seen in 14(25.9%) patients, VAS score 50-74% was seen in 13(24%) patients, VAS score less than 50% was seen in 22(40.7%) patients, where the total subjects included were 54. At 6th dose, VAS score 100% was seen in 12(48%) patients, VAS score 75-99% was seen in 1(4%) patient, VAS score 50-74% was seen in 5(20%) patients, VAS score less than 50% was seen in 7(28%) patients where the total number of subjects was 25. At 8weeks after dose 5, VAS score 100% was seen in 4(30.7%) patients, VAS score 75-99% was seen in 0 patients, VAS score 50-74% was seen in 7(53.8%) patients and VAS score less than 50% was seen in 0 patients. In a Study conducted by Shishira R Jartarkar et al¹⁴¹, they used Visual Analogue Scale (VAS) to assess the clinical improvement. In the MMR group in this study, VAS score 100% was seen in 23(69.7%) patients, VAS

score 75-99% was seen in 7(21.2%) patients, VAS score 50-74% was seen in 2(6.1%) patients and VAS score less than 50% was seen in 1(3%) patient. In our study, in the 5-FU group, at baseline that is at the first visit (at the first visit patient received the first dose) VAS score less than 50% was seen in 18(100%) patients. At 2nd dose, VAS score 100% was seen in 0 patients, VAS score 75-99% was seen in 0 patients, VAS score 50-75% was seen in 10(55.56%) patients and VAS score less than 50% was seen in 8(44.44%) patients. At 3rd dose, VAS score 100% was seen in 0 patients, VAS score 75-99% was seen in 0 patients, VAS score 50-75% was seen in 15(83.33%) patients and VAS score less than 50% was seen in 3(16.67%) patients. At 4th dose, VAS score 100% was seen in 1(5.56%) patient, VAS score 75-99% was seen in 0 patients, VAS score 50-75% was seen in 14(77.78%) patients and VAS score less than 50% was seen in 3(16.67%) patients. At 5th dose, VAS score 100% was seen in 4(22.22%) patients, VAS score 75-99% was seen in 1(5.56%) patient, VAS score 50-75% was seen in 11(61.11%) patients and VAS score less than 50% was seen in 1(5.56%) patient. At 6th dose, VAS score 100% was seen in 7(38.89%) patients, VAS score 75-99% was seen in 3(16.67%) patients, VAS score 50-75% was seen in 7(38.89%) patients and VAS score less than 50% was seen in 1(5.56%) patient. After the end of the study period, 11(61.11%) patients still had residual warts. In a study done by Tahir Kamal¹⁴⁴ et al, the total number of subjects included were 40. 30 (75%) patients had 75-100% improvement (that is excellent response) after 6 injections of intralesional 5-Flourouracil, 3 patients showed 75-100% improvement after second dose, 12 patients showed 75-100% improvement after the 4th dose and 5 patients showed 75-100% improvement after the 5th dose. 50-74% improvement (that is good response) was seen in 5 patients after 6 doses. 25-49% improvement (that is satisfactory response) was seen in 3 patients after 6 doses. Less than 25%

improvement (that is poor response) was seen in 2 patients after 6 doses. In a study done by Amenesh Yazdanfar et al¹⁴³, they have graded the therapeutic outcome as complete response, Partial response and no response. Here complete response was seen in 22 (64.7%) out of 34 patients, partial response was seen in 6 (17.6%) patients and no response was seen in 6(17.6%) patients by the end of 12 weeks.

In our study (n=36), 100% patients in both MMR and 5-FU group showed pain during injection. Similarly in the study by Pushpinder Chauhan et al¹⁴², except for pain in in the injection site, no other adverse effects were noted. In the study by Shishira et al¹⁴¹, side effects noted were flu-like symptoms in 4(12.1%) patients and pain during injection was noted in 20 (60.6%) patients in the MMR group. In the study by Amenesh Yazdanfar¹⁴³ et al the adverse effects noted were erythema and edema in 6 (17.6%) patients, hyperpigmentation in 6(17.6%) patients, hypopigmentation in 1(2.9%) patient, ulceration and necrosis in 4(11.7%) patients, scarring in 2(5.8%) patients and pain during injection in 34(100%) patients where as in our study, hyperpigmentation was noted in 4 (22.22%) cases in the 5-FU arm whereas all 18 (100%) patients complained of pain at the injection site. Compared to other studies like the study done by Pushpinder et al.¹⁴²and Shirisha et al¹⁴¹, our study had a longer period of intervention. In our study, the period of intervention and the total period of the study was the same, that is 12 weeks and no follow up was done afterwards, where as in Pushpinder et al¹⁴² study, the total period of intervention was 8 weeks followed by which the patients were followed up every 4 weeks for another 8 weeks. In the study done by Shirisha et al¹⁴¹, period of intervention was 6 weeks and patients were followed up for 3 months.

The sample size in our study was 36, with 18 in each group, where as in Pushpinder et al¹⁴² study and Shirisha et al¹⁴¹ study the sample sizes were 110 and 66 respectively.

We postulate that because of the differences in the sample size and period of intervention from the above studies, our study demonstrated a 100% resolution of warts in the MMR group, whereas, the resolution rates were 82.4% and 69.7% in Pushpinder et al¹⁴² study and Shirisha et al¹⁴¹ study respectively.

In our study, in the 5-FU group only 38.89% patients showed complete clearance of warts at the end of the study period, whereas other studies like Tahir Kamal et al.¹⁴⁴ study and Amenesh Yazdanfar et al.¹⁴³ study showed 75% and 64.7% efficacy.

Variation in the rate of resolution could be because of the type of warts chosen to be treated by us, i.e palmoplantar warts have greater viral load as compared to other types of warts. Also, some viral subtypes may respond differently to cytotoxic or immunotherapy.

CONCLUSION

In our study, it was found that MMR vaccine is a better treatment modality than 5-FU.

5-FU is an antimetabolite drug that causes cell cycle arrest, whereas MMR is an immunotherapeutic drug that induces the body's own immune response against HPV, thus helping in clearing HPV laden cells. 5-FU has a very localised, cytotoxic effect on the HPV laden cells whereas MMR vaccine induces a delayed type of hypersensitivity which helps in clearing the HPV laden cells. We have postulated that because of this difference in the mechanism of action, MMR vaccine showed better efficacy than 5-FU in this study.

When comparing immunotherapeutic methods with cytotoxic methods, it is found that scarring is seen in 30%¹⁴⁵ subjects, recurrence of warts in 30%¹⁴⁵ and pain leading to morbidity is seen in 64%¹⁴⁵ patients while using ablative methods to treat warts, whereas these adverse effects are not seen while using immunotherapy to treat warts.

Hence, we can conclude that immunotherapy and cytotoxic therapy is a safe, effective and cheap option for treatment of warts, especially palmoplantar warts.

The limitation of our study was that the sample size was small (n=36) and follow up of the patients beyond 12 weeks of study period was not done, so the rate of recurrence of warts in the MMR and 5-FU groups could not be compared and also, only palmoplantar warts were included in our study, so the effects of these therapeutic options on other types of warts could not be evaluated. Hence, trials with larger sample size and ones which include different variants of warts are required to further evaluate the effects of MMR vs 5-FU in the treatment of warts.

SUMMARY

Viral warts may present as cutaneous as well as mucosal lesions which are caused by various strains of human papilloma viruses. They are benign proliferations that can grow anywhere on the body.²

This study was undertaken to do comparative evaluation between 5-FU (cytotoxic) and MMR (immunotherapy) and to study which modality is more efficacious and faster in terms of resolution.

Our study included a total of 36 patients who were clinically diagnosed as having palmoplantar warts. These 36 patients were divided into two groups of 18 each using a randomization chart. The male to female ratio in our study was 2:1. The age of the subjects ranged from 14 to 56 years, mean age being 26.58 +/- 9.47 years.

In our study (n=36) only patients with palmoplantar warts were included. A total of 18 (50%) patients had palmar warts, of which 11(61.11%) patients belonged to 5-FU group (n=18) and 7(38.89%) patients belonged to MMR group (n=18). A total of 17(47.22%) patients had plantar warts, out of which 7(38.89%) patients belonged to 5-FU group (n=18) and 10(55.56%) patients belonged to MMR group (n=18). Only one (2.78%) patient had both palmar and plantar warts.

In our study (n=36), pain during injection was seen in all patients (100%) belonging to both MMR (n=18) and 5-FU groups (n=18). Hyperpigmentation around the lesions was seen in 4(22.22%) patients belonging to the 5-FU group.

From our study, we have found that intralesional MMR vaccine is efficacious than intralesional 5-Fluorouracil in the treatment of palmoplantar warts.

BIBLIOGRAPHY

1. Shruthi S Ghadgepatil, Sanjeev Gupta, and Yugal. K. Sharma. Clinicoepidemiological study of different types of warts. *Dermato Res Pract.*2016;2016
2. Rook's Textbook of Dermatology.9th ed.UK:John Wiley and sons Ltd:2016.P25.47,25.43,25.44,25.46.
3. Anukrtiti Srivasatava, B.C.Ghiya, Prasoon Soni, Hardik Dave, Ashok Dhanwal, R.D.Mehta. Efficacy of intralesional 5-FU in the treatment of palmo-plantar warts. *Int J Med Res Prof.*2016,2(3):60-63
4. Ahmad Nofal MD, Eman Nofal MD, Ayman Yosef MD and Hages Nofal MB, BCH(2014). Treatment of recalcitrant warts with intralesional mumps, measles, rubella vaccine: a promising approach. *International Journal of Dermatology*, 54(6),667-671.
5. Chesta Agarwal, Kapil Vyas, Asit Mittal, Ashok K Khare and Lalit K Gupta. A randomised double blind controlled study comparing the efficacy of intralesional MMR vaccine with normal saline in the treatment of cutaneous warts. *Indian Dermatol Online J.*2018,9(6): 389-393.
6. Adam Souhail, Aldahan, Stephanie Mlacker, Vidhi.V.Shah, Preetha Kamath, Mohammed Alsaidan, Sahal Samarkaudy and Keyvan Nouri(2016). Efficacy of intralesional immunotherapy for treatment of warts. A review of literature. *Dermatologic therapy*, 29(3),197-207.
7. Knipe DM, Howley PM, eds. *Field's virology* 6th edn. Newyork: Lippincott, Williams and Wilkin 2013.

8. Jones SK, Darville JM. Transmission of virus particles by cryotherapy and multi-use caustic pencils: a problem to dermatologists? *Br.J Dermatol* 1989;121:481-6.
9. Cardoso JC, Calonje E. Cutaneous manifestations of human papilloma viruses: A review. *Acta Dermatovenereol APA* 2011; 20: 145-54.
10. Burggink SC, Eekhof JAH, Eekhof JAH, Egberts PF, et al. Natural course of cutaneous warts among primary school children. A prospective cohort study. *Ann Fam Med* 2013;11:437-41
11. Marcoux D, Nadeau K, McCuaig C et al. Paediatric anogenital warts : A 7-year review of children referred to a tertiary – care hospital in Montreal, Canada. *Pediatr Dermatol* 2006;23: 199-207.
12. Laurent R, Coume-Marquet S, Kienzer JL et al. Comparative electron microscopic study of clear cells in epidermodysplasia verruciformis and flat warts. *Arch Dermatol Res* 1978;263:1-12.
13. Alisjahbana B, Dinata R, Sutedja E, et al. Disfiguring generalised verrucosis in an Indonesian man with idiopathic CD4 lymphopenia, *Arch Dermatol* 1984;120: 1314-17.
14. Zhu, D Fang H, Qiao J et al. Giant warts in a Chinese with epidermodysplasia verruciformis. *Ind J Dermatol Venereol Leprol*;2011;77: 730.
15. Keefe M, al-Ghamdi A, Coggon D, et al. Cutaneous warts in Butchers. *Br.J Dermatol* 1994, 130: 9-14.
16. Greenspan D, de Villiers EM, Greenspan JS et al. Unusual HPV types in oral warts in association with HIV infection. *J Oral Pathol* 1988;17:182-8.
17. Egawa K, Kitasato H, Honda Y, et al. Human Papillomavirus 57 identified in a plantar epidermoid cyst. *Br J Dermatol* 1998;138:510-4.

18. Egawa K. Eccrine – centred distribution of human papillomavirus 63 infection in the epidermis of the plantar skin.
19. Egawa K, Honda Y, Inaba Y, et al. Pigmented viral warts: A clinical and histopathological study including human papilloma virus typing. *Br J Dermatol* 1998; 138: 381-9.
20. Kinghorn GR. Genital warts: incidence of associated genital infections. *Br J Dermatol* 1978,99: 405-9
21. Gross G, Ikenberg H, Gissmann L, et al. Papillomavirus infection of the anogenital region: correlation between histology, clinical picture, and virus type. Proposal of a new nomenclature. *J invest Dermatol* 1985; 85: 147-52.
22. Praetorius F. HPV-associated diseases of oral mucosa. *Clin Dermatol*, 1997;15: 399-413.
23. Henke RP, Guerin-Reverchon J, Middle-Langoschk, et al. In situ detection of human papillomavirus type 13 and 32 in focal epithelial hyperplasia of oral mucosa. *J oral Pathol Med* 1989;18: 419-21.
24. Mounts P, Shah KV. Respiratory papillomatosis: etiological relation to genital tract papillomaviruses, *Prog Med Virol* 1984;29:90-114.
25. Derkay CS, Wiatrak B. Recurrent respiratory papillomatosis. A review. *Laryngoscope* 2008;118: 1236-47.
26. Jeong WJ, Park SW, Shin M et al. Presence of HPV type 6 in dysplasia and carcinoma arising from recurrent respiratory papillomatosis. *Head Neck* 2009;31:1095-101.
27. Minchotti S, Marsucci L, Serapiao Dos Santos M, et al. conjunctival papilloma and human papillomavirus: identification of HPV types by PCR. *Eur J Ophthalmol* 2006;16:473-7.

28. Segusa M, Tkanoy, Hashimura M, et al. HPV type 16 in conjunctival and junctional papilloma, dysplasia and squamous cell carcinoma. *J Clin Pathol*;995;48:1106-10.
29. Lawson W, Schlecht NF, Brandwein-Gensler M. The role of the Human papillomavirus in the pathogenesis of Schneiderian inverted papillomas an analytic over view of the evidence. *Head Neck Pathol* 2008;2: 49-59.
30. Massing AM, Epstein WL. Natural history of warts. A two – year study. *Arch Dermatol* 1963; 87: 306-10.
31. Iwatsuki K, Tagami H, Takigawa M, et al. Plane warts under spontaneous regression. Immunopathological study on cellular constituents leading to inflammatory reactions. *Ach Dermatol* 1986;122: 655-9.
32. Berman A, Domnitz JM, Winkelmann RK. Plantar warts recently turned black. Clinical and histopathological findings. *Arch Dermatol* 1982;118: 47-5.
33. Noel JC, Detremmerie O, Peny MO, et al. Transformation of common warts into squamous cell carcinoma on sun-exposed areas in an immunosuppressed patient. *Dermatology* 1994;189: 308-11.
34. Kreuter A, Gambichler T, Pfister H, Wieland U. Diversity of human papillomavirus types in periungual squamous cell carcinoma. *Br J Dermatol* 2009;161: 1262-9.
35. Bunney MH, Nolan MW, Williams DA. An assessment of methods of treating viral warts by comparative treatment trials based on a standard design. *Br J Dermatol* 2011;165: 233-46.
36. Focht DR 3rd, Spicer C, Fairchok MP. The efficacy of duct tape vs cryotherapy in the treatment of verruca vulgaris. *Arch Pediatr Adolesc Med* 2002;156: 971-4.

37. Jennings MB, Ricketti J, Guadara J, et al. Treatment for simple plantar verrucae: Monochloroacetic acid and 10% formaldehyde versus 10% formaldehyde alone. *J Am Pediatr Med Assoc* 2006;96:53-8.
38. Pezeshkpoor F, Banihashemi M, Yazdanpanah MJ et al. Comparative study of topical 80% trichloroacetic acid with 35% trichloroacetic acid in the treatment of common wart. *J Drugs Dermatol* 2012;11: e66-9.
39. Yazar S Basaran E. Efficacy of silver nitrate pencils in the treatment of common warts. *J. Dermatol* 1994;21: 329-33.
40. Durmazlor SP, Atacan D, Eskioglu F. Cantharidin treatment for recalcitrant facial flat warts: A preliminary study. *J Dermatolog Treat* 2009;20: 114-19.
41. Banihashemi M, Pezeshkpoor F, Yazdanpanah MJ, et al. Efficacy of 80% phenol solution in comparison with cryotherapy in the treatment of common warts of hand. *Singapore Med J* 2008;49: 1035-7.
42. Faghini G, Vali A, Radan M et al. A double blind randomized trial of local formic acid puncture technique in the treatment of common warts. *Skinmed* 2010; 8: 70-1.
43. Halsz CL. Treatment of warts with topical pyruvic acid: with and without added 5-Flourouracil. *Cutis* 1998;62: 283-5.
44. Borbujo J, Olmos O, Zamora E, et al. Treatment of verruca plana with 15% glycolic acid. *Int J Dermatol* 2000;39: 236-7.
45. Euvrad S, Verschoore M, Touraine JL, et al. Topical retinoids for warts and keratoses in transplant recipients. *Lancet* 1992;340: 48-9.
46. Ahmed I, Agarwal S, Ilchysyn A, et al. Liquid nitrogen cryotherapy of common warts: cryo-spray vs cotton wool bud. *Br J Dermatol* 2001;144: 1006-9.

47. Ross BS, Levine VJ, Nehal K, et al. Pulsed dye laser treatment of warts: an update. *Dermatol Surg* 1999;25: 377-80.
48. Sethuraman G, Richards KA, Hiremagalore RN, et al. Effectiveness of pulse dye laser in the treatment of recalcitrant warts in children. *Dermatol Surg* 2010; 36: 58-65.
49. Jim JT, Goh CL. Carbon dioxide laser treatment of periungual and subungual viral warts. *Australas J Dermatol* 1992;33: 87-91.
50. Sawchuk WS, Weber PJ, Lowry DR et al. Infectious papillomavirus in the vapor of warts treated with carbon dioxide laser or electrocoagulation: detection and protection. *J Am Acad Dermatol* 1989;2: 41-9.
51. Huo W, Gao X-H, Sun X-P et al. Local hyperthermia at 44°C for the treatment of plantar warts. A randomized, patient-blinded, placebo-controlled trial. *J Infect Dis* 2010;201: 1169-72.
52. Halasz CL. Treatment of common warts using the infrared coagulator. *J Dermatol Surg Oncol* 1994;20: 252-6.
53. Stender IM, Na R, Fogh et al. Photodynamic therapy with 5-aminolaevulinic acid or placebo for recalcitrant foot and hand warts: randomised double-blind trial. *Lancet* 2000;355: 963-6.
54. Mizuki D, Kaneko T, Hanada K. Successful treatment of topical photodynamic therapy using 5-aminolevulinic acid for plane warts. *Br J Dermatol* 2003;149: 1087-8.
55. Schrotes CA, KaasL, Waterval JJ, et al. Successful treatment of periungual warts using photodynamic therapy: a pilot study. *J Eur Acad Dermatol Venereol* 2007;21: 1170-4.

56. Fernandez-Guarino M, Harto A, Jaen P. Treatment of recalcitrant warts with pulsed dye laser MAL-PDT. *J Dermatolog Treat* 2011;22: 226-8.
57. Duthie DA, Mc Callum CD. Treatment of plantar warts with Elastoplast and podophyllin. *BMJ* 1951;2: 216-18.
58. Simone CD, Capizzi R, Carbone A, et al. Use of acitretin in a case of giant common warts in HIV-infected patient, *Eur J Dermatol* 2008;18: 346-7.
59. Katz RA. Isotretinoin treatment of recalcitrant warts in an immunocompromised man. *Arch Dermatol* 1986;122: 19-20.
60. Choi YL, Lee KJ, Kim WS, et al. Treatment of extensive and recalcitrant viral warts with acitretin. *Int J Dermatol* 2006;45: 480-2.
61. Al-Hamamy HR, Salman HA, Abdulsattar NA. Treatment of plane warts with a low dose oral isotretinoin. *ISRN Dermatol* 2012;2012: 163929.
62. Brogenalli P, Chiaretta A, Fragnelli B, et al. Intralesional cidofovir for the treatment of multiple and recalcitrant cutaneous warts. *Dermatol Ther* 2012;25: 468-71.
63. Field S, Irvine AD, Kirby B. The treatment of viral warts with topical cidofovir 1%: our experience of seven paediatric patients. *Br J Dermatol* 2009;160: 223-4.
64. Husak R, Zouboulis CC, Sander-Bahr C, et al. Refractory human papillomavirus-associated oral warts treated topically with 1-3% cidofovir solutions in human immunodeficiency virus type 1-infected patients. *Br J Dermatol* 2005;152: 590-1.
65. Thappa DM, Chiramel MJ. Evolving role of immunotherapy in the treatment of refractory warts. *Indian Dermatol Online J* 2016;7: 364-70.

66. Happle R, Hausen BM, Wiesner-Menzel L. Diphencyprone in the treatment of alopecia areata. *Acta Derm Venereol* (Stockh) 1983; 63 :49-52.
67. Buckley DA, Keane FM, Munn SE, Fuller LC, Higgins EM, Du Vivier AW. Recalcitrant viral warts treated by diphencyprone immunotherapy. *Br J Dermatol* 1999; 141 :292-296.
68. Lane PR, Hogan DJ. Diphencyprone. *J Am Acad Dermatol* 1988; 19 (Pt 1): 364-365.
69. Orecchia G, Douville H, Santagostino L, Rabbiosi G. Treatment of multiple relapsing warts with diphencyprone. *Dermatologica* 1988; 177 :225-231.
70. Choi MH, Seo SH, Kim IH, Son SW. Comparative study on the sustained efficacy of diphencyprone immunotherapy versus cryotherapy in viral warts. *Pediatr Dermatol* 2008; 25 :398-399.
71. Wilkerson MG, Henkin J, Wilkin JK. Diphenylcyclopropanone: examination for potential contaminants, mechanisms of sensitization, and photochemical stability. *J Am Acad Dermatol* 1984; 11 (Pt 1): 802-807.
72. Hausen BM, Stute J. Diphenylcyclopropanone: a strong contact sensitizer. *Chem Industry* 1980; 17 :699-700.
73. Rampen FH, Steijlen PM. Diphencyprone in the management of refractory palmoplantar and periungual warts: an open study. *Dermatology* 1996; 193 :236-238.
74. Choi Y, Kim do H, Jin SY, Lee AY, Lee SH. Topical immunotherapy with diphenylcyclopropanone is effective and preferred in the treatment of periungual warts. *Ann Dermatol* 2013; 25 :434-439.

75. Yoshizawa Y, Kitamura K, Maibach HI. Successful immunotherapy of chronic nodular prurigo with topical dinitrochlorobenzene. *Br J Dermatol* 1999; 141 :387-389.
76. Wilkerson MG, Connor TH, Wilkin JK. Dinitrochlorobenzene is inherently mutagenic in the presence of trace mutagenic contaminants. *Arch Dermatol* 1988; 124 :396-398.
77. Lee AN, Mallory SB. Contact immunotherapy with squaric acid dibutylester for the treatment of recalcitrant warts. *J Am Acad Dermatol* 1999; 41 :595-599.
78. Dall' Oglia F, Nasca MR, D'Agata O, Micali G. Adult and paediatric contact immunotherapy with squaric acid dibutylester (SADBE) for recurrent, multiple, resistant, mucocutaneous anogenital warts. *Sex Transm Infect* 2002; 78 :309-310.
79. Micali G, Nasca MR, Tedeschi A, Dal'Oglia F, Pulvirenti N. Use of squaric acid dibutylester (SADBE) for cutaneous warts in children. *Pediatr Dermatol* 2000; 17 :315-318.
80. Fowler JF Jr, Hodge SJ, Tobin GR. Persistent allergic contact dermatitis from squaric acid dibutyl ester. *J Am Acad Dermatol* 1993; 28 (Pt 1): 259-260.
81. Silverberg JI, Silverberg NB. Adjunctive trichloroacetic acid therapy enhances squaric acid response to verruca vulgaris. *J Drugs Dermatol* 2012; 11 :1228-1230.
82. Krebs HB. Treatment of extensive vulvar condylomata acuminata with topical 5-fluorouracil. *South Med J* 1990; 83 :761-764.
83. Pride GL. Treatment of large lower genital tract condylomata acuminata with topical 5-fluorouracil. *J Reprod Med* 1990; 35 :384-387.

84. Reid R, Greenberg MD, Lörincz AT, Daoud Y, Pizzuti D, Stoler M. Superficial laser vulvectomy. IV. Extended laser vaporization and adjunctive 5-fluorouracil therapy of human papillomavirus-associated vulvar disease. *Obstet Gynecol* 1990; 76 (3 Pt 1): 439-448.
85. Young S, Cohen GE. Treatment of verruca plantaris with a combination of topical fluorouracil and salicylic acid. *J Am Podiatr Med Assoc* 2005; 95 :366-369.
86. Zschocke I, Hartmann A, Schlöbe A, Cumberow R, Augustin M. Efficacy and benefit of a 5-FU/salicylic acid preparation in the therapy of common and plantar warts - systematic literature review and meta-analysis. *J Dtsch Dermatol Ges* 2004; 2 :187-193.
87. Luk NM, Tang WY, Tang NL, Chan SW, Wong JK, Hon KL, Lo KK. Topical 5-fluorouracil has no additional benefit in treating common warts with cryotherapy: a single-centre, double-blind, randomized, placebo-controlled trial. *Clin Exp Dermatol* 2006; 31 :394-397.
88. Böhle A, Büttner H, Jocham D. Primary treatment of condylomata acuminata with viable bacillus Calmette-Guerin. *J Urol* 2001; 165 :834-836.
89. Böhle A, Doehn C, Kausch I, Jocham D. Treatment of recurrent penile condylomata acuminata with external application and intraurethral instillation of bacillus Calmette-Guerin. *J Urol* 1998; 160 :394-396.
90. Metawea BM, Nashar AN, Kamal IK, et al. Application of viable Bacillus Calmette-Guerin topically as a potential therapeutic modality in condylomata acuminata. *J Urol* 2005; 65 :247-250.

91. Salem A, Nofal A, Hosny D. Treatment of common and plane warts in children with topical viable Bacillus Calmette-Guerin. *Pediatr Dermatol* 2013; 30 :60-63.
92. Edwards L, Ferenczy A, Eron L, Baker D, Owens ML, Fox TL, et al. Self-administered topical 5% imiquimod cream for external anogenital warts. HPV Study Group. *Human Papilloma Virus. Arch Dermatol* 1998; 134 :25-30.
93. Arican O, Guneri F, Bilgic K, Karaoglu A. Topical imiquimod 5% cream in external anogenital warts: a randomized, double-blind, placebo-controlled study. *J Dermatol* 2004; 31 :627-631.
94. Micali G, Dall'Oglio F, Nasca MR. An open label evaluation of the efficacy of imiquimod 5% cream in the treatment of recalcitrant subungual and periungual cutaneous warts. *J Dermatolog Treat* 2003; 14 :233-236.
95. Hoyme UB, Hagedorn M, Schindler AE, Schneede P, Hopfenmüller W, Schorn K, Eul A. Effect of adjuvant imiquimod 5% cream on sustained clearance of anogenital warts following laser treatment. *Infect Dis Obstet Gynecol* 2002; 10 :79-88.
96. Imagawa I, Suzuki H. Successful treatment of refractory warts with topical vitamin D3 derivative (maxacalcitol, 1alpha, 25-dihydroxy-22-oxacalcitriol) in 17 patients. *J Dermatol* 2007; 34 :264-266.
97. Egawa K, Ono T. Topical vitamin D3 derivatives for recalcitrant warts in three immunocompromised patients. *Br J Dermatol* 2004; 150 :374-376.
98. Labandeira J, Vázquez-Blanco M, Paredes C, Suárez-Penaranda JM, Toribio J. Efficacy of topical calcipotriol in the treatment of a giant viral wart. *Pediatr Dermatol* 2005; 22 :375-376.

99. Inaba H, Suzuki T, Adachi A, Tomita Y. Successful treatment of warts with a combination of maxacalcitol ointment and salicylic acid sticking plaster. *J Dermatol* 2006; 33 :383-385.
100. Balaji G. Sinecatechins: A better prospect for treating anogenital warts *Indian J Sex Transm Dis* 2014; 35 :75-76.
101. Tyring SK. Sinecatechins: effects on HPV-induced enzymes involved in inflammatory mediator generation. *J Clin Aesthet Dermatol* 2012; 5 :19-26.
102. Fantasia HC. Sinecatechins ointment 15% for the treatment of external genital warts. *Nurs Womens Health* 2012; 16 :418-422.
103. Nguyen HP, Doan HQ, Brunell DJ, Rady P, Tyring SK. Apoptotic gene expression in sinecatechins-treated external genital and perianal warts. *Viral Immunol* 2014; 27 :556-558.
104. Tockfleth E, Meyer T. The use of sinecatechins (polyphenon E) ointment for treatment of external genital warts. *Expert Opin Biol Ther* 2012; 12 :783-793.
105. Nofal A, Nofal E, Yosef A, Nofal H. Treatment of recalcitrant warts with intralesional measles, mumps, and rubella vaccine: a promising approach. *Int J Dermatol* 2015; 54 :667-671.
106. Johnson SM, Roberson PK, Horn TD. Intralesional injection of mumps or Candida skin test antigens: a novel immunotherapy for warts. *Arch Dermatol* 2001; 137 :451-455.
107. Horn TD, Johnson SM, Helm RM, Roberson PK. Intralesional immunotherapy of warts with mumps, Candida, and Trichophyton skin test antigens: a single-blinded, randomized, and controlled trial. *Arch Dermatol* 2005; 141 :589-594.
108. Chandrashekar L. Intralesional immunotherapy for the management of warts. *Indian J Dermatol Venereol Leprol* 2011; 77 :261-263.

109. Lewis TG, Nydorf ED. Intralesional bleomycin for warts: a review. *J Drugs Dermatol* 2006; 5 :499-504.
110. Lipke MM. An armamentarium of wart treatments. *Clin Med Res* 2006; 4 :273-293.
111. Agius E, Mooney JM, Bezzina AC, Yu RC. Dermojet delivery of bleomycin for the treatment of recalcitrant plantar warts. *J Dermatolog Treat* 2006; 17 :112-116.
112. Munn SE, Higgins E, Marshall M, Clement M. A new method of intralesional bleomycin therapy in the treatment of recalcitrant warts. *Br J Dermatol* 1996; 135 :969-971.
113. Soni P, Khandelwal K, Aara N, Ghiya BC, Mehta RD, Bumb RA. Efficacy of intralesional bleomycin in palmo-plantar and periungual warts. *J Cutan Aesthet Surg* 2011; 4 :188-191.
114. Blalock JE, Georgiades JA, Langford MP, Johnson HM. Purified human immune interferon has more potent anticellular activity than fibroblast or leukocyte interferon. *Cell Immunol* 1980; 49 :390-394.
115. Al-Zahrani D, Raddadi A, Massaad M, Keles S, Jabara HH, Chatila TA, Geha R. Successful interferon-alpha 2b therapy for unremitting warts in a patient with DOCK8 deficiency. *Clin Immunol* 2014; 153 :104-108.
116. Maronn M, Salm C, Lyon V, Galbraith S. One-year experience with candida antigen immunotherapy for warts and molluscum. *Pediatr Dermatol* 2008; 25 :189-192.
117. Perman M, Sterling JB, Gaspari A. The painful purple digit: an alarming complication of *Candida albicans* antigen treatment of recalcitrant warts. *Dermatitis* 2005; 16 :38-40.


118. Na CH, Choi H, Song SH, Kim MS, Shin BS. Two-year experience of using the measles, mumps and rubella vaccine as intralesional immunotherapy for warts. *Clin Exp Dermatol* 2014; 39 :583-589.
119. Nofal A, Nofal E. Intralesional immunotherapy of common warts: successful treatment with mumps, measles and rubella vaccine. *J Eur Acad Dermatol Venereol* 2010; 24 :1166-1170.
120. Gamil H, Elgharib I, Nofal A, Abd-Elaziz T. Intralesional immunotherapy of plantar warts: report of a new antigen combination. *J Am Acad Dermatol* 2010; 63 :40-43.
121. Sharma P, Mukherjee R, Talwar GP, Sarathchandra KG, Walia R, Parida SK, et al. Immunoprophylactic effects of the anti-leprosy Mw vaccine in household contacts of leprosy patients: clinical field trials with a follow up of 8-10 years. *Lepr Rev* 2005; 76 :127-143.
122. Singh S, Chouhan K, Gupta S. Intralesional immunotherapy with killed *Mycobacterium indicus pranii* vaccine for the treatment of extensive cutaneous warts. *Indian J Dermatol Venereol Leprol* 2014; 80 :509-514.
123. Rosales R, Rosales C. Immune therapy for human papillomaviruses-related cancers. *World J Clin Oncol* 2014; 5 :1002-1019.
124. Hast R, Bernell P, Hansson M. Cimetidine as an immune response modifier. *Med Oncol Tumor Pharmacother* 1989; 6 :111-113.
125. Cohler M, Schaffer JV. Successful treatment of massive anogenital warts in a two-year-old boy with imiquimod and cimetidine immunotherapy. *Pediatr Infect Dis J* 2009; 28 :1141.
126. Scheinfeld N, Rosenberg JD, Weinberg JM. Levamisole in dermatology: a review. *Am J Clin Dermatol* 2004; 5 :97-104.

127. Schou M, Helin P. Levamisole in a double-blind study: no effect on warts. *Acta Derm Venereol* 1977; 57 :449-454.
128. Gupta M, Mahajan VK, Mehta KS, Chauhan PS. Zinc therapy in dermatology: a review. *Dermatol Res Pract* 2014; 2014 :709152.
129. Al-Gurairi FT, Al-Waiz M, Sharquie KE. Oral zinc sulphate in the treatment of recalcitrant viral warts: randomized placebo-controlled clinical trial. *Br J Dermatol* 2002; 146 :423-431.
130. Mun JH, Kim SH, Jung DS, Ko HC, Kim BS, Kwon KS, Kim MB. Oral zinc sulfate treatment for viral warts: an open-label study. *J Dermatol* 2011; 38 :541-545.
131. Kim SK, Bae H. Acupuncture and immune modulation. *Auton Neurosci* 2010; 157 :38-41.
132. Ning S, Li F, Qian L, Xu D, Huang Y, Xiao M, et al. The successful treatment of flat warts with auricular acupuncture. *Int J Dermatol* 2012; 51 :211-215.
133. Fine PEM, Carneiro IAM, Milstein JB, Clements CJ. Issues relating to the use of BCG in immunization programs. Geneva: WHO: 1999.
134. Eassa BI, Abou-Bakr AA, El-Khalawany MA. Intradermal injection of PPD as a novel approach of immunotherapy in anogenital warts in pregnant women. *Dermatol Ther* 2011; 24 :137-143.
135. Abd-Elazeim FM, Mohammed GF, Fathy A, Mohamed RW. Evaluation of IL-12 serum level in patients with recalcitrant multiple common warts, treated by intralesional tuberculin antigen. *J Dermatolog Treat* 2014; 25 :264-267.
136. Srivastava PK, Bajaj AK. Autowart injection therapy for recalcitrant warts. *Indian J Dermatol* 2010; 55 :367-369.

137. Nischal KC, Sowmya CS, Swaroop MR, Agrawal DP, Basavaraj HB, Sathyanarayana BD. A novel modification of the autoimplantation therapy for the treatment of multiple, recurrent and palmoplantar warts. *J Cutan Aesthet Surg* 2012; 5 :26-29.
138. Moss WJ. Measles. *Lancet*. 2017 Dec 02;390 (10111):2490-2502.
139. Guneet Awal, MBBS, MD and Simplepreet Kaur MBBS, MD. Therapeutic outcome of intralesional immunotherapy in cutaneous warts using mumps, measles and rubella vaccine. A randomized, Placebo-controlled trial. *J Clin Aesthet Dermatol*. 2018 May; 11(5): 15-20.
140. Rater reliability testing of the physician wart assessment for common warts: A noninterventional, observational study. *Journal of the American Academy of Dermatology*, 81(4),j.jaad.2019.06.1153
141. Jartakar SR, Kadnur M, Mamatha P, Mishra SS, Spoorthy B. A comparative study of therapeutic efficacy of intralesional measles, mumps, and rubella vaccine and intralesional Vitamin D3 in the treatment of recurrent warts. *J Dermatol Dermatol Surg* 2021;25:14-7.
142. Pushpinder Singh Chauhan, Vikram K Mahajan, Karaninder Singh Mehta, Ritu Rawat and Vikas Sharma. The efficacy and safety of intralesional immunotherapy with measles, mumps, rubella virus vaccine for the treatment of common warts in adults. *Indian Dermatol Online J*.2019 Jan-Feb; 10(1): 19-26.
143. Amenesh Yazdanfar, MD, Mahmood Farshchian, MD, Morteza Fereydoonnejad, MD, and Mehdi Farshchian, MD. Treatment of common warts with an intralesional mixture of 5-Flourouracil, lidocaine and epinephrine: A

- prospective placebo-controlled, double blind randomized trial. *Dermatol Surg* 2008;34:656-659.
144. Tahir Kamal, Farhana, Ahmad, Usma Iftikhar. Efficacy and safety of intralesional 5-flourouracil in treatment of warts. *Journal of Pakistan Association of Dermatologists*. 2018; 28(3): 337-339.
145. An Armamentarium of wart treatments. Michelle M. Lipke, MPAS, PA-C. *Clin Med Res*. 2006 Dec;4(4): 273-293.

ANNEXURE-I- ETHICAL CLEARANCE LETTER

**K.J.E. ACADEMY OF HIGHER EDUCATION AND RESEARCH**
(Deemed - to-be University)
Accredited "A" Grade by NAAC (2nd Cycle) Placed in Category "A" by MHRD (Govt)

JAWAHARLAL NEHRU MEDICAL COLLEGE,
NEHRU NAGAR, BELAGAVI-590010 (KARNATAKA-INDIA)

Website: <http://www.jnmc.edu> Phone: (+ 91-0)831 Office : 2472550
E-Mail : jnmc@jnmc.edu Principal: 2471701
Fax No. +91 (0)831 - 2470759

Ref: MDC/DOME/ 312 Date: 24/12/2019


To,


REG NO: BT0119002 Leprosy,

J.N.Medical College,
BELAGAVI.

Sub: Institutional Ethical Clearance for the study.

With reference to the above, we wish to inform you that your proposed research project titled
"A COMPARATIVE ANALYSIS OF EFFICACY OF INTRALESIONAL MUMPS
MEASLES RUBELLA (MMR) VACCINE VERSUS 5-FLOUROURACIL (5FU) IN THE
TREATMENT OF PALMOPLANTAR WARTS - A RANDOMIZED CONTROL TRIAL",
is ethical and justifiable. The proposed research project has been cleared by the JNMC Institutional
Ethics Committee on Human Subjects Research.


(Dr. Anita Dalal)
Member Secretary
JNMC Institutional Ethics Committee
on Human Subjects Research,
J.N.Medical College, Belagavi.


(Dr. Roopa M Bellad)
Chairman,
JNMC Institutional Ethics Committee
on Human Subjects Research,
J.N.Medical College, Belagavi.

152

ANNEXURE II-INFORMED CONSENT

**TITLE OF THE STUDY: COMPARATIVE ANALYSIS OF EFFICACY OF
INTRALESIONAL MMR VACCINE VERSUS 5FLOUROURACIL (5FU) IN
THE TREATMENT OF VIRAL WARTS.**

The study is conducted by _____, Postgraduate (M.D) student in dermatology under the guidance of department of Dermatology, Venerology and Leprosy, JNMC, Belagavi.

Respected Sir/Madam,

We invite you to participate in our study as you are eligible for the same. During the study you will be asked some questions in detail regarding your present complaints.

Purpose of the study

Viral warts are very challenging to treat and none of the treatment modalities available now are successful in all patients uniformly. In this study we are comparing the efficacy of two intralesional agents ie.. MMR vaccine and 5Flourouracil. By this study we are intending to find out which of the two modalities gives faster clearance rates and less recurrence.

You are being requested to participate in this study because you have been diagnosed to have viral warts.

Procedure

Patients will be divided into two groups. Patients in the MMR vaccine group will be given 0.25ml of MMR vaccine which is to be injected intralesionally in all lesions and injection will be repeated in the same lesions at 2 weekly intervals until complete clearance or maximum 5/6 doses.

Patients in 5FU group will be given a solution of 5FU, Lidocaine and Epinephrine (4ml of 50mg/ml 5FU, 1ml of a mixture of 20mg/ml (2%) lidocaine, 0.125mg/ml epinephrine) up to maximum 5 injections intralesionally which is given at 2 weekly intervals until completely clearance or maximum 5/6 doses. Injection is to be given on all lesions.

On every visit the lesions will be photographed and measured using Vernier calliper . Repeated pictures and measurements will be taken on each visit for comparison.

Risks and Benefits:

The result of you taking part in this research would help health care providers towards a better understanding regarding the efficacy of 5Flourouracil vs MMR vaccine in the treatment of viral warts.

Alternatives:

If you decide not to participate in this study, you will still be receiving the usual standard care for your disease.

Privacy and confidentiality:

Your privacy will be respected and all information collected about you during the course of this study will be kept confidential. Your identity will remain undisclosed.

Relations with the Institutional policy:

The J N Medical College will provide, within the limitations of the laws of the State of Karnataka, facilities and medical attention to patients who suffer injuries as a result of participating in this project.

Financial incentives:

You shall not be receiving any payment or any financial incentives for participating in this study.

Authorization to publish results:

The results of this study may be published for scientific purpose or presented to a scientific group. Your identity, however, will be maintained confidential at all times.

Voluntary participation:

In case you need further information regarding your rights as a study participant, you may please contact Dr ROOPA M BELLAD, chairman of the ethical committee, J N Medical College, Belagavi.

STATEMENT OF CONSENT

I.D.NO:

--	--	--

I Mr/Ms/Mrs ----- volunteer and consent to participate in this study. I have read the consent document or it has been read to me in my vernacular language. I accept to participate in the study. All the information regarding this study is provided to me and I have understood the same. I have been given the opportunity to ask questions and obtain appropriate answers.

Participant's name:

Signature or left thumb print of participant:

Witness name:

Signature of witness:

Signature of the investigator:

Date:

STATEMENT OF ASSENT

I.D.NO:

--	--	--

I Mr/Ms/Mrs -----
parent/guardian/ward of----- consent to
enrol my daughter/son to participate in this study. I have read the consent document or
it has been read to me in my vernacular language. I give my acceptance on behalf of my
daughter/son for her/his participation in the study. All the information regarding this
study is provided to me and I have understood the same. I have been given the
opportunity to ask questions and obtain appropriate answers.

Participant's name:

Participant's parent/guardian name:

Signature or left thumb print of parent/guardian of participant:

Witness name:

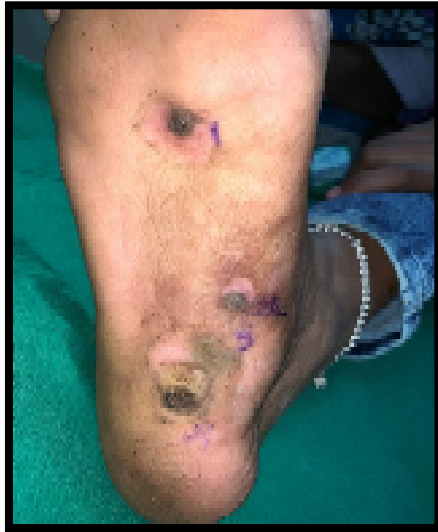Signature of witness:

Signature of the investigator:

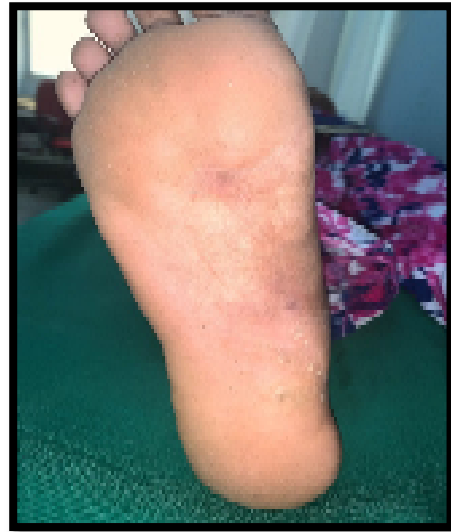Date:

ANNEXURE IV – PHOTOGRAPHS

PHOTOGRAPH 1: CLINICAL PICTURES OF A PATIENT IN THE MMR GROUP IN A CASE OF PLANTAR WART

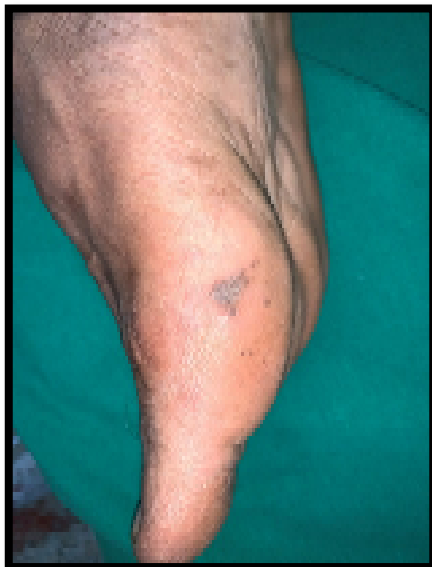

BASELINE

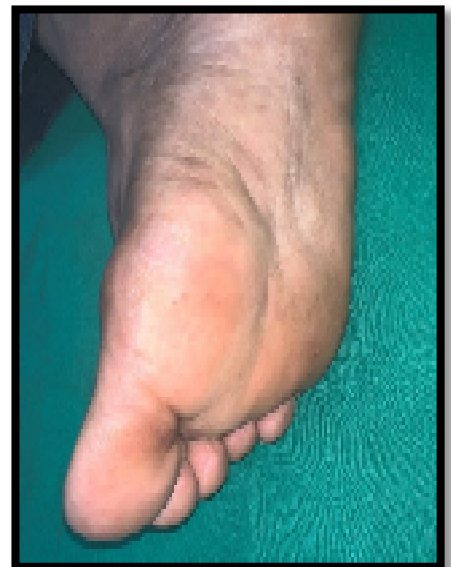

WEEK 6 (after 4 injections) – some residual warts seen. VAS - 75-99%.

PHOTOGRAPH 2: CLINICAL PICTURES OF A PATIENT IN THE MMR GROUP IN A CASE OF PLANTAR WART

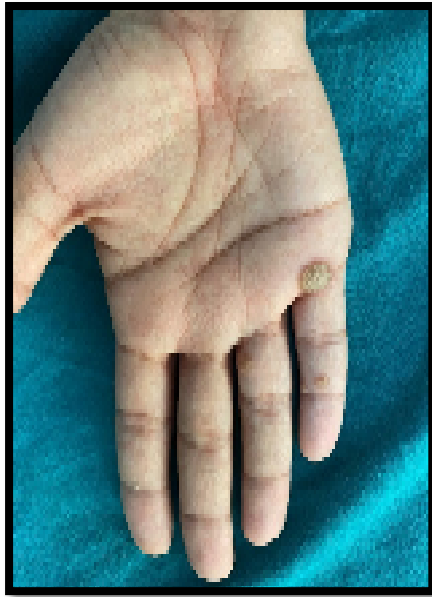

BASELINE

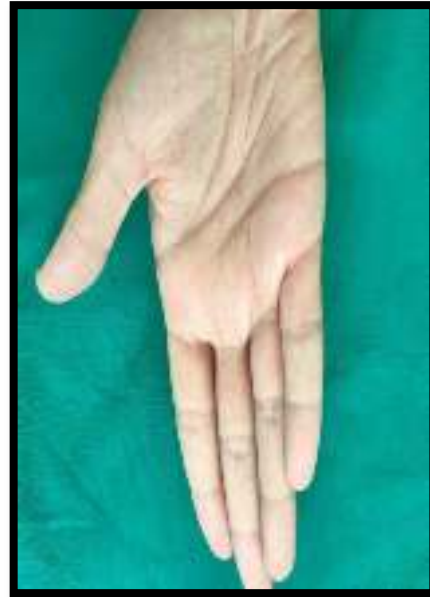

**WEEK 8 (after 5 injections)-
complete resolution of warts seen.
VAS – 100%**

PHOTOGRAPH 3: CLINICAL PICTURES OF A PATIENT IN THE MMR GROUP IN A CASE OF PALMAR WART

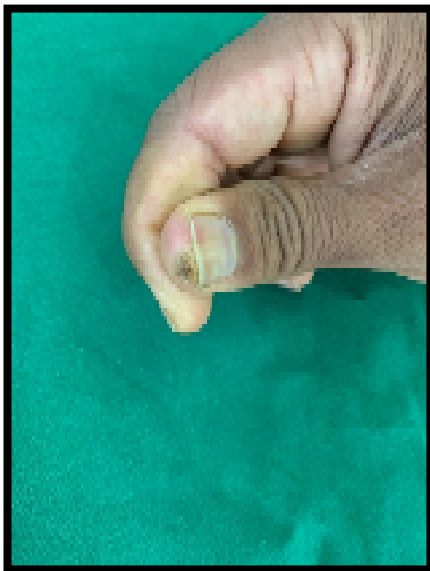

BASELINE

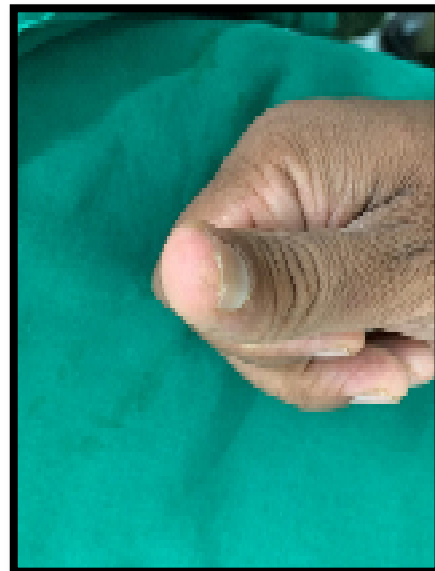


**WEEK 12(after 6 injections) –
complete resolution of warts seen.
VAS – 100%**

PHOTOGRAPH 4: CLINICAL PICTURES OF A PATIENT IN THE 5-FU GROUP IN A CASE OF SUBUNGUAL WART

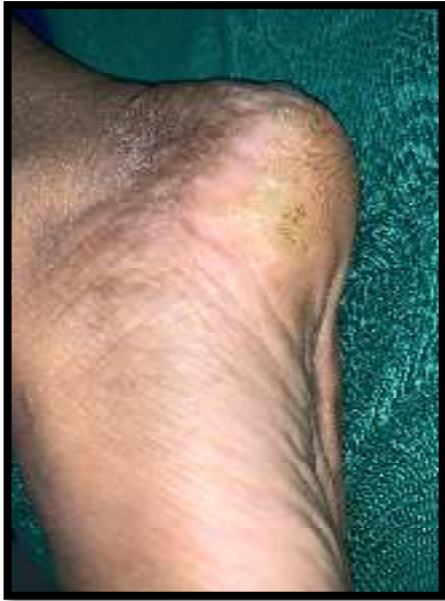

BASELINE

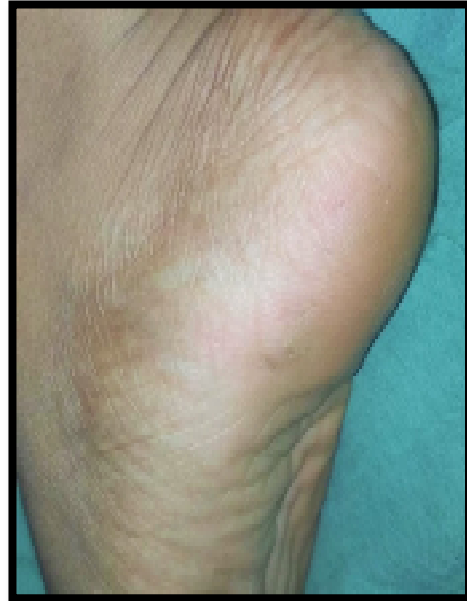

**WEEK 8 (after 5 injections) – some
residual warts seen. VAS 75-99%**

PHOTOGRAPH 5: CLINICAL PICTURES OF A PATIENT IN THE 5-FU GROUP IN A CASE OF MOSAIC WARTS

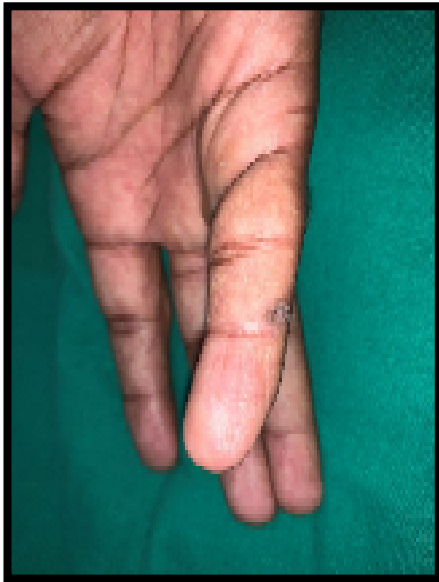

BASELINE

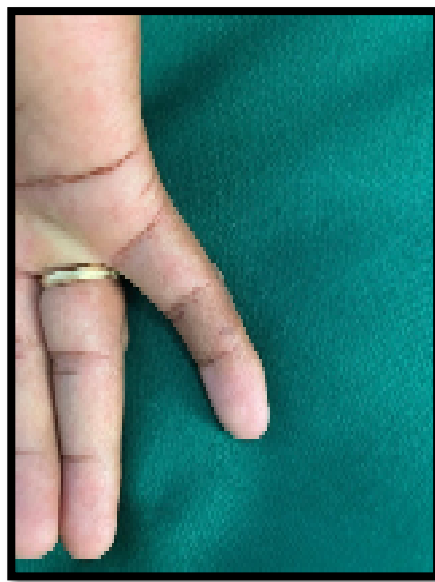


**WEEK 12 (after 6 injections)-
some residual warts seen. VAS 75-
99%**

PHOTOGRAPH 6: CLINICAL PICTURES OF A PATIENT IN THE 5-FU GROUP IN A CASE OF PALMAR WART



BASELINE



**WEEK 12 (after 6 injections) –
complete resolution of wart seen.
VAS – 100%**

ANNEXURES V - MASTER CHART

serial number	name	age	gender	type of wart	number of warts	location on the body	duration of warts	treatment group	physician's wart assessment (pwa)	pwa	pwa	pwa	pwa	pwa	vas score	vas	vas	vas	vas	vas	adverse effects
1	Rajani Durgannavar	26	female	palmar wart	3	right thumb	6 months	MMR	2	1	0				less than 50%	50-75%	100%				pain during injection
2	Basavaraj Kallappa	28	male	palmar wart	6	left hand	1 year	5FU	3	3	3	2	2	2	less than 50%	less than 50%	50-75%	50-75%	50-75%	50-75%	hyperpigmentation around the lesions, pain during injection
3	Ashwini Rajaram Kakade	23	female	plantar wart	11	right sole	2 months	5FU	3	3	3	3	3	1	less than 50%	less than 50%	50-75%	50-75%	50-75%	75-99%	hyperpigmentation around the lesions, pain during injection
4	Veena Raju Malagi	19	female	plantar wart	4	right sole	3 months	MMR	3	3	3	2	0		less than 50%	50-75%	50-75%	75-99%	100%		pain during injection
5	Sachin Appaji Patel	32	male	palmar wart	1	right thumb	2 months	5FU	2	2	3	2	2	1	less than 50%	less than 50%	less than 50%	50-75%	50-75%	75-99%	pain during injection
6	Sufiyan Jameer Mulla	20	male	plantar wart	13	left sole	6 months	MMR	2	2	2	0			less than 50%	50-75%	50-75%	100%			pain during injection
7	Shiva Amarappa Doddamani	27	male	palmar wart	1	right little finger	2 years	5FU	2	2	2	1	0		less than 50%	50-75%	50-75%	50-75%	100%		pain during injection
8	Drakashayani SL	51	female	palmar wart	1	right little finger	1 year	5FU	2	2	2	2	2	0	less than 50%	50-75%	50-75%	50-75%	50-75%	100%	pain during injection
9	Radhika Surendra Bhairannavar	20	female	plantar wart	2	right feet	4 months	5FU	2	2	2	2	2	2	less than 50%	less than 50%	50-75%	50-75%	50-75%	50-75%	pain during injection
10	Muthu Ramappa Talawar	23	male	plantar wart	4	left feet	1 month	5FU	2	2	2	2	2	2	less than 50%	50-75%	50-75%	50-75%	75-99%	75-99%	pain during injection
11	Vishnu Rarlad	21	male	plantar wart	1	left feet	1 month	MMR	3	3	0				less than 50%	50-75%	100%				pain during injection
12	Pradeep Kumar	34	male	plantar wart	1	right feet	4 months	MMR	3	3	2	0			less than 50%	50-75%	50-75%	100%			pain during injection
13	Bhimappa Mallappa Yunal	43	male	plantar wart	1	left feet	1 year	5FU	3	2	2	2	2	2	less than 50%	50-75%	50-75%	50-75%	50-75%	50-75%	pain during injection
14	Mohammed Wahi	20	male	palmar wart	4	right and left thumb	1 month	MMR	2	1	1	0			less than 50%	50-75%	50-75%	50-75%	100%		pain during injection
15	Maruti Ravidal Sunthkar	28	male	palmar wart	2	right thumb, left middle finger	4 months	5FU	3	3	2	2	2	2	less than 50%	less than 50%	50-75%	50-75%	50-75%	50-75%	pain during injection
16	naveen Chandra	20	male	plantar wart	3	left feet	1 month	MMR	3	3	0				less than 50%	less than 50%	100%				pain during injection
17	Amol Anand Hannurkar	27	male	palmar wart	1	right middle finger	3 months	5FU	2	2	2	2	2	2	less than 50%	less than 50%	less than 50%	less than 50%	less than 50%	less than 50%	pain during injection
18	Alka Anand Hannurkar	56	female	plantar wart	1	right big toe	6 months	MMR	2	2	2	0			less than 50%	less than 50%	50-75%	100%			pain during injection
19	Nidhi Sajeve	18	female	plantar wart	2	right sole, left sole	2 years	MMR	3	3	0				less than 50%	less than 50%	100%				pain during injection
20	Geetanjali Mahabaleshwar	29	female	palmar wart	1	left thumb	6 months	5FU	2	2	1	1	0		less than 50%	50-75%	50-75%	50-75%	100%		pain during injection
21	Abhishek Yuvraj Nikam	15	male	palmar wart	6	left palm, right index finger	8 months	MMR	2	2	1	1	0		less than 50%	50-75%	75-99%	75-99%	100%		pain during injection
22	Veena Kumar	39	female	palmar wart	2	left index finger	8 months	5FU	2	2	1	2	1	0	less than 50%	less than 50%	50-75%	less than 50%	50-75%	100%	pain during injection
23	satvik Kallappa	27	male	palmar wart	4	right thumb	1 year	5FU	2	2	1	1	1	1	less than 50%	50-75%	50-75%	50-75%	50-75%	50-75%	pain during injection
24	Sunil Shivaji	20	male	palmar wart	1	left palm	2 months	5FU	2	2	1	0			less than 50%	50-75%	50-75%	100%			pain during injection

serial number	name	age	gender	type of wart	number of warts	location on the body	duration of warts	treatment group	physician's wart assessment (pwa)	pwa	pwa	pwa	pwa	pwa	vas score	vas	vas	vas	vas	vas	adverse effects
25	Sandesh Balakrishna	26	male	plantar wart	1	right feet	1 year	5FU	3	3	3	3	3	3	less than 50%	50-75%	50-75%	50-75%	50-75%	50-75%	pain during injection, hyperpigmentation around the lesion
26	deepika V Ganapathi	25	female	palmar wart	5	right palm	1 year	MMR	3	3	3	0			less than 50 %	less than 50%	50-75%	100%			pain during injection
27	Abhishek Kabra	26	male	palmar wart	1	left index finger	1 month	MMR	1	1	0				less than 50%	50-75%	100%				pain during injection
28	swapnil annasaheb Bachagal	23	male	plantar wart	1	right 4th toe	5 months	MMR	3	3	3	0			less than 50%	less than 50%	75-99%	100%			pain during injection
29	Pradnya Raju Hulgekar	14	female	plantar wart	5	right sole	3 months	MMR	3	3	3	1	0		less than 50%	50-75%	50-75%	75-99%	100%		pain during injection
30	Adesh Patil	27	male	palmar wart	2	left palm	9 months	5FU	2	2	1	1	0		less than 50%	50-75%	50-75%	50-75%	100%		pain during injection
31	Safar Otari	38	male	palmar and plantar wart	3	sole, subungual wart	6 months	MMR	2	2	1	0			less than 50%	50-75%	50-75%	50-75%	100%		pain during injection
32	Yogesh Appayya Rajgatar	20	male	plantar wart	1	right sole	2 years	MMR	3	3	3	0			less than 50%	less than 50%	50-75%	100%			pain during injection
33	Devdan Jairaj Kalpal	20	male	plantar wart	1	right feet	1 month	5FU	3	3	3	3	3	2	less than 50%	less than 50%	less than 50%	less than 50%	50-75%	50-75%	pain during injection, hyperpigmentation around the lesions
34	Basagouda Kadagouda patil	22	male	palmar wart	1	right palm	6 months	MMR	2	2	0				less than 50%	50-75%	100%				pain during injection
35	Aswini Desai	35	female	plantar wart	2	right and left sole	8 months	5FU	3	3	2	1	0		less than 50%	50-75%	50-75%	50-75%	100%		pain during injection
36	Santhosh Kumar Shreeshail	15	male	palmar wart	2	right ring finger	1 year	MMR	2	2	0				less than 50%	less than 50%	100%				pain during injection


ANNEXURE-VI

KEY TO MASTER CHART

MMR	-	MUMPS MEASLES RUBELLA
5-FU	-	5-FLOUROURACIL
PWA	-	PHYSICIAN'S WART ASSESMENT
VAS	-	VISUAL ANALOGUE SCALE



Introduction



Objectives



Review of Literature



Methodology



Results



Discussion



Conclusion



Limitations




Recommendations



Summary



Bibliography



Annexure-I



Annexure-II



Annexure-III



Annexure-IV



Annexure-V
