

**“ EXTENDED TOTALLY EXTRAPERITONEAL REPAIR
(eTEP) VS CONVENTIONAL LAPAROSCOPIC REPAIR
WITH DEFECT CLOSURE (IPOM plus) FOR UMBILICAL
HERNIAS IN DR. PRABHAKAR KORE CHARITABLE
HOSPITAL FOR A PERIOD OF 1 YEAR”**

BY

REGISTRATION NO: BH0121018

Dissertation

*Submitted to the KLE Academy of Higher Education and
Research, Belagavi, Karnataka*

In Partial Fulfilment

of the Requirements for the Degree of

M.S. GENERAL SURGERY

**DEPARTMENT OF GENERAL SURGERY
JAWAHARLAL NEHRU MEDICAL COLLEGE,
BELAGAVI, KARNATAKA**

DECEMBER 2024/JANUARY 2025

KLE ACADEMY OF HIGHER EDUCATION AND RESEARCH,
BELAGAVI, KARNATAKA.

Endorsement

This is to certify that the dissertation entitled "EXTENDED TOTALLY EXTRAPERITONEAL REPAIR (ETEP) VS CONVENTIONAL LAPAROSCOPIC REPAIR WITH DEFECT CLOSURE (IPOM +) FOR UMBILICAL HERNIAS IN DR. PRABHAKAR KORE CHARITABLE HOSPITAL FOR A PERIOD OF 1 YEAR" is a bonafide research work done by REG NO. BH0121018.


Dr. SHRISHAIL C. METGUD,MS

Professor & Head, Dept. of General Surgery
J.N. Medical College, BELAGAVI
Department of General Surgery,

KAHER's J. N. Medical College,
Belagavi

Date: 01/07/24
Place: Belagavi


Dr. N. S. MAHANTASHETTI,MD

Principal,

KAHER's J. N. Medical College,

Belagavi

PRINCIPAL
J.N. Medical College,
BELAGAVI- 596 016



Date:
Place: Belagavi

UNDERTAKING

I, **Reg no- BH0121018**, hereby declare that the information and the data mentioned in my dissertation “**EXTENDED TOTALLY EXTRAPERITONEAL REPAIR (eTEP) VS CONVENTIONAL LAPAROSCOPIC REPAIR WITH DEFECT CLOSURE (IPOM plus) FOR UMBILICAL HERNIAS**” Belongs to me and is original. I am aware of the definition of plagiarism as detailed below:

An act or instance of using or closely imitating the language and thoughts of another author without authorisation and the representation of author’s work as one’s own, as by not crediting the original author.

A piece of writing or work reflecting such unauthorised use or imitation.

The deliberate or reckless representation of author’s words, thoughts or ideas as one’s own without attribution in connection with submission of academic work, whether graded or otherwise.

I hereby declare that the dissertation prepared by me is original one and does not involve plagiarism anywhere. In case at a later stage, it is found that I have indulged in plagiarism, then I am responsible for the same and the institution is at the liberty to take any disciplinary action against me including cancellation of dissertation or any other penalties imposed by the university.

Date: 02/07/2024
Place: Belagavi



Reg no- BH0121018

PLAGIARISM CERTIFICATE



JAWAHARLAL NEHRU MEDICAL COLLEGE

(A constituent unit of KLE Academy of Higher Education & Research Deemed-to-be-University)

(Recognized by National Medical Commission, New Delhi)

Accredited 'A+' Grade by NAAC (3rd Cycle)

Placed in Category 'A' by MoE (GoI)



Nehru Nagar, Belagavi- 590 010, Karnataka, INDIA

0831 - 2471350

0831 - 2470759

www.jnmc.edu

Principal@jnmc.edu

Ref No: MDC/PG/


Date: 01-07-2024

"ACCEPTANCE LETTER"

The softcopy of thesis entitled: "EXTENDED TOTALLY EXTRAPERITONEAL REPAIR (ETEP) VS CONVENTIONAL LAPAROSCOPIC REPAIR WITH DEFECT CLOSURE (IPOM +) FOR UMBILICAL HERNIAS IN DR. PRABHAKAR KORE CHARITABLE HOSPITAL FOR A PERIOD OF 1 YEAR" has been submitted for anti-plagiarism check through Turnitin software. The scan has been carried out and the scanned output reveals a match percentage of 10% which is within the acceptable limits of 10% as per the guidelines given by UGC.


Guide.




Dr. (Mrs.) N.S. Mahantashetti.
Chairperson-Antiplagiarism Committee &
Principal,
J. N. Medical College, Belagavi.

To,
Reg. No. BH0121018
Postgraduate Student,
2021-22 Batch,
Department of General Surgery
J. N. Medical College, Belagavi.



K.L.E. ACADEMY OF HIGHER EDUCATION AND RESEARCH
(Deemed to be University)

Accredited 'A+' Grade by NAAC in (3rd Cycle) Placed in Category 'A' by MHRD (GoI)

JNMC INSTITUTIONAL ETHICS COMMITTEE
JAWAHARLAL NEHRU MEDICAL COLLEGE,
NEHRU NAGAR, BELAGAVI-590010 (KARNATAKA-INDIA)

Website: <http://www.jnmc.edu>
E-Mail : dome@jnmc.edu

Phone: (+ 91-(0)831 Office : 2472550
Principal: 2471701
Fax No. +91 (0)831 – 2470759

Ref No.MDC/JNMCIEC/ 222

Date: 15/11/2022

To,



J. N. Medical College,
BELAGAVI.

Sub: Institutional Ethical Clearance for the study.

With reference to the above, we wish to inform you that your proposed research project titled "ETEP VS IPOM: EXTENDED TOTALLY EXTRAPERITONEAL REPAIR (ETEP) VS CONVENTIONAL LAPAROSCOPIC REPAIR WITH DEFECT CLOSURE (IPOM+) FOR UMBILICAL HERNIAS IN DR. PRABHAKAR KORE CHARITABLE HOSPITAL FOR A PERIOD 1 YEAR" is ethical and justifiable. The proposed research project has been cleared by the JNMC Institutional Ethics Committee.

(Dr. Smita Sonoli)
Member Secretary

JNMC Institutional Ethics Committee
J.N.Medical College, Belagavi.

(Dr. Harsha Hegde)
Chairman,

JNMC Institutional Ethics Committee
J.N.Medical College, Belagavi

ABBREVIATIONS

eTEP: Extended Totally Extra

peritoneal Repair

IPOM: Intraperitoneal Onlay Mesh

IPOM+: Intraperitoneal Onlay Mesh with Defect Closure

ABSTRACT

Background: Minimally invasive techniques have revolutionized hernia repair, offering advantages such as reduced blood loss, fewer complications, and shorter hospital stays compared to open surgery. The conventional laparoscopic approach (lap IPOM) for ventral hernias, while effective, can lead to complications like high postoperative pain and fibrous adhesions due to intra-abdominal mesh fixation. In contrast, the Extended Totally Extraperitoneal Repair (eTEP) has gained popularity for its potential to minimize complications and improve long-term outcomes. This study aimed to compare the clinical outcomes, specifically postoperative pain and functional recovery, between eTEP and lap IPOM techniques for umbilical hernia repair in an Indian population.

Material and Methods: A randomized observational study was conducted at KLES Dr. Prabhakar Kore Hospital and MRC, Belgavi, from January 2023 to December 2023. Sixty patients meeting inclusion criteria were divided into two groups: Group A underwent lap IPOM, and Group B underwent eTEP. Clinical parameters including operative time, postoperative pain scores, seroma formation, hospital stay duration, and wound infection rates were compared between the groups using appropriate statistical tests.

Results: The mean age of patients was 48.15 years, with a male predominance. Umbilical hernia was the primary diagnosis in both groups. Group A had significantly shorter operative times than Group B ($p < 0.05$). However, Group B exhibited significantly lower postoperative pain scores on day 1, day 7, 1st month, and 3rd month ($p < 0.05$). Seroma formation rates were similar between the groups, and Group B had a shorter mean hospital stay (5.8 days vs. 6.8 days in Group A, $p < 0.05$). Wound infection rates did not differ significantly between the groups.

Conclusion: In this study, eTEP demonstrated advantages over lap IPOM for umbilical hernia repair, including reduced postoperative pain and shorter hospital stays. Although lap IPOM offered quicker surgery, eTEP appears to provide superior postoperative outcomes and patient comfort. These findings support the consideration of eTEP as a preferred approach for selected patients undergoing umbilical hernia repair. Further research with larger cohorts is necessary to validate these results and optimize surgical strategies.

Keywords: Umbilical hernia, laparoscopic surgery, eTEP, IPOM+, minimally invasive surgery, postoperative pain.

TABLE OF CONTENTS

ABBREVIATIONS	V
ABSTRACT.....	VII
LIST OF TABLES	X
LIST OF FIGURES	XI
INTRODUCTION	1
REVIEW OF LITERATURE	2
AIMS & OBJECTIVES	27
MATERIAL & METHOD.....	28
STATISTICAL ANALYSIS	31
RESULTS	32
DISCUSSION.....	41
SUMMARY	45
CONCLUSION.....	47
REFERENCE.....	48
ANNEXURE.....	56
MASTERCHART.....	67

LIST OF TABLES

Table 1: Comparison of the mean age between the groups	32
Table 2: Comparison of the gender distribution between the groups	33
Table 3: Comparison of the diagnosis of patients between the groups.....	34
Table 4: Comparison of the operative time between the groups	35
Table 5: Comparison of the pain score between the groups	36
Table 6: Comparison of presence of seroma between the groups	38
Table 7: Comparison of the hospital stay between the groups	39
Table 8: Comparison of the presence of wound infection between the groups	40

LIST OF FIGURES

Figure 1: Abdominal wall hernias.....	5
Figure 2: Umbilical hernia	7
Figure 3: Umbilical cord development third to fifth week gestations	9
Figure 4: Overview of management of umbilical hernia in children.....	14
Figure 5: Umbilical hernia repair.....	15
Figure 6: Comparison of the mean age between the groups	33
Figure 7: Comparison of the gender distribution between the groups.....	34
Figure 8: Comparison of the diagnosis of patients between the groups	35
Figure 9: Comparison of the operative time between the groups	36
Figure 10: Comparison of the pain score between the groups.....	37
Figure 11: Comparison of presence of seroma between the groups	38
Figure 12: Comparison of the hospital stay between the groups	39
Figure 13: Comparison of the presence of wound infection between the groups.....	40

INTRODUCTION

Laparoscopic ventral or incisional hernia repair became feasible in 1993 because to the advent of minimally invasive surgery in the early 1990s. The approach to minimally invasive repair of ventral and incisional hernias has evolved significantly over the past decade.¹ Although Intra Peritoneal Onlay Mesh (IPOM) remains the most widely performed technique, it is not without issues such as pain and complications linked to the intraperitoneal placement of the mesh. Consequently, several newer techniques have been developed recently to address these challenges.²⁻⁴

Since extended completely extraperitoneal repair (eTEP) is linked to low rates of surgical-site infections and recurrence in long-term follow-up, it has become a popular treatment for open ventral hernias.⁵⁻⁷ Additionally, because the mesh is positioned outside of the intra-abdominal cavity, it minimizes intra-abdominal problems and restores the functioning of the abdominal wall.

In the context of the Indian population, where hernias are relatively common due to factors such as genetics, lifestyle, and socioeconomic status, the adoption of advanced techniques like holds significant importance. Limited literature is available among the Indian population to assess the outcome among the patients. Hence this study was designed to address the lacunae in the literature.

REVIEW OF LITERATURE

An organ or portion of an organ that protrudes through the bodily wall that typically confines it is known as a hernia. Usually, abdominal wall hernias are categorized based on their genesis or location. When an abdominal wall hernia is discovered, it is best to have a surgeon examine it. The size and location of the hernia determine the type of repair that is necessary.⁸

“The Greek word "Hernias," which means "bud" and refers to an outgrowth, protrusion, or bulge, is where the term "hernia" originates. Hernia is a Latin term meaning rip or rupture. About a millennium ago, hernias were first identified. The upright attitude that man has taken during the revolutionary process is most likely the cause of this. Hernias were treated in a variety of methods using readily accessible home remedies, including as bandages, ointments, poultices, and localized mixtures. Long before Hippocrates, cutting and counteracting techniques were widespread in India, China, and Japan.“

“Ambrose Pare was fully aware of ombeloccele, as he detailed in his 1634 book *The Works*. Astly Cooper (1804) invented the one-stage repair of minor omphalocele and was the first to describe an effective therapy for exompholos.”⁹

“Transversalis fascia was identified by Astley Cooper, who also noted that this layer served as the primary defense against herniation. In 1891, Lucas Championere is said to have been among the pioneers of the overlapping fascia method. Arroyo et al. conducted a limited number of randomized clinical studies including 200 participants in Spain. Their findings demonstrated a definite difference in the effectiveness of main suture and mesh healing. In contrast, the recurrence rate of the latter was just 1% following the use of a tension-free mesh repair.”^{10,11}

Umbilical hernias are common in adults. They are seen more in overweight people and in women, especially after pregnancy. They tend to get bigger over time.

Sometimes, smaller hernias that show no symptoms can be monitored. Patients who have significant medical issues may be at higher risk during surgery.

If surgery is not performed, there is a chance that a portion of the intestine or some fat will get imprisoned in the hernia and be difficult to re-enter. Usually, this hurts. In the event that this area's blood supply is severed (strangulation), immediate surgery is required. The swelling region may get blue or darker, and you may feel queasy or vomit.

Surgeons frequently advise individuals to get their umbilical hernias repaired in order to prevent this issue. Hernias that hurt or develop bigger can also be surgically repaired. Through surgery, any holes are sealed and the weakening fascia of the abdominal wall is stabilized.

Infection can impede the use of synthetic mesh even with aseptic procedures and perioperative prophylactic medicines. When these issues arise, the patient and the surgeon are presented with a challenging scenario that frequently calls for several surgical procedures. According to published research, the risk of infection after polytetrafluoroethylene (PTFE) mesh hernia surgery might reach 10%.¹²

The postoperative complications associated with mesh hernioplasty were seroma and surgical site infection. The important factors affecting the occurrence of complications were diabetes mellitus, obesity, smoking, hypoproteinemia, size of fascial defect, and number of defects.^{13,14} Small umbilical hernias are often successfully repaired with suture, while larger hernias may require a suitable mesh.^{15,16}

Brief anatomy

The abdominal wall is made up of overlapping layers of muscles and connective tissue that enclose and protect the intra-abdominal organs while also allowing for mobility and breathing.¹⁷

In the muscles of the abdominal wall, the xiphoid process and costal margins create an approximately cylindrical depression that is bounded on top by these structures and on the bottom by the pubic symphysis and iliac crests. “The two major pillars of the rectus abdominis muscles fuse together to produce the linea alba at the midline; laterally, they unite with a triple layer of flat muscles from the transversus abdominis, internal oblique, and external oblique (also referred to as the oblique muscles)”¹⁸ Each rectus muscle is encased in a rectus sheath made up of fibers from the lateral flat muscles' aponeurosis, the composition of which varies according on the location.

The abdominal wall muscles are supplied by the lumbar and intercostal arteries, as well as a deep circumflex branch of the iliac artery. The intercostal and lumbar nerves pierce the abdominal wall between the internal oblique and transversus abdominis muscles.

Classification of abdominal wall hernias¹⁹

They are commonly classified based on their location,

- Ventral hernia
- Groin hernia
- Pelvic hernia

- Flank hernia

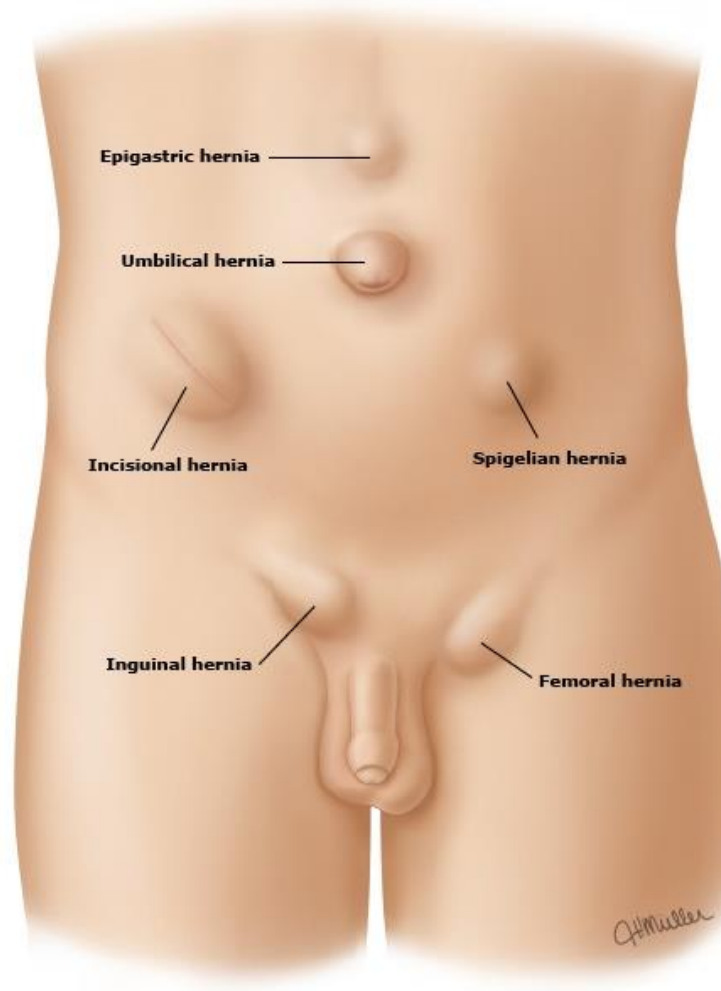


Figure 1: Abdominal wall hernias

Abdominal hernias classified based on the etiology

- Congenital hernia
- Acquired hernia

The most prevalent congenital abdominal wall anomalies are gastroschisis and omphalocele, which are disorders that are present from birth. The abnormality that develops when the abdominal wall's fibro-muscular tissue becomes weak or is disrupted. Primary hernias are those that form independently of previous surgical wounds, whereas incisional hernias are those that form following a surgical incision. Both have different pathophysiologies.

Umbilical hernias:

A main ventral hernia located in the middle of the umbilical ring (also known as periumbilical hernia) is known as umbilical hernia. "Adults most commonly develop umbilical hernias as a result of increased intra-abdominal pressure caused by obesity, ascites, abdominal distension, or pregnancy. Anatomically, some umbilical ring configurations may also lead to hernia development."^{20,21}

Hernias of the umbilical area are rather frequent. They were discovered in 23 to 50% of those who were examined by physical exam or ultrasonography.²² With a 3:1 ratio, they are more prevalent in girls than in males. On the other side, if a bowel knuckle becomes entrapped, bowel blockage or ischemia can occur.

Etiology

- 90% of the umbilical hernias are acquired and are seen in adults
- 10% are persistent from childhood
- More common among the women or with increased intra-abdominal pressure such as in case of pregnancy, ascites obesity, or the chronic abdominal distentions.
- Weak aponeurosis

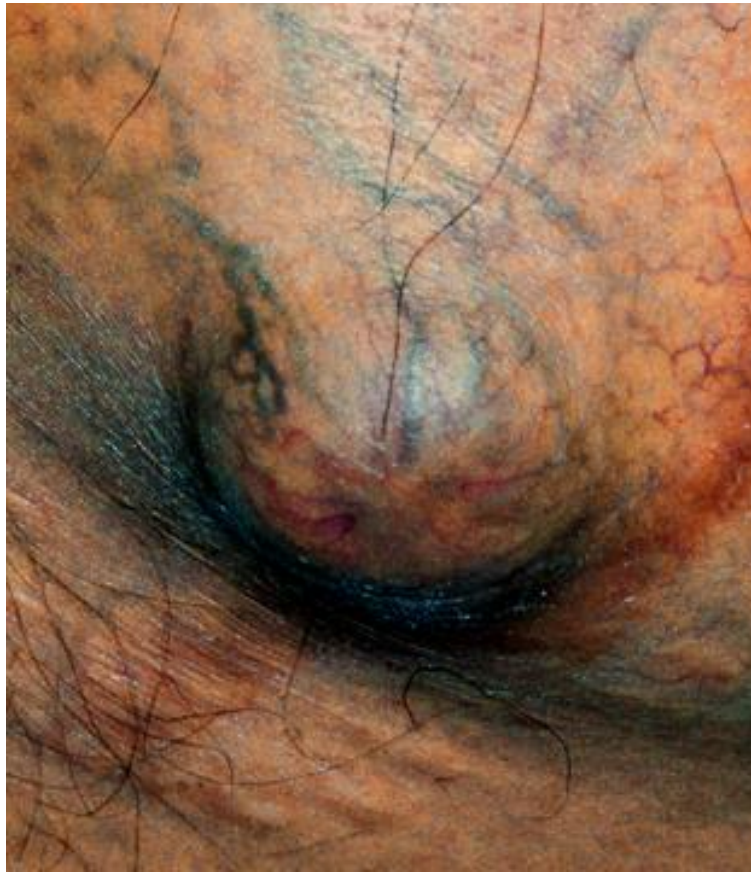

Figure 2: Umbilical hernia

While palpation and pressure can cause tenderness, it usually doesn't occur on its own. Larger umbilical hernias may be linked to skin erythema, ulceration, or ischemia.

Small and asymptomatic umbilical hernias that are not noticeable to the patient can be monitored without the need for correction. Of the 789 patients with umbilical/epigastric hernias in a five-year study, 16 percent needed elective treatment and just 4 percent needed emergency surgery.²³

Umbilical hernias can be minor (less than 1 cm), medium (between 1 and 4 cm), or big (greater than 4 cm). Surgical procedures, either open or laparoscopic, are used to treat

symptomatic umbilical hernias, depending on the patient's features and the extent of the hernia.²¹

Embryology

The umbilical cord around the eight weeks in short and thick enclosing the following structure;

- “The ductus omphalo entericus
- Vitelline vessels
- Umbilical coelom”

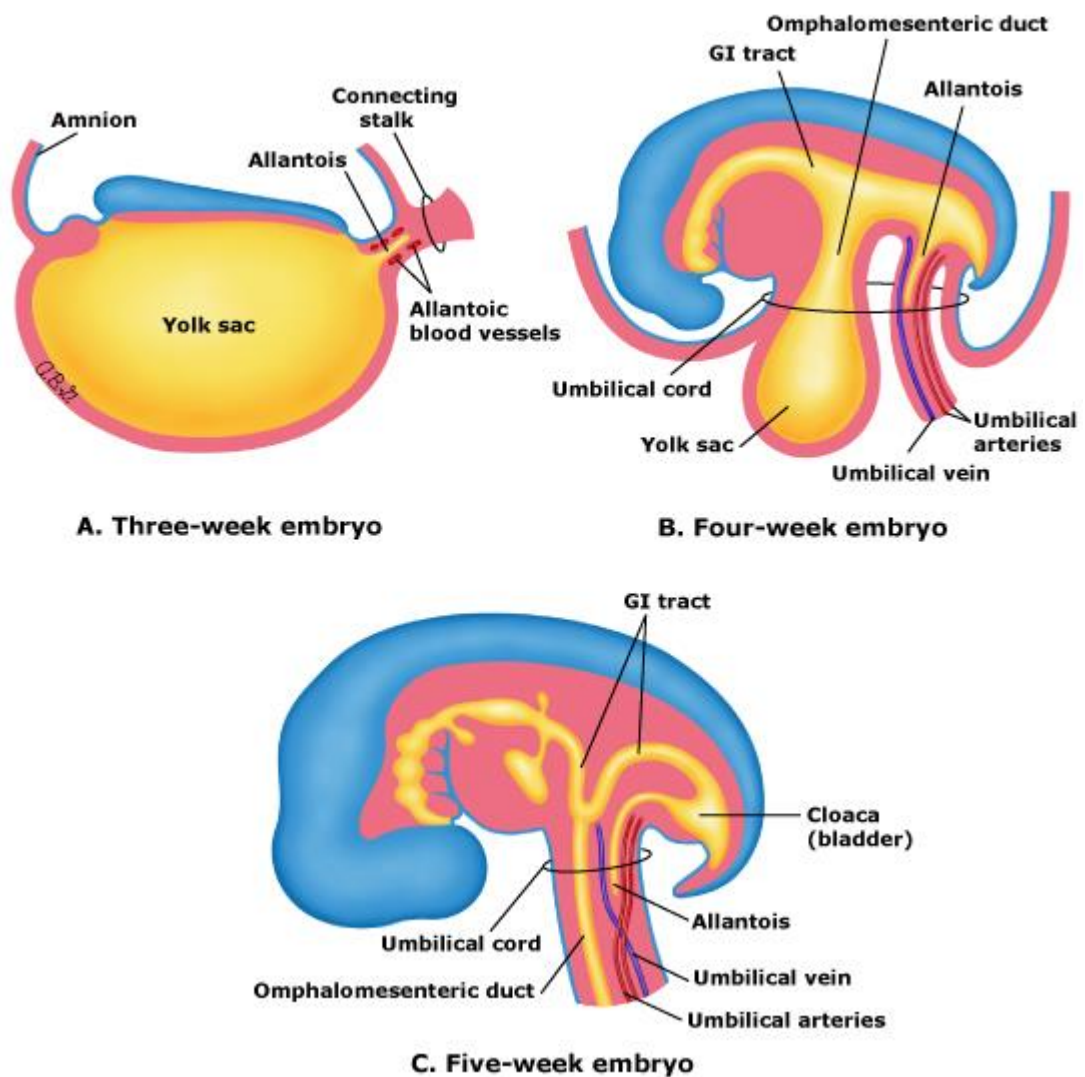


Figure 3: Umbilical cord development third to fifth week gestations

The flat trilaminar embryonic disc folds and becomes a cylindrical C-shaped embryo in the fourth week of development, narrowing the yolk sac entrance to the embryo (figure 2). The umbilical arteries, urachus, and omphalomesenteric duct all pass via this constricted aperture. The yolk sac is connected to the growing intestine via the omphalomesenteric duct. The allantois, a caudal hindgut diverticulum, develops and becomes the urachus at the same time. The urachus links the umbilicus to the growing genitourinary tract (bladder).

Natural occlusion of the umbilical cord happens even in the absence of external interventions during birth as a result of artery vasoconstriction and Wharton's jelly collapse. The blood flow is stopped by a natural clamp that forms. This clamping takes less than three minutes for an air delivery, but more than five minutes during a water birth. The ductus venosus closes and transforms into the baby's ligamentum venosum, whereas the umbilical vein closes and transforms into the round ligament of the liver.²⁴

Within seven to ten days of the delivery of a healthy term neonate, the remaining end of the umbilical cord shrivels and dries off, leaving behind a healed and healthy umbilicus. Any infection or sepsis that occurs during this stage can cause umbilical sepsis, which can subsequently cause an umbilical hernia.

Layers of umbilicus

“Layers of anterior abdominal wall namely

- Subcutaneous layer of fat
- Superficial fatty layer of fascia camper
- Deep membranous layer of scarpa”

Pathophysiology

A possible weakness existing at the exit site of involuted umbilical veins, “most notably the umbilical vein, or weaker umbilical fascia (Richet's fascia) might cause an umbilical hernia anatomically.²⁵ As a result, the epidermis, subcutaneous tissue, weaker superficial fascia, feeble umbilical fascia, and peritoneum that surround the umbilical hernia are all significantly attenuated and fused together. The umbilical fascia is typically absent in

individuals with umbilical hernia, and the round hepatic ligament is not connected to the inferior edge of the umbilical ring.”^{23,25}

Umbilical hernia can be caused by chronic abdominal wall distension with increased intra-abdominal pressure, such as in pregnancy, patients with ascites or peritoneal dialysis, stretching of abdominal muscle fibers, and connective tissue weakness. Umbilical hernia affects around 20% of cirrhotic individuals. Increased abdominal pressure from ascites, dilatation of umbilical veins, and muscle or connective tissue weakening caused by low nutritional condition all contribute to herniation.^{26,27}

Types of umbilical hernia

- Exomphalos
- Infants and children
- Paraumbilical Hernia of Adults

Exomphalos: is a developmental abnormality caused by the early stages of fetal life, the midgut's failure to fully or partially return to the abdominal cavity. As a result, the abdominal organs continue to protrude and are covered by a membrane made up of the peritoneum on the inside, Wharton's jelly in the center, and amniotic membrane on the outside.²⁸ types;

Exomphalos Minor: Where sac is relatively small and to its summit is attached to the umbilical cord.

Exomphalos Major: in which umbilical cord is attached to inferior aspect of large swelling containing small and large intestine and a portion of liver.

By undermining the subcutaneous tissue on both sides of the edema, skin flaps are produced. The flaps are used to try to bring the expanding sac over. If required, a relaxing incision in the flanks might be performed. Gastric suction is maintained after surgery to prevent distension. It's possible that a second procedure is needed to put the muscles across the peritoneal sac and close it in layers.

Children and newborns may experience an umbilical hernia due to a weak umbilical scar, which can happen after neonatal sepsis. Typically, the hernia has no symptoms and enlarges after sobbing. Male to female ratios of 2:1 are common for this to happen. Small hernias are spherical in form, but as they get bigger, they can take on a conical appearance. Strangulation with this kind of hernia is quite uncommon.²⁹

Para-umbilical hernia: “The umbilical cicatrix does not protrude through the hernia in adulthood. It is a protrusion through the linea alba slightly above or rarely below the umbilicus (supra-umbilical) (infra-umbilical). That's why it's referred to be para-umbilical.”

The larger omentum is frequently present in the hernia, along with small intestine or a piece of the transverse colon. The omentum's adhesion to its fundus causes the sac to become loculated in the majority of instances. As a result, para-umbilical hernia is seldom reversible.

Risk factors

- Low birth weight
- Trisomy 13
- Trisomy 18
- Trisomy 21
- Congenital hypothyroidism
- Mucopolysaccharides
- Marfan's syndrome
- Beckwith Widemann syndrome
- Umbilical sepsis
- Obesity
- Smoking
- Multiple pregnancies

Clinical features

- Swelling
- Pain
- Infections
- Umbilical drainage
- Asymptomatic presentation due to incidental finding on abdominal imaging study.

Management of umbilical hernia:

Because the umbilical ring's normal path is to close, most umbilical hernias will heal naturally.³⁰ Regardless of age, asymptomatic children with a shrinking umbilical ring are generally observed. Surgery before the age of four is generally discouraged because children

who have an umbilical hernia fixed before that age have a higher chance of recurrence and because surgery results in more ER visits and posthospitalizations.

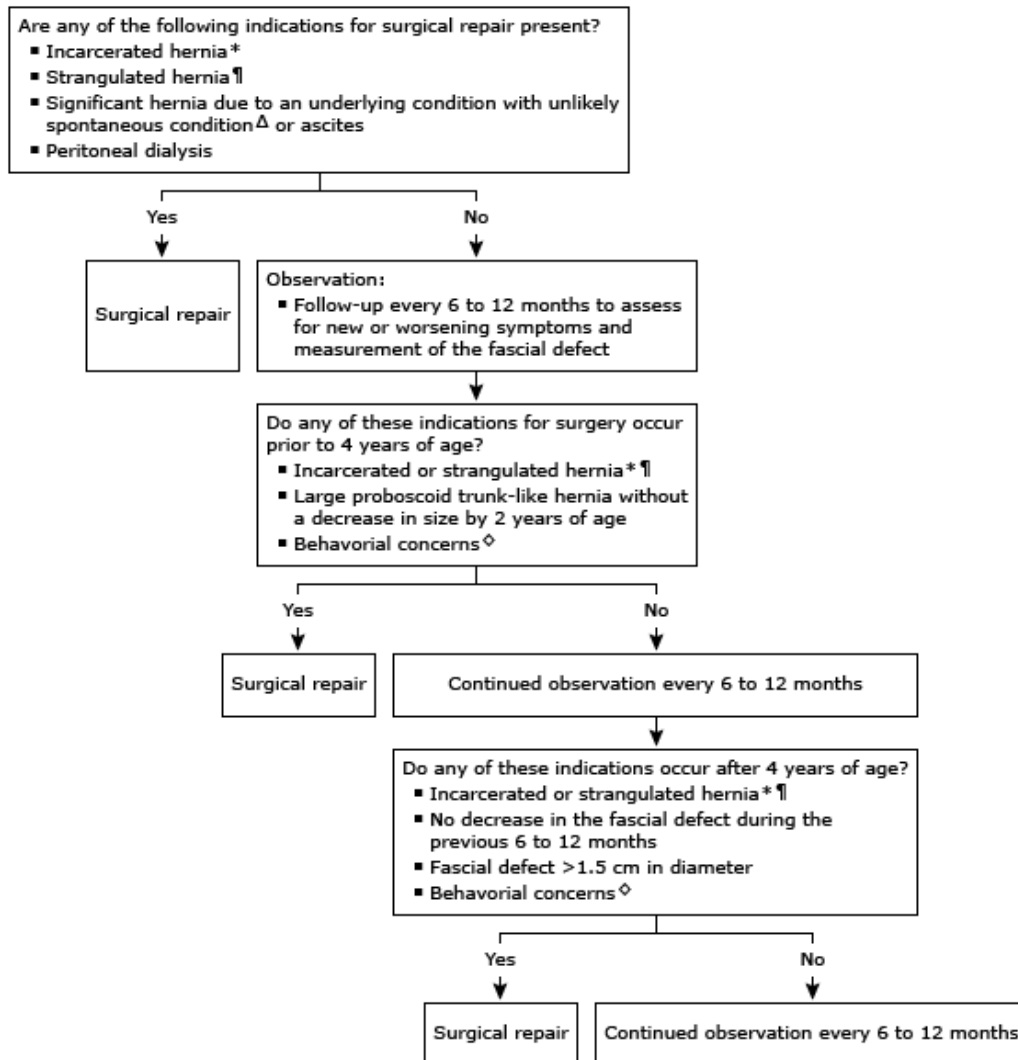


Figure 4: Overview of management of umbilical hernia in children

Various surgical techniques to repair umbilical hernia

- Mayo technique
- Umbilical repair with primary closure

- Open repair technique with MESH

Open repair: “a vertical or curvilinear incision are made over or at the adjacent of hernia sac. The hernia sac is identified and fascial attachments are dissected. Once the fascia is cleared, the sac can either be inverted or excised. Then the fascia is subsequently closed with non-absorbable sutures.” If in the presence of large defect or fascial edges cannot be approximated without the tension, MESH can be used to close.

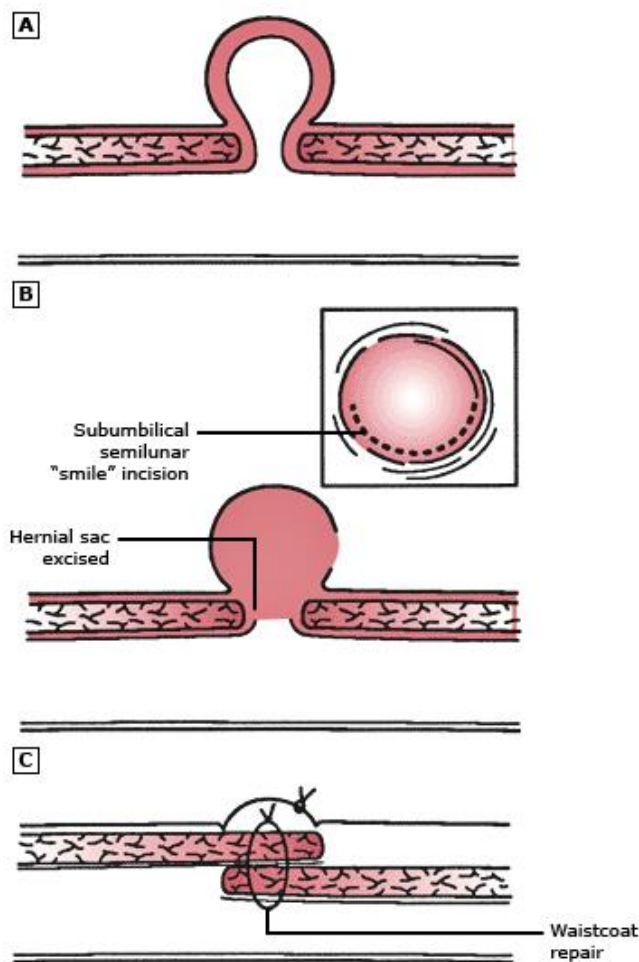


Figure 5: Umbilical hernia repair

The Mesh can be placed deeper to (sublay or underlay) or over the fascia (onlay) and must be circumferentially sutured to the fascia surrounding it, so that it prevents the migration. Various flat meshes or mesh plugs are designed for the same purpose. The recreation of umbilical skin for the cosmetic appealing can be made to tack. The mesh insertion will help in reinforcement for all the incisional hernias and those of the hernia measuring more than 1cm in diameter.^{31,32}

For thin individuals, laparoscopic treatment of tiny, easily detectable midline ventral hernias is usually not essential, and it is frequently more intrusive than an open repair. A laparoscopic treatment is advantageous for individuals who have a hernia greater than 4 cm and who may also be obese or have many abnormalities. “To assess the viability of an imprisoned intestinal loop (such as a spontaneously decreased Richter hernia), laparoscopy may also be used. Similar to other ventral hernias, umbilical hernias are repaired laparoscopically; the process is covered individually. To assess the viability of an imprisoned intestinal loop (such as a spontaneously decreased Richter hernia), laparoscopy may also be used.” Umbilical hernias are fixed laparoscopically in the same manner as other ventral hernias are; the procedure is discussed separately.^{33,34}

Extended Totally Extraperitoneal (eTEP) repair

Extended Totally Extraperitoneal (eTEP) repair is a sophisticated surgical technique employed for the repair of complex ventral and inguinal hernias. This approach, first introduced by Dr. Igor Belyansky and his colleagues in 2012, represents a significant advancement in hernia repair methodology, particularly in addressing challenging hernia cases with improved outcomes and reduced morbidity.³⁵

The eTEP repair procedure involves accessing the hernia defect through the retrorectus space, thereby minimizing intraperitoneal manipulation and potential complications associated with it. This technique provides excellent visualization and access to the hernia defect, facilitating the placement of mesh with optimal coverage and fixation, leading to decreased rates of recurrence and postoperative complications.³⁶

The surgical details of the eTEP repair procedure can be outlined as follows:

Patient Positioning: On the operating table, the patient is placed supine with both arms tucked by their sides. The legs are slightly abducted to provide optimal exposure for the surgical site.

Incision and Access to Retrorectus Space: A small transverse or midline infraumbilical incision is made to access the abdominal cavity. Subcutaneous tissue and rectus sheath are dissected to access the retrorectus space. Blunt dissection is performed to create a working space between the posterior rectus sheath and the peritoneum.

Creation of Extended Flaps: Extended flaps are created by separating the posterior rectus sheath from the rectus muscle laterally beyond the semilunar line. This step is crucial for obtaining adequate mesh coverage and minimizing the risk of recurrence.

Hernia Reduction and Mesh Placement: The hernia sac is dissected and reduced, and any adhesions or hernia contents are carefully managed. A lightweight, large-pore polypropylene mesh is then placed over the hernia defect, ensuring a minimum of 5 cm overlap beyond its borders. The mesh is secured in place using absorbable tackers or sutures.

Closure of the Retrorectus Space: Once the mesh is securely placed, the retrorectus space is closed primarily using absorbable sutures to prevent seroma formation and optimize mesh integration.

Layered Closure: The incision site is closed in layers, including subcutaneous tissue and skin, using absorbable sutures or surgical staples, ensuring proper wound approximation and minimizing the risk of wound complications.

Drain Placement (Optional): In some cases, a closed suction drain may be placed in the surgical site to minimize the risk of fluid accumulation and seroma formation.

Postoperative Care: Following surgery, patients are typically monitored closely for any signs of complications, such as seroma, hematoma, or wound infection. Early ambulation and pain management strategies are implemented to facilitate recovery and minimize discomfort.

The eTEP repair technique offers several advantages over traditional hernia repair approaches, including reduced postoperative pain, shorter hospital stays, faster recovery times, and lower rates of recurrence.³⁷ However, it requires specialized training and expertise in minimally invasive hernia surgery.

In conclusion, eTEP repair is a sophisticated surgical technique that provides a safe and effective approach for the repair of complex ventral and inguinal hernias. By utilizing the retrorectus space and minimizing intraperitoneal manipulation, this technique offers improved outcomes and reduced morbidity for patients with challenging hernia cases.

Conventional laparoscopic repair

Conventional laparoscopic repair with defect closure is a widely practiced surgical technique for the management of ventral and inguinal hernias. This approach involves the use of laparoscopic instruments and techniques to repair the hernia defect while also addressing any associated fascial defects or weaknesses. The procedure aims to provide durable hernia repair with minimal postoperative pain and faster recovery times.³⁸

The surgical details of conventional laparoscopic repair with defect closure can be outlined as follows:

Patient Preparation and Positioning: “The patient is placed under general anesthesia and positioned supine on the operating table with both arms tucked by their side.” The legs may be slightly abducted to provide optimal exposure for the surgical site.

Trocar Placement: Several trocars are inserted into the abdominal cavity to allow access for laparoscopic instruments and a camera. Typically, a 10 mm trocar is placed infraumbilically for the camera, and additional 5 mm trocars are placed in the bilateral lower quadrants and midline supraumbilically for instrument access.

Creation of Pneumoperitoneum: Carbon dioxide gas is insufflated into the abdominal cavity to create a pneumoperitoneum, providing space for laparoscopic visualization and instrument manipulation.

Identification of Hernia Defect: The hernia defect is identified using the laparoscopic camera, which provides a magnified view of the abdominal cavity. The size and location of the hernia defect are carefully assessed.

Reduction of Hernia Contents: Any hernia contents, such as omentum or bowel, are gently reduced back into the abdominal cavity using laparoscopic graspers or suction devices.

Defect Closure: If present, fascial defects or weaknesses surrounding the hernia defect are closed using non-absorbable sutures or mesh, depending on the surgeon's preference.

Closure of these defects helps reinforce the abdominal wall and reduces the risk of hernia recurrence.

Mesh Placement: A flat or pre-shaped mesh is introduced into the abdominal cavity and positioned over the hernia defect with adequate overlap. The mesh may be secured in place using either absorbable tacks, sutures, or a combination of both.

Fixation of Mesh: The mesh is carefully fixed to the abdominal wall to ensure optimal positioning and prevent migration. Fixation techniques may include tacking, suturing, or stapling, depending on the type of mesh used and surgeon preference.

Confirmation of Proper Placement: The laparoscopic camera is used to confirm the proper positioning of the mesh and absence of any folds or wrinkles that could compromise its integrity.

Closure of Port Sites: Once the hernia repair is completed, the trocars are removed under direct visualization, and the port sites are closed using absorbable sutures or surgical glue.

Postoperative Care: Following surgery, patients are typically monitored closely in the recovery area for any signs of complications such as bleeding, infection, or respiratory issues. Pain management strategies are implemented to ensure patient comfort, and early ambulation is encouraged to facilitate recovery.

Conventional laparoscopic repair with defect closure has been shown to be an effective and safe approach for the management of ventral and inguinal hernias, with low rates of recurrence and complications. However, it requires expertise in laparoscopic surgery and may not be suitable for all patients, particularly those with complex hernias or significant comorbidities.

In conclusion, conventional laparoscopic repair with defect closure is a well-established surgical technique for the management of ventral and inguinal hernias. By utilizing laparoscopic principles and techniques, this approach offers patients a minimally invasive option for hernia repair with excellent outcomes and faster recovery times.

Various articles discussing extended totally extraperitoneal repair (eTEP) vs conventional laparoscopic repair with defect closure (IPOM+) for umbilical hernias

In a study by Leque B et al., (2017) thirty-nine patients in IPOM+group and 40 in eTEP group were included. “When comparing the kinds of hernias, mean defect area, mean mesh area, and intraoperative/postoperative complications (apart from seroma rate, which favored the eTEP group), no statistically significant differences were found. The eTEP group had significantly longer operating times, while the IPOM+group had longer hospital stays. On the first, seventh, and thirty days postoperatively, the eTEP group had significantly less pain than the IPOM+group. On the 30th and 180th day following surgery, there was a significant decrease in the eTEP group's activity restriction. Significant differences were seen in the eTEP group's cosmetic outcomes 30 and 180 days following surgery. In the eTEP group,

the average follow-up was 15 months; in the IPOM+group, it was 28 months.” There was one recurrence in the IPOM+group and none in the eTEP group, with no discernible differences.³⁹

In a comparative study conducted by Jain M et al., (2022) to assess the eTEP versus IPOM repair for management of primary and incisional hernia repair. “Sixty patients were equally divided into randomized groups. Significantly reduced early post-operative pain levels and seroma rates, as well as an earlier return to activity, were seen in the eTEP group (p value < 0.05). In addition, the eTEP group demonstrated both positive and negative expenses, which increased its cost-effectiveness by a factor of 2.4. In summary, eTEP repair is preferable because it reduces early post-operative discomfort, allows for an earlier return to activities, and is more affordable, especially for minor and medium-sized abnormalities.”⁴⁰

In a study conducted by Bui NH et al., (2022), 72 patients were included, with 43 undergoing IPOM repair and 29 undergoing eTEP-RM repair. “The demographics of the patients showed a median age of 57 years and a body mass index of 30.5 kg/m², with no variations seen in gender, age, smoking status, or comorbidities. The IPOM group had a greater incidence of incisional hernias, but there was no difference in the size abnormalities of horizontal and vertical hernias. The length of hospital stay following IPOM was much greater than the duration of the operation, which was significantly shorter for IPOM. Furthermore, following IPOM, a substantially larger percentage of patients needed postoperative transversus abdominis plane (TAP) block or epidural analgesia (33% vs.0%, $p = 0.002$).” Similar findings were obtained from subgroup analysis of individuals receiving primary ventral hernia.⁴¹

In a study conducted by Elrifai A et al., (2022) to assess the laparoscopic IPOM versus open hernioplasty in ventral hernia management. In our investigation, the mean age across both groups was 41 ± 10.6 years, with males comprising the majority (70%) of cases. The average BMI was 29 kg/m², and the mean defect length for both groups was 2.5 cm. We observed a statistically significant earlier return to work and daily activities in the laparoscopic IPOM-repair group, along with lower postoperative pain scores. Although complication rates were lower in the laparoscopic IPOM group, the difference did not reach statistical significance. The mean operative time was 67.5 min for the laparoscopic IPOM group compared to 71.62 min for the open-hernioplasty group. No mortalities were recorded in either group. In conclusion, laparoscopic IPOM repair proves to be a safe, effective, and feasible approach for all ventral hernias. It offers advantages such as shorter operating time, reduced hospital stay, lower postoperative pain scores, and overall fewer complications compared to open hernioplasty. ⁴²

In a study conducted by Arish H et al., (2023) to assess the outcome in patients undergoing IPOM and eTEP repair. Sixty-six patients with ventral and incisional hernias were included in this study; forty had IPOM plus repair, and thirty-six underwent eTEP repair. There were similarities between the two groups in terms of defect diameters, kinds of hernias, and risk variables. There was a notable difference in the length of surgery; the eTEP group had operations that lasted 121.6 minutes, while the IPOM plus group had far shorter procedures (85.6 minutes). The IPOM plus group experienced significantly greater postoperative pain levels (7.5 and 5.6, respectively) than the eTEP group (3.8 and 1.6, respectively), as shown by VAS ratings on postoperative days 1 and 3. But on day 30, neither group's pain scores (IPOM plus-1.2 vs. eTEP 1.1) showed statistical significance. Compared to the eTEP group

(3.1 days), the IPOM plus cohort's average hospital stay was substantially longer (5.3 days). To sum up, the eTEP approach shows noticeably less discomfort following surgery and results in a shorter hospital stay. However, it's crucial to remember that eTEP requires a greater amount of time to do than IPOM Plus.⁴³

In a study conducted by Tasdelen HA et al., (2023) to assess the outcome of eTEP versus IPOM plus for midline incisional hernia repair. Both groups exhibited no statistically significant differences in age, sex, BMI, ASA score, or active smoking. The mean defect area (MDA) did not differ significantly between groups, but the eTEP-RS group showed higher mean mesh area (MMA) and mesh/defect (M/D) ratio. In terms of outcomes, the eTEP-RS group had significantly shorter hospital length of stay (LOS) and lower pain levels on the first and 10th postoperative days, despite a significantly longer operative time. There were no significant differences in intraoperative complications, seroma formation, or recurrence between the two techniques. In conclusion, the eTEP-RS technique offers advantages such as shorter hospital stay and less early postoperative pain compared to IPOM-plus, but it is associated with a longer operative time.⁴⁴

In a comparative study conducted by Yasin F et al., (2024) to compare the IPOM hernioplasty with IPOM-plus. In this study, “3 patients (7.14%) who had laparoscopic IPOM with fascial defect closure experienced seroma development, while 10 patients (23.81%) did not have defect closure (P-value = 0.035). Two patients (4.76%) who had the fascial defect closed and nine (21.43%) who had not (P-value = 0.024) experienced recurrence.” The study finds that compared to laparoscopic IPOM without fascial defect closure, laparoscopic IPOM with fascial defect closure in midline ventral hernia repair results in a decreased probability of recurrence.⁴⁵

In a study conducted by Sholapur S et al., (2024) to assess the IPOM plus repair versus eTEP in repair of primary hernia. “The average duration of surgery in the eTEP-RS group (192.3 ± 16.20 min) was notably longer compared to the IPOM Plus group (102.6 ± 16.78 min, $p=0.001$). Patients in the IPOM Plus group experienced a lengthier hospital stay on average (5.9 ± 2.19 days) compared to those in the eTEP-RS group (4.6 ± 3.17 days, $p=0.02$). Postoperative pain scores, assessed via the Visual Analogue Scale (VAS), were higher in the IPOM Plus group on days 1, 7, and 90, with mean scores of 3.2 ± 1.11 , 2.64 ± 1.11 , and 1.68 ± 1.46 respectively, in contrast to the eTEP-RS group with scores of 1.84 ± 0.688 , 0.76 ± 0.66 , and 0.08 ± 0.40 , respectively ($p=0.001$). In conclusion, although IPOM Plus is technically simpler and requires less time during surgery, it presents various drawbacks including increased postoperative pain, prolonged hospitalization, heightened risk of wound site seromas, and elevated incidence of postoperative paralytic ileus. Conversely, eTEP-RS, despite being a more demanding procedure with longer intraoperative duration, offers advantages such as reduced postoperative pain, shorter hospital stays, quicker recovery, and lower incidence of seromas and paralytic ileus.” However, further comprehensive data is necessary to thoroughly compare and verify the variances in short- and long-term outcomes between both techniques.⁴⁶

In a study conducted by Sehsah TM et al., (2024) to assess the eTEP versus IPOM in ventral hernia repair. Both the eTEP and IPOM techniques were applied in de-novo ventral hernia repair with comparable demographic data between groups. However, eTEP surgeries showed significantly longer operation times but resulted in decreased costs and hospital stays compared to IPOM procedures. Additionally, patients undergoing eTEP experienced significantly lower postoperative pain levels and quicker return to normal activities.

Cosmesis outcomes were similar between the two groups, while postoperative complications such as seroma, recurrence, and ileus did not significantly differ. Overall, both techniques were deemed safe and effective, but eTEP exhibited superiority in terms of reduced hospital stay, cost, postoperative pain, and quicker recovery.⁴⁷

AIMS & OBJECTIVES

Primary objective:

Compare post operative pain intensity in patients undergoing laparoscopic IPOM+ vs laparoscopic eTEP for umbilical hernia.

Secondary objective:

Compare the following in patients undergoing laparoscopic IPOM+ repair vs laparoscopic eTEP for umbilical hernia.

- 1.The duration of surgery,
- 2.Duration of hospital stay,
- 3.Postoperative complications

MATERIAL & METHOD

Source of Data: Study will be conducted among patients undergoing laproscopic umbilical hernia repair in department of general surgery of KLES Dr. Prabhakar kore hospital and MRC, Belgavi.

Study Design: Randomised observational study.

Study Period: One year from January 2023 to December 2023.

Sample Size: In a book entitled "**Umbilical Hernia**" by **Coste et al.[*]** the incidence of Umbilical hernia in the general adult population is 2% while it is much more common in obese multiparous women and cirrhotic patients.

So, considering an incidence rate of 2% (umbilical hernia in adult patients), we used the following incidence formula for calculating the sample size.

The sample size n and margin of error E are given by:

$$x = Z(c/100)^2 r(100-r)$$

$$n = N x / ((N-1)E^2 + x)$$

$$E = \text{Sqrt}[(N - n)x/n(N-1)]$$

where N is the population size ($N=20000$), r is the fraction of responses that you are interested in ($r=2\%$), and $Z(c/100)$ is the critical value for the confidence level c ($Z=1.96$).

Putting the values in the above formula, the sample size obtained is 31 patients with umbilical hernia, at a confidence interval of 95% and 80% power of the study.

Considering an attrition rate of 10%, we intend to include 34 patients with umbilical hernia in our study. These patients were divided into two groups of 17 each, where Group 1 patients

underwent minimally invasive surgical technique (eTEP) and Group 2 patients underwent conventional laparoscopic intraperitoneal mesh placement with defect closure (IPOM+).

As per the sample size calculation, 17 patients per group are sufficient, but for statistical significance at least 30 patients per group are required.

Hence, we intend to include more than 30 patients in each group.

Sampling technique: Convenient sampling technique will be used.

Sampling technique: Convenient sampling technique.

Inclusion Criteria:

1. Patients aged between 18 and 80 years old.
2. Patients giving informed written consent.
3. All patients undergoing Laproscopic umbilical hernia repair.

Exclusion Criteria:

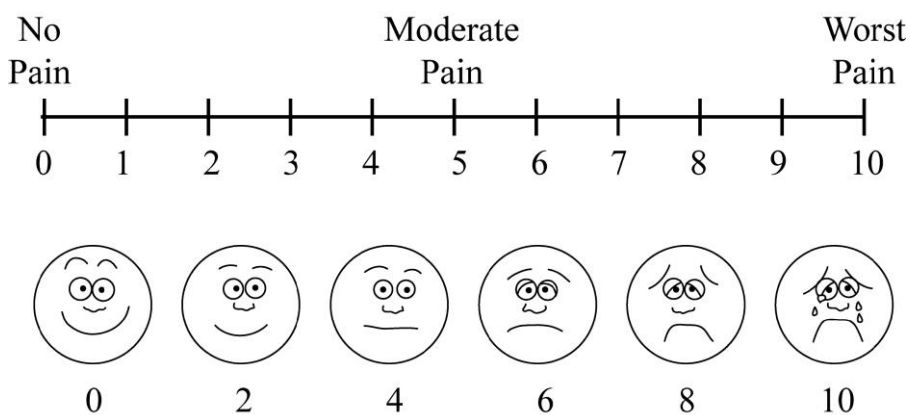
1. “Previous mesh placed in retromuscular or intra-abdominal position.
2. Patients with contraindication for general anaesthesia.
3. Incarcerated or strangulated hernias
4. Patients with uncontrolled BP, sugars and diabetes mellitus”

Study protocol: Study was conducted among “patients undergoing laproscopic umbilical hernia repair in department of general surgery of K.L.E.S. Dr. Prabhakar Kore Hospital and Medical Research Centre, Belgavi. Patients are divided into two groups, first group undergoing IPOM repair for umbilical hernia repair and second group undergoing eTEP for

umbilical hernia repair. These two groups are compared regarding postoperative pain, functional recovery, recurrence rates, intra- and postoperative complications, and aesthetic results.” The data obtained from the above study determined the better method of mesh fixation.

Visual analog scale (VAS) was used to quantify pain if any.

Data collection procedure: comparing post operative pain for patients undergoing eTEP vs IPOM using visual analogue scale to quantify pain if any.



Does the study require any investigations or interventions to be conducted on patients or other humans or animals? If so, please describe briefly.

Yes. Investigations to be done include: CBC, MR, LFT, RBS, HIV, HBSAG, PT/INR, Chest X-Ray, ECG, USG (abdomen + pelvis)

Surgery:

Laparoscopic umbilical hernia repair- eTEP + IPOM

STATISTICAL ANALYSIS

The data were initially captured into the customized proforma which developed for the specific requirement of the study. Then this data was transferred to Microsoft Excel for analysis. Statistical Software IBM SPSS Version 20.0.0.0 was used for calculating the P value. Descriptive statistics were presented in the form of numbers and percentages. Comparison of proportions was done using Z test / Fisher's Exact test, comparison of means between the two groups were done using Unpaired 't' test and Association between two non-parametric variables was done using Pearson Chi-square test. A p value of < 0.05 was taken as statistically significant.

RESULTS

Present study included total of 60 patients fulfilling inclusion criteria. Patients were divided into two groups as;

Group A: patients undergoing conventional laparoscopic intraperitoneal mesh placement with defect closure (IPOM+).

Group B: patients undergoing minimally invasive surgical technique (eTEP)

Table 1: Comparison of the mean age between the groups

	Group A		Group B		p-value
	Mean	SD	Mean	SD	
Age	48.3	14.0	48.0	13.7	0.926

The mean age of patients between the groups were comparable with overall mean age of 48.15yrs.

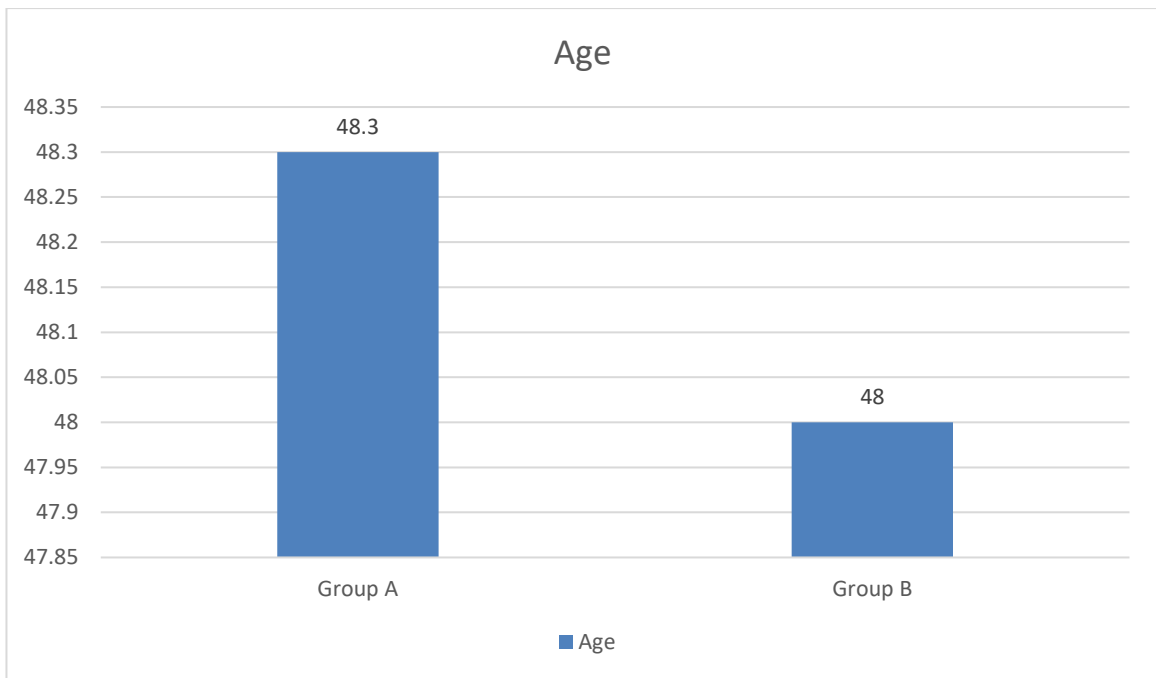


Figure 6: Comparison of the mean age between the groups

Table 2: Comparison of the gender distribution between the groups

		Group A		Group B	
		Count	N %	Count	N %
Gender	Female	10	33.3%	11	36.7%
	Male	20	66.7%	19	63.3%

Among the gender distribution, there is no significant difference noted between the groups, however overall there is male preponderance in the study.

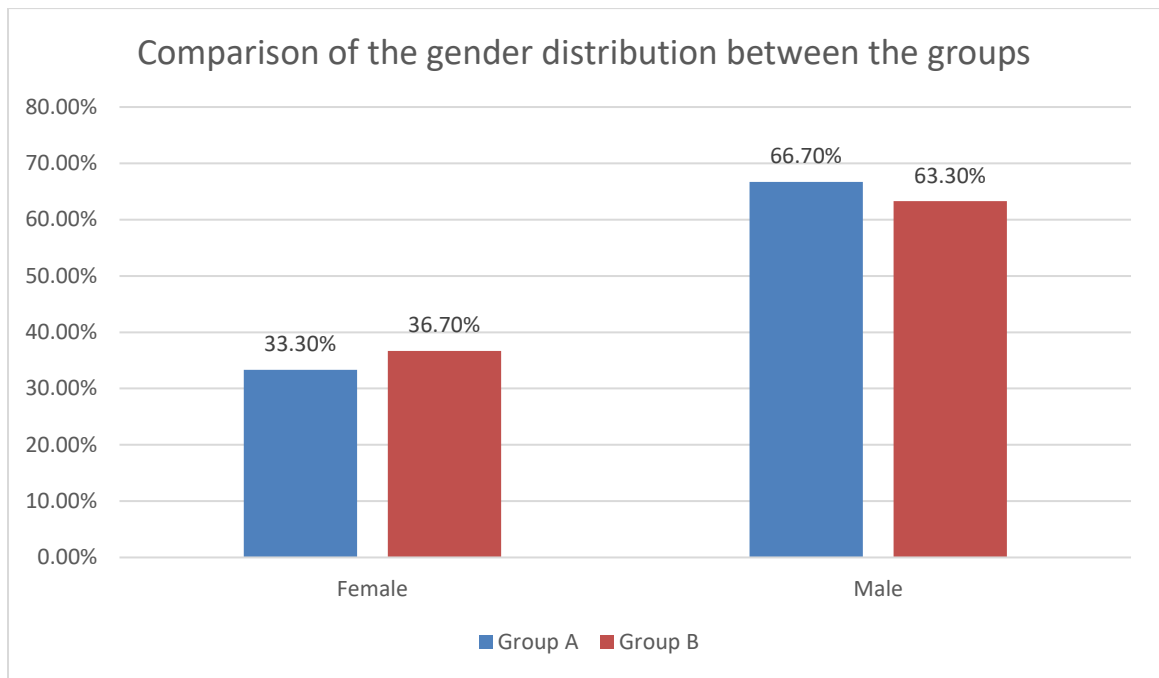


Figure 7: Comparison of the gender distribution between the groups

Table 3: Comparison of the diagnosis of patients between the groups

		Group A		Group B	
		Count	N %	Count	N %
Diagnosis	Paraumbilical hernia	8	26.7%	8	26.7%
	Umbilical hernia	22	73.3%	22	73.3%

On assessment of the diagnosis majority of the patients presented with umbilical hernia in both the groups.

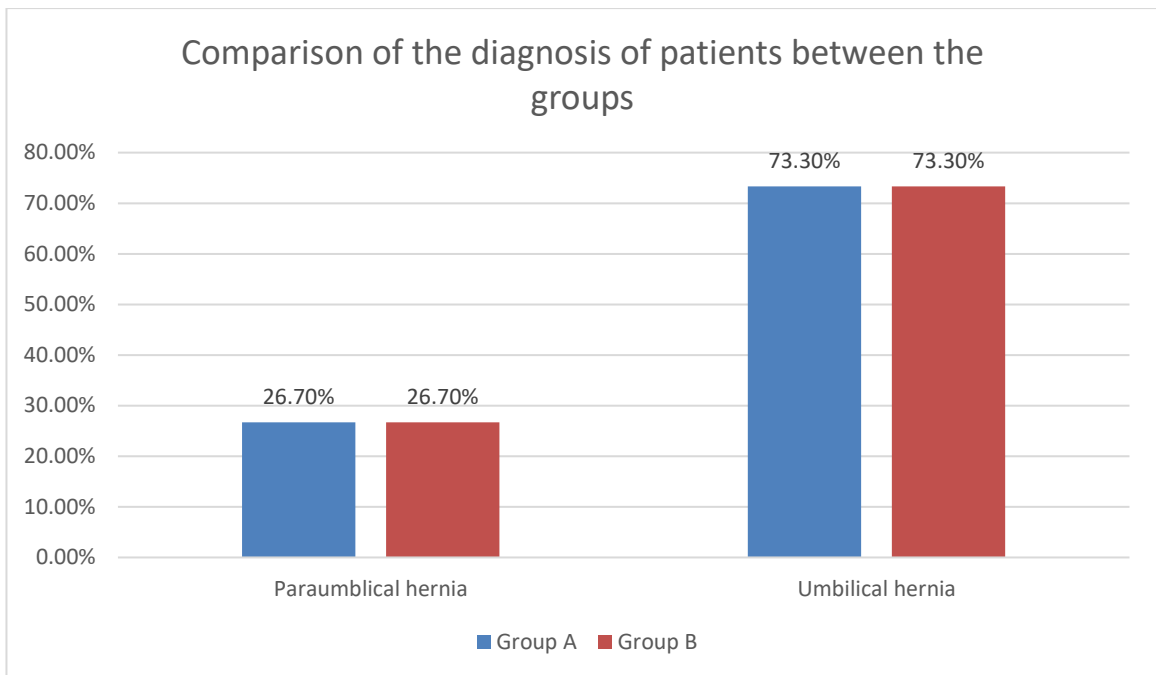


Figure 8: Comparison of the diagnosis of patients between the groups

Table 4: Comparison of the operative time between the groups

	Group A		Group B		p-value
	Mean	SD	Mean	SD	
Operation time mins	82.9	26.1	123.0	18.9	0.01*

The operative time between two groups were significantly different. The mean duration of operation was significantly shorter in group A compared to the patient sin group B.(p<0.05)

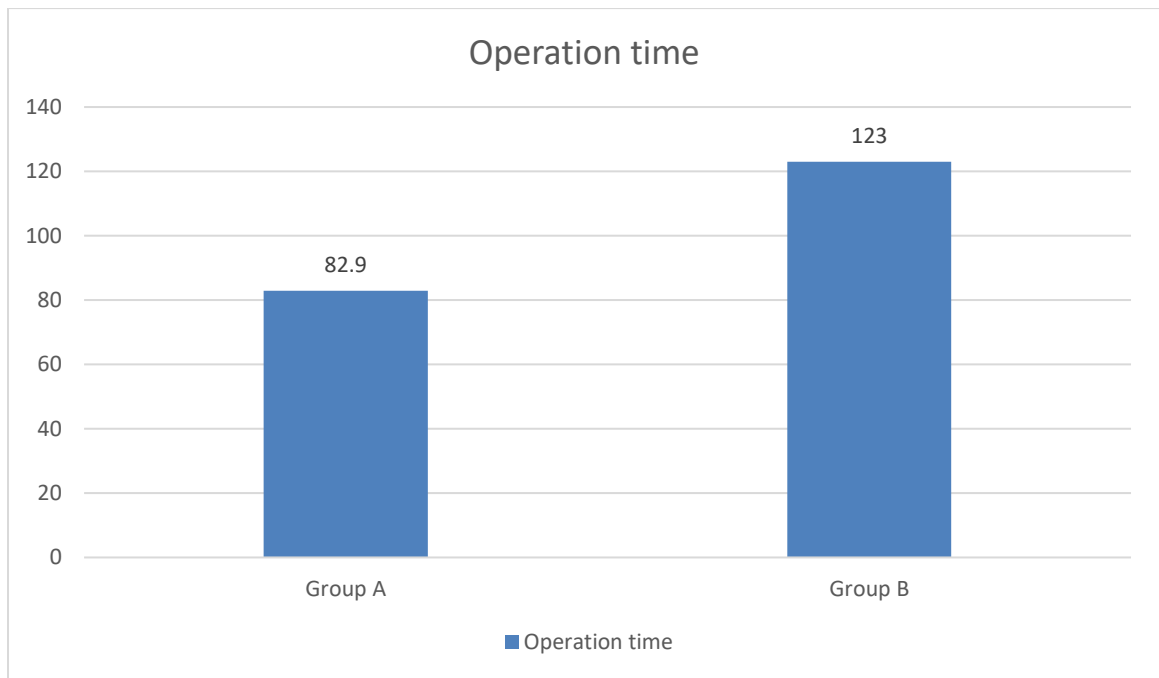


Figure 9: Comparison of the operative time between the groups

Table 5: Comparison of the pain score between the groups

Pain	Group A		Group B		p-value
	Mean	SD	Mean	SD	
POD 1	8.7	1.4	7.9	1.1	0.019*

POD 7	5.4	1.8	4.5	1.5	0.02*
POD 14	2.9	1.6	2.9	1.4	0.93
POD 1 month	1.7	1.1	1.1	1.2	0.04*
POD 3 month	.8	.7	0.5	.9	0.05*

On assessment of the pain score between the groups, there is significant lower mean pain score among the patients in group B compared to the patients in group A. ($p < 0.05$) The pain score in group B was significantly lower on post operative day 1, day 7, 1st month and 3rd month. ($p < 0.05$)

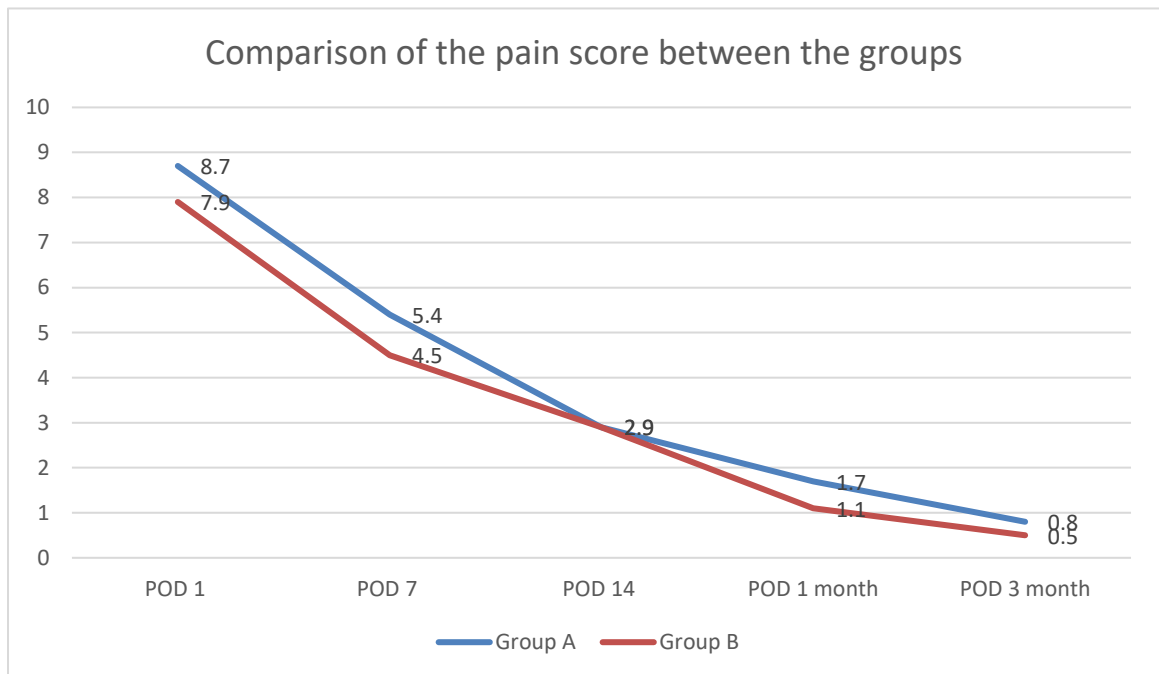


Figure 10: Comparison of the pain score between the groups

Table 6: Comparison of presence of seroma between the groups

		Group A		Group B		Chi-square (p-value)
		Count	N %	Count	N %	
Seroma	No	25	83.3%	28	93.3%	1.45 (0.228)
	Yes	5	16.7%	2	6.7%	

On assessment of the seroma formation, there is no significant difference noted between the groups.

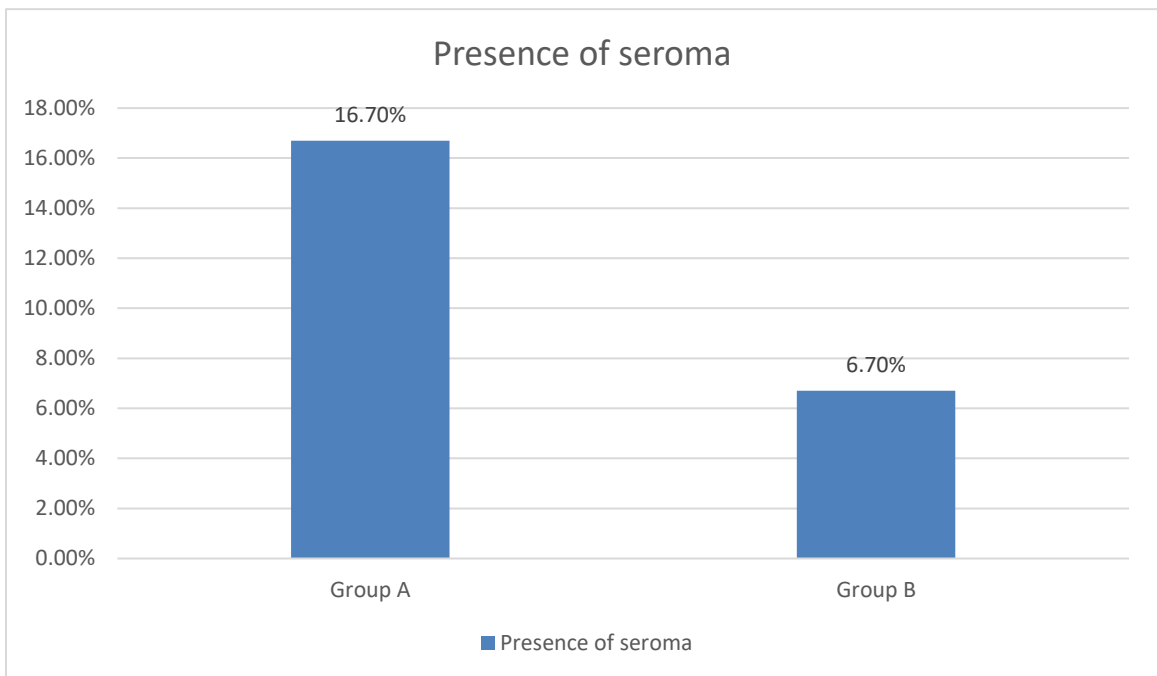


Figure 11: Comparison of presence of seroma between the groups

Table 7: Comparison of the hospital stay between the groups

	Group A		Group B		p-value
	Mean	SD	Mean	SD	
Hospital stay	6.8	1.9	5.8	1.3	0.01*

The mean duration of hospital stay was significantly shorter in group B patients (5.8days) compared to patients in group A (6.8days).(p<0.05)

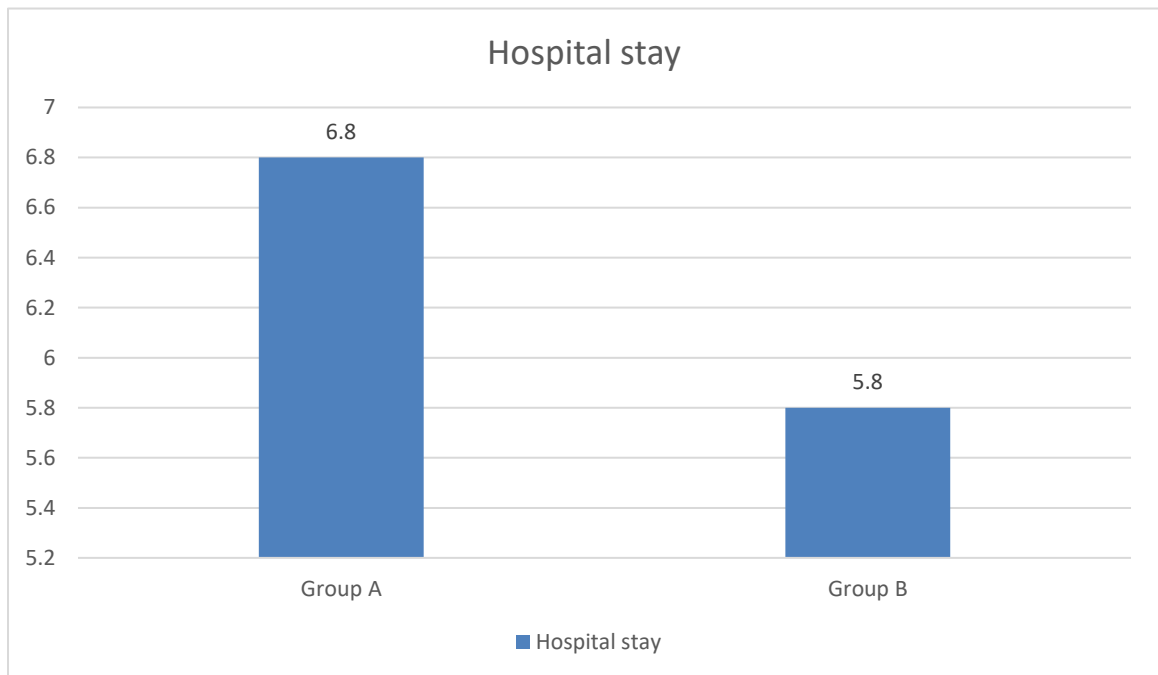


Figure 12: Comparison of the hospital stay between the groups

Table 8: Comparison of the presence of wound infection between the groups

		Group A		Group B		Chi-square (p-value)
		Count	N %	Count	N %	
Wound infection	No	28	93.3%	28	93.3%	-
	Yes	2	6.7%	2	6.7%	

The wound infection rate was found to be comparable between the groups with no significant difference noted between the groups.

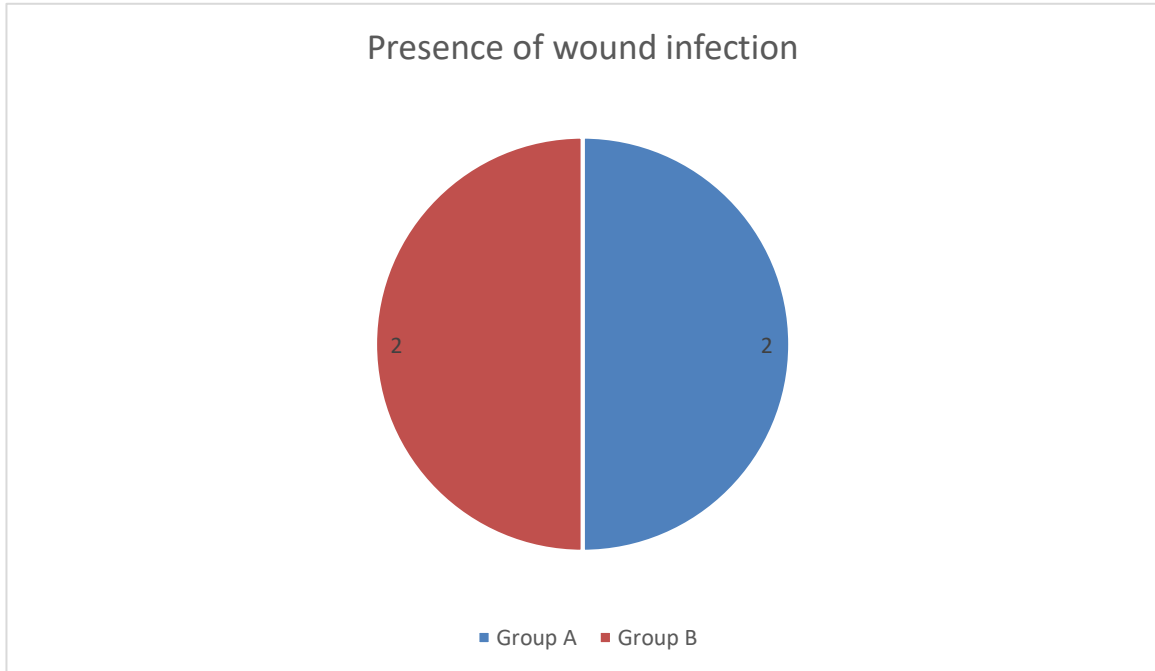


Figure 13: Comparison of the presence of wound infection between the groups

DISCUSSION

Umbilical hernias, characterized by the protrusion of intra-abdominal contents through a defect at the umbilical ring, present a common clinical challenge in abdominal surgery. The management of these hernias has evolved significantly over recent decades, moving from traditional open techniques to more advanced minimally invasive methods. Among these, two prominent approaches have garnered considerable attention: Extended Totally Extraperitoneal Repair (eTEP) and Conventional Laparoscopic Repair with Defect Closure (IPOM+).⁴⁸

Extended Totally Extraperitoneal Repair (eTEP) represents a nuanced and advanced approach to hernia repair, specifically designed to optimize outcomes by minimizing intra-abdominal complications. This technique, introduced to refine the principles of minimally invasive surgery, involves creating a space between the posterior rectus sheath and the rectus abdominis muscle, allowing for the placement of mesh without breaching the peritoneal cavity. The eTEP method capitalizes on an extraperitoneal route, reducing the risk of intra-abdominal adhesions and potential complications associated with intraperitoneal mesh placement. This approach not only aims to restore the integrity of the abdominal wall but also enhances patient recovery through decreased postoperative pain and reduced hospital stays.⁴⁹⁻⁵¹

Conventional Laparoscopic Repair with Defect Closure (IPOM+), on the other hand, has been a cornerstone in the minimally invasive treatment of hernias. This method involves the closure of the hernia defect and the placement of a mesh within the peritoneal cavity. The IPOM+ technique, with its emphasis on intraperitoneal mesh placement and defect closure,

has been well-regarded for its effectiveness in addressing hernia recurrence and achieving durable repairs. However, it also involves a degree of intraperitoneal manipulation, which can pose risks such as bowel adhesions and mesh-related complications.⁵²⁻⁵⁴

In comparing these two techniques, the discussion centers on their respective advantages, limitations, and overall efficacy in managing umbilical hernias. Factors such as surgical outcomes, complication rates, recurrence, and patient recovery trajectories are critical in evaluating the relative merits of eTEP versus IPOM+.

Present study included total of 60 patients fulfilling inclusion criteria. Patients were divided into two groups as; Group A: patients undergoing conventional laparoscopic intraperitoneal mesh placement with defect closure (IPOM+), Group B: patients undergoing minimally invasive surgical technique (eTEP).

The operative time between two groups were significantly different. The mean duration of operation was significantly shorter in group A (IPOM PLUS) compared to the patient sin group B (eTEP). ($p < 0.05$)

The increased operative time in the eTEP group (group B) attributed to increased time taken to dissect the recto-rectus plane for placement of the mesh as compared to the IPOM plus group.

In study by Sehsah TM et al., the eTEP surgeries showed significantly longer operation times but resulted in decreased costs and hospital stays compared to IPOM procedures.⁴⁷

In study by Arish H et al., the duration of surgery notably differed, with the IPOM plus group undergoing significantly shorter procedures (85.6 minutes) compared to the eTEP group (121.6 minutes).⁴³

On assessment of the pain score between the groups, there is significant lower mean pain score among the patients in group B (eTEP) compared to the patients in group A (IPOM PLUS) ($p < 0.05$). The pain score in group B (eTEP) was significantly lower on post operative day 1, day 7, 1st month and 3rd month. ($p < 0.05$).

Contrary to previous studies in our study pain was significantly lower in group B (eTEP) even though patients who underwent eTEP (group B) underwent extensive dissection of recto-rectus plane. The increased pain in patients who underwent IPOM plus (group A) maybe due to transfacial sutures and tackers used to fix mesh intraperitoneally.

In concordance to present study Sholapur S et al., documented significant lower VAS score among the IPOM plus group compared to patients with eTEP-RS group.⁴⁶ Sehshah TM et al., reported patients undergoing eTEP experienced significantly lower postoperative pain levels and quicker return to normal activities.⁴⁷

In a study by Arish H et al., the postoperative pain levels, as “indicated by VAS scores on postoperative days 1 and 3, were markedly higher in the IPOM plus group (7.5 and 5.6, respectively) compared to the eTEP group (3.8 and 1.6, respectively)”.⁴³

On assessment of the seroma formation, there is no significant difference noted between the groups. The wound infection rate was found to be comparable between the groups with no significant difference noted between the groups. The mean duration of hospital stay was significantly shorter in group B patients (5.8days) compared to patients in group A (6.8days).($p < 0.05$)

Sholapur S et al., stated that although IPOM Plus is technically simpler and requires less time during surgery, it presents various drawbacks including increased postoperative pain, prolonged hospitalization, heightened risk of wound site seromas, and elevated incidence of

postoperative paralytic ileus.⁴⁶ in another study by Yasin F et al., “the seroma formation occurred in 3 (7.14%) patients who underwent laparoscopic IPOM with fascial defect closure, compared to 10 (23.81%) in those without defect closure (P-value = 0.035). Concludes that laparoscopic IPOM with fascial defect closure in midline ventral hernia repair leads to a lower frequency of recurrence compared to laparoscopic IPOM without fascial defect closure.”⁴⁵

Another study by Arish H et al., “average length of hospital stay in the IPOM plus cohort (5.3 days) was significantly lengthier than in the eTEP cohort (3.1 days). In conclusion, the eTEP technique demonstrates notably lower postoperative pain and leads to a shortened hospital stay.” Nevertheless, it's important to note that the eTEP procedure does necessitate a longer operative duration compared to IPOM Plus.⁴³

In line with present study Elrifai A et al., found laparoscopic IPOM repair proves to be a safe, effective, and feasible approach for all ventral hernias. It offers advantages such as shorter operating time, reduced hospital stay, lower postoperative pain scores, and overall fewer complications compared to open hernioplasty.⁴²

SUMMARY

- Present study included total of 60 patients fulfilling inclusion criteria. Patients were divided into two groups as;
- Group A: patients undergoing conventional laparoscopic intraperitoneal mesh placement with defect closure (IPOM+).
- Group B: patients undergoing minimally invasive surgical technique (eTEP)
- The mean age of patients between the groups were comparable with overall mean age of 48.15yrs.
- Among the gender distribution, there is no significant difference noted between the groups, however overall there is male preponderance in the study.
- On assessment of the diagnosis majority of the patients presented with umbilical hernia in both the groups.
- The operative time between two groups were significantly different. The mean duration of operation was significantly shorter in group A compared to the patient in group B.($p < 0.05$)
- On assessment of the pain score between the groups, there is significant lower mean pain score among the patients in group B compared to the patients in group A.($p < 0.05$) The pain score in group B was significantly lower on post operative day 1, day 7, 1st month and 3rd month. ($p < 0.05$)
- On assessment of the seroma formation, there is no significant difference noted between the groups.
- The mean duration of hospital stay was significantly shorter in group B patients (5.8days) compared to patients in group A (6.8days).(p<0.05)

- The wound infection rate was found to be comparable between the groups with no significant difference noted between the groups.

CONCLUSION

In conclusion, this study demonstrates that eTEP offers several advantages over IPOM plus for umbilical hernia repair, including reduced postoperative pain, shorter hospital stays, and comparable rates of seroma formation and wound infection. The shorter operative time associated with IPOM plus may appeal to surgeons seeking efficiency, but the superior postoperative outcomes and patient comfort associated with eTEP suggest it may be a preferable option for selected patients. Further research with larger sample sizes and longer follow-up periods is warranted to confirm these findings and refine surgical decision-making in managing umbilical hernias.

REFERENCE

1. Poelman M, Apers J, van den Brand H, Cense H, Consten E, Deelder J, et al. The INCH-Trial: a multicentre randomized controlled trial comparing the efficacy of conventional open surgery and laparoscopic surgery for incisional hernia repair. *BMC Surg.* 2013 Jun;13:18.
2. Olmi S, Scaini A, Cesana GC, Erba L, Croce E. Laparoscopic versus open incisional hernia repair: an open randomized controlled study. *Surg Endosc.* 2007;21:555–9.
3. LeBlanc KA, Booth W V. Laparoscopic repair of incisional abdominal hernias using expanded polytetrafluoroethylene: preliminary findings. *Surg Laparosc Endosc Percutaneous Tech.* 1993;3(1):39–41.
4. Misra MC, Bansal VK, Kulkarni MP, Pawar DK. Comparison of laparoscopic and open repair of incisional and primary ventral hernia: results of a prospective randomized study. *Surg Endosc Other Interv Tech.* 2006;20:1839–45.
5. Berger D. [Laparoscopic IPOM technique]. *Chirurg.* 2010;81(3):211–5.
6. Bittner R, Bingener-Casey J, Dietz U, Fabian M, Ferzli G, Fortelny R, et al. Guidelines for laparoscopic treatment of ventral and incisional abdominal wall hernias (International Endohernia Society [IEHS])-Part III. *Surg Endosc.* 2014;28(2):380–404.
7. Giuffrida M, Rossini M, Pagliai L, Del Rio P, Cozzani F. Laparoscopic Intraperitoneal Onlay Mesh (IPOM): Short- and Long-Term Results in a Single Center. *Vol. 4, Surgeries.* 2023. p. 98–107.

8. Brooks D, Rosen M, Chen W. Overview of abdominal wall hernias in adults. UpToDate Waltham, MA Wolters Kluwer. 2017;
9. Ardeleanu V, Georgescu C, Fulga I. Major omphalocele with liver protrusion. Liver dysmorphism. A case study. Rom J Morphol Embryol = Rev Roum Morphol Embryol. 2013;54(2):423–6.
10. Luijendijk RW, Hop WCJ, Van Den Tol MP, De Lange DCD, Braaksma MMJ, IJzermans JNM, et al. A comparison of suture repair with mesh repair for incisional hernia. N Engl J Med. 2000;343(6):392–8.
11. Arroyo A, García P, Pérez F, Andreu J, Candela F, Calpena R. Randomized clinical trial comparing suture and mesh repair of umbilical hernia in adults. Br J Surg. 2001;88(10):1321–3.
12. Kulaçoğlu H. Current options in umbilical hernia repair in adult patients. Ulus cerrahi Derg. 2015;31(3):157–61.
13. Rana KV, Singh G, Deshpande NA, Bharathan VK, Sridharan S. Postoperative complications of mesh hernioplasty for incisional hernia repair and factors affecting the occurrence of complications. Med J Dr DY Patil Univ. 2013;6(1).
14. Wilson RB, Farooque Y. Risks and Prevention of Surgical Site Infection After Hernia Mesh Repair and the Predictive Utility of ACS-NSQIP. J Gastrointest Surg. 2022;26(4):950–64.
15. Madsen LJ, Oma E, Jorgensen LN, Jensen KK. Mesh versus suture in elective repair of umbilical hernia: systematic review and meta-analysis. BJS open. 2020;4(3):369–

79.

16. Mitura K, Skolimowska-Rzewuska M, Rzewuska A, Wyrzykowska D. Is mesh always necessary in every small umbilical hernia repair? Comparison of standardized primary sutured versus patch repair: retrospective cohort study. *Hernia*. 2021;25(3):571–7.
17. Park AE, Roth JS, Kavac SM. Abdominal wall hernia. *Curr Probl Surg*. 2006 May;43(5):326–75.
18. Earle DB, McLellan JA. Repair of umbilical and epigastric hernias. *Surg Clin North Am*. 2013;93(5):1057–89.
19. Muysoms FE, Miserez M, Berrevoet F, Campanelli G, Champault GG, Chelala E, et al. Classification of primary and incisional abdominal wall hernias. *Hernia*. 2009;13(4):407–14.
20. Fathi AH, Soltanian H, Saber AA. Surgical anatomy and morphologic variations of umbilical structures. *Am Surg*. 2012 May;78(5):540–4.
21. Henriksen NA, Montgomery A, Kaufmann R, Berrevoet F, East B, Fischer J, et al. Guidelines for treatment of umbilical and epigastric hernias from the European Hernia Society and Americas Hernia Society. *Br J Surg*. 2020 Feb;107(3):171–90.
22. Bedewi MA, El-Sharkawy MS, Al Boukai AA, Al-Nakshabandi N. Prevalence of adult paraumbilical hernia. Assessment by high-resolution sonography: a hospital-based study. *Hernia*. 2012;16(1):59–62.

23. Kokotovic D, Sjølander H, Gögenur I, Helgstrand F. Watchful waiting as a treatment strategy for patients with a ventral hernia appears to be safe. *Hernia*. 2016;20(2):281–7.
24. Botezatu R, Raduteanu S, Ciobanu AM, Gica N, Peltecu G, Panaitescu AM. Absence of Wharton’s Jelly at the Abdominal Site of the Umbilical Cord Insertion. Rare Case Report and Review of the Literature. Vol. 57, *Medicina* (Kaunas, Lithuania). Switzerland; 2021.
25. Moschcowitz A V. THE PATHOGENESIS OF UMBILICAL HERNIA. *Ann Surg*. 1915 May;61(5):570–81.
26. Celdrán A, Bazire P, Garcia-Ureña MA, Marijuán JL. H-hernioplasty: a tension-free repair for umbilical hernia. *Br J Surg*. 1995 Mar;82(3):371–2.
27. Belghiti J, Durand F. Abdominal wall hernias in the setting of cirrhosis. *Semin Liver Dis*. 1997;17(3):219–26.
28. Nitzsche K, Fitze G, Rüdiger M, Wimberger P, Birdir C. Prenatal diagnosis of exomphalos and prediction of outcome. *Sci Rep*. 2021 Apr;11(1):8752.
29. Lucas AGT, Jaafar S, Mendez MD. Pediatric umbilical hernia. In: *StatPearls* [Internet]. StatPearls Publishing; 2023.
30. Zens T, Nichol PF, Cartmill R, Kohler JE. Management of asymptomatic pediatric umbilical hernias: a systematic review. *J Pediatr Surg*. 2017;52(11):1723–31.
31. Pereira C, Gururaj S. Onlay Versus Sublay Mesh Repair for Incisional Hernias: A

Systematic Review. *Cureus*. 2023 Jan;15(1):e34156.

32. McKnight CL, Fowler JL, Cobb WS, Smith DE, Carbonell AM. Concomitant sublay mesh repair of umbilical hernia and abdominoplasty. *Can J Plast Surg*. 2012;20(4):258–60.
33. Pereira C, Rai R. Open Versus Laparoscopic Ventral Hernia Repair: A Randomized Clinical Trial. *Cureus*. 2021 Dec;13(12):e20490.
34. Kalyan M, Rathore SS, Verma V, Sharma S, Choudhary M, Irshad I, et al. Laparoscopic Versus Open Ventral Hernia Repair: Experience at a Tertiary Care Center in Western Rajasthan. *Cureus*. 2022 Jul;14(7):e27279.
35. Belyansky I, Daes J, Radu VG, Balasubramanian R, Reza Zahiri H, Weltz AS, et al. A novel approach using the enhanced-view totally extraperitoneal (eTEP) technique for laparoscopic retromuscular hernia repair. *Surg Endosc*. 2018;32:1525–32.
36. Morrell ALG, Morrell A, Morrell-Junior AC, MENDES J, DE FREITAS M, MORRELL AG. Standardization and ten essential steps in the lateral robotic extended totally extraperitoneal (eTEP) repair of ventral hernias. *Rev Col Bras Cir*. 2020;47:e20202622.
37. Gunasekaran G, Balaji VC, Paramsivam S. Comparative Study of Self-Gripping Mesh vs. Polypropylene Mesh in Lichtenstein's Open Inguinal Hernioplasty. *Cureus*. 2023;15(8):e43652.
38. Takahashi T, Kalka C, Masuda H, Chen D, Silver M, Kearney M, et al. Ischemia- and cytokine-induced mobilization of bone marrow-derived endothelial progenitor

cells for neovascularization. *Nat Med.* 1999;5(4):434–8.

39. Luque JAB, Luque AB, Menchero JG, Grau JMS, Moreno JG, Gomez AT, et al. Safety and effectiveness of self-adhesive mesh in laparoscopic ventral hernia repair using transabdominal preperitoneal route. *Surg Endosc.* 2017;31:1213–8.
40. Jain M, Asuri K, Prakash O, Kumar S, Sagar R, Ramachandran R, et al. Comparison of extended totally extra peritoneal (eTEP) vs intra peritoneal onlay mesh (IPOM) repair for management of primary and incisional hernia in terms of early outcomes and cost effectiveness—a randomized controlled trial. *Surg Endosc.* 2022;36(8):1–6.
41. Bui NH, Jørgensen LN, Jensen KK. Laparoscopic intraperitoneal versus enhanced-view totally extraperitoneal retromuscular mesh repair for ventral hernia: a retrospective cohort study. *Surg Endosc.* 2022;36(2):1500–6.
42. Elrifai AY, Elfouly MG, Farrag AM. Laparoscopic intraperitoneal onlay mesh versus open hernioplasty in ventral hernia treatment: A nonrandomized controlled trial. *Egypt J Surg.* 2022;41(2):495–501.
43. Arish H, Masudi FA. A study to compare outcomes in patients undergoing intraperitoneal onlay mesh plus and eTEP repair for ventral wall and incisional hernia. *Int Surg J.* 2023;10(10):1642–6.
44. Taşdelen HA. Comparison of outcomes of the extended-view totally extraperitoneal rives-stoppa (eTEP-RS) and the intraperitoneal onlay mesh with defect closure (IPOM-plus) for W1-W2 midline incisional hernia repair-a single-center experience. *Surg Endosc.* 2023;37(4):3260–71.

45. Yasin F, Abaid A, Shafiq A, Umar M, Khan WH, Ayyaz M, et al. Comparison of Laparoscopic Intraperitoneal Onlay Mesh (IPOM) Hernioplasty With Laparoscopic IPOM-Plus: Our Initial Experience in Pakistan. *Cureus*. 2024;16(2):7–11.
46. Sholapur S, Shaikh A, C G A, Tandur A, Padekar HD, Bhandarwar A, et al. Intraperitoneal Onlay Mesh (IPOM Plus) Repair Versus Extended-View Totally Extraperitoneal Rives-Stoppa (eTEP-RS) Repair in Primary Ventral Hernias: Experience With 50 Cases in a Tertiary Care Hospital. *Cureus*. 2024;16(4):e57678.
47. Sehsah TM, Elshora AA, Abd-Raboh OH. Extended Totally Extraperitoneal (eTEP) Technique vs. Laparoscopic Intraperitoneal Onlay Mesh (IPOM) in Ventral Hernia Repair: A Randomized Comparative Study. *Egypt J Surg*. 2024;43(1).
48. Coelho JCU, Claus CMP, Campos ACL, Costa MAR, Blum C. Umbilical hernia in patients with liver cirrhosis: A surgical challenge. *World J Gastrointest Surg*. 2016;8(7):476–82.
49. Baig SJ, Priya P. Extended totally extraperitoneal repair (eTEP) for ventral hernias: Short-term results from a single centre. *J Minim Access Surg*. 2019;15(3):198–203.
50. Salido Fernandez S, Fraile Vilarrasa M, Osorio Silla I, Georgiev Hristov T, Bernar de Oriol J, González-Ayora S, et al. Extended Totally Extraperitoneal (eTEP) Approach for Ventral Hernia Repair: Initial Results. *Cir Esp*. 2020;98(5):260–6.
51. Mitura K, Rzewuska A, Skolimowska-Rzewuska M, Romańczuk M, Kisielewski K, Wyrzykowska D. Laparoscopic enhanced-view totally extraperitoneal Rives-Stoppa repair (eTEP-RS) for ventral and incisional hernias—early operative outcomes and

technical remarks on a novel retromuscular approach. *Videosurgery Other Miniinvasive Tech.* 2020;15:533–45.

52. Yanari S, Suto T, Fujiwara H, Ariyoshi Y, Umemura A, Sasaki A. Intraperitoneal onlay mesh repair (IPOM) plus technique using a hybrid procedure of open laparotomy and laparoscopic approach (hybrid IPOM plus) for incarceration of umbilical hernia in a severely obese patient: a case report. *Surg case reports.* 2020;6(1):83.
53. Grapotte A, Cimpean S. Laparoscopic Intraperitoneal Onlay Mesh (IPOM) “Swiss Cheese” Ventral Incisional Hernia Repair with Urinary Bladder Mobilization: A Case Report. *Am J Case Rep.* 2022;23:e937606.
54. Slavu IM, Filipoiu F, Munteanu O, Tulin R, Ursuț B, Dogaru IA, et al. Laparoscopic Intraperitoneal Onlay Mesh (IPOM) in the Treatment of Ventral Hernias: Technique Discussion Points. *Cureus.* 2024;11:1–6.

ANNEXURE 1 (Consent form)

I am making a voluntary decision to participate in the study “**TILE OF THE PROJECT/STUDY**”. My signature below indicates that I have decided to participate and I have read the information provided above or the information provided above has been read to me in the language that I understand best. I was given the opportunity to ask questions and that they have been answered to my satisfaction.

Name of the participant:

Signature or left thumb impression of the participant:

Name of the witness:

Signature or left thumb impression of the witness:

Name of the investigator:

Signature of the investigator:

ANNEXURE 2 (Performa)

The proposed proforma / questionnaire to be used for data collection for the study titled Extended totally extraperitoneal repair (eTEP) vs conventional laparoscopic repair with defect closure (IPOM +) for umbilical hernias in tertiary Hospital for a period of 1 year.

Preoperative:

Name: IP no.:

Sex: Age:

Date of admission:

Date of discharge:

Mobile number:

Address:

Comorbidites and on any medication:

Umbilical swelling: yes=1 , no=2

Reducible: yes =1, no=2

Cough impulse: yes =1, no=2

History of any pervious surgeries for the same:yes =1, no=2

History of any admonished surgery:yes =1, no=2

History of any blood disorders:yes =1, no=2

Ultrasound Abdomen and pelvis:

Strangulation:yes =1, no=2

Intra operative:

No of ports placed:

Adhesions:yes =1, no=2

Prolene mesh vs other: Prolenemesh =1, other=2

eTEP VS IPOM: eTEP =1, IPOM=2

Absorbable vs non absorbable sutre: Absorbable =1, non absorbable =2

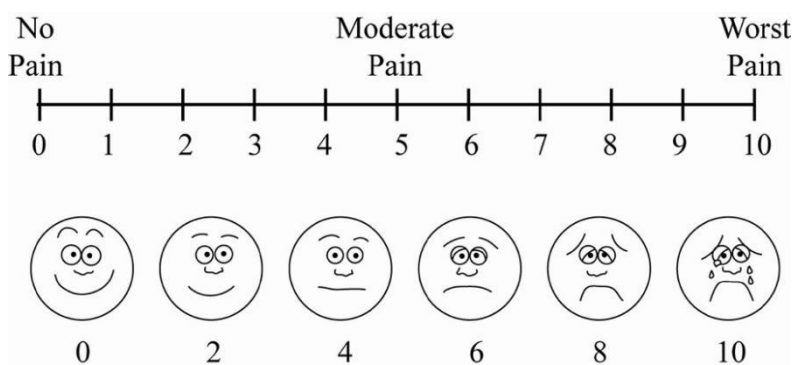
Absorbable vs non absorbable tacker: Absorbable =1, non absorbable=2

Operation time taken:

Any Intra operative complications:yes =1, no=2

Post operative:

Pain on POD 0:Visual Analog Scale(VAS) will be used to quantify pain if any.



Pain on POD 1 : Visual Analog Scale(VAS) will be used to quantify pain if any.

Infection:yes =1, no=2

Surgical site infection: yes =1, no=2

Drain placed :yes =1, no=2

Reoccurrence:yes =1, no=2

Return to work:yes =1, no=2

Disability:yes =1, no=2

ANNEXURE 3 (Pictures)\

- IPOM plus

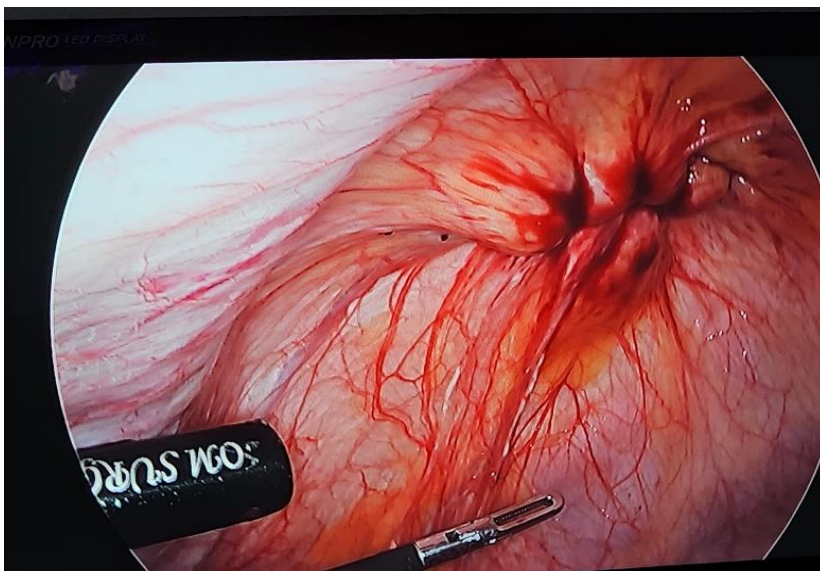
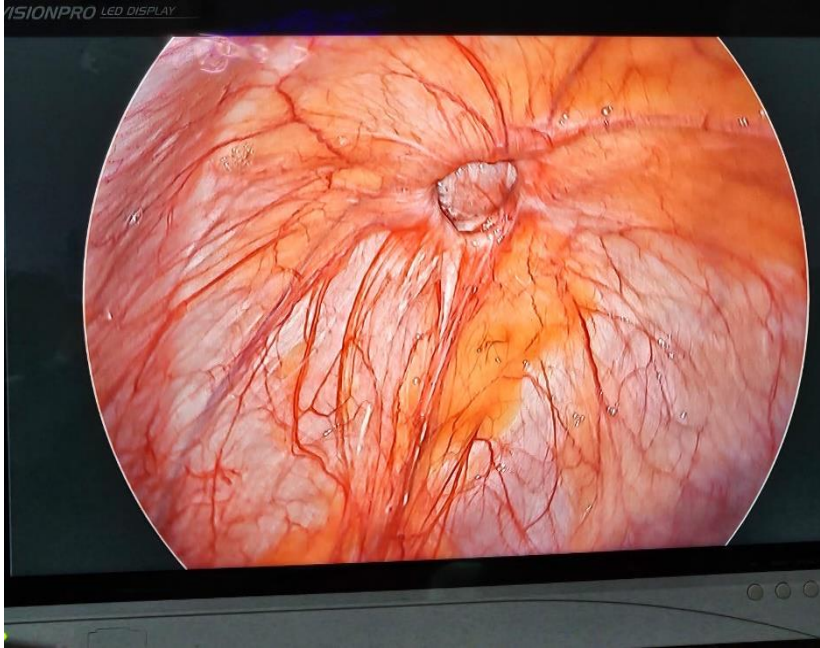


Figure1. (a)umbilical defect size; Figure 1.(b) Primary closure of the defect.

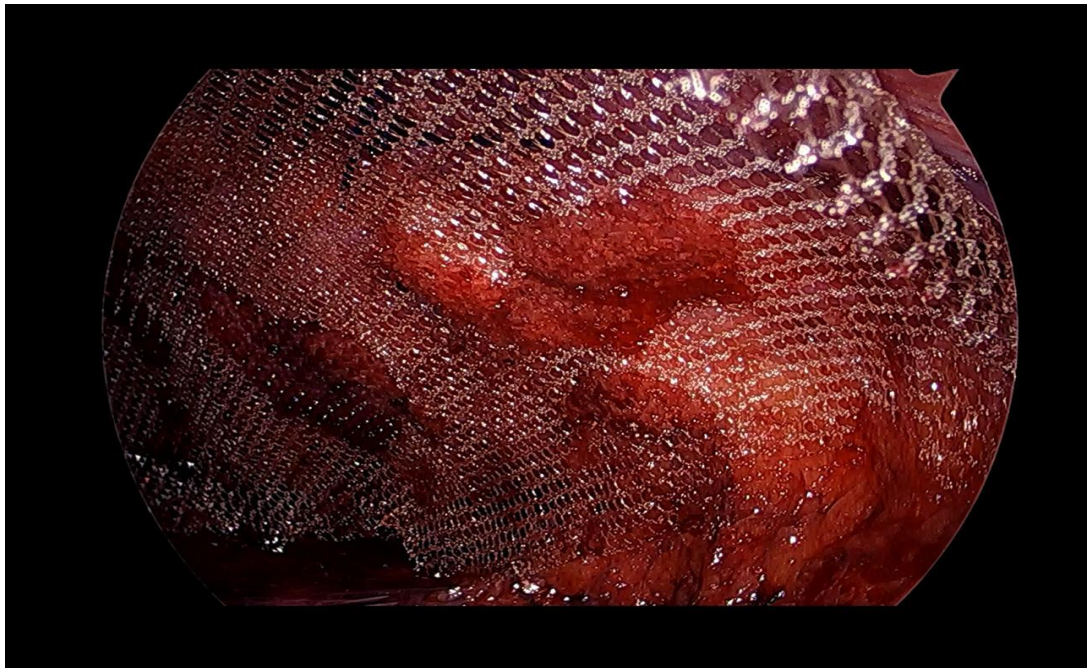
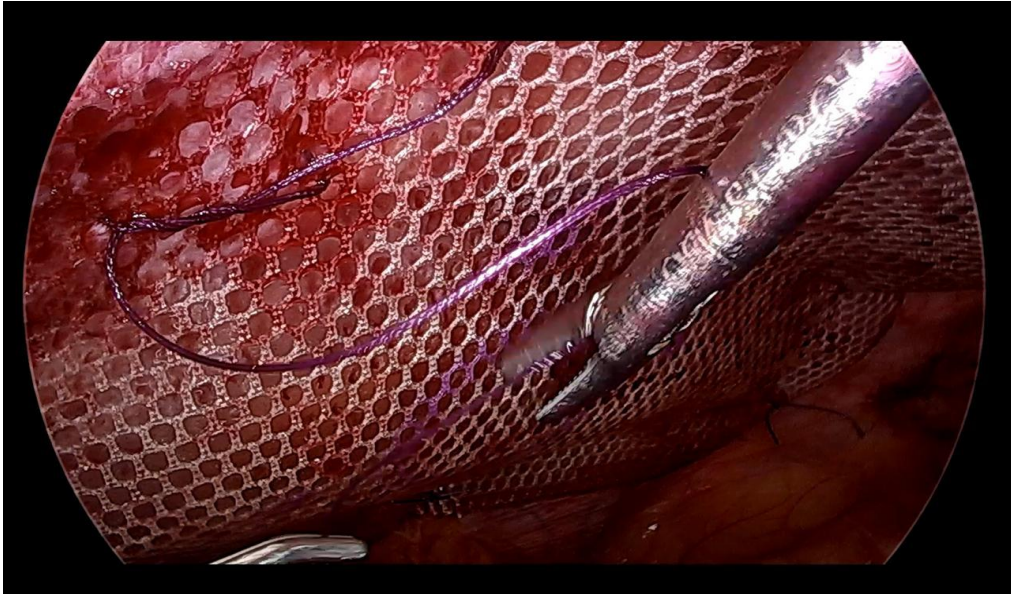


Figure 2a.Composite Mesh fixation with Vicryl 2-0 sutures; 2b. Post mesh fixation.

- eTEP

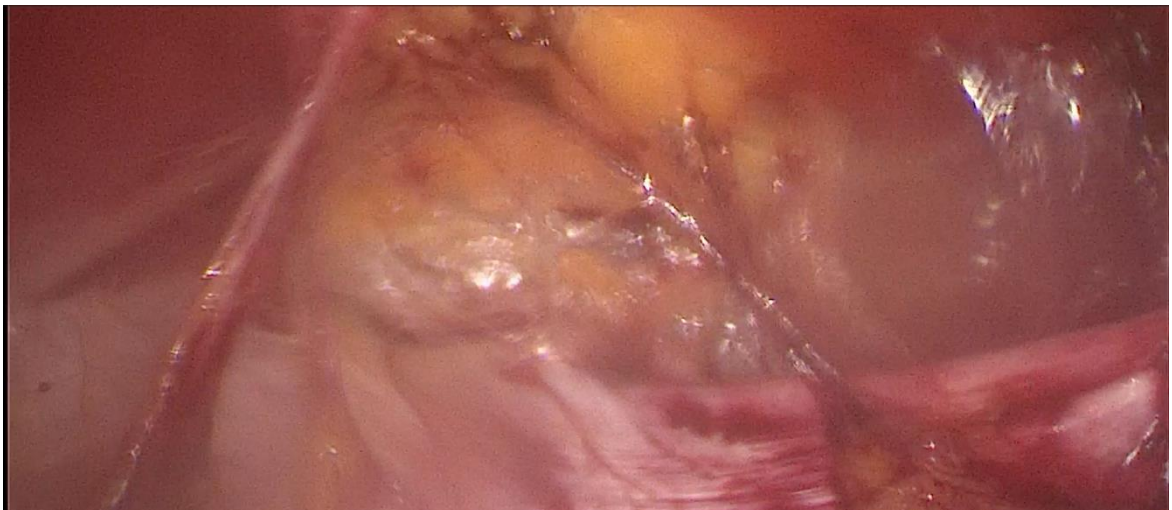
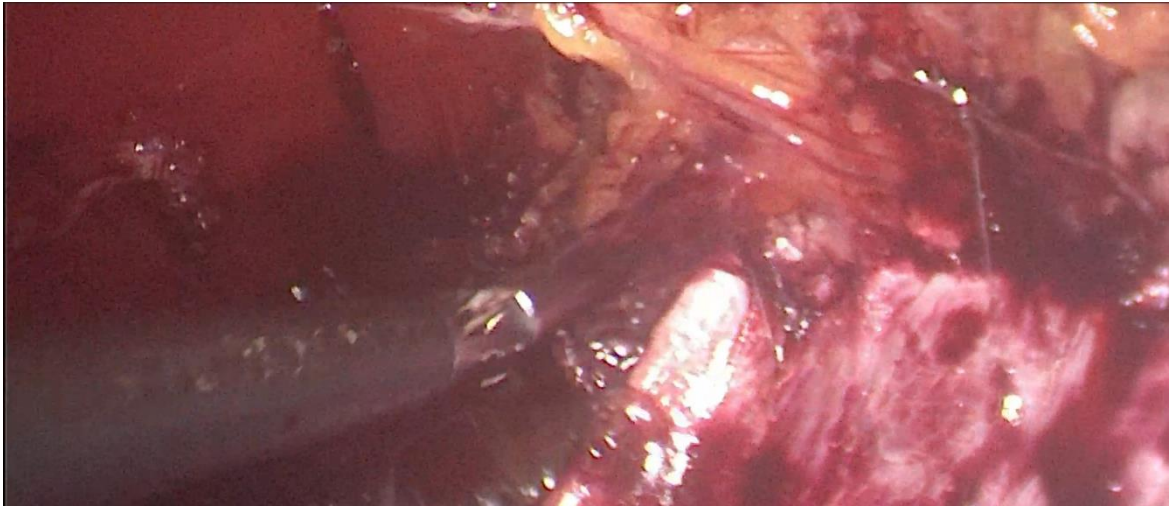


Figure 3a,3b: Dissection of recto-rectus plain.

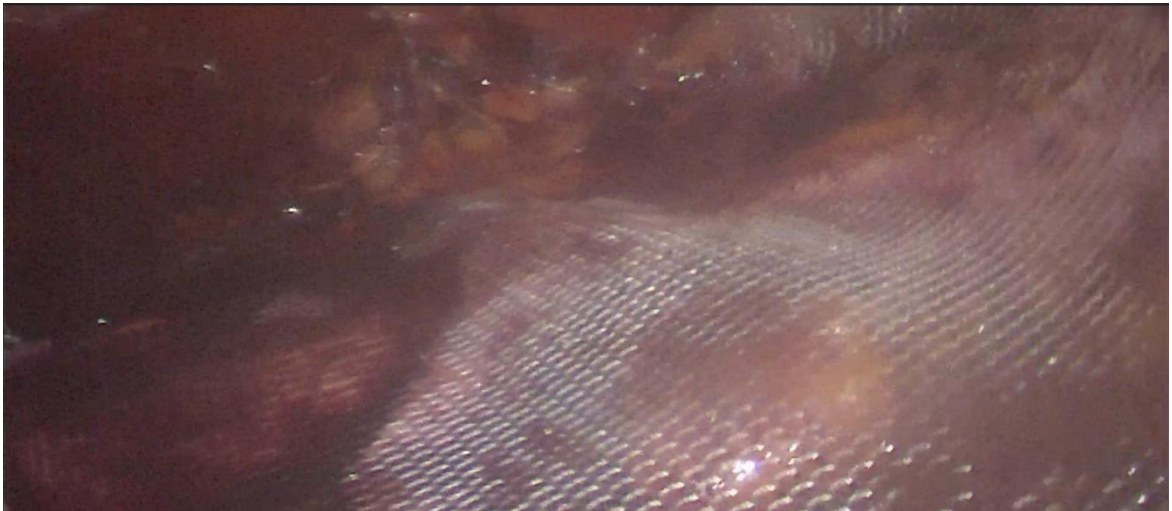
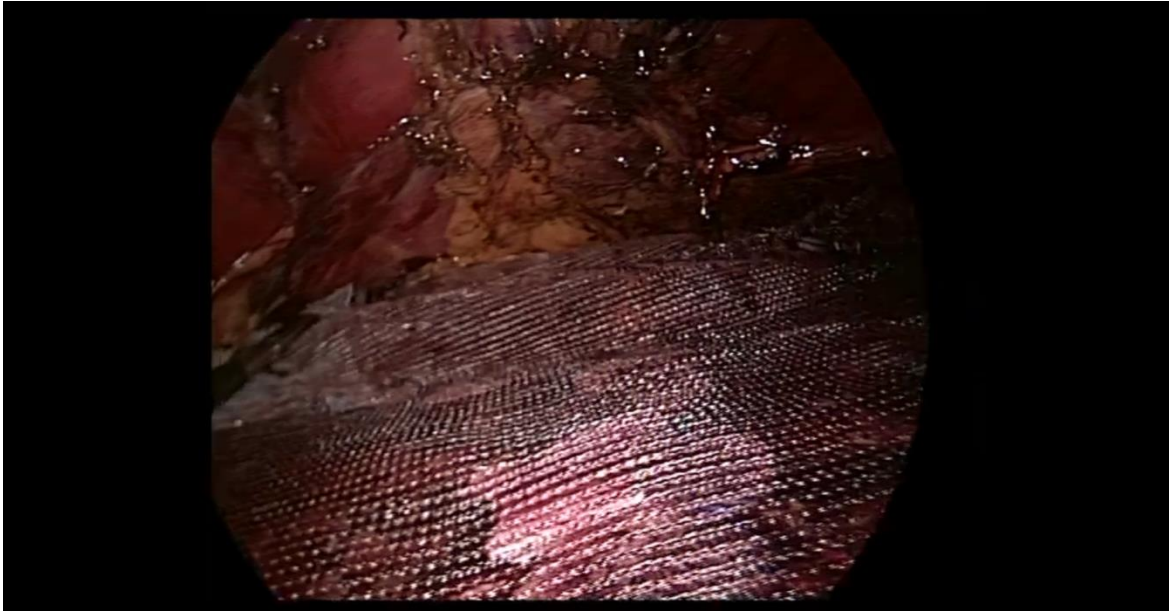


Figure 4a,4b: Prolene mesh placement in the recto-rectus plain.

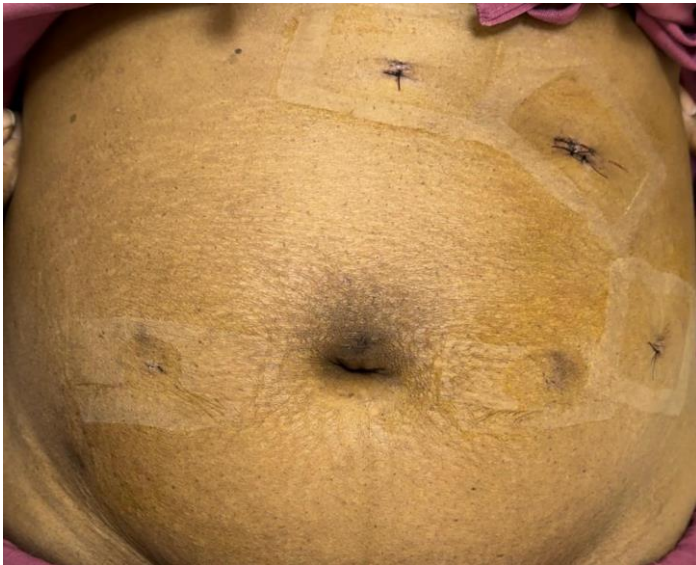
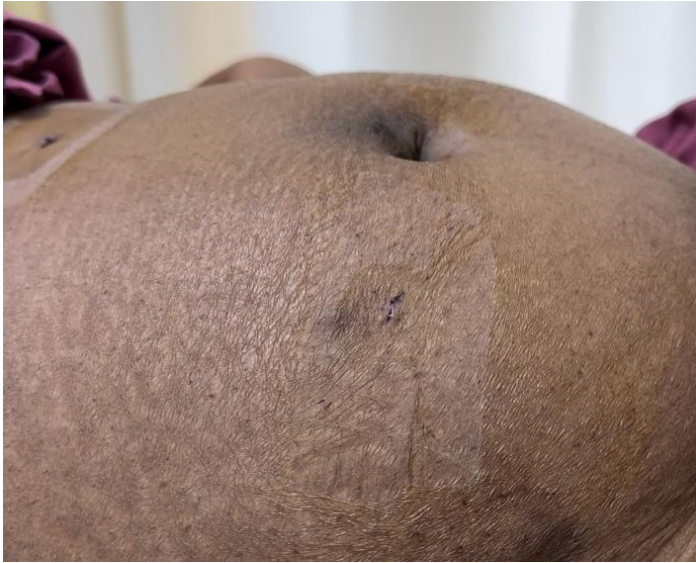

Figure 5a.5b: Post Operative day 3.

MASTERCHART

GROUP A (UMBLICAL HERNIA REPAIR WITH IPOM+)																	
Serial number	AGE/S EX	UPID	DIAGNOSIS	DATE OF ADMISSION	DATE OF SURGERY	DATE OF DISCHARGE	SIZE OF DEFECT	MESH USED	OPERATION TIME (mins)	PO D 1 PAI N	PO D 7 PAI N	PO D 14 PAI N	POD 1 MONTH	POD 3 MONTH	SEROMA	HOSPITAL STAY	WOUND INFECTION
1.	40/M	1203268	Umbilical hernia	9/20/2023	9/21/2023	9/26/2023	3 cm	Composite	84	10	4	2	2	1	NO	6 DAYS	NO
2.	60/M	1195946	Umbilical hernia	3/12/2023	3/13/2023	3/17/2023	2.4 cm	Composite	90	9	5	4	2	1	NO	6 DAYS	NO
3.	36/M	1202247	Umbilical hernia	4/13/2023	4/14/2023	4/19/2023	4.2 cm	Composite	130	10	6	4	3	2	NO	7 DAYS	NO
4.	32/F	1201612	Umbilical hernia	9/12/2023	9/13/2023	9/19/2023	3 cm	Composite	140	8	7	6	4	2	NO	8 DAYS	NO
5.	58/M	1200644	Umbilical Hernia	8/9/2023	8/10/2023	8/14/2023	2.8 cm	Composite	123	9	4	3	1	1	NO	6 DAYS	NO
6.	39/M	1207010	Umbilical hernia	6/6/2023	6/7/2023	6/12/2023	2.1 cm	Composite	142	10	5	3	2	3	NO	7 DAYS	NO
7.	63/M	1199851	Paraumbilical hernia	4/22/2023	4/25/2023	4/30/2023	3 cm	Composite	116	10	6	2	2	1	NO	8 DAYS	NO
8.	45/M	1199857	Umbilical hernia	6/16/2023	6/17/2023	6/22/2024	3.6 cm	Composite	105	9	4	2	1	1	NO	7 DAYS	NO
9.	63/M	1199671	Paraumbilical hernia	1/3/2024	1/4/2024	1/8/2024	2 cm	Composite	70	8	4	3	3	1	YES	6 DAYS	NO
10.	75/M	1199605	Umbilical hernia	4/3/2023	4/4/2023	4/9/2024	4 cm	Composite	81	10	7	3	2	2	NO	7 DAYS	YES
11.	39 / F	1199671	Umbilical hernia	7/4/2023	7/5/2023	7/12/2023	2.6 cm	Composite	70	9	5	2	2	2	NO	9 DAYS	NO
12.	59/F	1195472	Paraumbilical hernia	4/25/2024	4/26/2024	4/30/2024	3.2 cm	Composite	78	10	4	3	1	1	NO	6 DAYS	NO

13.	57 / F	11986 122	Paraumb lical hernia	10/27/2 023	10/28/2 023	10/30/2 023	1.6 cm	Compo site	62	9	5	5	4	4	NO	4 DAYS	NO
14.	47 / F	11987 93	Umblical Hernia	1/12/20 24	1/13/20 24	1/16/20 24	2 cm	Compo site	55	10	5	5	2	2	NO	5 DAYS	NO
15.	32 / M	11986 89	Umblical hernia	10/23/2 023	10/24/2 023	10/26/2 023	4 cm	Compo site	69	7	3	3	2	2	NO	4 DAYS	NO
16.	41 / M	11959 46	Paraumb lical hernia	1/1/202 4	1/2/202 4	1/8/202 4	1.2 cm	Compo site	72	9	2	3	3	2	NO	8 DAYS	NO
17.	80/M	11687 62	Paraumb lical hernia	4/9/202 3	4/9/202 3	4/12/20 23	3.3 cm	Compo site	62	10	5	4	2	2	NO	4 DAYS	NO
18.	55 / F	11672 19	Umblical hernia	4/11/20 23	5/12/20 23	5/22/20 23	2.2 cm	Compo site	90	10	8	4	2	1	YES	11 DAYS	NO
19.	57 / F	11998 51	Umblical hernia	4/6/202 4	4/7/202 3	4/11/20 24	1.4 cm	Compo site	58	8	6	3	1	1	NO	6 DAYS	NO
20.	51/ M	11692 68	Paraumb lical hernia	1/2/202 3	1/3/202 3	1/10/20 23	1.9 cm	Compo site	106	9	5	2	1	1	NO	9 DAYS	YES
21.	50/ M	11996 63	Umblical hernia	6/14/20 23	6/14/20 23	17-06- 2023	4 cm	Compo site	49	8	4	4	2	3	NO	4 DAYS	NO
22.	59 / F	12005 45	Umblical hernia	10/21/2 023	10/22/2 023	10/24/2 023	2.2 cm	Compo site	66	9	5	3	2	2	NO	4 DAYS	NO
23.	59/ M	12006 90	Umblical hernia	3/10/20 23	3/13/20 23	3/17/20 23	4.5 cm	Compo site	77	10	4	2	1	1	NO	7 DAYS	NO
24.	25/ M	12009 00	Umblical hernia	9/9/202 3	9/10/20 23	9/14/20 23	2 cm	Compo site	56	7	6	4	4	4	NO	6 DAYS	NO
25.	39/ M	12013 01	Umblical hernia	11/21/2 023	11/22/2 023	12/1/20 23	4 cm	Compo site	90	10	6	3	2	1	YES	11 DAYS	NO
26.	24 / F	11670 42	Umblical hernia	6/28/20 22	6/30/20 22	7/3/202 2	2 cm	Compo site	58	7	8	4	3	3	NO	6 DAYS	NO
27.	32 / F	11480 44	Umblical hernia	9/3/202 3	9/4/202 3	9/8/202 3	3 cm	Compo site	59	9	7	7	2	2	NO	7 DAYS	NO

28.	55 / M	11683 84	Paraumb lical hernia	11/10/2 022	11/12/2 022	11/16/2 022	3.3 cm	Compo site	79	8	8	6	4	4	YES	6 DAYS	NO
29.	44/ M	11725 33	Umblical hernia	3/3/202 3	3/5/202 3	4/11/20 23	4 cm	Compo site	90	6	9	4	3	2	NO	9 DAYS	NO
30.	33 / M	11726 39	Umblical hernia	3/20/20 23	3/20/20 23	3/25/20 23	1.9 cm	Compo site	60	9	9	4	4	4	YES	6 DAYS	NO
GROUP B (UMBLICAL HERNIA REPAIR WITH eTEP)																	
SERIA L NUMB ER	AGE/S EX	UPID	DIAGNO SIS	DATE OF ADMISSI ON	DATE OF SURGER Y	DATE OF DISCHA RGE	SIZE OF DEFE CT	MESH USED	OPERATI ON TIME (mins)	PO D 1 PAI N	PO D 7 PAI N	PO D 14 PAI N	POD 1 MON TH	POD 3 MON TH	SERO MA	HOSPI TAL STAY	WOUN D INFECTI ON
1.	26/F	11612 19	Umblical hernia	1/26/20 23	1/27/20 23	1/30/20 23	3 cm	Prolene	170	7	4	0	0	1	NO	5 days	NO
2.	55/F	11672 19	Umblical hernia	5/19/20 23	5/20/20 23	5/24/20 23	4.2 cm	Prolene	140	8	7	5	1	1	NO	6 days	NO
3.	54/F	11408 88	Paraumb lical hernia	6/21/20 23	6/23/20 23	3/27/20 23	1.8 cm	Prolene	130	7	7	4	0	0	NO	7 days	NO
4.	54/M	11620 12	Umblical hernia	1/10/20 24	1/11/20 24	1/14/20 24	2.4 cm	Prolene	114	9	8	4	0	0	YES	5 days	NO
5.	33 / M	11351 40	Umblical hernia	6/22/20 23	6/23/20 23	3/26/20 23	3.5 cm	Prolene	110	7	4	2	0	0	NO	5 days	NO
6.	72/M	11705 11	Umblical hernia	2/11/20 23	2/12/20 23	2/14/20 23	4 cm	Prolene	100	8	6	3	1	1	NO	4 days	NO
7.	64/M	11191 78	Umblical hernia	3/14/20 23	3/15/20 23	3/17/20 23	3.1 cm	Prolene	103	7	4	3	2	1	NO	4 days	NO
8.	47/F	11193 31	Paraumb lical hernia	6/22/20 23	6/23/20 23	6/25/20 23	4 cm	Prolene	90	8	5	3	1	0	NO	4 days	YES
9.	46/M	11189 29	Paraumb lical hernia	2/25/20 24	2/26/20 24	2/29/20 24	2.4 cm	Prolene	120	6	3	1	1	0	NO	5 days	NO

10.	45/F	11190 20	Umblical hernia	3/10/20 23	3/11/20 23	3/14/20 23	3 cm	Prolene	130	8	5	2	0	0	NO	5 days	NO
11.	50/M	11192 87	Umblical hernia	11/12/2 022	11/13/2 022	11/19/2 022	1.4 cm	Prolene	122	8	4	2	1	0	NO	8 days	NO
12.	36 / F	11622 57	Paraumb lical hernia	4/9/202 3	4/11/20 23	4/14/20 23	1.6 cm	Prolene	130	8	6	2	0	0	NO	6 days	NO
13.	52/ F	11611 49	Umblical hernia	2/2/202 3	3/3/202 3	3/5/202 3	1.2 cm	Prolene	112	7	5	4	1	0	NO	4 days	NO
14.	41/ M	11623 04	Umblical hernia	1/19/20 24	1/20/20 24	1/24/20 24	2.8 cm	Prolene	93	7	4	2	1	0	YES	6 days	YES
15.	61 / M	11631 23	Umblical hernia	9/8/202 2	9/9/202 3	9/13/20 23	2.1 cm	Prolene	90	7	6	4	1	0	NO	6 days	NO
16.	43 / F	11627 56	Paraumb lical hernia	3/13/20 24	3/14/20 24	3/17/20 24	1.8 cm	Prolene	123	7	4	2	1	1	NO	5 days	NO
17.	25/ M	11634 9	Umblical hernia	2/19/20 23	2/20/20 23	2/25/20 23	1.23 cm	Prolene	112	7	3	1	1	0	NO	7 days	NO
18.	59 / M	11627 35	Umblical hernia	1/31/20 23	2/2/202 3	2/4/202 3	1.2 cm	Prolene	140	8	5	4	0	1	NO	5 days	NO
19.	33/ M	11629 35	Umblical hernia	10/5/20 22	10/6/20 22	10/11/2 022	3.2 cm	Prolene	133	8	6	2	0	0	NO	7 days	NO
20.	22 / F	11652 69	Umblical hernia	1/10/20 23	1/11/20 23	1/16/20 23	2.9 cm	Prolene	100	7	4	2	1	0	NO	7 days	NO
21.	51/ M	11692 70	Umblical hernia	2/18/20 23	2/19/20 23	2/22/20 23	2.2 cm	Prolene	129	8	4	1	0	0	NO	5 days	NO
22.	30/ M	11681 85	Umblical hernia	4/19/20 23	4/20/20 23	4/22/20 23	1.9 cm	Prolene	144	7	2	1	0	0	NO	4 days	NO
23.	50 / M	11683 84	Paraumb lical hernia	8/10/20 23	8/11/20 23	8/16/20 23	3.8 cm	Prolene	130	9	7	4	3	1	NO	7 days	NO
24.	59/M	11689 32	Umblical hernia	2/12/20 24	2/14/20 24	2/19/20 24	3.2 cm	Prolene	120	9	7	5	3	1	NO	8 days	NO

25.	47/M	11955 25	Umblical hernia	4/19/20 24	4/20/20 24	4/26/20 24	3 cm	Prolene	110	6	3	2	0	0	NO	8 days	NO
26.	58 / M	11954 99	Umblical hernia	2/20/20 24	2/22/20 24	2/25/20 24	2.1 cm	Prolene	143	8	4	5	2	0	NO	6 days	NO
27.	48 / F	11955 19	Umblical hernia	3/30/20 24	3/2/202 4	3/5/202 4	2.2 cm	Prolene	132	9	7	4	2	1	NO	6 days	NO
28.	72/ M	11954 29	Paraumb lical hernia	6/28/20 23	6/30/20 23	7/2/202 3	3.5 cm	Prolene	140	8	8	3	2	0	NO	5 days	NO
29.	71/ M	11506 19	Umblical hernia	12/6/20 23	12/8/20 23	12/12/2 023	3.4 cm	Prolene	150	6	4	2	0	0	NO	7 days	NO
30.	35 / F	11507 22	Paraumb lical hernia	3/15/20 24	3/17/20 24	3/20/20 23	2.5 cm	Prolene	130	7	3	2	1	1	NO	6 days	NO