
**“ TO EVALUATE THE FUNCTIONAL OUTCOME OF
DISTAL END RADIUS FRACTURE TREATED USING
VARIABLE ANGLE VOLAR LOCKING COMPRESSION
PLATES” – AN OBSERVATIONAL PROSPECTIVE STUDY**

**BY
REGISTRATION NO: BL0121001**

Dissertation

*Submitted to
KAHER, Belagavi, Karnataka
In partial fulfilment
of the requirements of the degree of*

MASTER OF SURGERY

IN

ORTHOPAEDICS

**DEPARTMENT OF ORTHOPAEDICS
JAWAHARLAL NEHRU MEDICAL COLLEGE,
BELAGAVI, KARNATAKA.**

DECEMBER 2024 / JANUARY 2025

**KLE ACADEMY OF HIGHER EDUCATION AND RESEARCH
BELAGAVI, KARNATAKA**

Endorsement by the HOD/ Principal/ Head of the Institution

This is to certify that the dissertation entitled "TO EVALUATE THE FUNCTIONAL OUTCOME OF DISTAL END RADIUS FRACTURE TREATED USING VARIABLE ANGLE VOLAR LOCKING COMPRESSION PLATES"- AN OBSERVATIONAL PROSPECTIVE STUDY is a bonafide research work done by BL0121001, Department of Orthopaedics , Jawaharlal Nehru Medical College, Nehru Nagar, Belagavi - 590010.



DR. RAVI S JATTI

MS(Ortho)

Professor and Head,

Department of Orthopaedics,

J. N. Medical College,

Nehru Nagar, Belagavi

Date : 29/06/2024.

Place : Belagavi.



DR.(Mrs.) N.S. MAHANTSHETTI

MD (Paediatrics)

Principal,

J. N. Medical College,

Nehru Nagar, Belagavi

PRINCIPAL
J.N. Medical College,
BELAGAVI- 590 016

Date : 29/06/2024

Place : Belagavi.

PLAGIARISM CERTIFICATE



JAWAHARLAL NEHRU MEDICAL COLLEGE

(A constituent unit of KLE Academy of Higher Education & Research Deemed-to-be-University)

(Recognized by National Medical Commission, New Delhi)

Accredited 'A+' Grade by NAAC (3rd Cycle)

Placed in Category 'A' by MoE (Gov)



Nehru Nagar, Belagavi- 590 010, Karnataka, INDIA

☎ 0831 - 2471350

☎ 0831 - 2470759

🌐 www.jnmc.edu

✉ jnctpal@jnmc.edu

Ref No: MDC/PG/

Date: 20-06-2024

"ACCEPTANCE LETTER"

The softcopy of thesis entitled: "TO EVALUATE THE FUNCTIONAL OUTCOME OF DISTAL END RADIUS FRACTURE TREATED USING VARIABLE ANGLE VOLAR LOCKING COMPRESSION PLATES - AN OBSERVATIONAL PROSPECTIVE STUDY" has been submitted for Anti-Plagiarism check through Turnitin software. The scan has been carried out and the scanned output reveals a match percentage of 04% which is within the acceptable limits of 10% as per the guidelines given by UGC.

Guide.



Dr. (Mrs.) N.S. Mahantashetti,
Chairperson-Antiplagiarism Committee &
Principal,
J. N. Medical College, Belagavi.

To,
Reg. No. BL0121001
Postgraduate Student,
2021-22 Batch,
Department of Orthopaedics.
J. N. Medical College, Belagavi.

UNDERTAKING

I Reg No. BL0121001, hereby declare that the information and the data mentioned in my dissertation entitled **“TO EVALUATE THE FUNCTIONAL OUTCOME OF DISTAL END RADIUS FRACTURE TREATED USING VARIABLE ANGLE VOLAR LOCKING COMPRESSION PLATES – AN OBSERVATIONAL PROSPECTIVE STUDY”** belongs to me and is original. I am aware of the definition of plagiarism as detailed below.

- An act or instance of using or closely imitating the language and thoughts of another author without authorization and the representation of that author's works as one's own, as by not crediting the original author.
- A piece of writing or other work reflecting such unauthorized use or imitation.
- The deliberate or reckless representation of another's words, thoughts or ideas as one's own without attribution in connection with submission of academic work, whether graded or otherwise

I hereby declare that the dissertation prepared by me is original one and does not involve plagiarism anywhere. In case at a later stage, it is found that I have indulged in plagiarism, then I am solely responsible for the same and the institution is at liberty to take any disciplinary action against me including cancellation of dissertation or any other penalties imposed by the university.

DATE: 29/06/2024

PLACE: BELAGAVI



BL0121001

ABSTRACT

KEY WORDS – Distal end radius fractures, variable angle volar locking compression plates, Modified Mayo Wrist Score (MMWS), Functional Outcome.

INTRODUCTION - Distal end of radius fractures are one of the most common fractures seen worldwide, accounting for approximately one-sixth of all the fractures. Closed reduction and cast immobilization has been the mainstay of treatment but recently open reduction and plating with conventional plates has gained importance as they can be of great value in treating distal end radius fractures. This study is based on the latest innovation in this regard, the effectiveness of the volar variable angle locking compression plate in treating distal end radius fractures.

OBJECTIVE - To evaluate functional outcome of wrist associated with variable angle volar locking compression plate in distal end radius fractures.

METHOD - The patients presenting to orthopaedics OPD and emergency with history of trauma and wrist x-ray suggestive of distal end radius fracture will be evaluated, all patients will be assessed post operatively and followed up for 1 year for functional outcome after fixing it with Variable angle volar locking compression plates.

RESULT - 27 patients were followed up for a total of 1 year. The extent of ROM at wrist joint was noted. And patients were asked to answer the Modified mayo wrist score questionnaire at the end of one year and results was calculated accordingly. 70.37% patients had excellent results and 18.52% patients had good results, while 11.11% patients had fair results. Complications like wrist stiffness, infection were seen.

CONCLUSION - Use of variable angle locking compression plates in distal radius fractures provide fair to excellent results and are effective in the correction and maintenance of distal radius anatomy. Hence Variable angle volar locking compression plate is useful and better implant in fixing unstable and comminuted intraarticular distal radius fractures.

LIST OF ABBREVIATIONS

ACL	Anterior Cruciate Ligament
AC joint	Acromio Clavicular joint
AO	Arbeitsgemeinschaft for Osteosynthesefragen (Association of Orthopaedics)
AP	Antero Posterior
CRPS	Complex Regional Pain Syndrome
CT	Computed Tomography
DRUJ	Distal Radio UlnarJoint
FCR	Flexor Carpi Radialis
FPL	Flexor Pollicis Longus
LCP	Locking Compression Plate
MMWS	Modified Mayo Wrist Score
OPD	Out Patient Department
ORIF	Open Reduction and Internal Fixation
ROM	Range Of Motion
SD	Standard Deviation
TFCC	Triangular Fibro Cartilagenous Complex
VAVLCP	Variable Angle Volar Locking Compression Plate
#	Fracture
%	Percentage
<	Less than

TABLE OF CONTENTS

SI. NO	CONTENT	PAGE NO
1	INTRODUCTION	11
2	OBJECTIVES	12
3	LITERATURE REVIEW	13
4	ANATOMY	18
5	MATERIALS AND METHODS	40
6	GALLERY	46,47,48
7	RESULTS	49
8	DISCUSSION	64
9	CONCLUSION	67
10	OVERVIEW	68
11	BIBILOGRAPHY	69
10	ANNEXURES	
	CONSENT FORM	77
	CASE PROFORMA	81
	ETHICAL COMMITTEE CLEARANCE	84
	PHOTOGRAPHS	85
	MASTERCHART	88

LIST OF TABLES AND GRAPHS

TABLE.NO	TITLE	PAGE.NO
1	Sex Ratio of our study	49
2	Affected side distribution	50
3	Mechanism of injury	51
4	Age Distribution	52
5	AO classification	54
6	Other Injuries	56
7	Functional Outcome	57
8	Results vs Outcome	60
9	Adverse events	62
10	Evaluation of results	63

GRAPH.NO	TITLE	PAGE.NO
1	Sex Ratio	49
2	Affected side	50
3	Mechanism of injury	51
4	Age distribution	53
5	AO Classification	55
6	Other Injuries	56
7	Functional Outcome	59
8	Results vs Outcome	61
9	Adverse Events	62
10	Evaluation of results	63

LIST OF FIGURES

FIG .NO	TITLE	PAGE.NO
1	Axial image of wrist	18
2	Articulating area of distal radius and ulna	19
3	Facets of distal radius	20
4	Important structures at level of wrist and forearm	21
5	Ligaments of distal radius	20
6	Vascular supply of distal radius	23
7	Frykman classification	25
8	Melone and Fernandez classification of distal radius fractures	26
9	AO/OTA classification of distal radius type A	27
10	AO/OTA classification of distal radius type B	27
11	AO/OTA classification of distal radius type C	28
12	Volar tilt of distal radius	29
13	Radiological measurement of radial height	30
14	Radiological measurement of ulnar variance	30
15	Radiological measurement of radial inclination	31
16	Carpal malalignment	31
17	Positive ulnar variance	32
18	Acceptable reduction criteria for distal radius fracture	33
19	Management of distal radius fracture	35
20	Depicting variable locking screws cup shaped threads	37
21	VAVLCP SET	38

**“ TO EVALUATE THE FUNCTIONAL OUTCOME OF
DISTAL END RADIUS FRACTURE TREATED USING
VARIABLE ANGLE VOLAR LOCKING COMPRESSION
PLATES” – AN OBSERVATIONAL PROSPECTIVE
STUDY**

INTRODUCTION

The most common fractures in the upper limb are those of Fractures in Distal end Radius , which is seventeen percent of other fractures and seventy five percent of forearm fractures. [1] Of all fractures examined and treated, these injuries make up around one-sixth of cases.As Dr. Abraham Colle's put it [2] "this fracture takes place about an inch and a half above the carpal extremity of the radius and there is a 17% lifetime probability for distal radius fractures."

Majority of the wounds are "closed" . For optimal functional outcomes, restoring radial height, volar tilt, and congruency of articulating area is crucial. [3] A variety of malformations and limitations may result from an inability to attain and maintain near anatomic repair. To do this, the surgeon can choose from a variety of approaches. Different approaches, such as percutaneous K wire fixation with cast immobilizations, universal mini external fixators, and opening up the fracture and reducing it with help of plate, are used to treat fractures of lower Radius. Though widespread, there isn't a clear consensus on how to treat these fractures because the literature doesn't provide any conclusive clinical based information. [4] A successful result is frequently unattainable when utilizing the same methods and materials for various kinds of fractures. The secret to successfully managing more complicated distal radius fractures is the recognizing fracture pattern, safe fracture repair, and holding anatomic reduction.(5)

STUDY OBJECTIVE

Study Objective was to assess functional recovery of fractures in distal end radius treated with Variable angle Volar locking compression plate.

LITERATURE REVIEW

A prospective study done in between October 2015 to September 2017 done by Dr.amarnath ap et al [6] concluded “Variable angle volar locking compression plates can produce good functional results because they enable quick mobilization without causing fracture collapse or loss of reduction. Due to its low rate of complications, this therapeutic approach may prove beneficial in the management of unstable distal end radius fractures, hence promoting prompt rehabilitation.”

A prospective study done in between may 2013 to October 2015 done by Dr.Ashish et al [7] “determined that lower radius fractures treated with variable angle volar locking plate when compared to fixed angle volar locking plate reduces risk of loss of anatomic reduction and wrist stiffness, and that positive outcomes are possible.”

A prospective study done in between January 2018 to December 2018 done by maj Hemant singh chahar et al “concluded that variable angle volar Locking plates at the distal end radius represents a notable advancement in the treatment of distal radius fractures, enhancing the restoration of wrist shape and function.”

A prospective study done in between September 2018 to October 2019 done by Dr Sanjeev gupta and co [14] “The study found that using variable angle volar Locking plates for distal radius fractures minimizes complications and the risk of redisplacement and malunion, leading to improved patient outcomes.”

Dobyns JH et al (1980) “A study of 565 patients with Colles fractures treated conservatively between 1968 and 1975 revealed a high complication of thirty one percent” [2]

JK Bradway et al “ A retrospective review of 16 patients with distal end radius fractures treated with open reduction and internal fixation concluded that this method is preferred for

displaced, comminuted intra-articular fractures. This approach is recommended when closed reduction fails to align the articular surface, as anatomical restoration is crucial to prevent post-traumatic arthritis.”[48]

IP WY,Chow SP et al.(1997) “In their study involving 34 patients with intra-articular distal end radius fractures, the use of open reduction and internal fixation with buttress plates and screws was found to primarily offer the advantages of restoring normal alignment and ensuring stable fixation.”[47]

Jakob M et al (2000)“ A study involving 76 patients concluded that for dorsally displaced fractures requiring open reduction to restore congruency and extra-articular anatomy, utilizing a double plating technique with 2mm titanium plates is a dependable approach. This method ensures stable internal fixation and facilitates early functional recovery.”[46]

Richard A. Rogachejesky et al (2001) Research findings “indicate that severe comminuted intra-articular fractures of the distal radius necessitate treatment through open reduction coupled with a combination of internal and external fixation methods. This integrated approach, complemented by bone grafting and plate fixation as required, proves to be an effective and acceptable treatment option.”[49]

Spranger A et al.(2003) “In Berlin, his initial clinical encounters with variable angle volar locking compression plate for dorsally displaced fractures of the distal radius were documented. Out of 24 patients, most achieved a favorable range of motion and promptly resumed regular activities.”[21]

“Between 2001 and 2003 in Hong Kong, Wong KK and Chan KW et al administered open Reduction and internal fixation with a locking compression plate to 54 patients with Unstable

distal radius fractures. Their findings indicated excellent to good outcomes, Supporting the efficacy and safety of volar locking compression plating for these Fractures.”[22]

“In Germany, from January 1999 to December 2003, Köck et al managed 603 patients with Distal end radius fractures but no additional injuries, using a locking compression plate. Thanks to the permanent retention provided by subchondral fixation, early mobilization Was feasible. Opting for the volar approach minimized infection risks and eliminated the Need for plate removal.”[31]

“In Washington, Musgrave DS et al investigated the applicability of locking compression Plates for treating unstable distal end radius fractures. Their findings confirmed that Employing volar fixed-angle plate fixation, with or without radial styloid fixed-angle plate Fixation, offered ample rigidity, enabling early active range of motion without compromising Fracture reduction. This approach also enhanced the early initiation of functional Outcomes.”[23]

“In the US, Cognet JM et al examined the use of plate fixation with locking screws for distal Radius fractures in 67 patients. His analysis revealed that while the ideal fixation method for Distal radius fractures is debatable, the initial stability attained with a locking screw in a Plate facilitates early mobilization, leading to a swifter recovery of function.”[24]

In Mineola, USA, Scott M. Levin et al “noted that fixed angle constructs endure cyclical Loading, mimicking typical physiological forces encountered during postoperative recovery. Their conclusion emphasized that volar fixed-angle locking plates represent an efficient Treatment option for unstable extra-articular distal radius fractures, enabling the initiation Of early postoperative rehabilitation safely.”[27]

Adam Hart's research in 2009 showed that "variable-angle screws offer similar Biomechanical stability as fixed-angle VLPs in the DU position, allowing for a 3 mm margin In both sagittal and coronal directions. While the use of more expensive polyaxial plates Might not be warranted in uncomplicated extra-articular fractures, the additional flexibility Provided by independent screw trajectories aids in placing plates in intricate intra-articular Fractures." [45]

Sascha Rausch's research in 2011, conducted in Germany, "revealed that the polyaxial 2 Column plate is an effective solution for managing intra-articular fractures of the distal end Radius. This plate type demonstrates increased construct stiffness and superior Performance during cyclic loading, establishing it as a reliable and advanced device." [43]

William J. Marlow from Macclesfield, U.K., in 2012, "highlighted the emerging shift towards Volar plating systems featuring variable angle distal locking screws. This advancement Enables surgeons to customize screw orientation to avoid intersecting articular surfaces And achieve more accurate fragment capture. The new plating system offers benefits in Securing comminuted fractures and reconstructing the intricate geometry of the distal Radius articular surface, all while minimizing the irritation of the tendon and joint Penetration. Variable angle locking plates hold promise for increased flexibility in implant Positioning and improved intra-fragmentary fixation in specific fracture cases." [39]

Mark Lenz observed in 2014 that "variable angle locking screws enable screw orientation Within a 15° cone, making it easier to directly fix fracture fragments with precise screw Placement. These screws exhibit locking strength comparable to orthogonally placed fixed Angle locking screws when inclined up to 15°, whereas fixed angle screws inserted at 5 to 15° inclination showed reduced locking strength." [10]

In 2014, Louay observed that the “polyaxial volar locking plate system allows for deeper insertion of distal screws into the subchondral bone, enhancing support for fracture fragments. This capability to adjust screw insertion angles by 15° from the center likely contributes to increased construct rigidity, potentially leading to improved outcomes for patients with osteoporotic lower end radius fractures.”[29]

ANATOMY

The distal part of radius and ulna are crucial components of wrist and restoring the normal anatomy is vital for wrist range of motion and load transmission

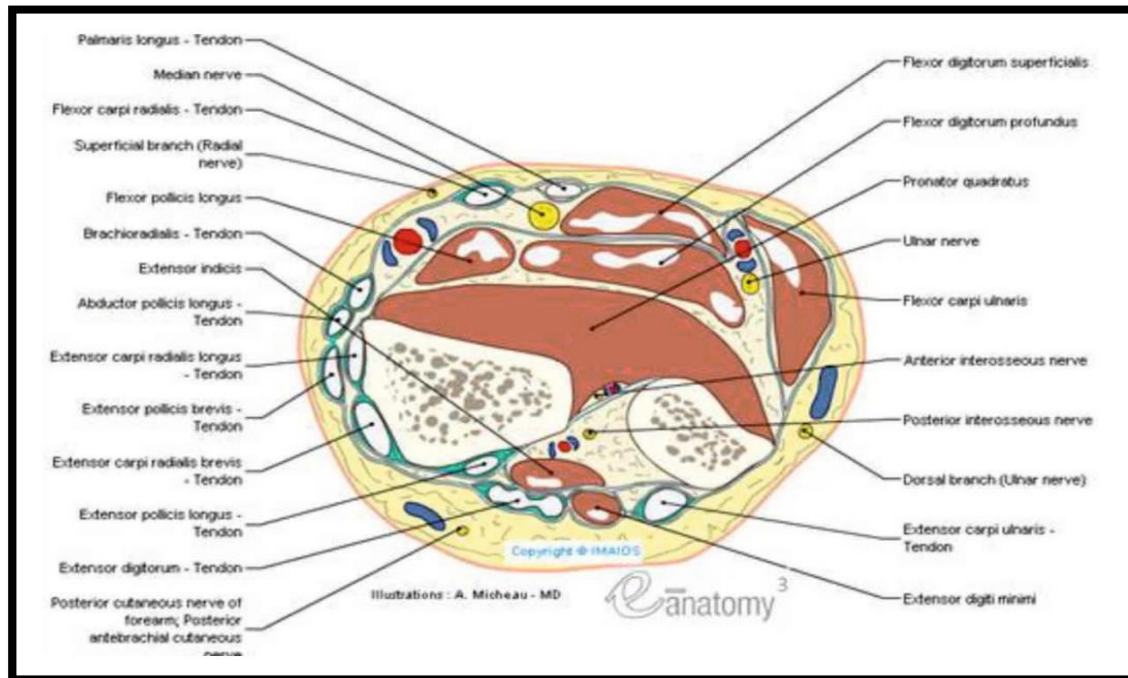


Figure 1 AXIAL IMAGE OF WRIST

The wrist joint plays a crucial role in maintaining hand posture and enabling full hand function. Consequently, fractures that heal improperly may negatively impact hand function.

The distal radius's articular surface comprises two concave areas, one articulates with scaphoid and another one articulates with lunate. A ridge separates these two by extending from dorsal surface to volar. The surface shaped like a triangle, with its widest part created by the sigmoid notch and its narrowest point at tip of styloid process of Radius. Additionally, The articulating area slopes towards the palmar side and the ulnar side. The volar aspect of radius curves inward proximally to distally. It's quite smooth, facilitating the good placement of curvature of plate in this region. Additionally, it provides anchorage for robust radio-carpal

ligament, which help counter the natural inclination of the wrist to move toward the ulna and palmar side . This curvature's overlaid by horizontal muscle fiber group of Pronator Quadratus muscle, which connects to lateral aspect of Radius.

Dorsum part of the bone is convex and notably uneven, with Listers tubercle being the most prominent feature, serving as the passage point for the tendon of extensor pollicis longus. Grooves over this surface create base for extensor compartments

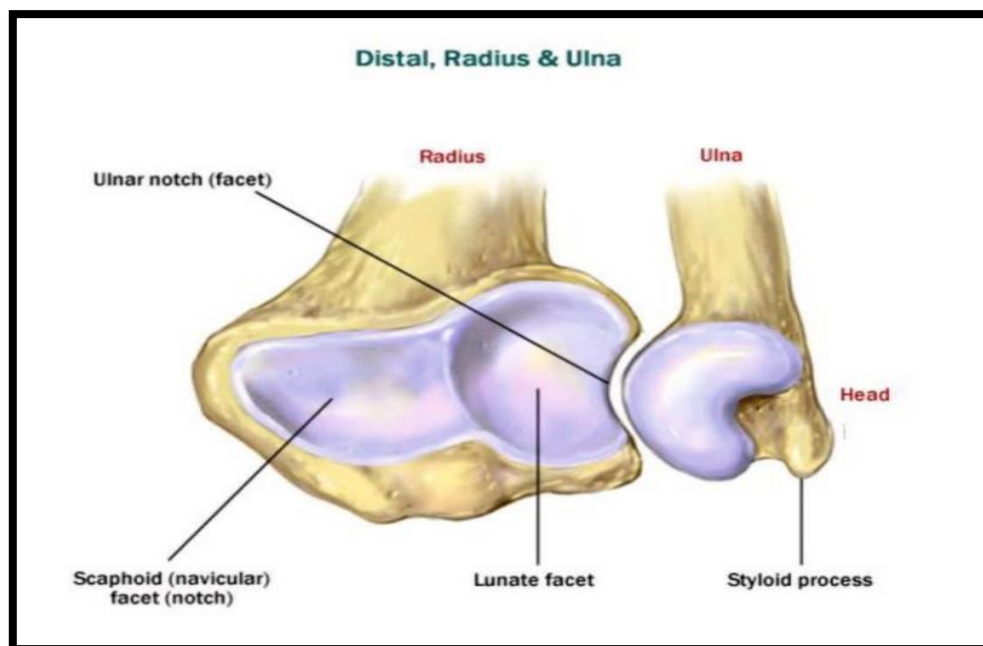


Figure 2 : Shows articulating area of distal ulna and radius

The Radius Sigmoid Notch is a smoothly curved surface semi-cylindrical in shape which allows rotatory movement of radius around the ulnar. The ulnar head moves volarly during supination and Dorsally during pronation. The cartilage is mostly present all over the ulnar

head, even the inferior region. It does not come in direct contact with carpal bones because the TFCC articulates with the triquetrum. TFCC functions as primary stabilizer of the distal Radio-ulnar joint along with flexor Carpi Ulnaris, pronator quadratus, extensor Carpi Ulnaris, inter-osseous membrane of fore-arm.

Dorsal surface of wrist give rise to Radioscapholunate and radiotriquetral ligament.

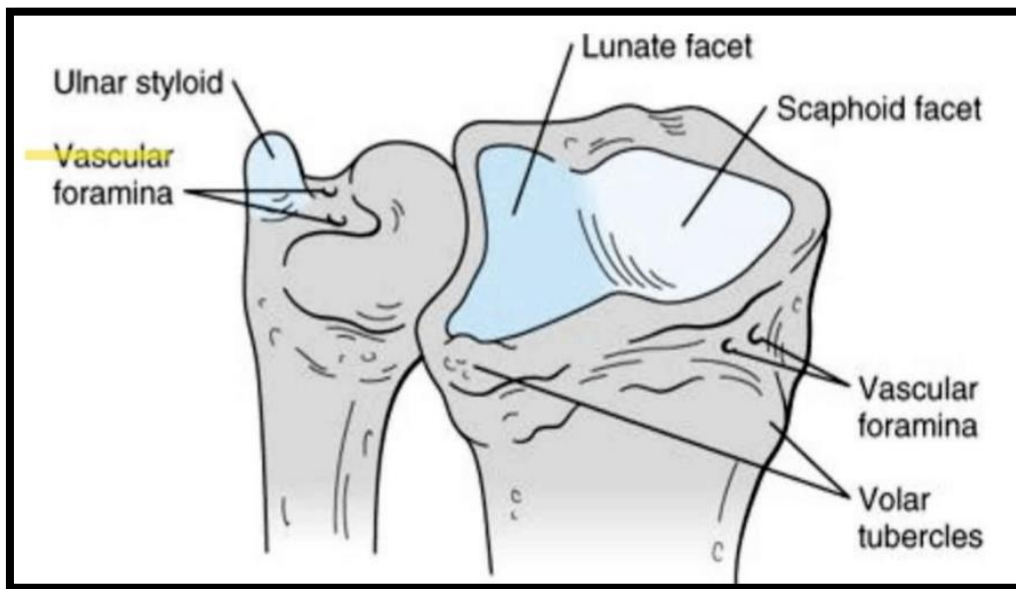


Figure 4 : Facets of distal radius

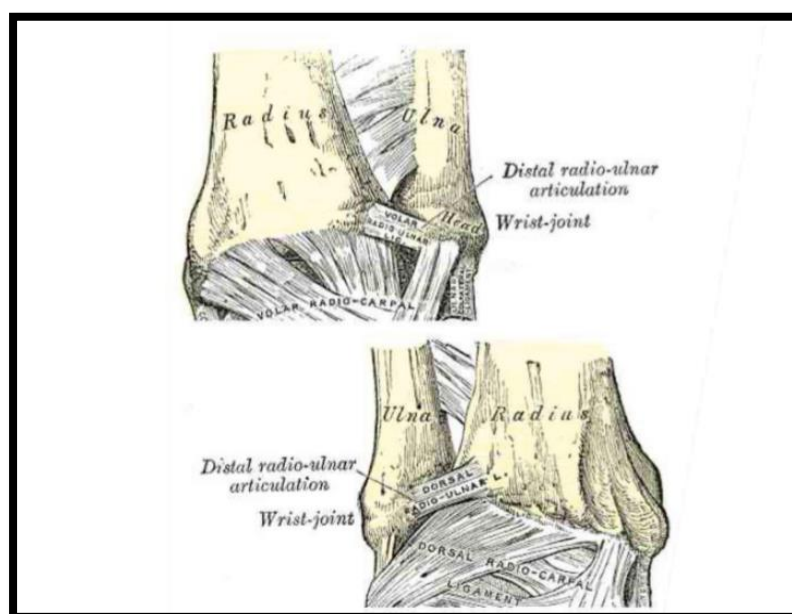


Figure 3 : LIGAMENTS OF DISTAL RADIUS

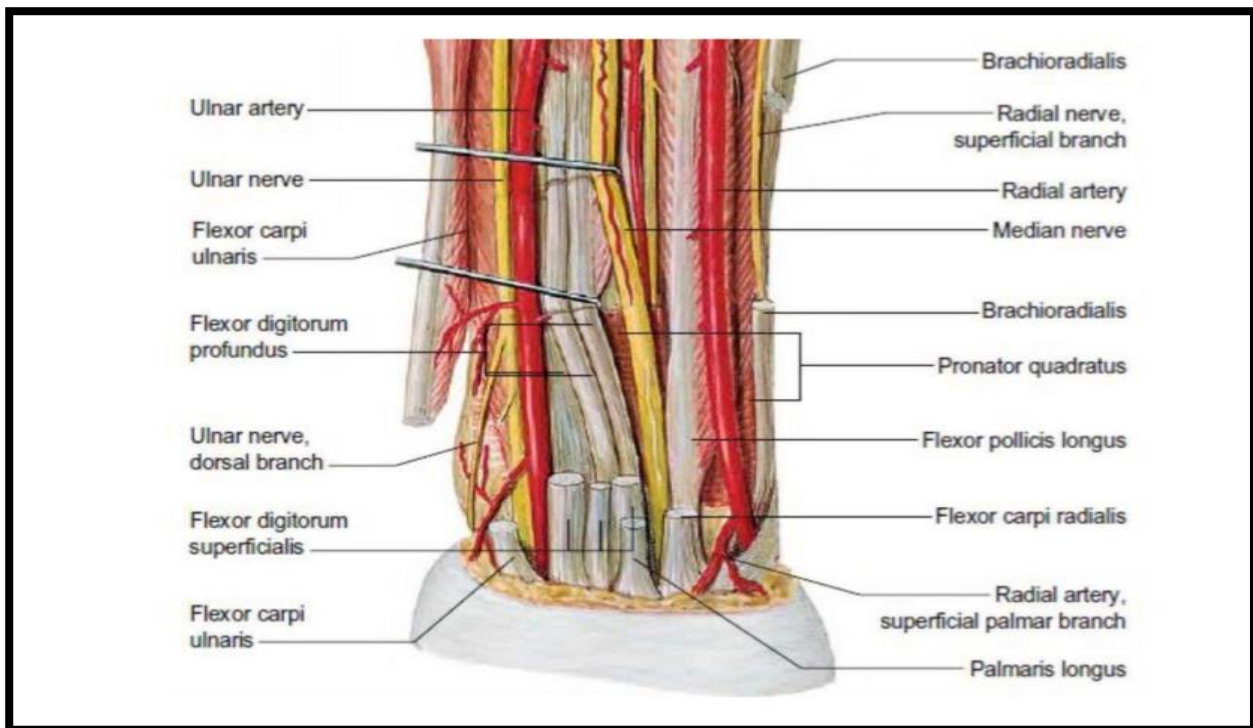


Figure 5: IMPORTANT STRUCTURES AT LEVEL OF WRIST AND FOREARM

The palmar aspect of wrist give rise to Radio-capitate ,Radio-triquetral and Radio-collateral ligament.The TFCC spans from notch of Radial styloid to Ulnar styloid

There are 2 radioulnar ligaments one on dorsal aspect and one on volar aspect which are formed by the thickened edges of dorsal and volar side of TFCC .Distal end of radius along with TFCC articulates with scaphoid,lunate and triquetrum with the help of scapholunate ligament,lunotriquetral ligament,interosseous ligament and extrinsic wrist ligaments.

The tendon of the brachioradialis muscle if the only attachment at lower Radius.Other wrist extensors and flexors after traversing distal radius insert into the base of metacarpal bones and carpal bones

VASCULAR SUPPLY AND NERVE SUPPLY

Distal end radius primarily is supplied by dorsal epiphyseal branches , palmar epiphyseal branches which arise from radial artery, anterior inter-osseous artery and Palmar carpal branch which supply the Radial palmar aspect, sigmoid notch and dorsal surface of Lister 's tubercle, the metaphysis is supplied by periosteal and cortical branches which arise deep from the pronator quadratus and the anterior inter-osseous artery. Nutrient artery supplies diaphysis region along with anastomosis of branches of the Ulnar artery and posterior interosseous artery

The cutaneous nerve supply to Dorsum of wrist is by superficial branch of Radial nerve and Posterior interosseous nerve, palmar supply is from anterior inter-osseous nerve and palmar branch of median nerve

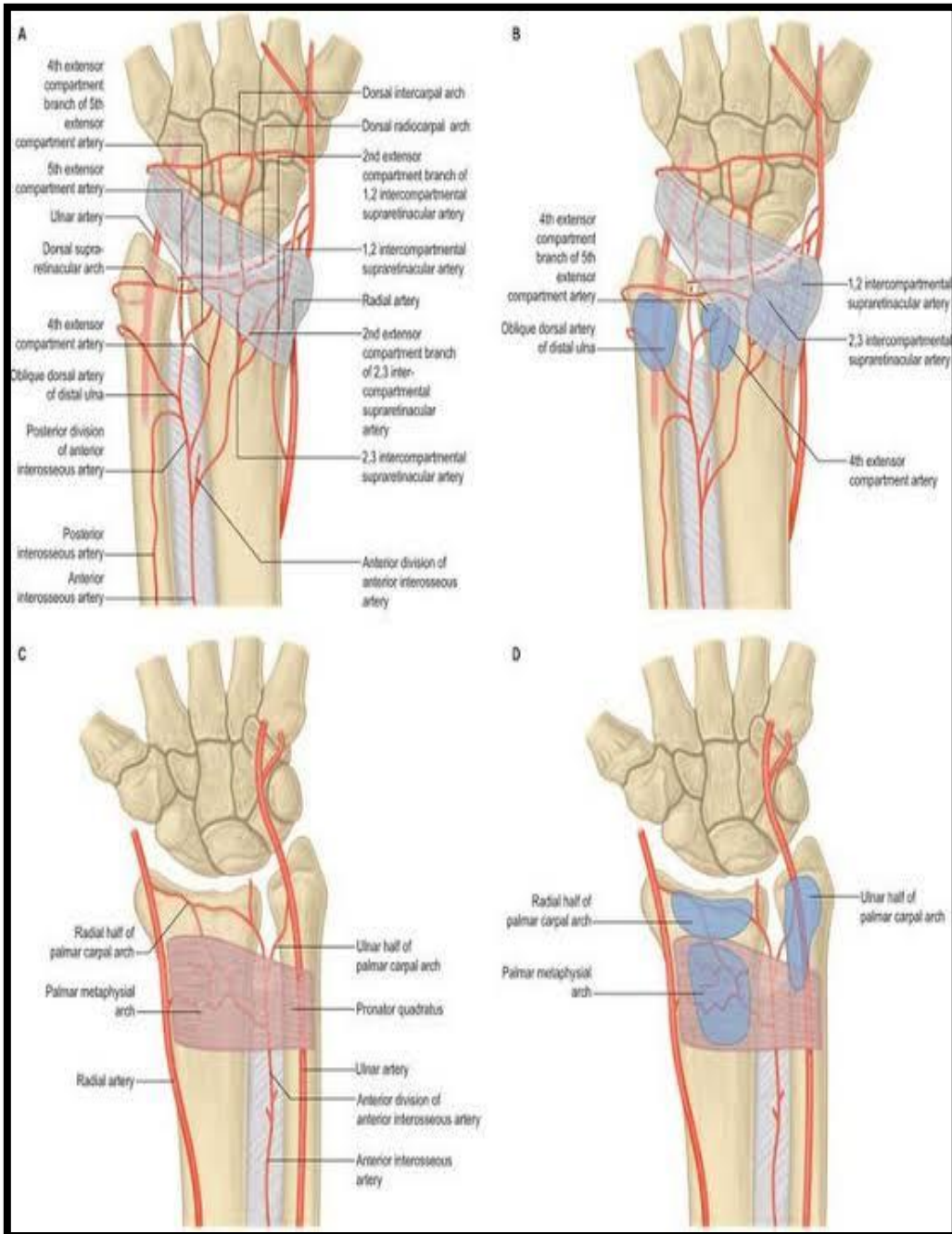


Figure 6 : VASCULAR SUPPLY OF DISTAL RADIUS

BIOMECHANICS OF DISTAL RADIOULNAR JOINT

The radius moves around a fixed stable ulna . There is dorsal or volar dislocation of radius in comparison with stable Ulna. Distal Radio-ulnar joint exhibits both rotational and translational Motion. 4 main structures stabilize the joint in various forearm rotation Dorsal and Palmar radioulnar ligaments, Interosseous membrane and Pronator quadratus

Palmar radio-ulnar ligaments tighten most during forearm supination, stabilizing the joint, while The dorsal ligaments tighten most during forearm pronation.

The axial load transmission takes place mainly through the radius, volar or dorsal displacement of Radius fracture disrupts this mechanism and forces start acting on the TFCC onto the ulna causing positive ulnar variance and increased axial forces through distal ulna

CLASSIFICATION

1) Frykman classification

This classification primarily focused on identifying fracture in articulating surface and distal ulnar fractures. It described regarding radio-carpal involvement and distal radio-ulnar involvement as they were deemed the most significant prognostic factors.

2)Melone devised a classification system for intra-articular fractures, identifying four Components: styloid process of the radius,medial dorsal,volar medial fragment and involvement of radial shaft as shown in the figure

3)Fernandez classified based on mechanism of injury as shown in figure

4)Later AO classified it into extra articular,partial intraarticular and complete intraarticular as shown in the figure which is standardized all over the world

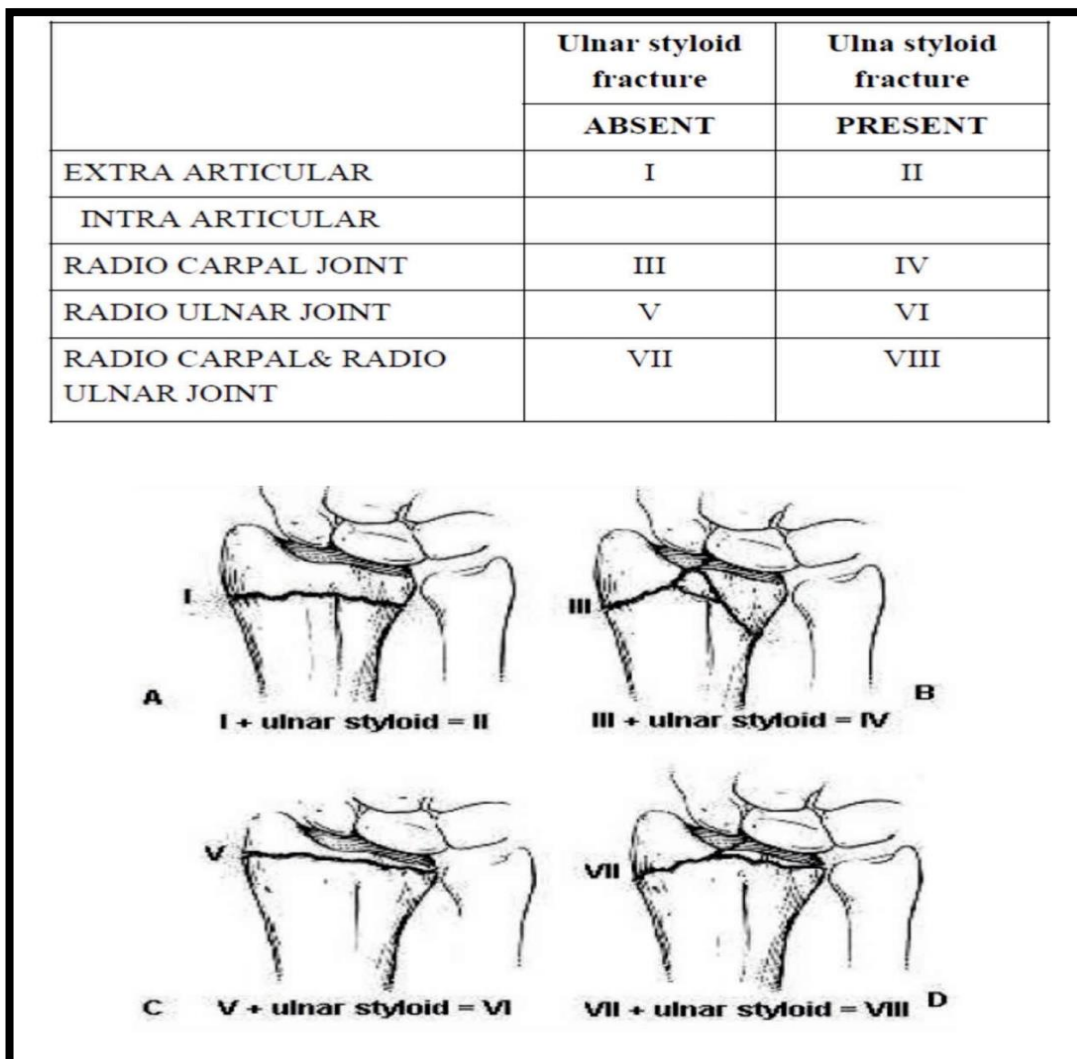
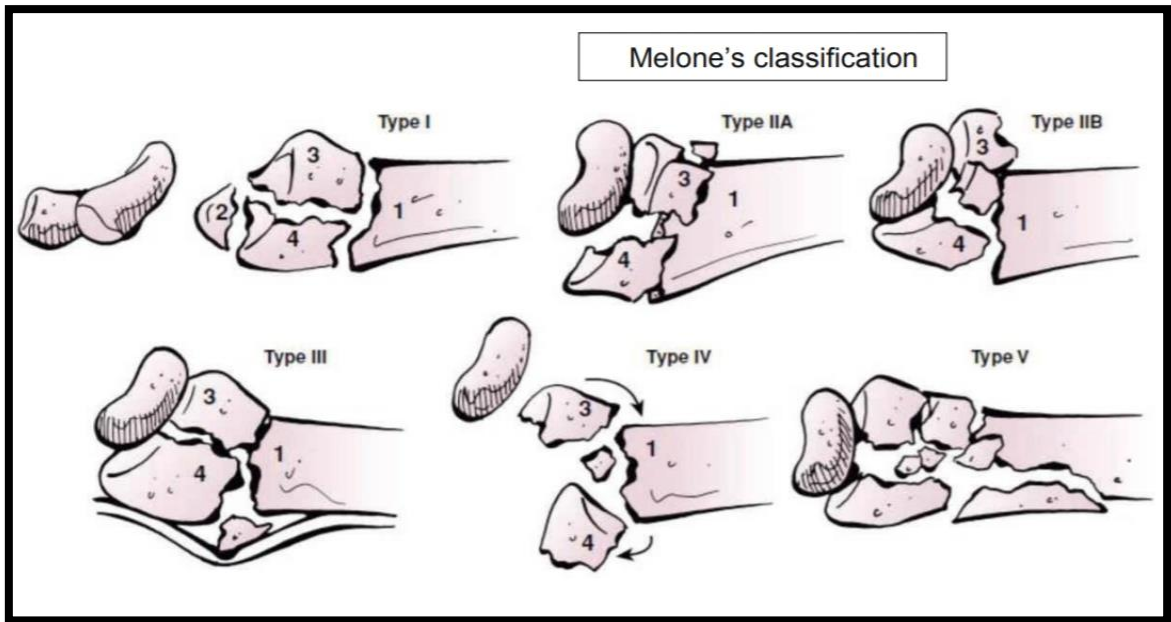


Figure 7 : FRYKMAN CLASSIFICATION



FERNANDEZ (1987)

Fracture Types (Adults) Based on the Mechanism of Injury	Children Fracture Equivalent	Stability/Instability: High Risk of Secondary Displacement After Initial Adequate Reduction	Displacement Pattern
Type I Bending fracture of the metaphysis	Distal forearm Fracture	Stable	Non-displaced Dorsally (Colles-Pouteau)
Type II Shearing fracture of the joint surface	Salter II	Unstable	Volarly (Smith) Proximal Combined
Type III Compression fracture of the joint surface	Salter IV	Unstable	Dorsal Radial Volar Proximal Combined
Type IV Avulsion fractures, radio carpal fracture dislocation	Salter III, IV, V	Stable Unstable	Non-displaced Dorsal Radial Volar Proximal Combined
Type V	Very rare	Unstable	Dorsal Radial Volar Proximal Combined
	Combined fractures (I-II-III-IV) high-velocity injury	Very rare	Unstable

Figure 8 : MELONE AND FERNANDEZ CLASSIFICATION

AO/OTA classification is an inclusive, alphanumeric classification and has 27 different subgroups. Three different types (A —extra-articular, B—partial articular, and C—complete articular) are divided into 9 main groups and 27 different subtypes depending on comminution and direction of displacement.

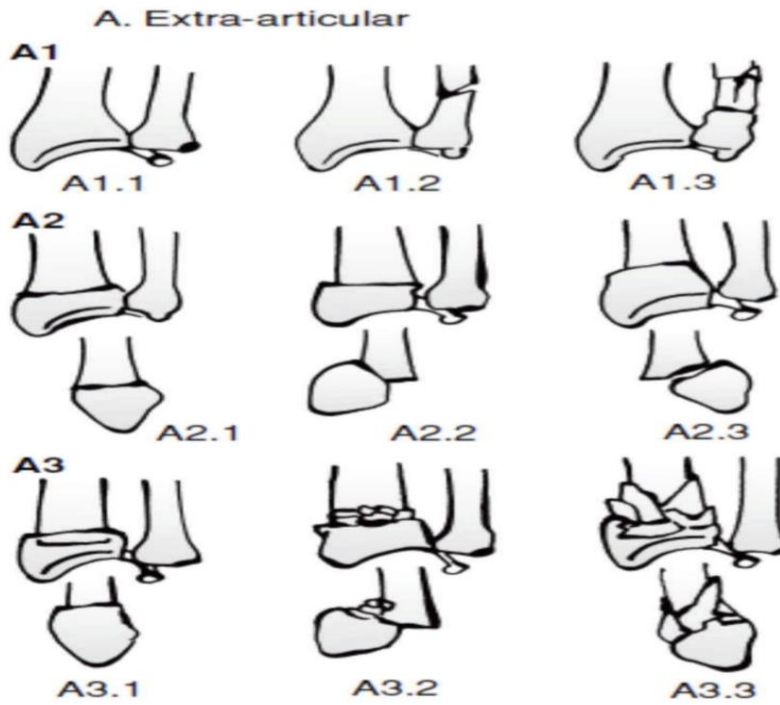


Figure 9 : AO TYP A CLASSIFICATION

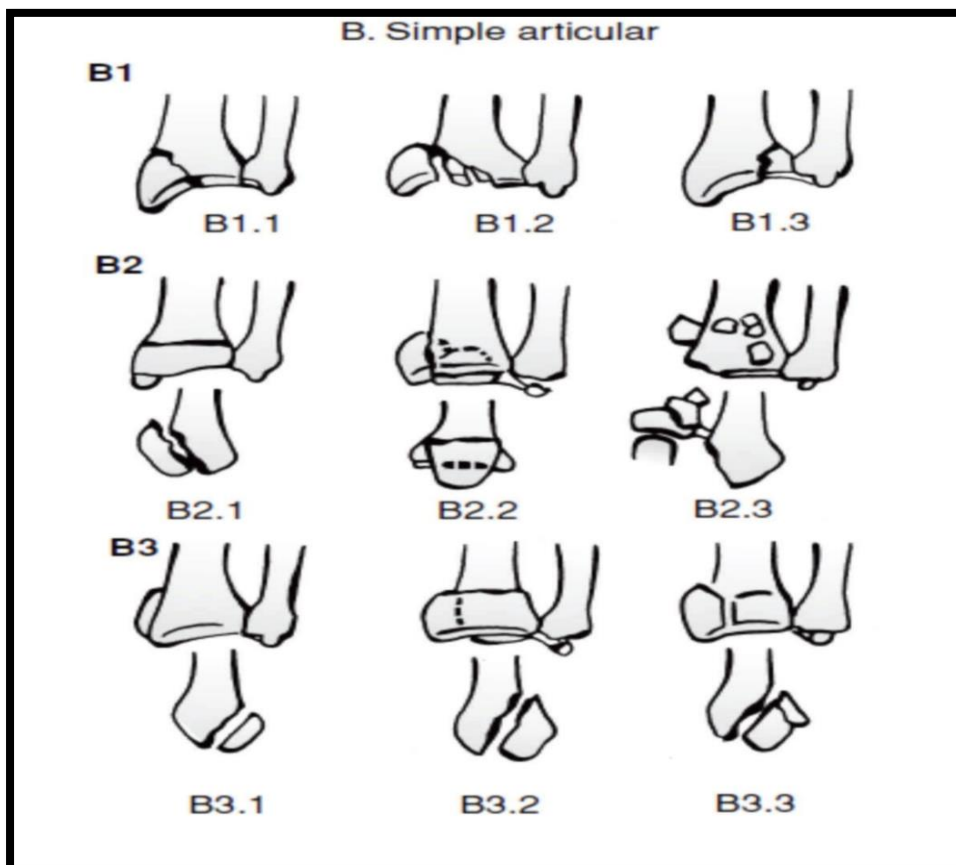


Figure 10 : AO TYPE B CLASSIFICATION

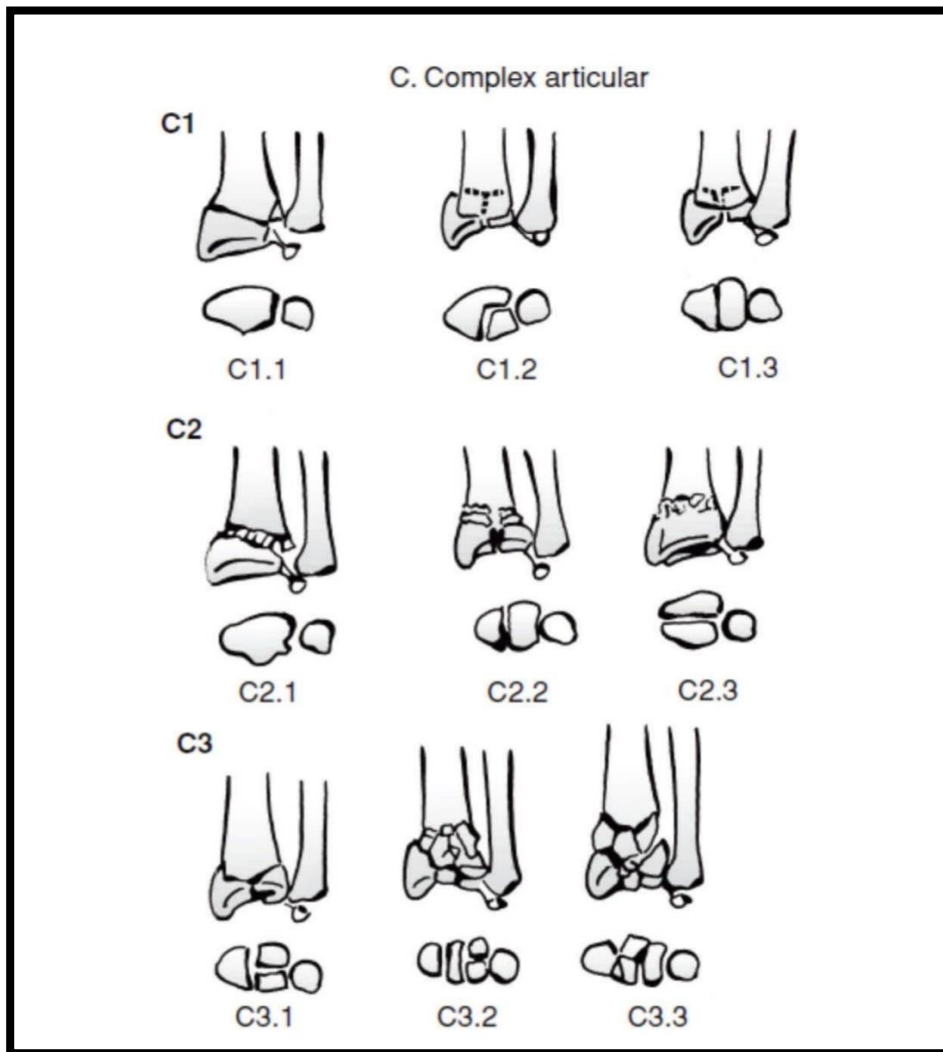


Figure 11 : AO TYPE C CLASSIFICATION

ASSOCIATED INJURIES

Interosseous Ligament Injury:

In distal radius fractures, interosseous ligament damage typically affects the scapholunate and lunatotriquetral ligaments.

Triangular Fibrocartilage Complex (TFCC) Injury:

They are more frequent than interosseous ligament injuries. However with regards to clinical outcome it's not of much significance except for loss of grip strength

EVALUATION METHODS:

X-ray of the involved wrist joint would be the first investigation needed to confirm the clinical diagnosis usually wrist AP view, wrist lateral view would suffice to diagnose .

Additional views might be necessary to assess Associated injuries and displacement accurately. Various radiologic measurements are Commonly employed to gauge distal radius orientation, reducing observer discrepancies.

Palmar/Dorsal Tilt:

Angle formed by a line parallel to radius's longitudinal axis on the lateral view and furthest points of its dorsal and volar lips indicates this tilt.

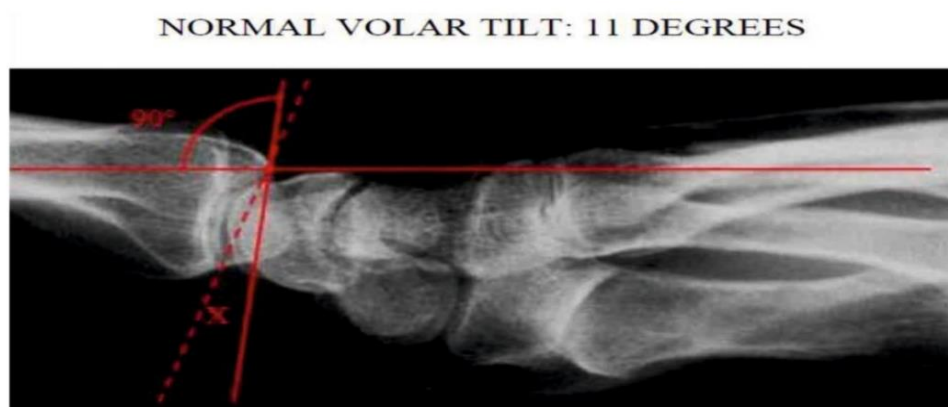

Figure 12 : VOLAR TILT OF DISTAL RADIUS

Radial Length:

In AP view, the distance from the perpendicular drawn to the axis of distal end of ulna and a perpendicular drawn at the distal end of the radial styloid.

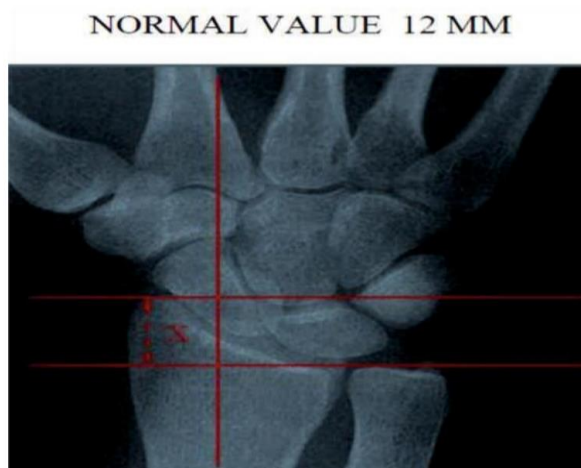


Figure 13 : RADIAL HEIGHT OF DISTAL RADIUS

Ulnar Variance:

This measures radial shortening. The distance between one tangent to the radius longitudinal axis's articular surface with the other tangent Through ulnar head's distal articular surface.

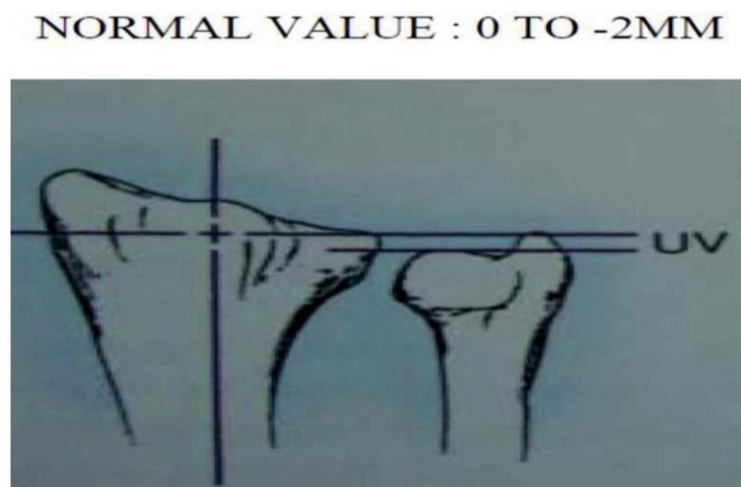


Figure 14 : ULNAR VARIANCE MEASUREMENT

Radial Inclination:

When evaluated in the posteroanterior view, it is the angle between the articular surface of distal end radius and a perpendicular drawn to radius's longitudinal axis.

RADIAL INCLINATION NORMAL VALUE - 23 DEGREES

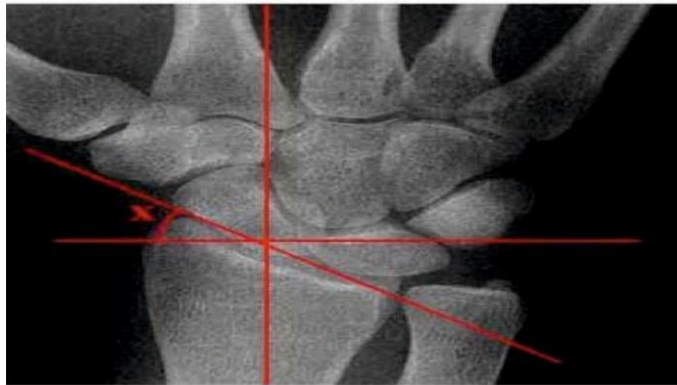

Figure 15 : RADIAL INCLINATION MEASUREMENT

Carpal Malalignment:

It includes compensation for distal radius tilt and can be extrinsic or caused by carpal Ligament disruption. It's evaluated by intersecting lines along the capitate and radius axes On a lateral view.

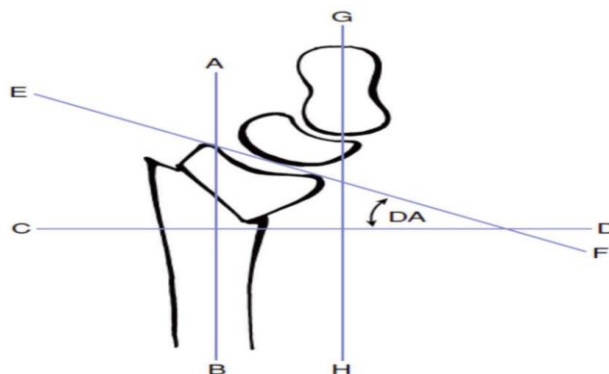


Figure 16 CARPAL MALALIGNMENT

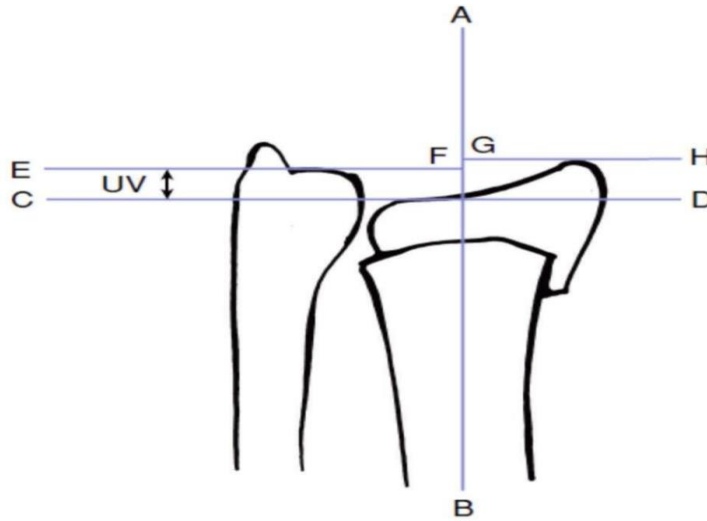


Figure 17 POSITIVE ULNAR VARIANCE

Advanced Techniques:

Computerized Tomography (CT) scans with three dimensional reconstruction offer enhanced visualization and accuracy in Assessing intra-articular fractures, displaying fracture lines and displacement more Precisely than x-rays,improving intraobserver agreement and facilitating surgeon decisions on the type of approach needed for that particular fracture pattern.

However, Their impact on functional outcomes requires further investigation.

THEORY OF MANAGEMENT:

STABILITY ASESSMENT

These variables were identified by LaFontaine et al. as indicators of instability: (1) first dorsal angulation more than 20° ; (2) dorsal metaphyseal fragmentation; (3) involvement of articular surface ; (4) concomitant ulna fracture; and (5) age greater than 60 years

The fundamental AO concepts were:

The original AO principles emphasized anatomic fracture reduction and rigid stability, Alongside preserving blood supply and promoting early limb function. Recognizing that not All fractures allow for perfect reconstruction, modifications include prioritizing axial Realignment over anatomic perfection in long bones, ensuring appropriate stability for Healing, utilizing minimally invasive techniques, and promoting early mobility.

In treating distal radius fractures, the goals include restoring articular congruity, achieving Proper alignment, regaining functional wrist joint movement, and addressing associated Injuries. Developing a tailored treatment plan hinges on variety of factors like bone Quality, patient's demand,age, injury characteristics, and reduction quality.

Radiographic Criteria for Acceptable Reduction of Distal Radial Fracture		
CRITERION	NORMAL	ACCEPTABLE
Ulnar variance (radial length)	±2 mm comparing level of lunate facet to ulnar head	No more than 2 mm of shortening relative to ulnar head
Radial height	12 mm	????
Palmar (lateral) tilt	11 degrees of volar tilt	Neutral
Radial inclination	20 degrees as measured from lunate facet to radial styloid	No less than 10 degrees
Intraarticular step or gap	None	Less than 2 mm of either

Figure 18 : ACCEPTABLE REDUCTION CRITERIA FOR DISTAL RADIUS FRACTURE

TREATMENT OPTIONS

Closed reduction with cast application

K wire percutaneous pinning +/- cast application

External fixator application

Opening up the fracture and reducing it with plate

CONSERVATIVE MANAGEMENT

Conservative treatment is used for non-displaced or mildly displaced fractures, which are usually not associated with carpal malalignment, dorsal tilt $< 10^\circ$, and ulnar variance $< 3\text{mm}$.

This involves immobilization in a below elbow cast or splint with Radiographic assessments at 7 days. If satisfactory, wrist mobilization follows. If there is instability or significant

Articular displacement in Displaced Fracture, early operative intervention is advised. Manual

Manipulative reduction may be attempted under regional anesthesia for fractures with acceptable articular alignment and lower instability risk. Cast immobilization usually lasts four to six weeks, based on x-ray radiograph healing and symptomatology.

Closed reduction and immobilisation: For undisplaced fracture and Colles fracture the fracture can be reduced with help of traction, palmar flexion, ulnar deviation, ligamento-taxis and cast immobilisation, reduction can be confirmed under fluoroscopy. Cast immobilisation for a 4-6 week period then can be started with wrist ROM and radiograph shows healing signs

OPERATIVE INDICATION FOR SURGERY:

Unstable fracture, displaced partial intraarticular fracture, complete intraarticular fracture

K wiring +/- cast application :

Reducing the fracture with help of multiple K wire and if required cast immobilization

External fixation:

Patient under effect of anaesthesia reduce the fracture. Three millimeters half threaded schanz pin on dorsal aspect of hand into second/third metacarpal then 2 three millimeters half-threaded schanz pins by using tissue protectors into dorsum of radius. Apply an external

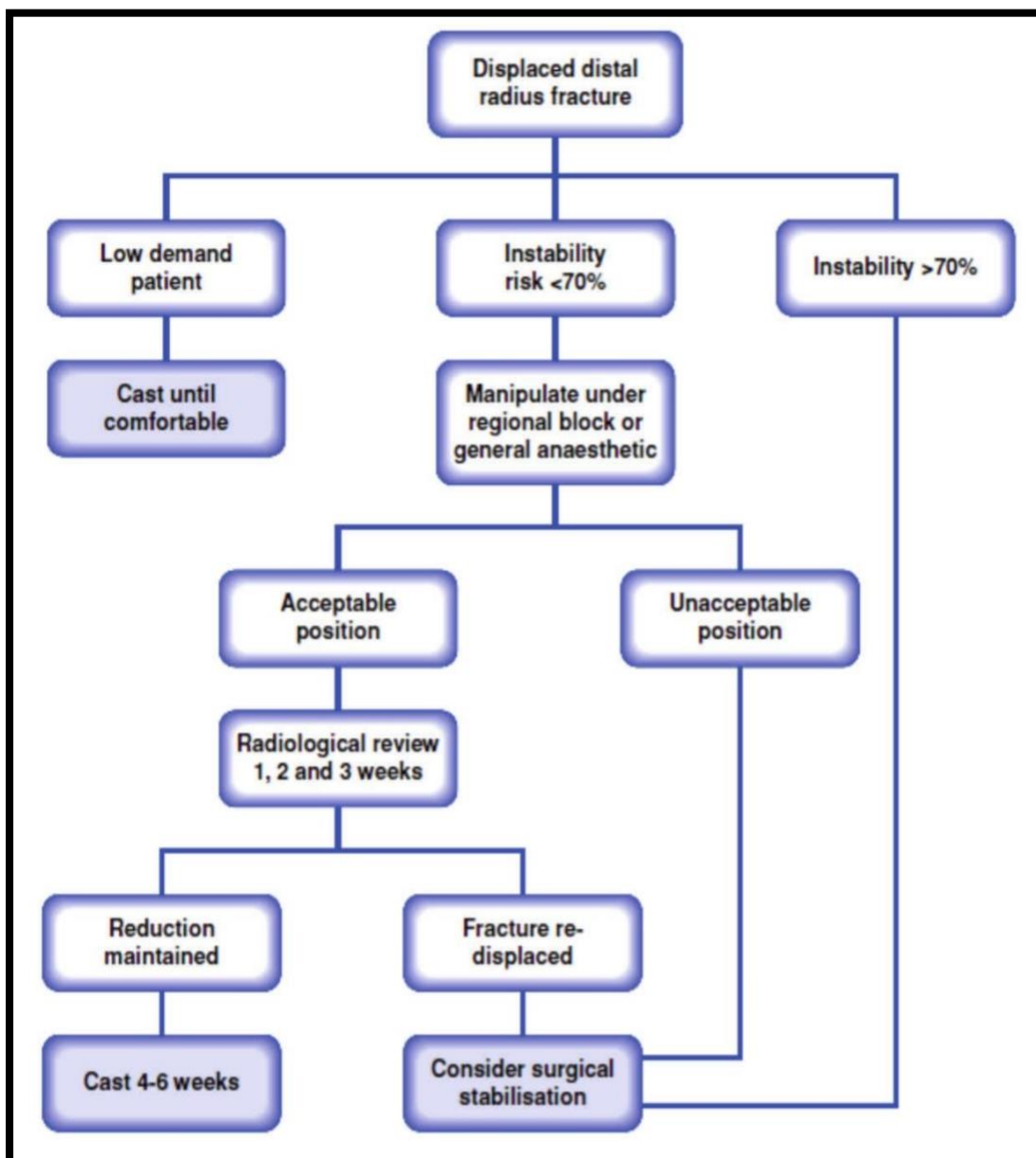


Figure 19 : MANAGEMENT OF DISTAL RADIUS FRACTUR

Fixation frame, potentially reinforced with K-wires, especially beneficial for complex or Compound fractures.

CHARACTERISTIC FEATURE OF VAVLCP:

This plate offers Variable angle distal locking Holes which allow up to 15° of free movement in order for capturing the specific fragment. With fixed LCP there were high chances of intraarticular placement of screws but with variable angle plate with the 15 degree of freedom this problem has been overcome. It prevents the angular collapse at the fracture site. It provides a more stable construct than fixed angle plates.

PLATE:

The variable angle volar locking compression plate has a thin frame comes in 2 profiles 3.5mm plate as well as 2.7mm plate which is available in titanium as well as stainless steel form with a volar tilt of twenty six degrees for maintaining the volar tilt at articular surface for normal function. The distal holes are for 2.7mm/2.4mm locking screws with locking sleeve guide with 15° of freedom, the proximal combi holes are for 3.5mm/2.7mm locking as well as cortical screws. Fixed angle locking screws has a traditional cone shape threaded head whereas the variable angle locking screws have a cupped design for the additional 15° freedom of screw placement and locking to the plate.

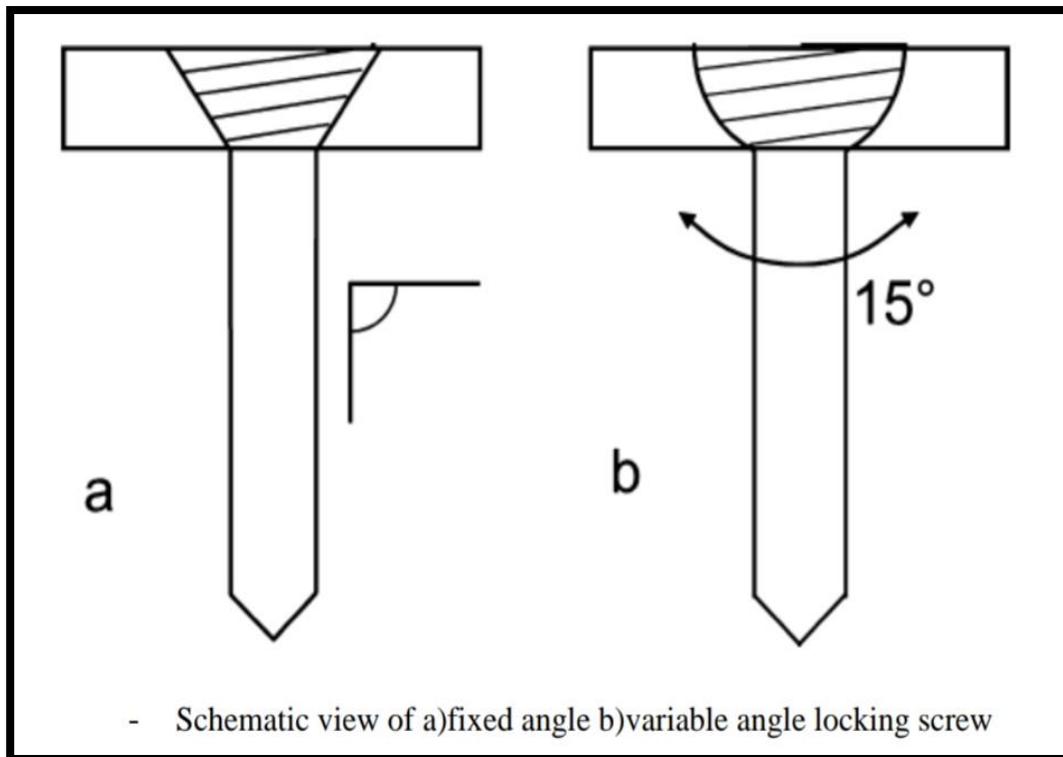




Figure 20 : DEPICTING VARIABLE LOCKING SCREWS CUP SHAPED THREADS



21(A)



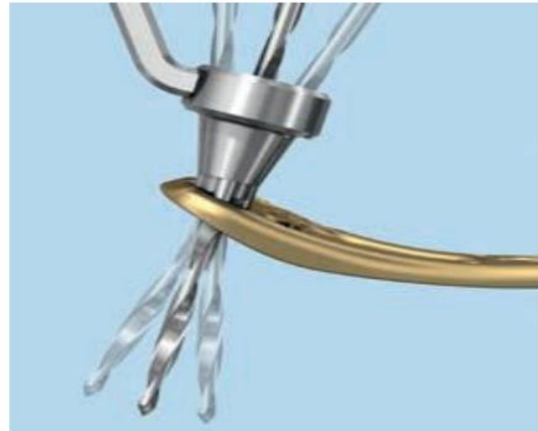
21(B)

21(C)



Figure 21 A,B,C : VAVLCP SET

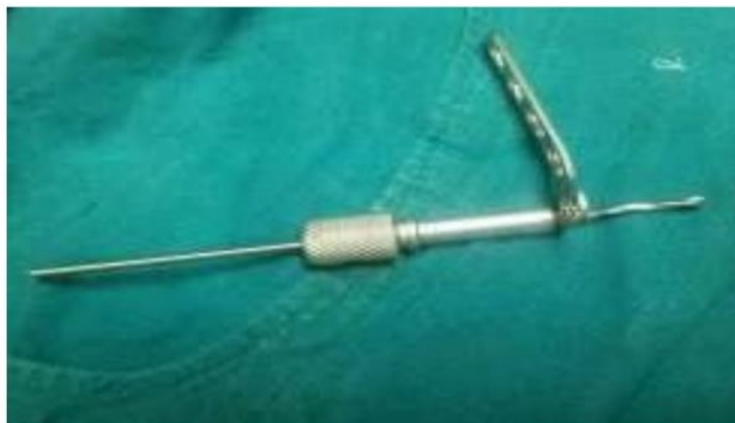Variable angle technique



- To drill variable angle holes up to 15° deviation from the nominal trajectory of the locking hole, the tip of the VA-LCP drill sleeve and key inserted into the cloverleaf design of the VA locking hole.
- Using funnel-shaped end of the VA-LCP drill sleeve variable angle holes are drilled at the desired angle
- Alternatively, we use the freehand VA-LCP drill sleeve and insert it fully into the VA locking hole and Drill variable angle holes at the desired angle²⁶

DRILL BIT:

- A 2mm regular drill bit is used for all the cancellous locking screws²⁵.
- 2.8mm regular drill bit for all the cortical locking and non locking screws



MATERIALS AND METHODS

This study was done in KLE's Dr. Prabhakar kore's hospital ,Belagavi,Between June 15th, 2022, and June 14th, 2023, individuals with complaints of pain and swelling over the wrist after a history of trauma,injuries or fall were evaluated for distal end radius fractures at the emergency or OPD of orthopaedics

Study Period:

Over a period of one year from 15/06/2022 to 14/06/2023

Sample Size:

The sample size was 27

Sampling technique:

The minimum sample size formula based on prevalence rate is

$$n=[z\alpha^2P(1-P)]/d^2$$

where P is the percentage of Distal end radius fracture and d is the percentage likely difference in the prevalence.

$z\alpha$ is linked with the level of significance. For 5% level of the significance $z\alpha =$

1.96.

Ref:

With ^[13] P = 78% and d = 20% of P = 15.6%

Criteria for Inclusion:

- 1) Individuals with extraarticular and intra articular fractures in Distal Radius.
- 2) Individuals with age more than or equal to 18 years who provide consent for participating in our study.

Criteria for Exclusion:

- 1) Pathological fractures excluding osteoporosis.
- 2) Patients who are skeletally immature.
- 3) Individuals with active infections or open fractures.
- 4) Participants with injuries like severe head injury(paresis and plegia) and spinal cord injury which may interfere with our rehab protocol
- 5) Those with associated neurovascular injuries.

Data processing and analysis/statistical analysis:

Since the study is of observational study the plan of analysis will be as follows. For the continuous quantitative variables mean and standard deviation will be calculated. For the purpose of comparison if the data is divided into two groups with respect to certain qualitative characteristic, the continuous variables will be compared using suitable tools of statistics like student's unpaired t test. The pre and post treatment measures will be compared using student's paired t test. Discrete variables will be represented by median. The categorical data will be expressed in terms of rates, ratios and percentages. The association between the outcome, clinical and demographic characteristics will be tested using Chi-square test, test of proportion or Fisher's exact test. For discrete variables nonparametric tests will be used. Apart from the above suitable

tools like ANOVA, correlation, regression etc., will be used according to the need. Suitable graphs will be used to depict the comparison. For all the tests the value of p less than 5% (0.05) will be considered significant.

INSTRUMENTS AND IMPLANTS USED:

- 3.5mm/2.7mm Variable angle volar LCP set
- 2.7mm/2 mm drill bit,guide sleeve and k wire set
- AO drill.
- Cortical Tap and depth gauge for 3.5mm/2.7mm cortical screws
- Screw driver for 3.5mm/2.7mm/2.4mm locking screws and 3.5mm/2.7mm cortical screws.
- Scalpel,blade,retractor, periosteum elevator,bone spikes,clamp,cautery, suction etc
- Arm tourniquet with different size cuffs.

OPERATIVE PROCEDURE:

A straight incision radial to flexor carpi radialis between FCR and Radial artery with forearm kept in supination . Protect radial nerve's sensory branch beneath Muscle Brachioradialis.Incise sheath over tendon of flexor carpi radialis, retract tendon along with radial artery and vein,deeper to that muscles Flexor pollicis Longus and Pronator quadratus are exposed.Retract FPL and incise pronator quadratus in reverse L shape if not already torn Elevate it subperiosteally from the anterolateral radius,visualize fracture.Utilize manipulation,ligamento-taxis to Reduce the fracture, possibly using provisional K-wires for stabilization. Place the plate of choice and fix the fracture and confirm the reduction through fluoroscopy to mitigate complications. Suture the pronator quadratus over the plate's distal end to prevent tendon irritation.followed by skin closure, followed by below elbow slab immobilisation for 4 weeks after operation.

POST OPERATIVE PROTOCOL

Following surgery, we collected data on the time it took for patients to regain full wrist Mobility and monitored for post-operative complications, including symptoms of median Nerve compression, improper bone healing, fixation failure, infections, compartment syndrome and complex regional pain syndrome (CRPS). All individuals began gentle wrist exercises approximately four weeks after surgery. All individuals were asked to follow up and functional outcome was assessed using the Modified Mayo Wrist Score (MMWS) at six, twelve weeks, six months, twelve months post operative period.

MMWS is scoring system for the patients

Out of 100 points

Twenty five for pain severity

Twenty five for work status

Twenty five for range of motion

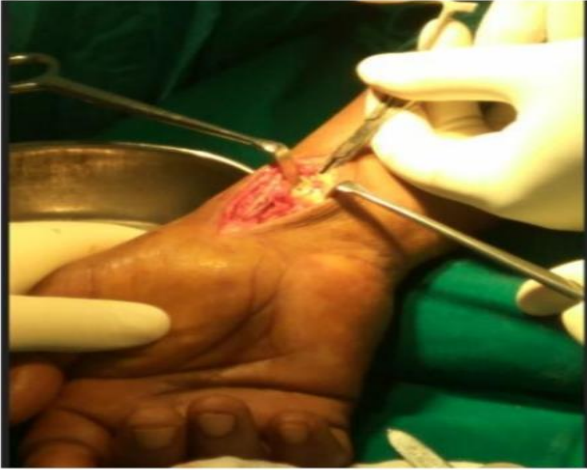Twenty five for grip strength calculated as percentage of normal

MODIFIED MAYO WRIST SCORE

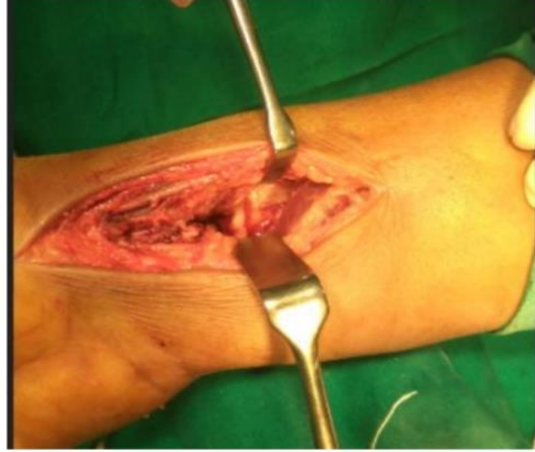Category	Findings	Score
Pain (25 points)	No pain	25
	Mild occasional	20
	Moderate	15
	Severe	0
Work status (25 points)	Regular job	25
	Restricted job	20
	Able to work but unemployed	15
	Unable to work due to pain	0
Range of motion (25 points)	>120°	25
	100° to 119°	20
	90° to 99°	15
	60° to 89°	10
	30° to 59°	5
	0° to 29°	0
Grip strength (% of normal) (25 points)	90 to 100	25
	75 to 89	15
	50 to 74	10
	25 to 49	5
	0 to 24	0

Final result (total points)	Excellent	90-100
	Good	80-89
	Fair	65-79
	Poor	<65

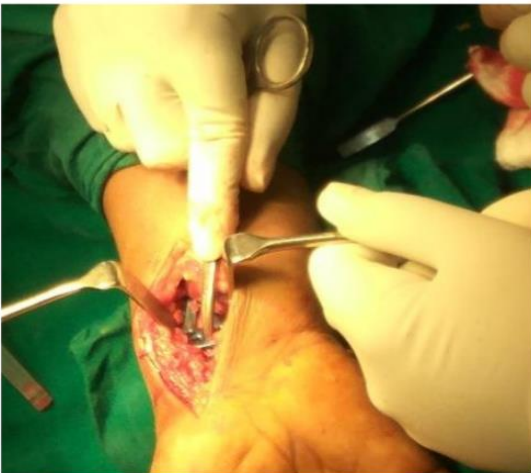GALLERY



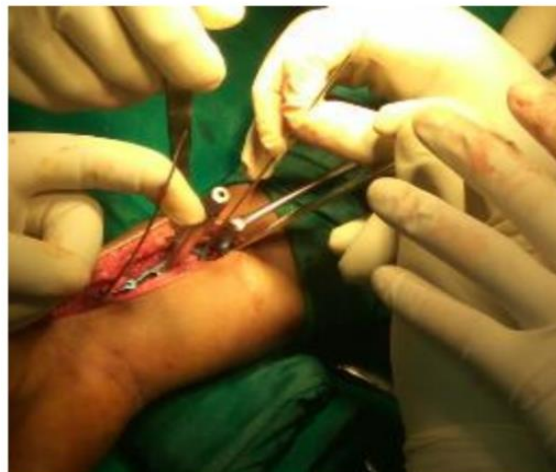SKIN INCISION



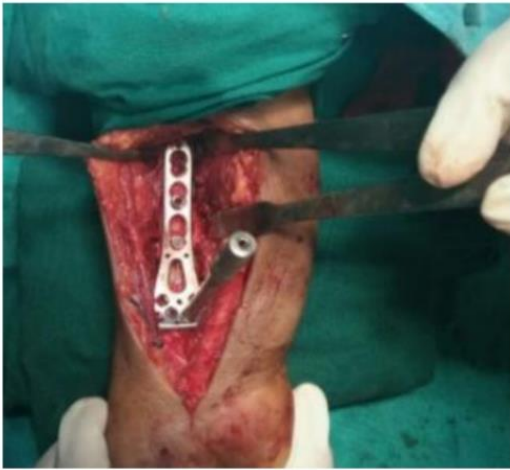EXPOSING FRACTURE SITE



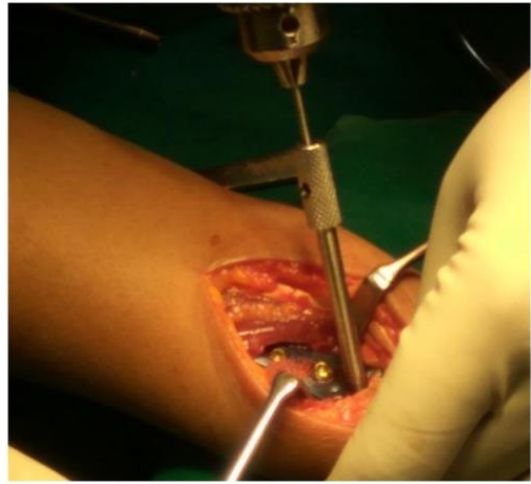
FRACTURE REDUCTION
AND PLATE PLACEMENT



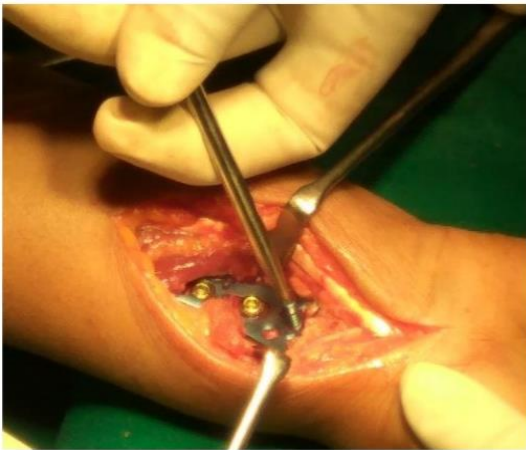HOLDING REDUCTION WITH
PLATE AND K WIRE



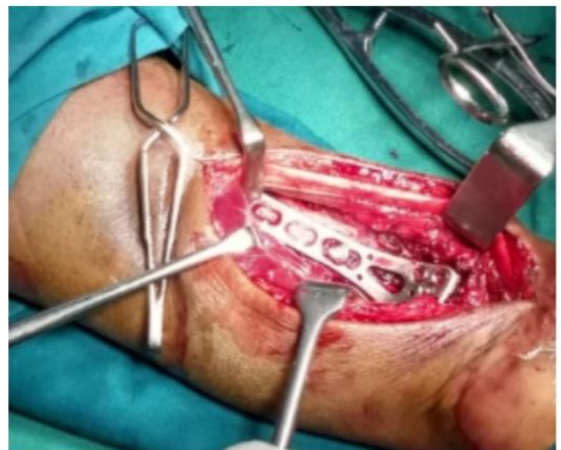PROXIMAL SCREW FIXATION



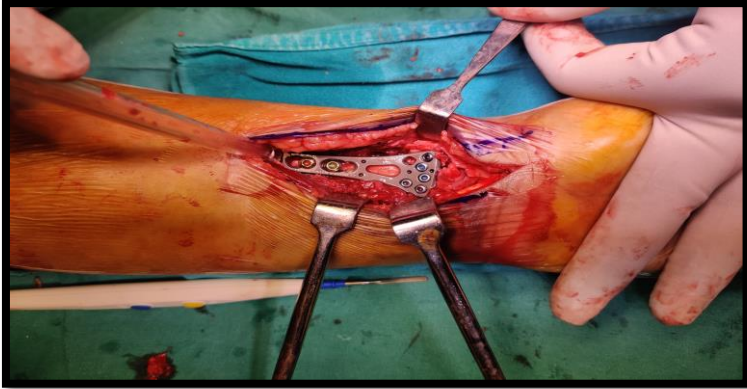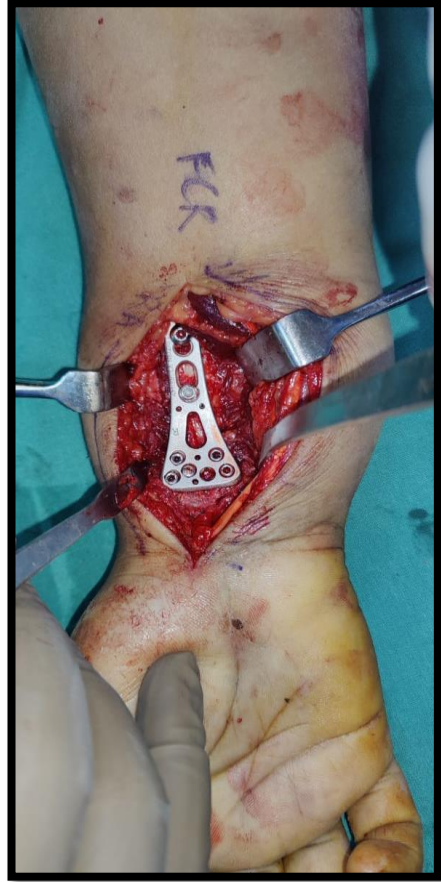
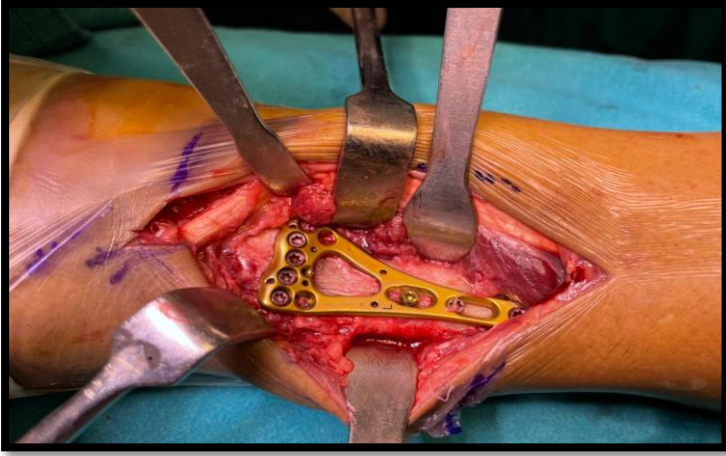
DISTAL LOCKING DRILL BIT
WITH SLEEVE



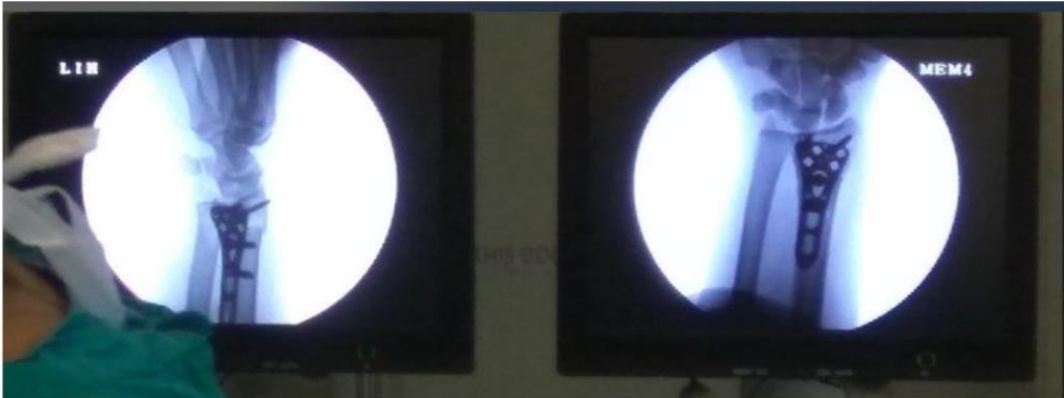DISTAL LOCKING SCREW
INSERTION



FINAL REDUCTION WITH
PLATE FIXATION



BROAD AND NARROW VAVLCP PLATES



INTRA OPERATIVE C-ARM IMAGES

Figure 22 : DEPICTING INTRA OPERATIVE IMAGES OF SURGERY

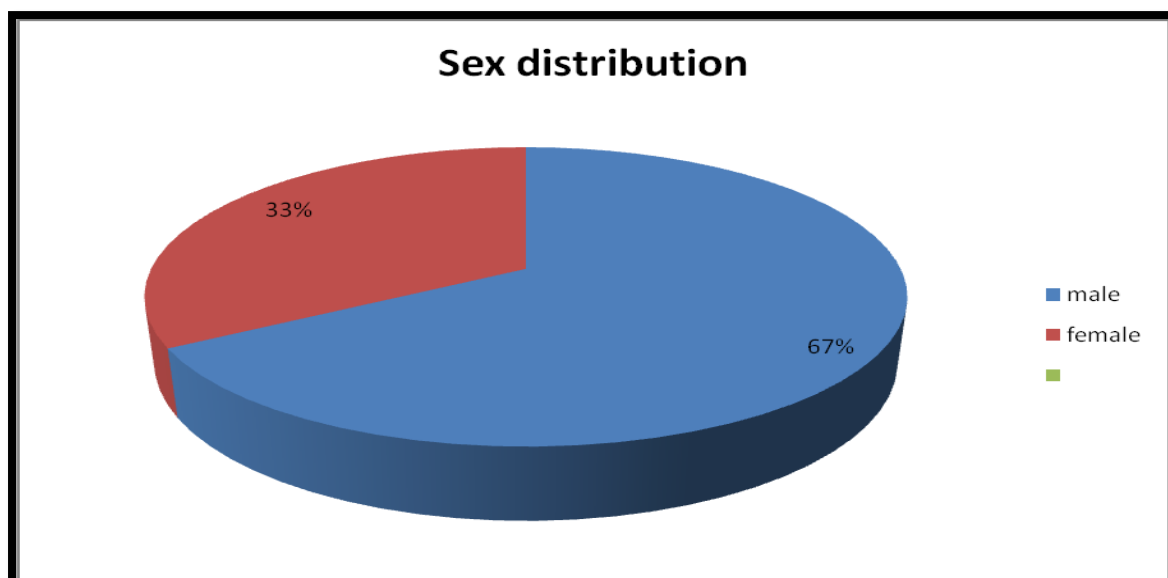
RESULTS

Our research involved treating twenty seven subjects . We diligently tracked each case's Progress. The average age of participants is 48 yrs. After thorough assessment of our cases we compared it with other studies.

Sex ratio of our study: Out of the total participants, 18 were male (63.3%), while 9 were female (36.6%), indicating A higher proportion of male participants in our study

Table 1: sex ratio of our study

Gender	Number of patients	Proportion
Males	18	67%
Females	9	33%

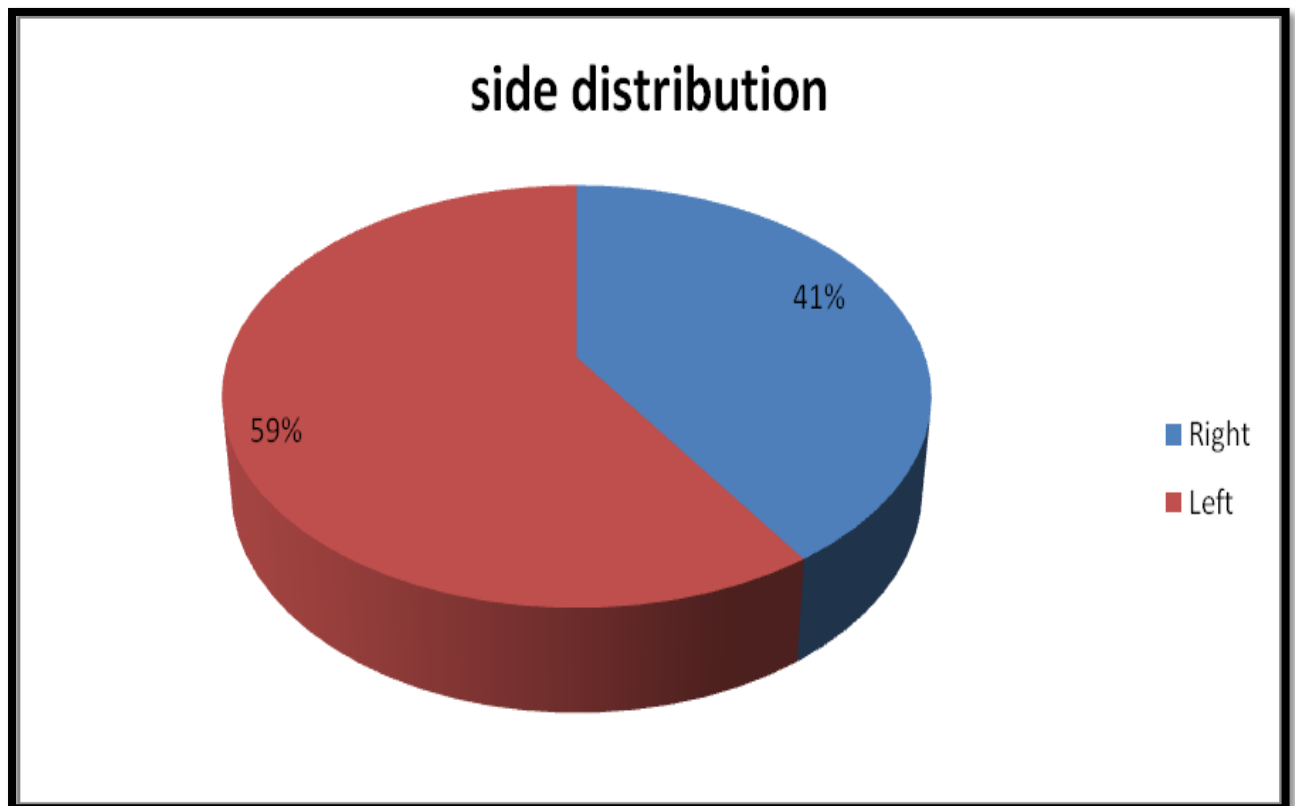


Affected side :

Out of the cases examined in our research, 11 cases right side and 16 cases left Side.

Table 2: Affected side distribution

Affected Side	cases	%
Right	11	41%
Left	16	59%

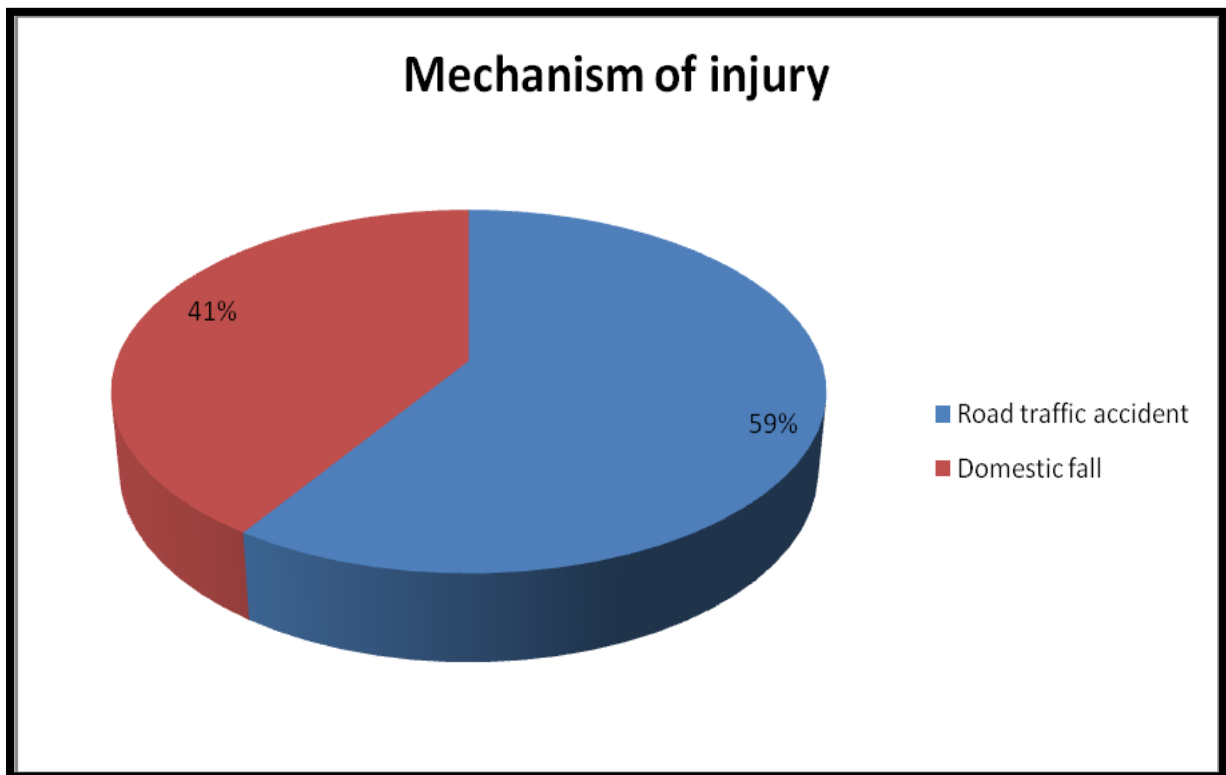


Mechanism of injury :

Among the cases examined, 16 (59%) patients sustained injuries from road traffic Accidents, while 11 (41%) experienced falls at home.

Table 3 : Mechanism of injury

Mechanism	Number of case	Proportion
Road accidents	16	59%
Domestic fall	11	41%



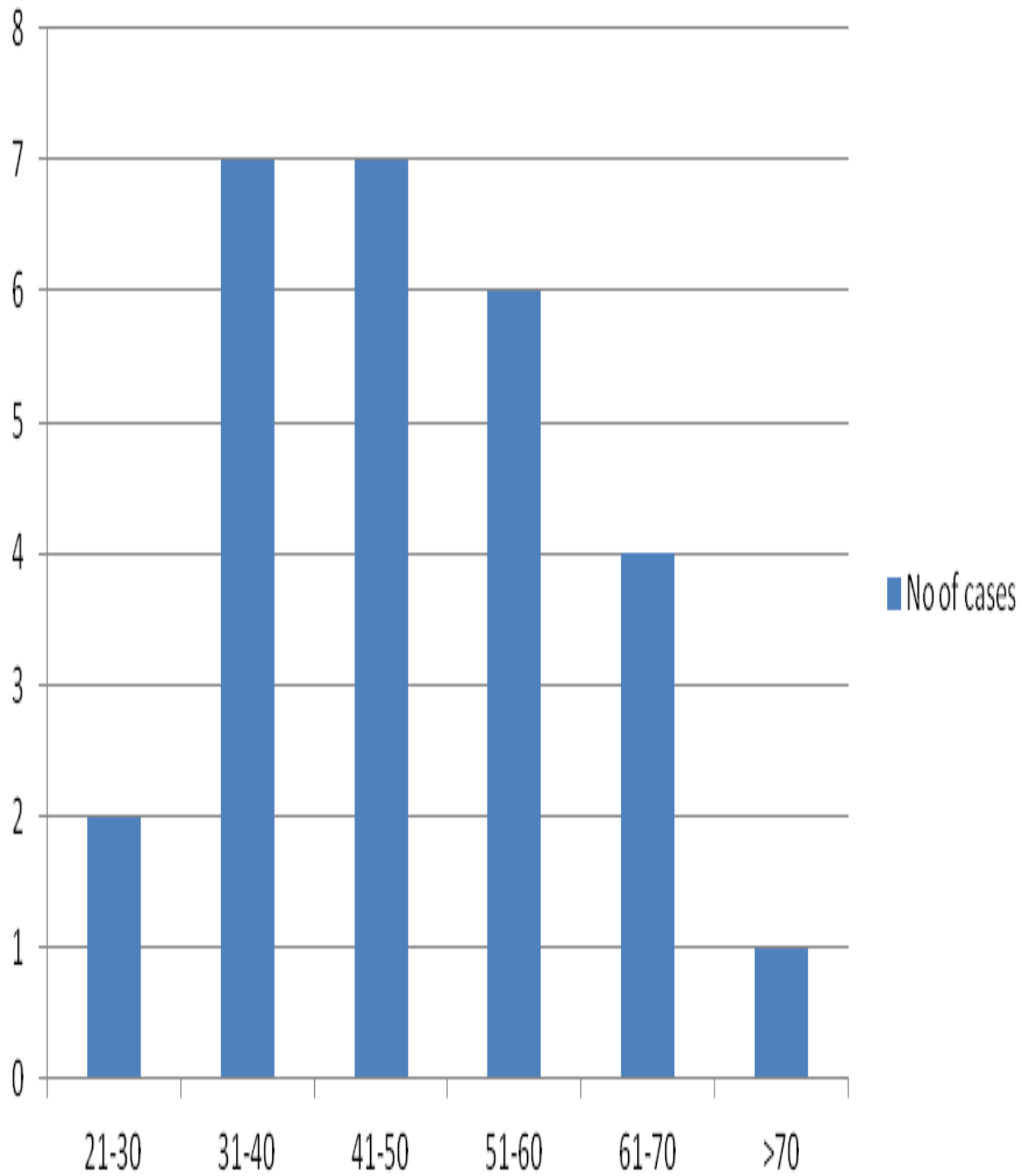
Age Distribution:

Table 4: Age distribution

Age-range	Number of patients	Proportion
21 to 30	2	7%
31 to 40	7	26%
41 to50	7	26%
51 to 60	6	22%
61 to70	4	15%
>70	1	4%

Patients average age was 48 yrs.

AGE DISTRIBUTION



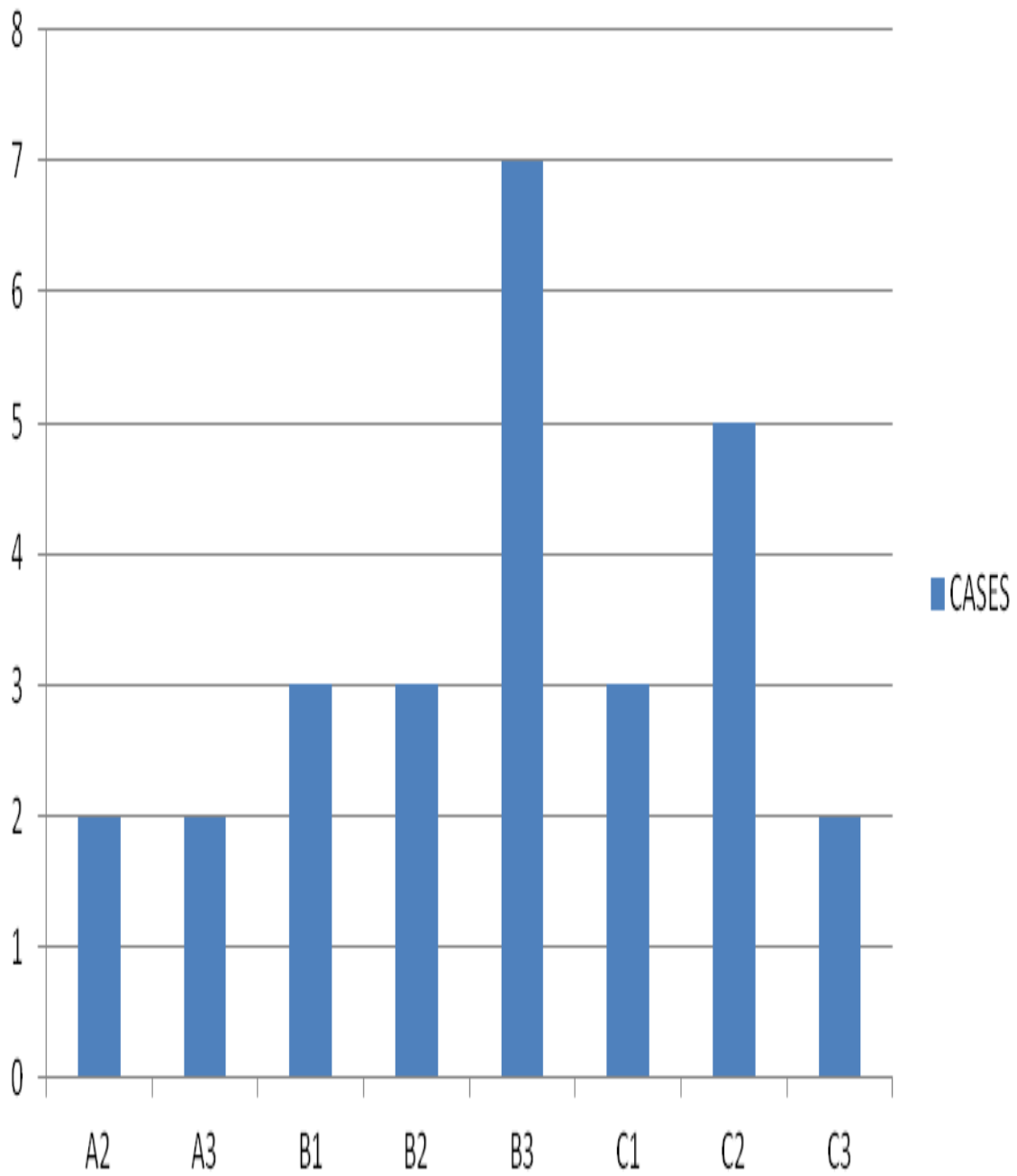
Fracture type

Table 5 : AO CLASSIFICATION

AO Classification type	Number of patients
A ₂	2
A ₃	2
B ₁	3
B ₂	3
B ₃	7
C ₁	3
C ₂	5
C ₃	2

The Majority of cases were of B3 followed by C2 Type.

TYPE OF FRACTURE

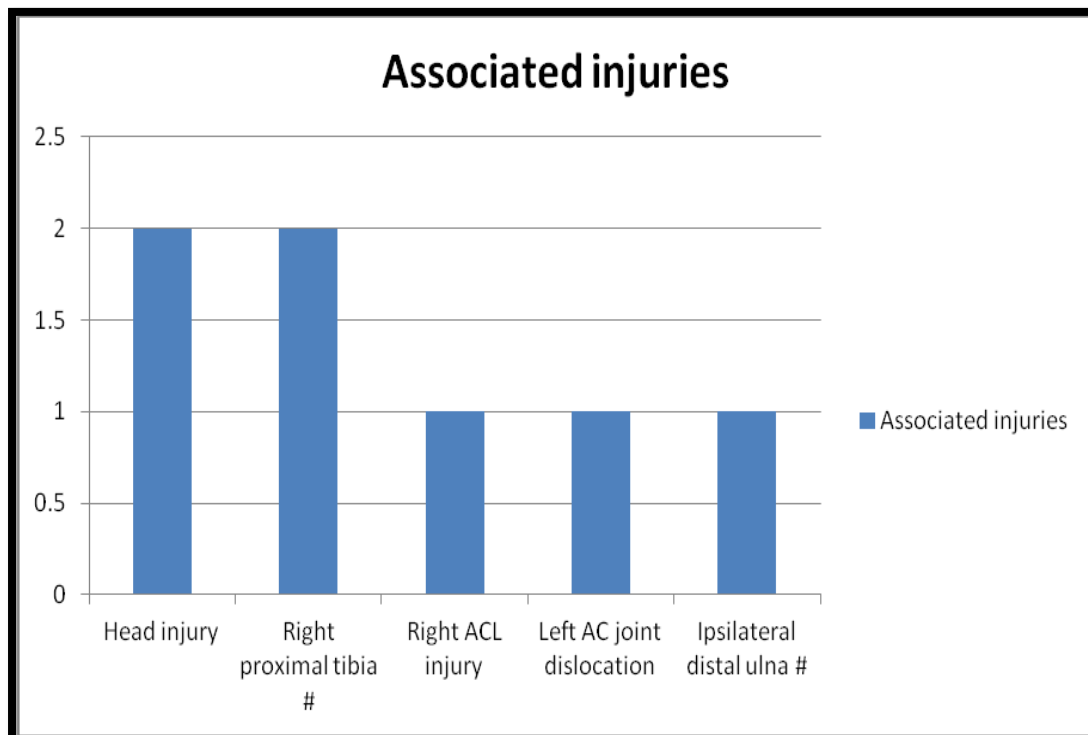


Other associated injuries:

Table 6 : Other associated injuries

Other associated injury	Number of patients	Proportion
Head injury	2	7.41%
Right proximal tibia #	2	7.41%
Right ACL injury	1	3.70%
Left AC Joint dislocation	1	3.70%
Ipsilateral distal ulna #	1	3.70%

Out of 27 cases 7(25.9%) cases had associated injuries



Functional Outcome:

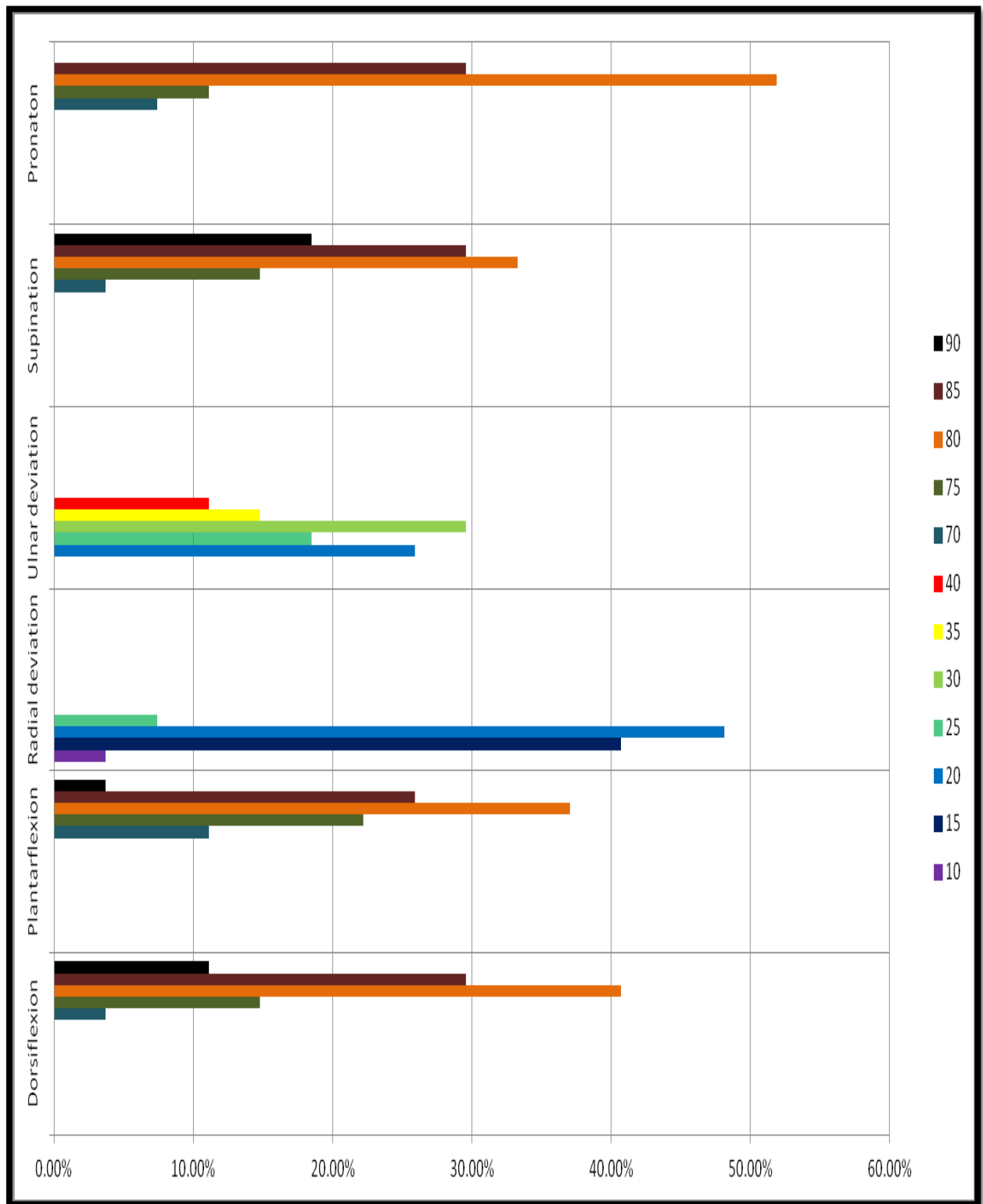
Table 7 : Functional outcome of our study

	Degrees	count	%
Dorsiflexion	70	1	3.7%
	75	4	14.8%
	80	11	40.7%
	85	8	29.6%
	90	3	11.1%
Plantarflexion	70	3	11.1%
	75	6	22.2%
	80	10	37.04%
	85	7	25.9%
	90	1	3.7%
Radial deviation	10	1	3.7%
	15	11	40.7%
	20	13	48.14%
	25	2	7.4%

Ulnar deviation	20	7	25.9%
	25	5	18.5%
	30	8	29.6%
	35	4	14.8%
	40	3	11.1%
	70	1	3.7%
Supination	75	4	14.8%
	80	9	33.3%
	85	8	29.6%
	90	5	18.5%
	70	2	7.4%
Pronation	75	3	11.1%
	80	14	51.9%
	85	8	29.6%

In our study 81.4% of patients had dorsiflexion of more than and equal to 80 degrees,66.64% of patients had plantar flexion of more than and equal to 80degrees,96.2% of patients had radial deviation of more than and equal to 15 degrees,55.5% of patients had ulnar deviation

of more than and equal to 30 degrees,81.4% of patients had supination of more than and equal to 80 degrees,81.5% of patients had pronation of more than and equal to 80 degrees



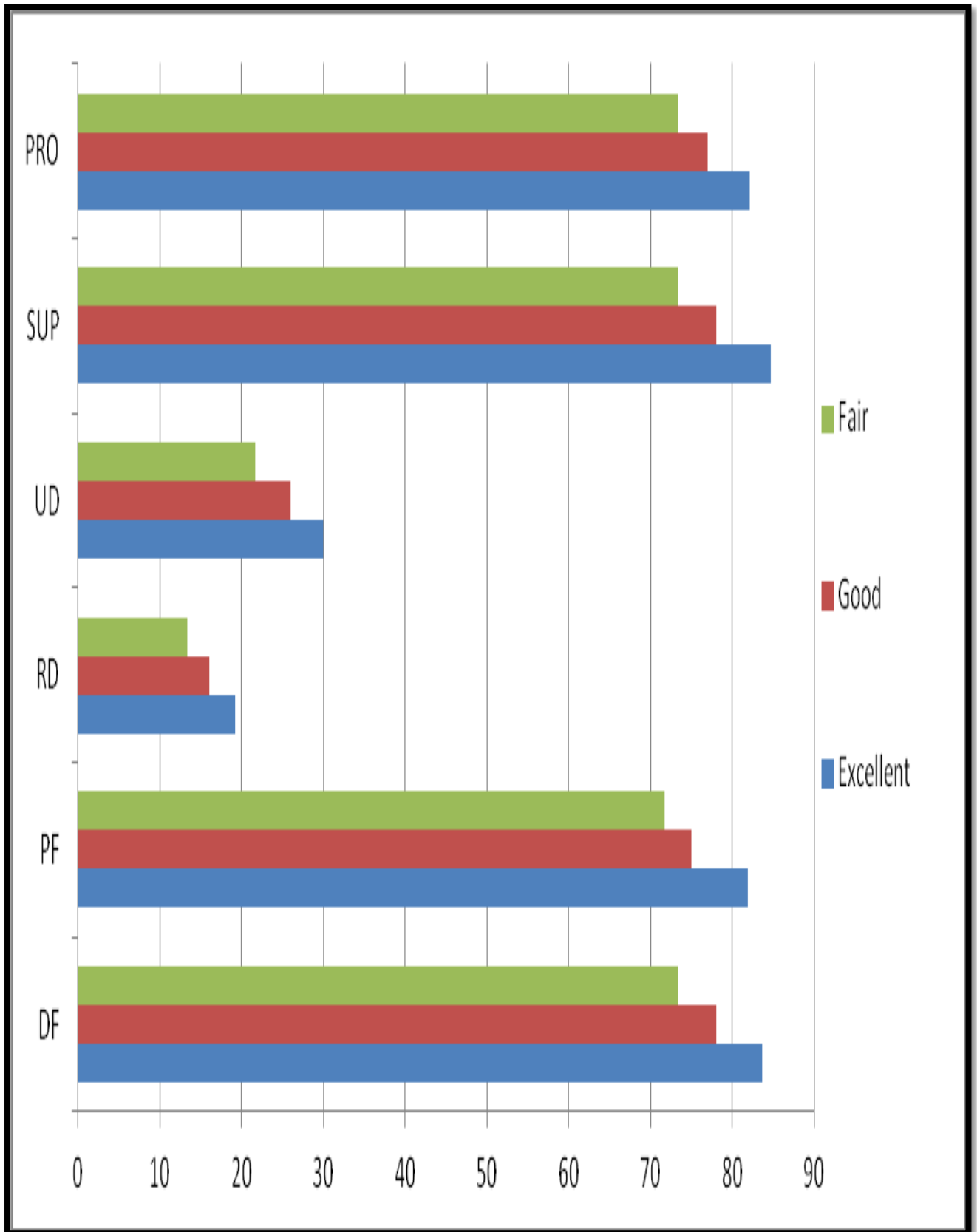
Graph depicting Functional outcome of our study

RESULTS VS OUTCOME :

Table 8 : Results vs outcome

Outcome	Results						P Value
	Excellent		Good		Fair		
	Mean	SD	Mean	SD	Mean	SD	
Dorsiflexion	83.68	3.67	78	2.74	73.33	2.89	<0.0001*
Plantarflexion	81.84	3.80	75	3.54	71.67	2.89	<0.0001*
Radial deviation	19.21	3.01	16	2.23	13.33	2.89	0.0052*
Ulnar deviation	30	6.87	26	4.18	21.67	2.89	<0.0001*
Supination	84.74	3.9	78	2.74	73.33	2.89	<0.0001*
Pronation	82.1	2.54	77	2.74	73.33	5.77	<0.0001*

*The functional outcome with respect to results the P Value is (<0.05) is significant for all the outcomes.



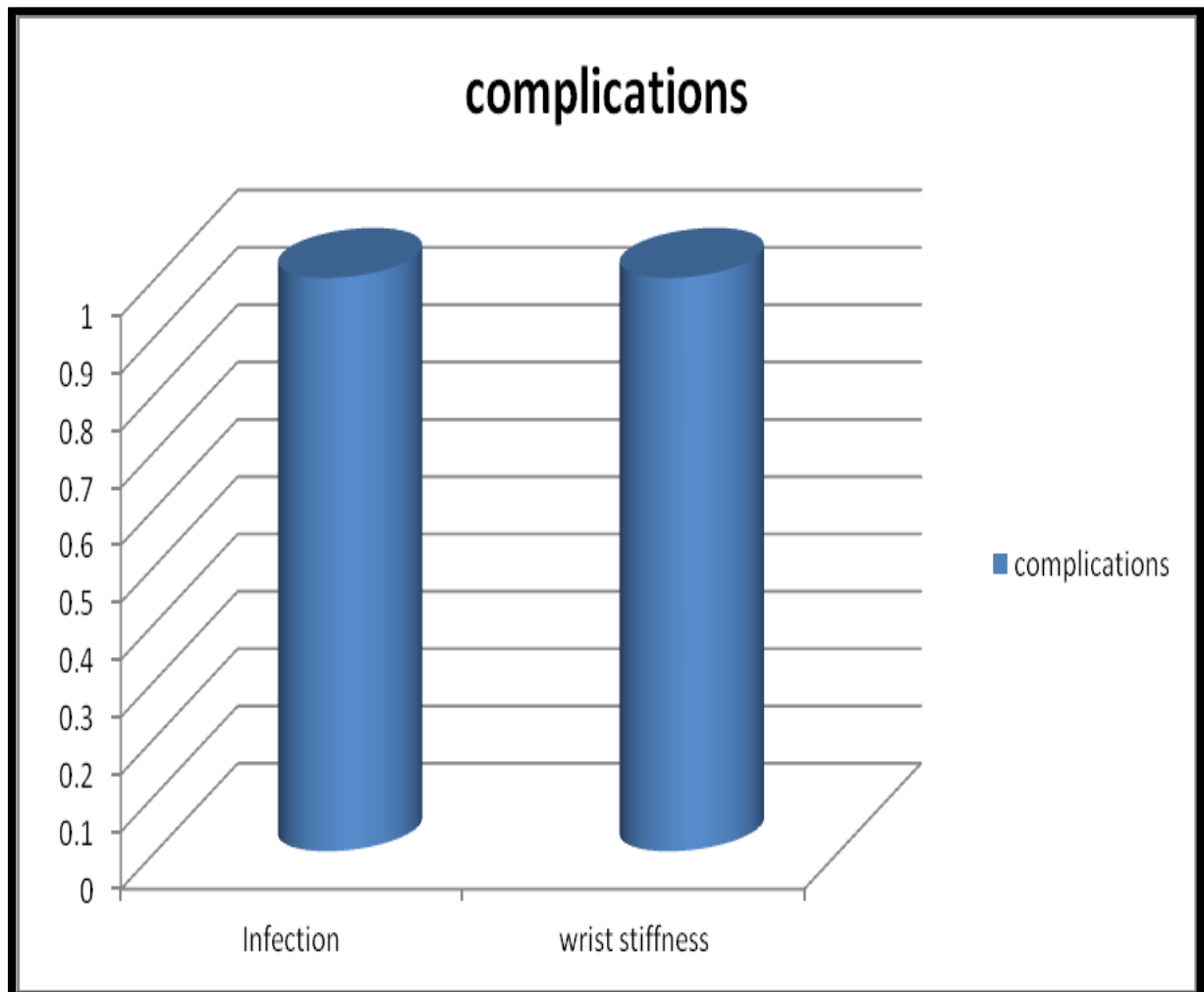
Graph depicting results vs outcome of our study

Adverse events in our study:

Table 9: Adverse Events

Adverse events	cases	%
Infection	1	3.7%
Wrist stiffness	1	3.7%

Out of 27 only 2 patients (7.4%) had complications which improved with treatment and physiotherapy

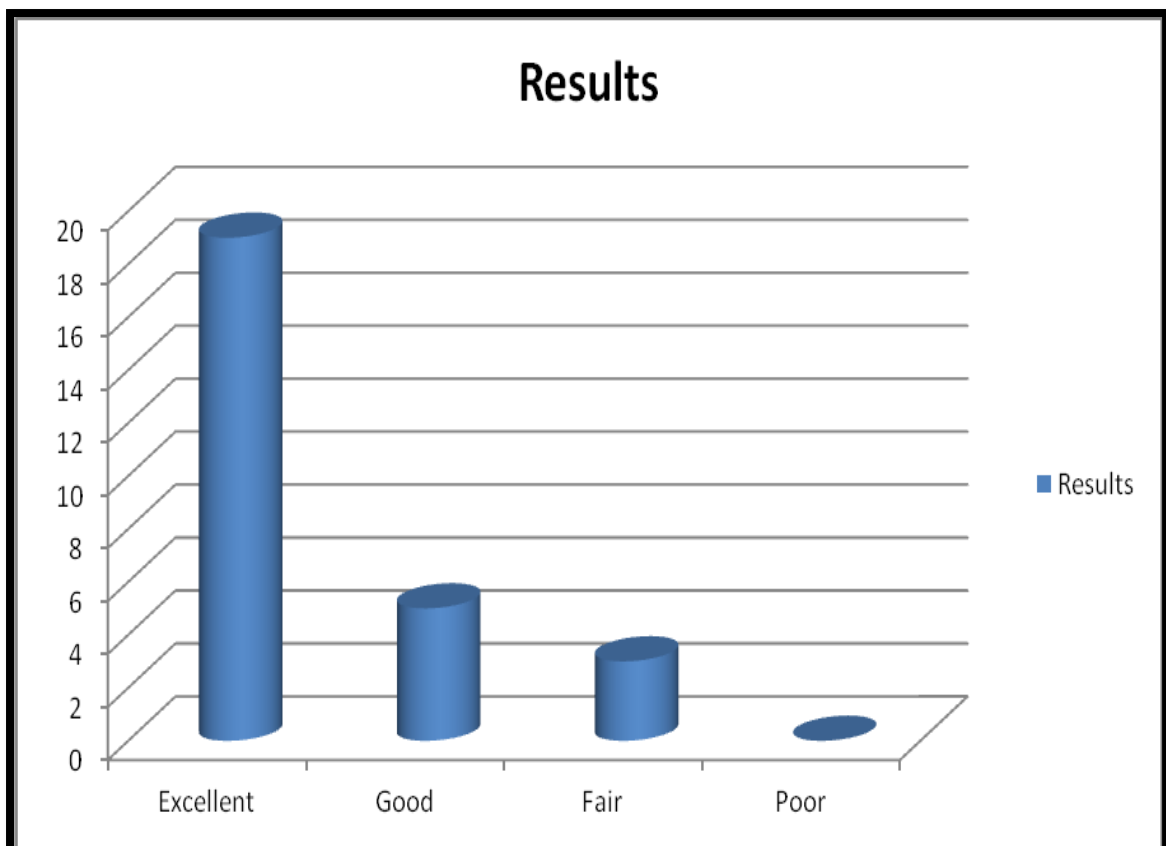

Evaluation of Results

Table 10 : Evaluation of Results

Outcome	cases	%
Excellent	19	70.37%
Good	5	18.52%
Fair	3	11.11%
Poor	0	0

Out of 27 cases, 19 cases(70.37%) had excellent results,5 cases(18.52%) had good results,3 cases(11.11%) had fair results.



DISCUSSION

Recent advancements in managing distal radial fractures have been shaped by an Enhanced understanding of radial anatomy, patient preferences, and innovative fixation Methods.

Locking plates are now preferred, especially in cases of osteoporosis or complex Fractures. The volar approach has gained popularity in recent times.

The Variable-angle volar locking compression plate (VAVLCPs) marks significant leap forward in the treatment of bad comminuted fractures. These plates offer increased Versatility in screw placement, enabling surgeons to precisely position subchondral screws For better fracture fragment stabilization.

Our study results have been compared with Various other research findings across different parameters such as the affected side, Injury mechanism, and fracture types.

1) Involved side:

Out of our research cohort, 11 cases featured injuries to the dominant wrist (right side), While 16 cases involved the non-dominant (left) side

2)Mechanism of injury:

In our investigation, 16 cases (59.25%) resulted from road traffic accidents, while 11 cases (40.74%) stemmed from domestic falls.

3) Type of fracture:

In our study,AO classification system was used. We observed that A2 and A3 fractures accounted for 7.4% each, B1 and B2 fractures each Represented 11.11%, B3 fractures constituted 25.93%, C1 fractures made up 11.11%, C2 Fractures were 18.52%, and C3 fractures accounted for 7.4%. Comparing our findings with Other studies, Anakwe et al.

(2010) reported different distributions: 4 C1 cases, 8 C2 cases, 9 C3 cases. Studies done by Sanjay A shows 1 A1 case, 5 A2 cases, 7 A3 cases, 7 B2 cases, 3 B3 cases, 1 C2 case and 1 C3 case. Studies by Kavin showed 4 A3 cases, 9 C2 cases, and 10 C3 cases. Studies by William JM showed 15 A3 cases, 5 B3 cases, and 45 C3 cases. We found that the most of our fracture fall into the B3 and C2 categories.

4) Adverse events

In our research, we encountered two complications (7.4%). One patient developed an Infection at the surgical site, while another experienced wrist stiffness due to noncompliance with our physiotherapy protocol. In comparison, studies by Anakwe showed 4.8% complications, studies by Sanjay A showed a 4% complications, studies by Kavin showed 21.7% complications, and studies by William JM showed 7.69% complications.

5) Results :

In research study done by us outcomes varied, with 70.37% of cases categorised as excellent, 18.52% Categorized as good, and 11.11% as fair, with no instances of poor results. Patients with Excellent outcomes resumed normal activities without pain and maintained normal movements often starting physiotherapy earlier.

Those with good outcomes experienced no pain and near normal movements .Those with fair outcomes included residual issues like mild deformity with pain along with limitation of movements .

In comparison with other studies, Anakwe et al. (2010) utilized clinical examinations, measuring grip Strength of the affected wrist along with radiographs,patient rated wrist evaluation scoring, reporting 95% results. Studies by Sanjay A Employed the MMWS, revealing 100% achieving excellent results after one year. Studies by William JM et al. Achieving 100% excellent results.

Our research investigation results mirror those of Kavin et al. (2015), reporting 65% excellent and 35% good, Offering a similar perspective on treatment efficacy

CONCLUSION

In conclusion, domestic fall onto outstretched hands commonly result in distal radius fractures, With those from road traffic accidents often being displaced and intra-articular, primarily Falling under AO B2,AO B3, AO C1,AO C2, and AO C3 classification. Our findings support the Efficacy of variable angle Volar locking compression plate for treatment of intra-articular unstable fracture in distal radius .These plates facilitate precise anatomical realignment and early wrist Mobilization, offering biomechanical superiority by preventing angular collapse and good subchondral screw plate hold with 15° freedom of screw placement in various columns of fracture. Anatomic reduction was achieved in most cases irrespective of fracture displacement allowing most of patients to return to normal activities. Moreover, these plates contribute to quicker recovery of joint motions and daily Functioning.

OVERVIEW

- Our Research study presents a total of 27 patients who were diagnosed to have Distal radius fracture treated with Variable angle Volar locking compression plate in Dr. Prabhakar Kore's KLE Hospital and MRC in Belagavi.
- Higher proportion of males compared to females.
- Majority patients were in 3rd and 4th decade of life, accounting for 26% of the total.
- The predominant cause of injury was road traffic accidents.
- Two patients sustained head injuries, two had proximal tibia fractures, one had a right ACL injury, one had a left AC joint dislocation, and one had an associated distal ulna Fracture. In total, 7 patients (25.9%) presented with associated injuries.
- The VAVLCP is preferred treatment approach in management of fracture in distal radius, particularly for AO B3, C1, and C2 fractures.
- However, in severely comminuted Type C3 fractures with osteoporosis, VALCP Proved less effective due to inadequate bone purchase for the screws.
- Despite lower MMWS scores in Type C3 fractures, the VALCP remains the preferred implant For Type C fractures among the available options.

BIBLIOGRAPHY

1. Weber ER: A rationale approach for the recognition and the treatment of colle's fracture
Hand Clin 1987;3:3 – 21.
2. Cooney WP III, Dobyns JH, Linscheid RL. Complications of colles' fractures. J Bone Joint Surg 1980; 62-A: 613.
3. Bagby GW. Compression bone-plating:historical considerations. J Bone Joint surg Am.1977;59:625-631.
4. Knirk JL, Jupiter JB. Intra-articular fractures of the distal end of the radius in young adults.
Journal of bone and joint surgery 1986;
5. Rikli DA, Regazzoni P. Fractures of the distal end of the radius treated by internal fixation and early function. A preliminary report of 20 cases. J Bone Joint
6. Helfet DL, Haas NP, Schatzker J, et al. AO philosophy and principles of fracture management-its evolution and evaluation. J Bone Joint surg Am. 2003;85:1156-1160.
7. Egol KA, Kubiak EN, Fulkerson E, et al. Biomechanics of locked plates and screws.J Orthop Trauma. 2004;:488–93.
8. Haidukewych GJ. Innovations in locking plate technology.J Am AcadOrthop Surg. 2004;12:205–212.
9. Chan KW, Kwork TK , Mak KH. Early experience with locking compression plate in the treatment of distal radius fracture Hong Kong J Orthop.surg. 2003;7;88-93.

-
10. mark lenz, dieter wahl et al.,concept of variable angle locking-evolution and mechanical evaluation of a recent technology journal of Orthopaedic Research Society. 2015;988-992.
 11. Park JH, Hagopian J, Ilyas AM. Variable-angle locking screw volar plating of distal radius fractures. *Hand Clin.* 2010;26:373–380, vi.
 12. Arun Pal Singh. Anatomy of Distal Radius. *Bone and Spine journal* 2014
 13. Benjamin Z philips, MD, MPH; chief editor: thomas R Gest . wrist joint anatomy.medscape.com/article/1899456-overview
 14. Dr.Tim Luijckx and A.Prof Frank Gaillard et al.Frykman classification of distal radial fractures.
 15. Melone C P Jr Articular fracture of distal radius. *ortho clin north Am.*1984;15;217-36
 16. Boyer MI, Korcek KJ, Gelberman RH, Gilula LA, Ditsios K, Evanoff BA.. Anatomic tilt x-rays of the distal radius: an ex vivo analysis of surgical fixation.. *Journal of hand surgery* 2004
 17. Altissimi M, Antenucci R, Fiacca C, Mancini GB.. Long-term results of conservative treatment of fractures of the distal radius.*Clinical orthopaedics and related research* 1986;
 18. Jakiml JB,Pieterse HS,Sweet MB, External fixaion for intraarticular fractures of the distal radius. *J Bone Joint Surg.* 1991; 73-B (2):302-306.
 19. J. Arora, A. C. Malik. External fixation in comminuted, displaced intra-articular fractures of the distal radius: is it sufficient?. *Archives of Orthopaedic and Trauma Surgery* 2005; 125(8):

-
20. Leung F, Zhu L, Ho H, Lu WW, Chow SP. Palmar plate fixation of AO type C2 fracture of distal radius using a locking compression plate: a biomechanical study in a cadaveric model. *J Hand Surg.* 2003;28B:263–6.
21. Schütz M, Kolbeck S, Spranger A, Arndt-Kolbeck M, Haas NP. Palmar plating with the locking compression plate for dorsally displaced fractures of the distal radius--first clinical experiences *Zentralbl Chir.* 2003 Dec;128(12):997-1002.
22. Wong KK, Chan KW, Kwok TK, Mak KH, Volar fixation of dorsally displaced distal radial fracture using locking compression plate. *J Orthop Surg (Hong Kong).* 2005 Aug;13(2):153-7
23. Musgrave DS, Idler RS., Volar fixation of dorsally displaced distal radius fractures using the 2.4-mm locking compression plates. *J Hand Surg Am.* 2005 Jul;30(4):743-9.
24. Cognet JM, Geanah A, Marsal C, Kadoch V, Gouzou S, Simon P. Plate fixation with locking screw for distal fractures of the radius ,*Rev Chir Orthop Reparatrice Appar Mot.* 2006 Nov;92(7):663-72.
25. Wagner M. General principles for the clinical use of the LCP. *Injury.* 2003; 34(suppl 2):B31-42.
26. John R. Fowler.MD , Asif M. Ilyas, MD. Prospective evaluation of distal radius fractures treated with variable-angle volar locking plates *jhsa.*2013.08.116.
27. Scott M .Levin, Cory O.Nelson, Jonathan D.Glenn A. Teplitz,Yong Kwon, and Fred Serra-Hsu Biomechanical Evaluation of Volar Locking Plates for Distal Radius Fractures *J Orthop Surg* Received April 2, 2007; Accepted June 20, 2007.

-
28. Hebert-Davies J, Laflamme GY, Rouleau D, et al. A biomechanical study comparing polyaxial locking screw mechanisms. *Injury*. 2013; 1358–1362.
 29. Louay Al-Mouazzen, Daud Tai Shan Chou, et al polyaxial versus Uniaxial volar locking plate for distal radial fractures. *Journal of orthopaedic surgery* 2014;22(1):9-12.
 30. rockwood and green's fractures in adults eighth edition vol-1, chapter32, page no-1089.
 31. Köck H, Bandl WD, Chan T.,Experiences and results with the locked compression plate for 603 fractures of the distal radius. *Handchir Mikrochir plast chir*. 2005 oct;37(5):303-8.
 32. Arora R, Lutz M, Hennerbichler A, Krappinger D, Espen D, Gabl M. Complications following internal fixation of unstable distal radius fracture with a palmar locking-plate. *J Orthop trauma*.2007 May;21(5):316-22
 33. Hanae minegishi, Osamudohi, Soukanan & Hidetsugu sato, Treatment of unstable distal radius fractures with the volar locking plate. *Upsala Journal of Medical Sciences*. 2011; 116: 280–284.
 34. Joideep Phadnis, Alex Trompeter, Kieran Gallagher, Lucy Bradshaw, David S Elliott and Kevin J Newman, Mid-term functional outcome after the internal fixation of distal radius fractures Phadnis et al. *Journal of Orthopaedic Surgery and research* 2012,7:4.
 35. Cognet JM, Geanah A, Marsal C, Kadoch V, Gouzou S, Simon P Plate fixation with locking screw for distal fractures of the radius *Rev Chir Orthop Reparatrice Appar Mot*. 2006 Nov;92(7):663-72.

-
36. RE Anakwe, LAK Khan, RE Cook, and JE McEachan Locked volar plating for complex distal radius fractures: Patient reported outcomes and satisfaction *J Orthop Surg Res.* 2010;5:51.
37. Sanjay Agarwala, Ganesh S Mohrir, Shreyans D. Functional Outcome in Distal Radius Fractures Treated with Locking Compression Plate. *Gadiya Bombay Hospital Journal*, Vol. 54, No.2,2012.
38. Kavim Khatri, Vijay Sharma, Kamran Farooque, and Vivek Tiwari surgical treatment of unstable distal radius fractures with a volar variable-angle locking plate: clinical and radiological outcomes. *Arch Trauma Res.* 2016 June; 5(2):e25174.
39. William J. MARLOW, Rohit SiNghAL, Sujay Dheerendra, Peter RALtE, Jochen FiSChER, Mohammad WASEEM Distal radius volar locking plates : Does a variable angle locking system confer a clinical advantage ?. *Acta Orthop. Belg.*, 2012, **78**, 309-316.
40. Masood K, Akhtar M, Qureshi KZ, Zahoor MU, Siraj M, et al (2016) Radiological and Clinical Outcome of Distal Radial Fractures Managed by Variable Angle 2.4 mm Titanium Volar Plate. *Orthop muscular Syst* 5:222. doi:10.4172/2161-0533.1000222.
41. Hebert-Davies J, Laflamme GY, Rouleau D, et al. A biomechanical study comparing polyaxial locking screw mechanisms. *Injury.* 2013;1358-1362.
42. Park JH, Hagopian J, Ilyas AM. Variable-angle locking screw volar plating of distal radius fractures. *Hand clin.*2012;26:373-380.
43. Rausch S, Klos K, Stephan H, et al. Evaluation of a polyaxial angle-stable volar plate in a distal radius C-fracture model—a biomechanical study. *Injury.* 2011;42:1248–1252.

-
44. Hoffmeier KL, Hofmann GO, Muckley T. The strength of polyaxial locking interfaces of distal radius plates. *Clin Biomech (Bristol,Avon)*. 2009;24:637-641.
45. Adam Hart, MSc, MD, Melissa Collins, MSc, MD et al. Can the Use of Variable-Angle Volar Locking plates Compensate for Suboptimal Plate Positioning in Unstable Distal Radius Fractures? A Biomechanical study *J Orthop Trauma* 2015;29:e1-e6.
46. Jakob M, Rikli DA, Regazzoni P. Fractures of the distal radius treated by Internal fixation and early function: a prospective study of 73 consecutive Patients. *The Journal of Bone and Joint Surgery. British volume*. 2000 Apr;82(3):340-4.
47. Fitoussi F, Ip WY, Chow SP. Treatment of displaced intra-articular fractures of The distal end of the radius with plates. *JBJS*. 1997 Sep 1;79(9):1303-2.
48. Bradway JK, Amadio PC, Cooney WP. Open reduction and internal fixation of Displaced, comminuted intra-articular fractures of the distal end of the radius. *J Bone Joint Surg Am*. 1989 Jul 1;71(6):839-47.
49. Rogachefsky RA, Scott RL, Applegate B, Ouellette EA, Savenor AM, McAuliff JA. Treatment of severely comminuted intra-articular fractures of the distal end Of the radius by open reduction and combined internal and external fixation. *J Bone and Joint Surg* 2001; 83-A (4): 509-519
50. Frank a, Liporce md, Mark R, Adams, John T capo, Kenneth j koval. Distal radius fractures. *J Orthop Trauma*. 2009;23:739-748
51. Colles A. On the fracture of the carpal extremity of the radius. *Edinburgh Med Surg* 1814; 10:182-6.

52. Bassett RL. Displaced intraarticular fractures of the distal radius. Clin Orthop Relat Res. 1987; 214(214):148-152.
53. Koi K, Hattori Y, Otsuka K. Intra-articular fractures of the distal aspect of the radius: Arthroscopically assisted Reduction Compared with Open Reduction and Internal Fixation. J Bone Joint Surg. 1999;81:1093-110.
54. Amarnath AP, Dr Anusha Sonti. Intra articular distal fractures treated with variable angle locking compression plates: an outcome analysis. int j orthopsci 2020;6940:267-273
55. Chavhan an, dudhekar uj, badole cm, Wandile kn. functional and radiological outcome in distal radius fractures treated with locking compression plate. int j res med sci 2017;5:574-82
56. Minegishi H, Dohi O, An S, Sato H. treatment of unstable distal radius fractures with the volar locking plates. Ups j Med sci. 2011;116:280-4
57. Xavier CRM, Molin DCD, Santos RMM, Santos RDT, Neto JCF, surgical treatment of distal radius fractures with a volar locked plate: correlation of clinical and radiographic results. Rev Bras Ortop. 2011;46(5):505-13
58. Kilic A, Kabukcuoglu Y, Ozkaya U, Gul M, Sokusu S, Ozdogan U. Volar locking plate fixation of unstable distal radius fractures. Acta Orthop Traumatol Turc. 2009;43(4):303-8.

59. Rundgren, J., Bojan, A., Mellstrand Navarro, C. et al. Epidemiology, classification, treatment and mortality of distal radius fractures in adults: an observational study of 23,394 fractures from the national Swedish fracture register. *BMC Musculoskelet Disord* 21, 88 (2020). <https://doi.org/10.1186/s12891-020-3097-8>.

60. Dr Sanjeev Gupta, Dr Tanveer Ali, "Functional and Radiological Outcome of Distal Radius Fractures Treated by Volar Locking Plating", *International Journal of Science and Research (IJSR)*, Volume 9 Issue 2, February 2020, pp. 985-990, https://www.ijsr.net/get_abstract.php?paper_id=SR20211223900, DOI: 10.21275/SR20211223900.

ANNEXURE 1 : INFORMED CONSENT

**“TO EVALUATE THE FUNCTIONAL OUTCOME OF DISTAL END RADIUS
FRACTURE TREATED USING VARIABLE ANGLE VOLAR LOCKING
COMPRESSION PLATES – An observational prospective study”**

Name of Student/Principal Investigator:

Name of Guide/Co Investigators:

**Objective: “TO EVALUATE THE FUNCTIONAL OUTCOME OF DISTAL END
RADIUS FRACTURE TREATED USING VARIABLE ANGLE VOLAR LOCKING
COMPRESSION PLATES - An observational prospective study”**

Introduction: Fractures of lower end radius are most common fractures of the upper extremity encountered in practice and constitute 17% of all fractures and 75% of all forearm fractures. These injuries account for approximately one sixth of all fractures seen and treated. In the words of Dr. Abraham Colles “this fracture takes place about an inch and a half above the carpal extremity of the radius and there is a 17% lifetime probability for distal radius fractures”. The majority of these injuries are 'closed', with no evidence of breach of the surrounding skin. Restoration of radial length, radial tilt and congruity of articular surfaces is important for good functional results. Failure to achieve and maintain near anatomic restoration can lead to various deformities and disabilities. The treating orthopedician has an armamentarium of treatment options to select from to accomplish this. Distal radial fractures are being treated by various methods i.e. closed reduction with cast immobilizations, percutaneous pinning, external fixation and ORIF with conventional plating. Regardless of these fractures being common, there is no clear consensus on their treatment as there is no clear clinical-

based evidence in the literature. It is often not possible to have a successful outcome using the same approach and materials for different types of fractures. Recognition of fracture patterns, secure fixation of fractures and maintenance of reduction is the key for successful management of more complex fractures of distal radius. The purpose of this study was to determine anatomical restoration and stabilization of acute fracture of the distal radius and functional outcome following ORIF by applying variable angle locking volar plate.

Explanation of procedure:

Range of movements at wrist and forearm and wrist x-ray to be evaluated and studied over a period of one year in 27 selected patients at KLE'S Dr Prabhakar kore's hospital and Medical research centre and charitable hospital, Belagavi

All the patients will be reviewed post operatively at 2weeks, 6weeks, 12weeks and 6 months or until the fracture has healed clinically and radiologically

All the patients will be assessed for functional outcome and radiographs will be taken at every visit

Withdrawal from participation in the study: Participation in this study is voluntary. You will be free to decide whether to participate in this study or continue participation once enrolled. In case you decide to withdraw your participation, you are free to do so. However, please convey the decision to the principal investigator.

Possible benefits from participating in the study: You will/will not have nor get any benefits by participating in this study. The data gathered will help the population at large.

Possible risks from participating in the study: There are no risks involved in participating in this study.

Privacy and confidentiality: The information collected from you will be coded, to prevent any person from identifying you. Your identity will never be revealed. The data collected from you will be kept confidential and only processed or aggregated data will be used for publication.

Financial incentives: You will not receive any payment for participating in this study.

Authorization for publication of aggregated data: Results obtained after processing of the aggregated data will be published for scientific purposes and or presented to scientific groups. However, your identity will never be revealed.

Questions: In case of any questions with regard to this study, you are free to contact BL0121001 If you have any question or complaints with regard to your right as study participant you may contact Dr Harsha Hegde, Chairperson, Ethical committee of JNMC, 0831-2473777 Extension 4052.

Legal rights: By signing this consent form, we are not waving any of your legal rights.

CONSENT STATEMENT

I am making a voluntary decision to participate in the study **“TO EVALUATE THE FUNCTIONAL OUTCOME OF DISTAL END RADIUS FRACTURE TREATED USING VARIABLE ANGLE VOLAR LOCKING COMPRESSION PLATES -An observational prospective study”** . My signature below indicates that I have decided to participate and I have read the information provided above or the information provided above has been read to me in the language that I understand best. I was given the opportunity to ask questions and that they have been answered to my satisfaction.

Name of the participant:

Signature or left thumb impression of the participant:

Name of the witness:

Signature or left thumb impression of the witness:

Name of the investigator:

Signature of the investigator:

ANNEXURE 2 : CASE PROFORMA

**“TO EVALUATE THE FUNCTIONAL OUTCOME OF DISTAL END RADIUS FRACTURE
TREATED USING VARIABLE ANGLE VOLAR LOCKING COMPRESSION PLATES”- AN
OBSERVATIONAL PROSPECTIVE STUDY**

PATIENT NAME:

IP NO:

AGE:

SEX:

ADDRESS:

DOA:

DOD:

PHONE NUMBER:

DIAGNOSIS:

PROCEDURE DONE:

FUNCTIONAL OUTCOME:

6 WEEKS

12 WEEKS

6 MONTHS

DORSIFLEXION			
PALMARFLEXION			
PRONATION			
SUPINATION			
RADIAL DEVIATION			
ULNAR DEVIATION			

MMWS			
------	--	--	--

MODIFIED MAYO WRIST SCORE

Category	Findings	Score
Pain (25 points)	No pain	25
	Mild occasional	20
	Moderate	15
	Severe	0
Work status (25 points)	Regular job	25
	Restricted job	20
	Able to work but unemployed	15
	Unable to work due to pain	0
Range of motion (25 points)	>120°	25
	100° to 119°	20
	90° to 99°	15
	60° to 89°	10
	30° to 59°	5
	0° to 29°	0
Grip strength (% of normal) (25 points)	90 to 100	25
	75 to 89	15
	50 to 74	10
	25 to 49	5
	0 to 24	0
Final result (total points)	Excellent	90-100
	Good	80-89
	Fair	65-79
	Poor	<65

Modified Mayo wrist score will be used for assessment, it is a physician rating scoring system which gives us a total score of 100; 25 for assessment of pain, 25 for the active extension/flexion Arc of wrist, 25 for grip strength and 25 for the ability to return to regular activities, the pain is rated according to patient's description

ANNEXURE 3 : ETHICAL CLEARANCE



K.L.E. ACADEMY OF HIGHER EDUCATION AND RESEARCH
(Deemed - to - be - University)

Accredited 'A+' Grade by NAAC in (3rd Cycle) Placed in Category 'A' by MHRD (Govt)

JNMC INSTITUTIONAL ETHICS COMMITTEE
JAWAHARLAL NEHRU MEDICAL COLLEGE,
NEHRU NAGAR, BELAGAVI-590010 (KARNATAKA-INDIA)

Website: <http://www.jnmc.edu>
E-Mail : deme@jnmc.edu

Phone: (+ 91-(0)831 Office : 2472550
Principal: 2471701
Fax No. +91 (0)831 - 2470759

Ref No.MDC/JNMCIEC/

Date: 27/09/2022

To,

BL0121001

PG Student in Orthopaedics,
J. N. Medical College,
BELAGAVI.

Sub: Institutional Ethical Clearance for the study.

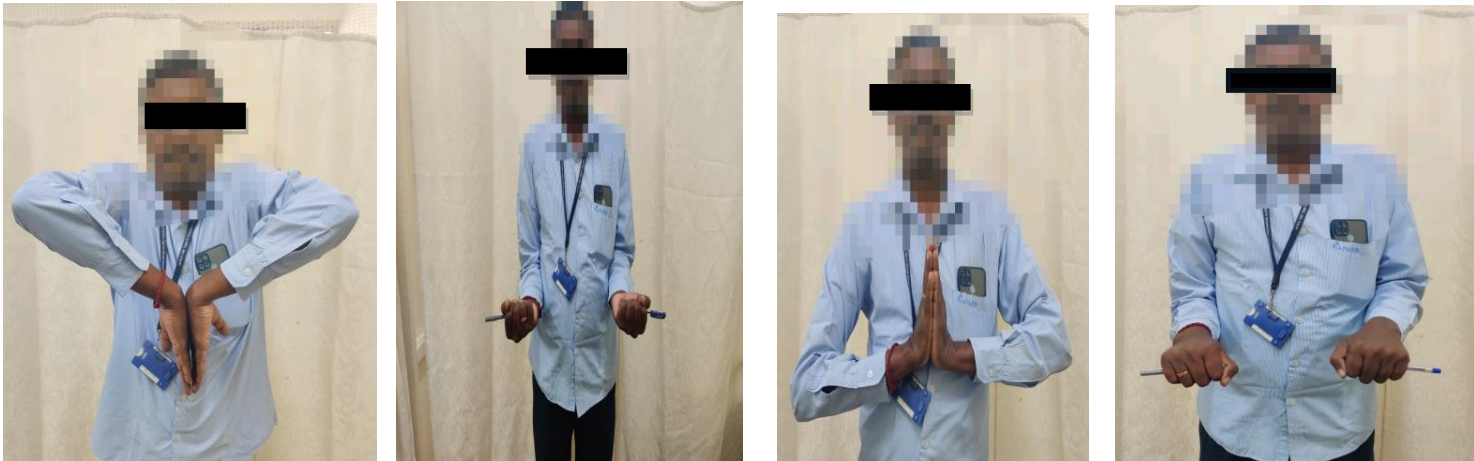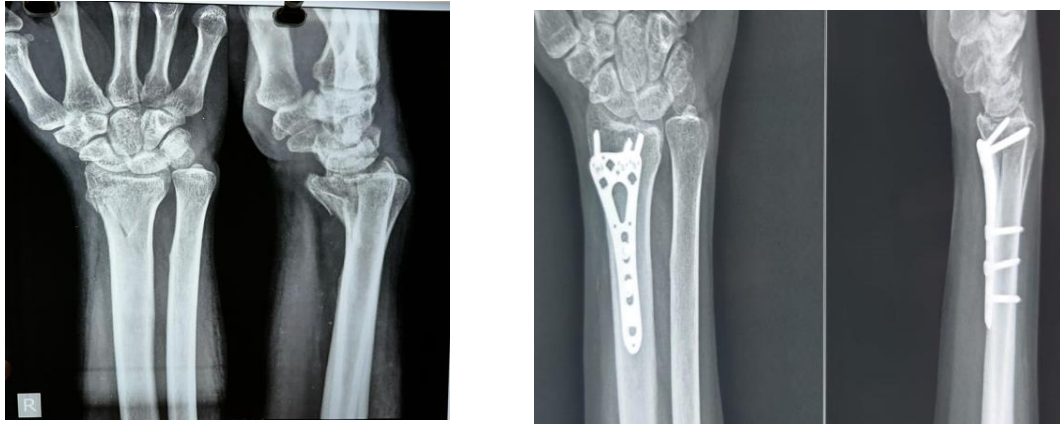With reference to the above, we wish to inform you that your proposed research project titled "TO EVALUATE THE FUNCTIONAL OUTCOME OF DISTAL END RADIUS FRACTURE TREATED USING VARIABLE ANGLE VOLAR LOCKING COMPRESSION PLATES -AN OBSERVATIONAL PROSPECTIVE STUDY" is ethical and justifiable. The proposed research project has been cleared by the JNMC Institutional Ethics Committee.

(Dr. Smita Sonoli)
Member Secretary
JNMC Institutional Ethics Committee
J.N.Medical College, Belagavi.

(Dr. Harsha Hegde)
Chairman,
JNMC Institutional Ethics Committee
J.N.Medical College, Belagavi

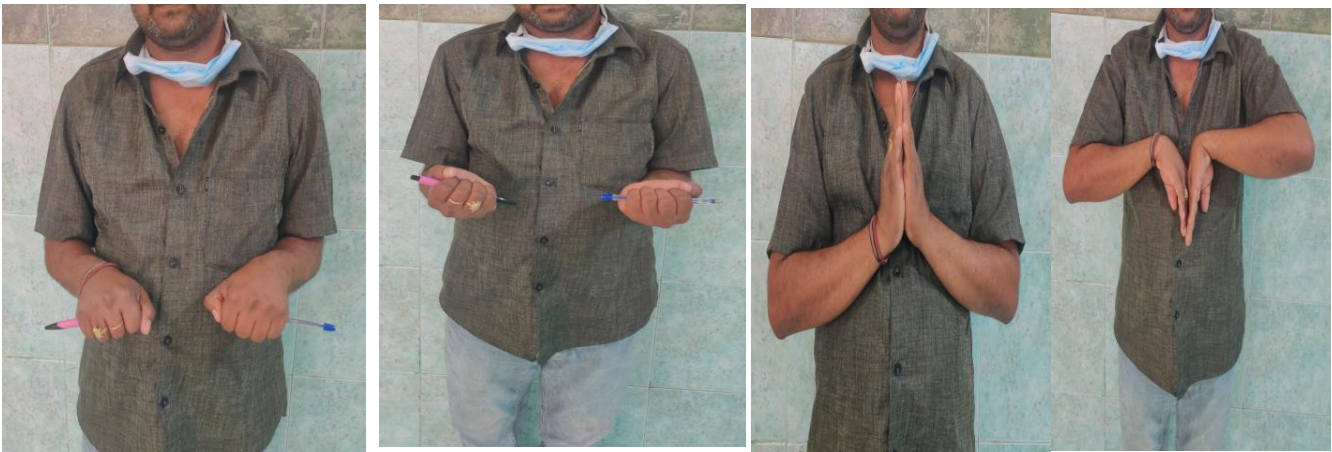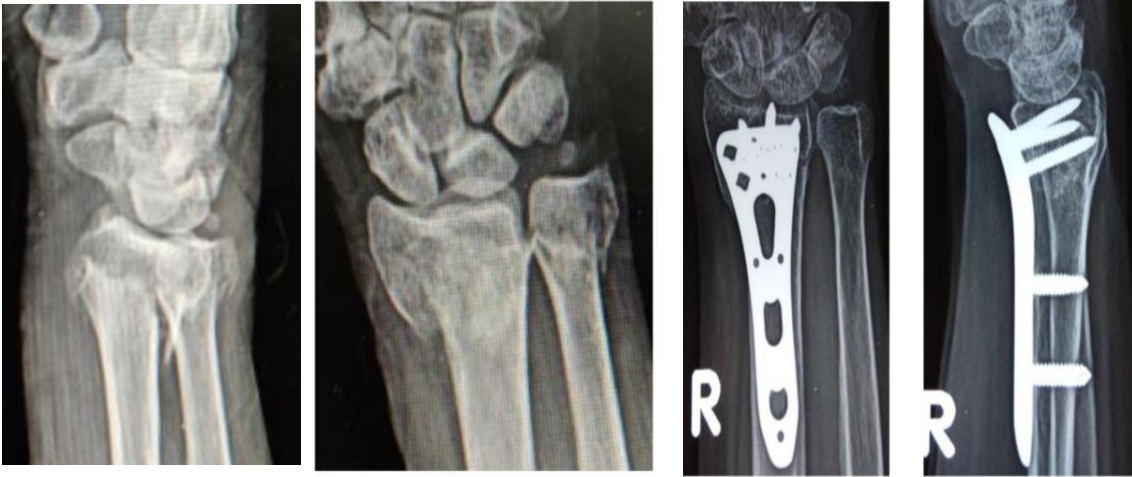ANNEXURE 4 : PHOTOGRAPHS

PATIENT 1



EXCELLENT RESULT

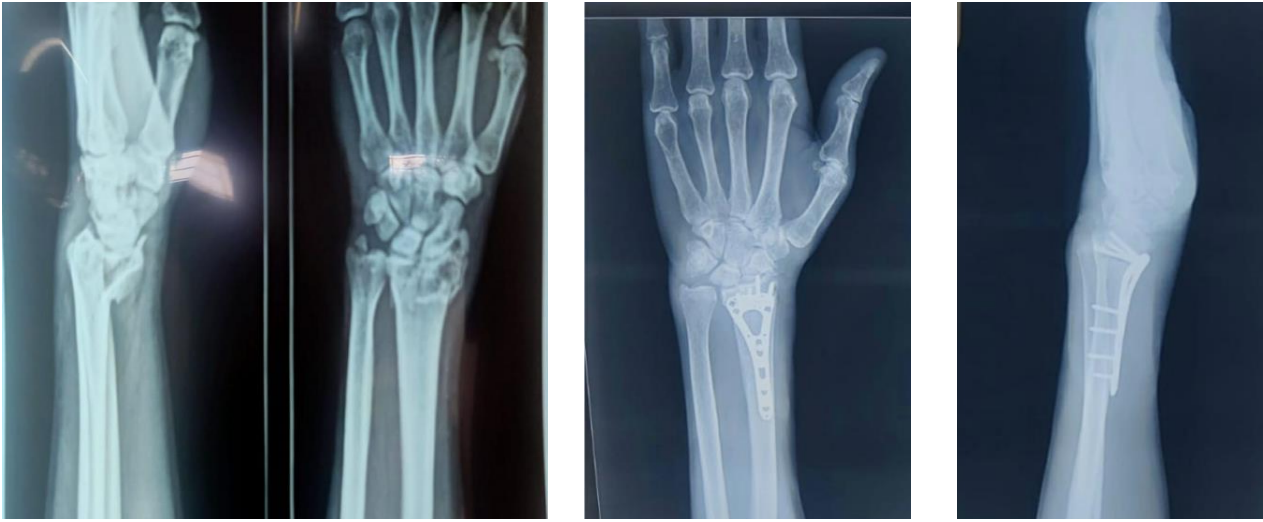PATIENT 2



GOOD RESULT

PATIENT 3

:



FAIR RESULT

ANNEXURE 5 :MASTER CHART

Case Number	Name	age	sex	Side	AO Type	Mode of injury	Associated injury	Functional Outcome						Complications	MMWS	Results
								DF	PF	RD	UD	SUP	PRO			
1	Ashok	73	Male	Left	23A2	RTA	Nil	80	80	20	40	90	85		95	Excellent
2	Sudha	42	Female	Left	23B1	RTA	Right proximal tibia# with acl injt	80	85	20	30	85	80		90	Excellent
3	Deepak	38	Male	Left	23C2	RTA	Nil	70	70	10	20	70	70		70	Fair
4	Harna	63	Female	Left	23C2	RTA	Right proximal tibia#	80	85	15	40	80	80		90	Excellent
5	Anuraag	21	Male	Left	23B3	RTA	Left AC joint dislocation	80	80	15	20	85	80		90	Excellent
6	Shahid	38	Male	Right	23C1	RTA	Nil	90	80	20	40	90	80		95	Excellent
7	suresh	60	Male	Right	23B3	Domestic Fall	Nil	85	80	20	35	85	80		90	Excellent
8	mahesh	41	Male	Right	23B2	RTA	Nil	80	75	15	30	75	80		85	Good
9	savitri	68	Female	Right	23B1	Domestic Fall	Nil	80	75	20	25	80	75		85	Good
10	ratnawa	49	Female	Left	23B2	Domestic Fall	Nil	80	85	20	30	85	85		90	Excellent
11	baburao	66	Male	Left	23C1	Domestic Fall	Nil	75	70	15	20	75	80	Wkst stiffness	75	Fair
12	ragesh	45	Male	Left	23C2	Domestic Fall	nil	85	80	20	35	90	85		95	Excellent
13	priya	30	Female	Right	23B3	RTA	Nil	85	75	15	20	80	80		90	Excellent
14	virupaxi	59	Male	Left	23B3	RTA	Head Injury	75	70	15	25	75	70	infection	75	Fair
15	suprabha	62	Male	Left	23B1	Domestic Fall	Nil	85	85	20	35	85	80		95	Excellent
16	manjunath p	55	Male	Left	23C2	RTA	Nil	80	85	20	30	80	80		90	Excellent
17	manjunath b	60	Male	Right	23C1	RTA	Nil	80	80	20	35	80	85		90	Excellent
18	savita	57	Female	Left	23B3	Domestic Fall	Nil	75	80	15	20	80	80		80	Good
19	irappa	35	Male	Left	23B2	RTA	Nil	85	80	15	30	80	80		90	Excellent
20	anandi	55	Female	Right	23B3	Domestic Fall	Nil	90	85	25	30	85	85		95	Excellent
21	joy	36	Male	Left	23C3	RTA	Head Injury	85	90	20	25	90	85		90	Excellent
22	raju	47	Male	Right	23B3	RTA	Nil	80	75	20	30	85	85		90	Excellent
23	chandrashekha	32	Male	Right	23C3	RTA	Nil	75	75	15	30	75	75		80	Good
24	Sabira	40	Female	Right	23A2	Domestic Fall	Nil	85	85	15	25	90	80		90	Excellent
25	Mallikarjun	42	Male	Left	23A3	Domestic Fall	ipsilateral distal ulna#	90	80	25	20	85	85		90	Excellent
26	Iranna	38	Male	Right	23C2	RTA	Nil	85	80	20	20	80	80		90	Excellent
27	Laxmi	43	Female	Left	23A3	Domestic Fall	Nil	80	75	15	25	80	75		80	Good