

**“RADIOGRAPHIC ASSESSMENT OF ANATOMICAL  
VARIATION OF NASOPALATINE CANAL IN PATIENTS  
ATTENDING TERTIARY CARE CENTER USING CBCT - A  
PROSPECTIVE STUDY.”**

---

**By**

**REG NO. IG0221002**

**Dissertation**

*Submitted to KLE Academy of Higher Education and Research (KAHER),*

*Belagavi*

*In Partial Fulfillment of the Requirements for the Degree Of*

**MASTER OF DENTAL SURGERY**

**In**

**ORAL MEDICINE AND RADIOLOGY  
(BRANCH- VII)**

**DEPARTMENT OF ORAL MEDICINE AND RADIOLOGY,**

**KAHER'S KLE VISHWANATH KATTI**

**INSTITUTE OF DENTAL SCIENCES, JNMC CAMPUS,**

**NEHRU NAGAR, BELAGAVI- 590010, KARNATAKA.**

---

**2021 -2024**

---

**KLE ACADEMY OF HIGHER EDUCATION AND RESEARCH,  
BELAGAVI, KARNATAKA**

**Endorsement by the HOD, Principal/  
Head of the Institution**

This is to certify that this dissertation/ thesis entitled "Radiographic assessment of anatomical variation of nasopalatine canal in patients attending tertiary care center using CBCT - A Prospective Study"- is a bonafide research work done by **Dr SURAYYA KIRESUR** under the guidance of **Dr. ARVIND SHETTI, M.D.S.**, Professor Department of **ORAL MEDICINE AND RADIOLOGY**, (Branch VII), KAHER's KLE Vishwanath Katti Institute of Dental Sciences, JNMC Campus, Nehru Nagar, Belagavi-590010.

*Vaishali Keluskar*

**Dr. VAISHALI KELUSKAR, M.D.S.,**  
Professor and Head,  
Department of Oral Medicine  
and Radiology  
KLE Vishwanath Katti Institute of  
Dental Sciences,  
JNMC Campus, Nehru Nagar,  
Belagavi-590010.

Date: 22/04/2024

Place: Belagavi.

**Professor and Head**  
Department of Oral Medicine and Radiology  
KLE VK Institute of Dental Sciences, Belagavi

*Alka D. Kale*

**Dr. ALKA D. KALE M.D.S, Ph.D.**  
Principal,  
KLE VK Institute of Dental Sciences,  
Nehru Nagar, Belagavi-590010.

**PRINCIPAL**  
KLE V.K. Institute of Dental Sciences  
Nehru Nagar BELAGAVI-590010

Date: 22/4/24

Place: Belagavi.

## **ABSTRACT:**

**Background:** Anatomical variations exist between males and females in the anterior region of maxillary jaw and thorough knowledge of these structures is essential in planning of any surgeries to avoid any potential complications. An accurate diagnosis and course of therapy may be achieved with the use of (CBCT) evaluation of critical anatomical structures.

**Aim and objectives:** The current study assesses the morphometric features of the (NPC), the diameters of the incisive and Stenson's foramen (IF and SF), and the thickness of the buccal bone (BBT) in various age groups and gender.

**Material and Method:** The present prospective observational study used data of 101 CBCT scans belonging to the age range of 20-69 years categorized into three groups. The assessment of dimensions of NPC, SF, IF, and BBT were carried out in the sagittal and axial sections of CBCT, values obtained were tabulated for males and females and then appropriate statistical analysis was done.

**Results:** The average diameters for SF, IF, NPC length, BBT1, BBT2, and BBT3 were  $2.48 \pm 1.02$  mm,  $3.09 \pm 0.90$  mm,  $9.48 \pm 2.71$  mm,  $5.92 \pm 1.05$  mm,  $5.98 \pm 1.13$  mm,  $6.42 \pm 1.29$  mm, respectively. At the 0.0001 level, statistically significant variance was found amongst gender in the NPC length mean dimension. Regarding NPC morphology, cylindrical shape was the most commonly found (73.27%) followed by hourglass (13.86%) and conical shape (8.91%).

**Conclusion:** Dimensions of the NPC, SF, IF, and BBT vary among males and females with differences in dimensions between different age groups. To enhance the success of procedures affecting the maxillary anterior region of jaw, preoperative examination with CBCT is crucial.

## **LIST OF ABBREVIATIONS**

<b>ABBREVIATION</b>	<b>FULL FORM</b>
<b>CT</b>	Computed Tomography
<b>MSCT</b>	Multi-slice spiral CT
<b>CBCT</b>	Cone Beam Computed Tomography
<b>2D</b>	Two Dimension
<b>3D</b>	Three Dimension
<b>NCP</b>	Nasopalatine canal
<b>DICOM</b>	Digital Imaging and Communications in Medicine
<b>SF</b>	Stensons foramen
<b>IF</b>	Incisive foramen
<b>BBT</b>	Buccal bone thickness
<b>PSP</b>	Photostimulable phosphor
<b>CMOS</b>	Complementary metal-oxide-semiconductor sensors
<b>SPSS</b>	Statistical Package for the Social Sciences
<b>ANOVA</b>	Analysis of Variance
<b>FOV</b>	Field of view
<b>kVp</b>	Kilovoltage peak
<b>mA</b>	Milliamperage
<b>mm</b>	Millimeter

<b>cm</b>	Centimeter
<b>h</b>	Height
<b>W</b>	Width
<b>OPG</b>	Orthopantomogram

## CONTENTS

<b>SL.NO.</b>	<b>PARTICULARS</b>	<b>PAGE NO.</b>
<b>1</b>	<b>INTRODUCTION</b>	<b>1-7</b>
<b>2</b>	<b>AIM &amp; OBJECTIVES</b>	<b>8</b>
<b>3</b>	<b>REVIEW OF LITERATURE</b>	<b>9-12</b>
<b>4</b>	<b>METHODOLOGY</b>	<b>13-19</b>
<b>5</b>	<b>RESULTS</b>	<b>20-28</b>
<b>6</b>	<b>DISCUSSION</b>	<b>29-33</b>
<b>7</b>	<b>LIMITATIONS OF THE STUDY</b>	<b>33</b>
<b>9</b>	<b>CONCLUSION</b>	<b>35</b>
<b>11</b>	<b>BIBLIOGRAPHY</b>	<b>36-40</b>

<b>11</b>	<b>ANNEXURES</b>	<b>41-48</b>
-----------	------------------	--------------

### **LIST OF TABLES**

<b>TABLE NO.</b>	<b>PARTICULARS</b>	<b>PAGE NO.</b>
<b>1</b>	Comparison of shapes according to various age groups	<b>21</b>
<b>2</b>	Comparison of shapes in different age groups	<b>22</b>
<b>3</b>	Comparison of shape according to gender	<b>23</b>
<b>4</b>	Comparison of mean SF score, IF scores, mean length, BBT 1, BBT 2 , BB3 between males & females	<b>24</b>
<b>5</b>	Comparison of mean SF score, IF scores, mean length, BBT 1, BBT 2 and BBT 3 between three age groups	<b>26</b>

### **LIST OF GRAPHS**

<b>GRAPH NO.</b>	<b>PARTICULARS</b>	<b>PAGE NO.</b>
------------------	--------------------	-----------------

<b>1</b>	Comparison of three groups according to gender and age	<b>20</b>
<b>2</b>	Comparison of shape according to various age group	<b>22</b>
<b>3</b>	Comparison of Shapes in gender	<b>23</b>
<b>4</b>	Mean SF and IF scores of male and female	<b>24</b>
<b>5</b>	Mean length scores of in male and female	<b>25</b>
<b>6</b>	Comparing mean BBT1, BBT2 and BBT3 in male and female	<b>25</b>
<b>7</b>	Comparison of three groups with mean length	<b>27</b>
<b>8</b>	Comparison of shape according to gender	<b>27</b>
<b>9</b>	Comparison of three groups with mean SF and IF scores	<b>28</b>

## LIST OF FIGURES

<b>FIGURE NO.</b>	<b>PARTICULARS</b>	<b>PAGE NO.</b>
<b>1</b>	Diagram of premaxilla & maxilla	<b>2</b>
<b>2</b>	Diagram of development of premaxilla	<b>3</b>
<b>3</b>	Diagram of nasopalatine canal	<b>4</b>
<b>4</b>	Radiograph of periapical granuloma	<b>5</b>
<b>5</b>	Radiograph of periapical cyst	<b>5</b>
<b>6</b>	CBCT machine	<b>6</b>
<b>7</b>	CBCT machine	<b>16</b>
<b>8</b>	Exposure Parameter	<b>16</b>
<b>9</b>	Orthogonal plane used to measure parameter	<b>17</b>
<b>10</b>	Measurement of diameter of the nasopalatine canal, in axial section	<b>17</b>
<b>11</b>	Measurement of length of the NPC on sagittal section	<b>18</b>
<b>12</b>	Measurement of diameter of the Stensons foramen in sagittal section	<b>18</b>
<b>13</b>	Measurement of buccal bone thickness	<b>19</b>
<b>14</b>	Different shapes of NPC	<b>20</b>

## LIST OF ANNEXURES

<b>S. NO.</b>	<b>PARTICULARS</b>	<b>PAGE NO.</b>
<b>1</b>	<b>Ethical Clearance Certificate</b>	
<b>2</b>	<b>MASTER CHART – Measurement of length, diameter of SF,IF,BBT in group I</b>	
<b>3</b>	<b>MASTER CHART - Measurement of length, diameter of SF,IF,BBT in group II</b>	
<b>4</b>	<b>MASTER CHART - Measurement of length, diameter of SF,IF,BBT in group III</b>	

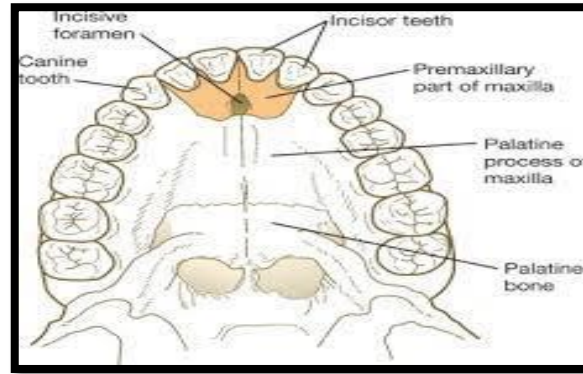
# **RADIOGRAPHIC ASSESSMENT OF ANATOMICAL VARIATIONS OF NASOPALATINE CANAL IN PATIENTS ATTENDING TERTIARY CARE CENTER USING CBCT-A PROSPECTIVE STUDY**

## **Introduction**

Anatomical landmarks aid in picture navigation and provide proof for anomaly detection. Primary responsibilities of medical diagnostic systems is the identification of anatomical landmarks. CBCT is exceptionally valuable diagnostic tool in dentomaxillofacial surgeries because of its ability to illustrate different anatomical landmarks without superimposition of buccal and lingual cortical plates [1][2]. Most common surgeries involving anterior maxillary area sometimes referred as premaxillary region are implant surgery, osteotomy, orthognathic surgery, and post trauma procedures. These surgeries may end up in significant complications, due to the presence of major sensory nerves and blood vessels. Therefore, pre surgical assessment of architecture of tissue in anterior maxillary area is essential to understand the anatomical variances [4].

## **GROSS ANATOMY OF PREMAXILLA**

The anterior maxilla, which refers to the front part of the upper jawbone area and teeth spanning the first premolars from the right to the left are collectively referred to as the anterior maxilla, or premaxilla, plays a crucial role in dental health. Moreover, the anterior maxilla also provides support to the facial structure and helps maintain the alignment of the teeth. Additionally, the term aesthetic zone is frequently used to highlight its significance in contemporary dentistry [3]. The nasopalatine canal and the thin labial bone plate are two sensitive aspects that must be considered during surgical treatment involving the anterior maxilla [35].



**Fig1-Premaxilla**

### **DEVELOPMENT OF PREMAXILLA AND INCISIVE CANAL**

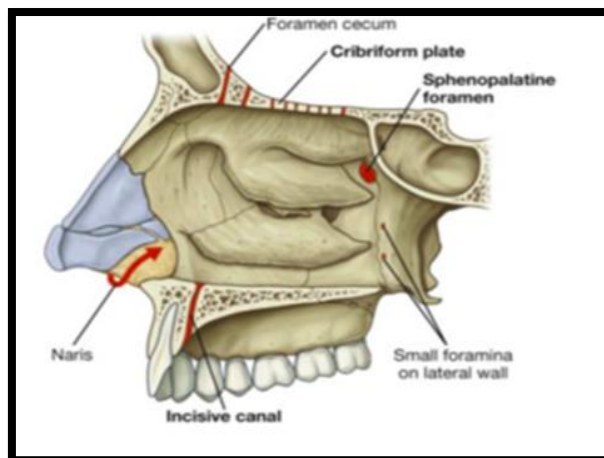
The upper lip and premaxilla develop between four and seven weeks of gestation. After then, the embryo's head lifts off the cardiac eminence. The next step is for the mandible to enlarge, which makes room for the tongue to descend. Meanwhile, the palatine processes combine to form the secondary palate as they proliferate and rise in a hinge action towards the midline. During the vital time of seven months of intrauterine life, when the face and palate are developing, there is a shift in the blood flow to the face. The premaxilla begins to ossify and the ossification center divides from the maxilla at this stage, while keeping the midline incisive foramen and canal intact. [35]

### **ANATOMY OF INCISIVE CANAL**

An interosseous conduit that goes through the premaxilla, the incisive canal (also known as the nasopalatine canal) connects the nasal and oral canals. A vascular anastomosis between the larger palatine and sphenopalatine arteries and the nasopalatine nerve are located inside the canal [9][10] A vascular anastomosis connects the posterior septal branch of the sphenopalatine artery to the larger palatine artery, and the nervous incisivus extends from the mucosa of the hard palate and gingiva around the upper incisors to the upper canine teeth, providing sensory input to the nasal ganglia [2]. The nasopalatine duct is an uncommon addition to the incisive canal. Surgical procedures carried out in anterior maxilla are extraction, endodontic therapy,

implant placement, flap operations, orthognathic surgery and enucleation of cyst. When it comes to surgical procedures involving the mouth and its surrounding structures, dental experts need a deeper knowledge of the NPC's anatomy and variances [7]. The success of the surgery depends on the administration of adequate anaesthesia in this specific area. The arrangement, size, location, and perimeter of each nasopalatine foramen opening at the nasal fossa vary. The nasopalatine canal varies in length and form among populations. The NPC's average length varies, ranging from 10 mm to 20 mm. [9] Its incisive fosse width might be as wide as 6 mm. In most cases, it will divide into two sections, creating a "Y" shape, however it might occasionally seem like a single canal. A NPC's shape could change depending on factors like age, gender, and race [5].

**Figure 2: Incisive canal**



**Figure 3: Development of premaxilla and incisive canal**

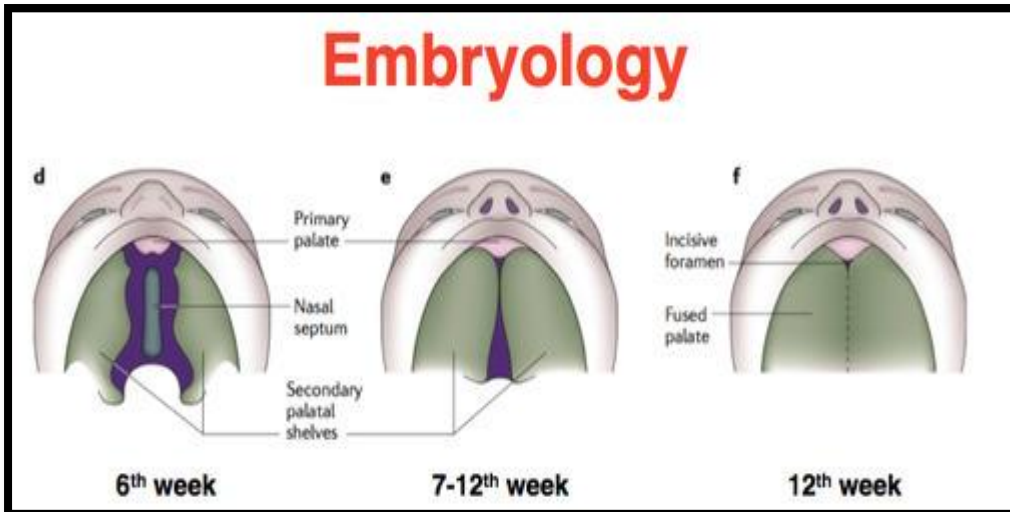


Figure 3: Development of premaxilla and incisive canal

### INCORRECT INTERPRETATION OF INCISIVE CANAL

In the anterior maxilla domain, a number of osteolytic lesions might be misdiagnosed as anatomic structures,

### PERIAPICAL GRANULOMA

Manifested as a well-defined, radiolucent lesion smaller than 1.5 cm in diameter, radiolucent lesion.

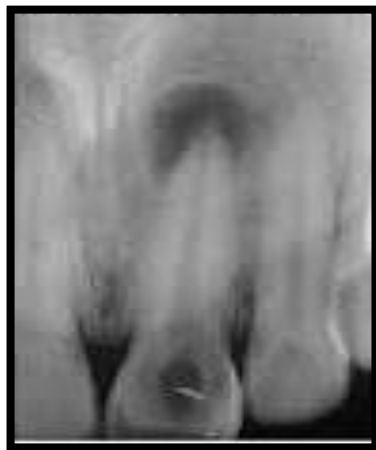
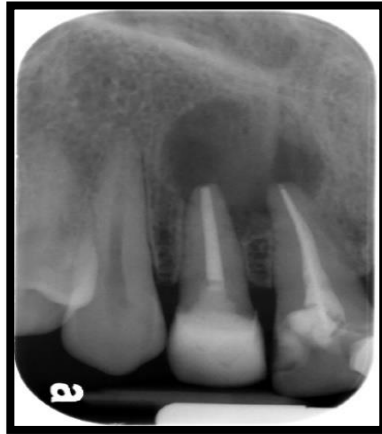
Figure 4: Periapical granuloma

## APICAL CYST

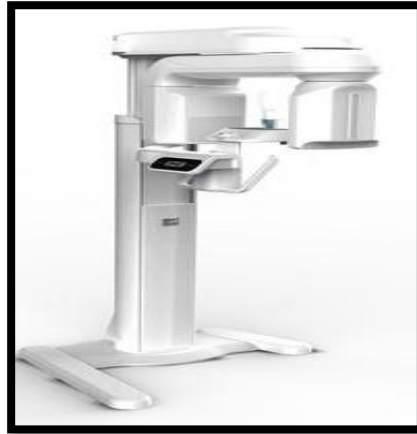Periapical radiolucency with corticated borders measuring greater than 1.5cm.



**Figure 5-Periapical cyst**

Meyer in 1914 first described about nasopalatine cyst, arises from embryogenic remnants of nasopalatine duct.

Radiographs are a vital diagnostic resource for disease management and screening. The two-dimensional projections used in diagnostic imaging of the anterior maxilla have long been the gold standard for diagnosis. Despite the fact that 2D radiographic imaging scans can show the NPC these techniques have inherent constraints like superimposition, distortion, and magnification, which may result in the distortion of structures. Compared to 2D radiography, CBCT has a number of advantages, including the lack of geometric distortion and superimposition. It also creates a 3D representation of hard tissue [11] [12].



**Figure 6: CBCT- machine**

### **CONE BEAM COMPUTED TOMOGRAPHY**

CBCT equipment makes use of solid-state flat panel detectors that reciprocate and emits cone-shaped x-ray beams. The whole dental/maxillofacial volume or a smaller, targeted region of interest is covered by one 180–360-degree rotation of the detector around the subject. A single sweep (rotation) is used to acquire the desired data (180–1024)2D photographs, each slightly offset, similar to lateral cephalometric images. The working range of CBCT is typically 1–15 mA at 90–120 kVp, which is similar to panoramic radiography's X-ray characteristics [37] The computer immediately analyses the two-dimensional photographs when they are uploaded. It employs a modified version of the Feldkamp method to reconstruct the images into the anatomical volume, allowing for axial, coronal, and sagittal orthogonal plane viewing at a 1:1 ratio. Due to inherent limitations of two-dimensional radiographs, including magnification and distortion the characterization of nasopalatine canal (NPC) morphometry is demonstrably inadequate. Consequently, exploration of alternative imaging modalities with superior spatial resolution is imperative. CBCT allows for precise three-dimensional evaluation of skeletal and muscular components, has become more important in this context [11] [12][37]

## **ADVANTAGES OF CBCT**

### **X-ray beam limitation**

By narrowing the principal beam, it is possible to restrict x-rays to the specific region in CBCT. Accordingly, based on probable conditions and presentation of specific region for each patient, a perfect field of vision (FOV) is selected.

### **Image accuracy**

With submillimetre isotropic voxel resolution, CBCT imaging may provide images as small as 0.4 mm to 0.076 mm. This provides images with ideal resolution for evaluation the maxillofacial region, where accuracy in every dimension matters.

### **Short scan time**

Duration required to capture image ranges from 20-30 seconds.

### **Low radiation dose**

It has been found that CBCT gives less than 76.2% to 98.5% of conventional CT when patient doses are compared between conventional CT and CBCT.

**Aim of this study:** Determine gender and age-based variations in the anatomical characteristics of nasopalatine canal.

**Objectives:**

- To assess length of the (NPC) among males and females in various age group.
- To assess diameter of incisor foramen and Stenson's foramen across various age group and genders.
- To analyse the nasopalatine canal morphology between in varying age group and genders.
- To measure bone thickness on labial side of the nasopalatine canal various age groups and genders.

## REVIEW OF LITERATURE

**Mraiwa et al (2004)** Used 2D and 3D CT scans to reevaluate the nasopalatine canal; 34 spiral CT images were used for preoperative planning of maxillary implant implantation. The typical measurement for the nasopalatine canal length was 8.1 (3.4) mm. This tooth has an incisive foramen located at its palatal aperture; its mean inner size is 4.6 (1.8) mm. At the base of the nose, you may usually find two openings, also called Y-canals. There were cases where the canal seemed to be one cylinder-shaped nasal orifice. The jaw's bucco palatal breadth was 7.4 (2.6) mm in front of the canal. There was a substantial difference in the interpretation of canal morphology between the 2D/3D combined observation technique and 2D image observation[17]

**Mardinger,et al (2008)** ascertained various resorption stages of the alveolar bone in front maxilla in relation to dental implants. Study included 207 participants in the research underwent maxillary computed tomography scans prior to receiving dental implants. control group and research group were the divisions made in the pictures based on the remaining bony ridge, as per the Lekholm and Zarb categorization. Study showed that canal diameter increased in all dimensions depending on how much of the ridge has reabsorbed. According the study extraction of the tooth was the primary cause of the larger canal diameter.

**Xin Liang (2009)** investigated the micro- and macro-anatomical diversity and features of the human nasopalatine canal on CT image data. The researchers used 160 preserved human skulls and 120 spiral CT images of the upper jaw from patients to measure the canal features, which were then used to determine the preoperative placement of implants in the incisor area. By using a high-resolution (HR-MRI) human cadaver specimens were imaged. The nasopalatine canal's content and area were evaluated by serially sectioning these tissues for histological investigation. Results demonstrated significant anatomical heterogeneity, increasing canal diameters with age, and neurovascular canal content; hence, the anterior maxillary area necessitates meticulous three-dimensional planning before to surgical procedures, including implant insertion.

**Tözüm et al (2012)** A multicentre clinical study used computerised tomography to evaluate the features of the maxillary incisive canal. included 933 participants were either partly or completely edentulous and planned to have implants. The usual dimensions of the canals were 2.59 mm in width and 10.86 mm in extent. Edentulous anterior maxilla has a shorter canal length than the dentate maxilla. There was no difference in canal diameter

between the dentate and edentulous groups. Compared to females, men' incisive canals were broader and longer.

**Meryem Etoz et al (2014)** utilized 500 CBCT scans to investigate incisive canal anatomy and morphology at a particular site in Turkey. Breadth of the Stenson foramina and incisive foramen (IF) were measured. Outcome of the study showed that 387.78% of NPCs had an hourglass-like form, 273.5% of canals had a funnel-shaped shape, 9.18% had a conical shape, and 82.5% had a cylindrical shape, average IF diameter and NPC length were 5.06 and 12.59 mm. Men were found to have a substantially greater mean canal length than women.

**Amery et al, (2015) assessed direction and course of the canal by using CBCT** included ninety Mongoloids .Males had higher values in the front maxillary bone thickness and the incisive foramen and canal diameters, indicating gender differences. Thickness of the front maxillary bone altered by age but the canal dimensions did not show this difference. The incisive canals of most individuals resemble funnels, with the larger opening situated at the superior end. Their slanted-curve canal appears to be longer, with a single channel in its middle, and their incisive foramen is narrower .

**Mehrdad Panjnoush et al, conducted descriptive cross-sectional (2016)** Which comprised CBCT pictures of 300 patients' maxillae. The architecture and size of the nasopalatine canal were determined by reviewing sagittal and coronal scans. Sixty-six percent of patients had a cylindrical NPC without a branch, twenty-three percent had a canal with an upper branch, and 10.7 percent had a middle branch. On the sagittal section, the diameter of the incisive foramen was  $4.7\pm 1.11$ mm. In the front section of the canal, the breadth of the alveolar bone was  $12.3\pm 1.7$ mm in the top 1/3,  $10.7\pm 1.7$ mm in the middle 1/3, and  $9.8\pm 1.4$ mm in the lower 1/3. The canal-palate angle was  $109.5\pm 5.7^\circ$ . The dimensions of the canals on the inside of the skull were  $14.1\pm 3.0$ mm in length,  $4.6\pm 1.0$ mm in diameter at the incisive foramen, and  $5.1\pm 1.0$ mm in diameter at the nasal floor.

**Gönül, et al (2016) Analysed morphometry and variability of the nasopalatine canal using MDCT** included one hundred patients in the research, ages ranging from eighteen to ninety years. Measures were taken of the following: NPC length, nasal foramen diameter, incisive foramen length . Men's (NPC) length ( $13.68\pm 2.73$ mm) was also greater than women's. When comparing men and women, found no difference in the NPC measurements: NPC angle, lengths between labial bone plate and root of maxillary CI, or buccal wall of incisive foramen.

**Safi et al (2017) Assessed nasopalatine canal anatomic variations in Iranian ipopulation,** total 326 CBCT images were analysed in order to evaluate anatomical features of the NPC. The NPC had a cylinder form was most common. The NPC length averaged  $2.63 \pm 2.85$  mm, with a greater value in the male population. Anteroposterior and mediolateral dimensions of the sinus cavity (SF), the number of orifices at the nasal floor, the span of the canal, (IF) were all affected by gender. There was also a strong correlation between the furcation level of the canal, the anteroposterior dimension of the IF and SF, and the curvature of the canal.

**S. Hakbilen et al, conducted a retrospective study (2018)** Where a total of 619 participants, ranging in age from 17 to 86, were analyzed using CBCT for NPC measurements. Assessed effect of gender, age, and upper central incisors on NPC and buccal bone thickness. Sagittal view found notable variations in the length of the NPC and buccal bone thickness between boys and girls.

**Kemal Ö,zgü et al in the year (2018)** calculated the volume of the NPC in both those without teeth in the front and those with teeth in the front, and to compare the results by age, gender, form, and degree of premaxillary resorption. When comparing the AE and AD groups for NPC volume, the results revealed no statistically significant differences. The narrowing of the buccal residual bone dimensions and the widening of the incisive and nasal foraminae showed a strong correlation with NPC edentation and complex implant surgery. The correlation between NPC volume and age was shown to be statistically significant.

**Linjawi et al (2018) Used the archived CBCT data for retrospective analysis of** incisive canal's size and form at the palatal and nasal opening levels, both in a sagittal and coronal sections. The sagittal and coronal views did not reveal any significant changes in the morphologies of the incisive canals according to age or gender. In both the sagittal and coronal views, there were no obvious gender or age variations in the incisive canal shapes. Age also did not correlate with the incisive canal diameters in a statistically meaningful way. On the other hand, when looking at the incisive canal length in relation to gender, we found that male participants had a longer canal than female ones.

## **METHDOLOGY**

**SOURCE OF DATA:** CBCT scans advised for anterior maxilla reported to the Department of Oral Medicine and Radiology. CBCT was used to obtain images of the (NPC) in the sagittal, axial, and coronal planes. The research made use of anterior maxillary area CBCT images obtained for a variety of diagnostic purposes. 0.4 voxels were employed in the Planmeca Sirona Dental System GMB4 devise software 6.1.

### **Inclusion criteria**

- CBCT scans in age range 20 to 69 years were included in the study.
- Dentate patients who were advised CBCT scans for anterior region of maxilla were included in the study.

### **Exclusion criteria**

- Individuals with cleft palates and jaw fractures
- Individuals with pathology in the premaxillary area has any type of pathologic lesion.
- Individuals undergoing orthodontic treatment with implanted teeth ware excluded from this study.

## **METHOD OF DATA COLLECTION:**

The research was carried at Department of Oral Medicine and Radiology at Vishwanath Katti Institute of Dental Sciences (KAHER) University Belagavi. CBCT scans of anterior maxilla were evaluated for anatomical variations of anterior palatine canal (NPC).

## **SAMPLE SIZE:**

The research comprised 100 CBCT scans from participant, age was between 20 to 69 years. Subjects were assigned to one of three age categories:

Group A - 20–34 years

Group B - 35–59 years, and

Group C - 60–69 years.

## **ARMAMENTARIUM:**

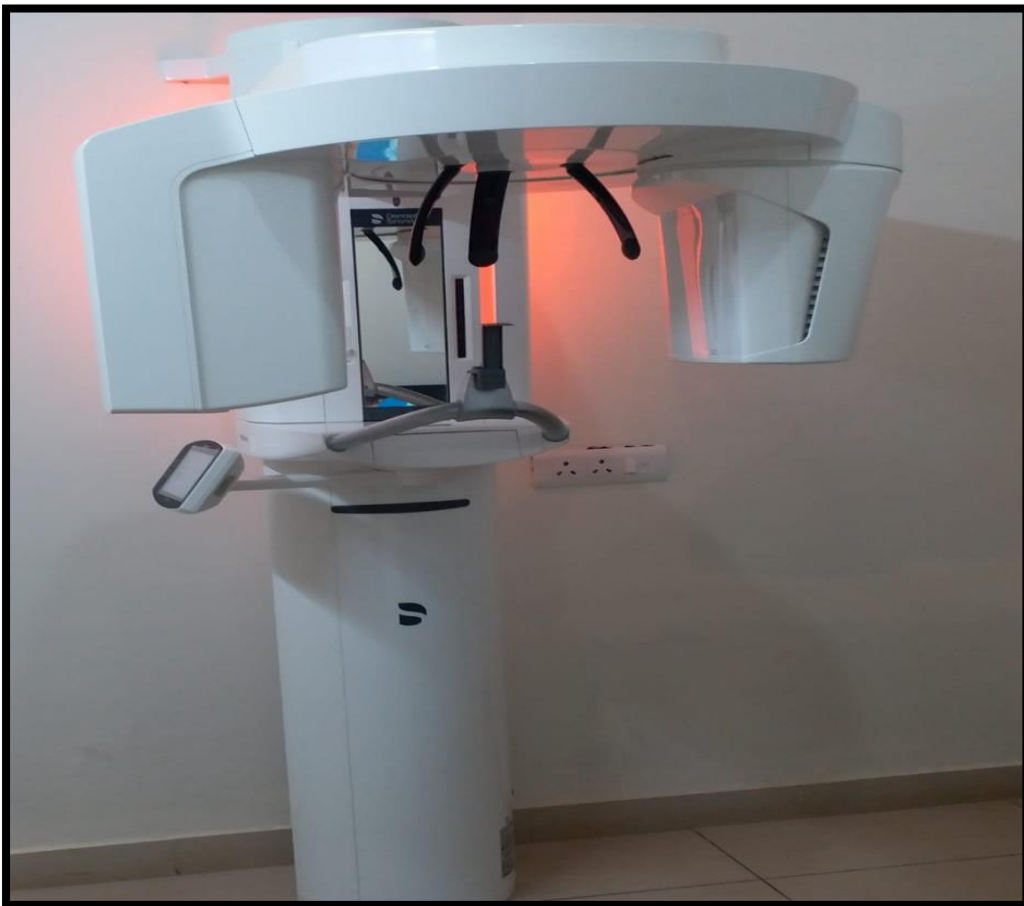- A. 100 scans of maxilla
- B. Guide sheet outlining the parameters to be measured
- C. Electronic calliper integrated into the Sidaxis 4 implant software
- D. Dentsply Sirona Axeos machine
- E. Scoring matrix to document the observations

## **RADIOGRAPHIC TECHNIQUE:**

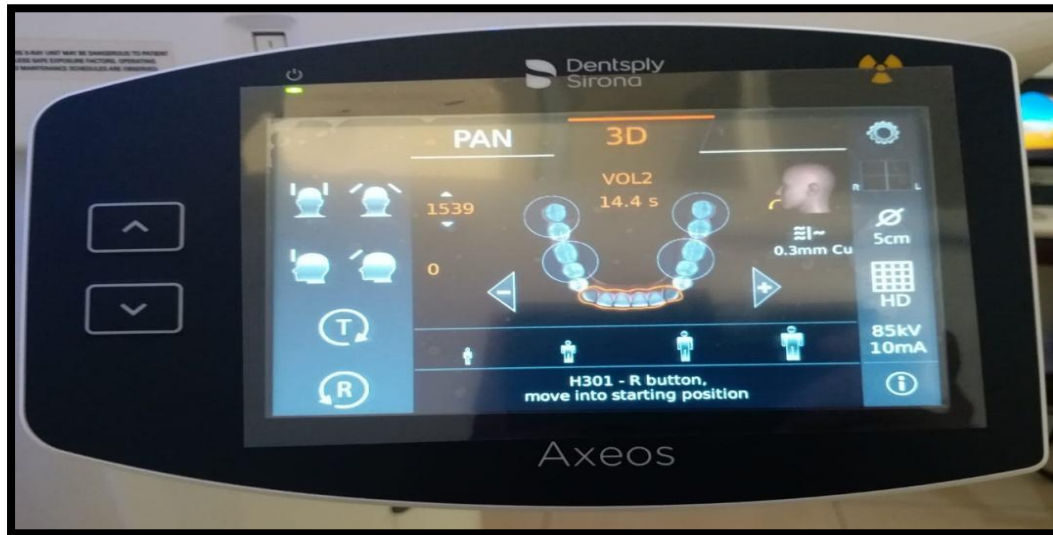
Images were obtained from Dentsply Sirona Axeos CBCT using the following parameters 5x5 cm field of view, 85 Kvp, a tube current of 10–12 mA, and a voxel size of 0.3 mm. In order to ensure that the occlusal plane was perfectly horizontal and the midsagittal plane was completely vertical, the patients were asked to remain upright during the image acquisition. A machine head support assist and system localizers were used to align the patients head. The anterior maxillary area with no pathologies, bone fracture were selected for scans and only

dentate patients were selected for scans. With a 0.3 mm slice thickness, the measurements were taken on the sagittal and axial orthogonal planes.

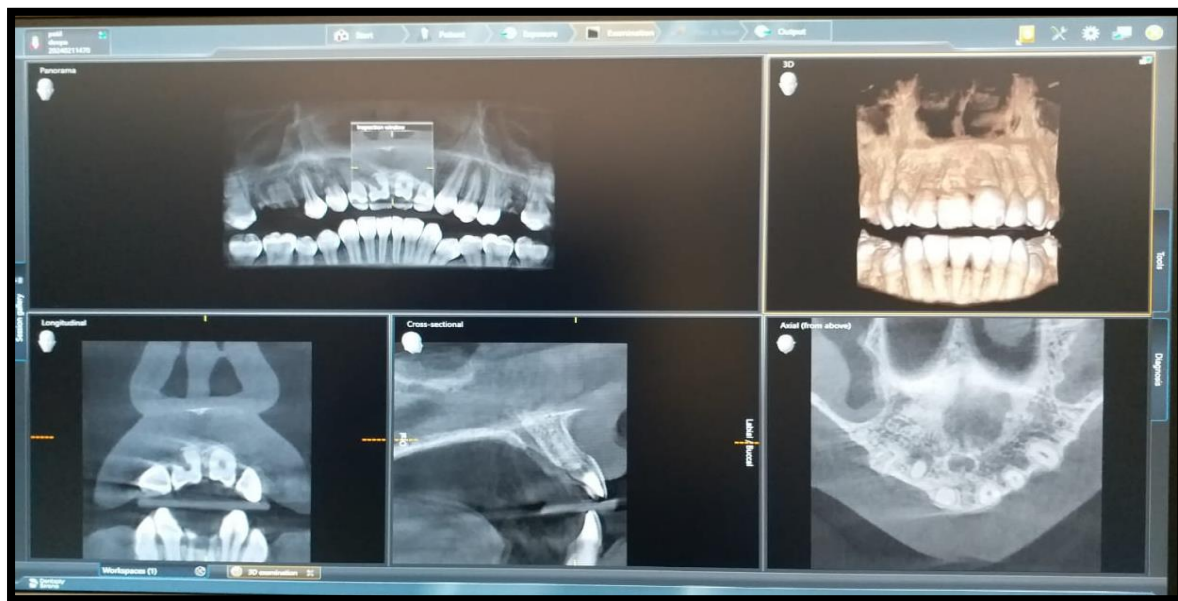
**Figure 7: CBCT machine**



**Figure 8: Control panel**



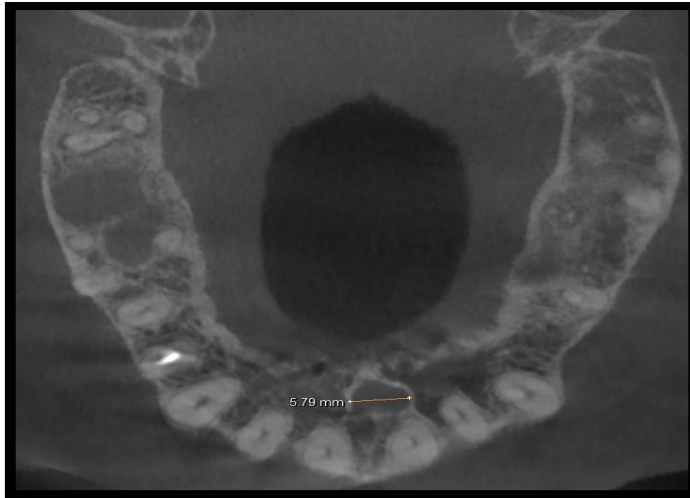
**Figure 9: Sagittal and axial orthogonal planes of CBCT used to measure parameters**



## **MEASUREMENT OF INSCIVE CANAL**

Images were viewed by the observer under the supervision of a trained maxillofacial radiologist.


## MEASUREMENT OF ORAL OPENING OF INCISIVE CANAL



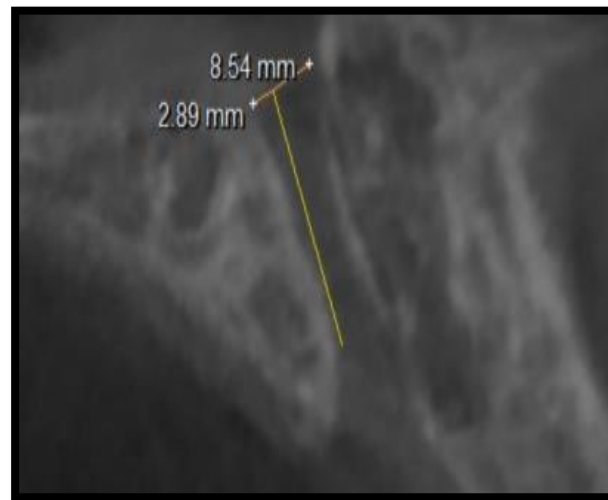
**Figure 10-showing Measurement of diameter of the nasopalatine canal, in axial section**

Measurement of mesio-distal dimensions of the incisive foramen were recorded (internal circumference) near the base of the hard palate on an axial slice (Figure 10).

**Figure 11-showing Measurement of length of the NPC, on sagittal section**

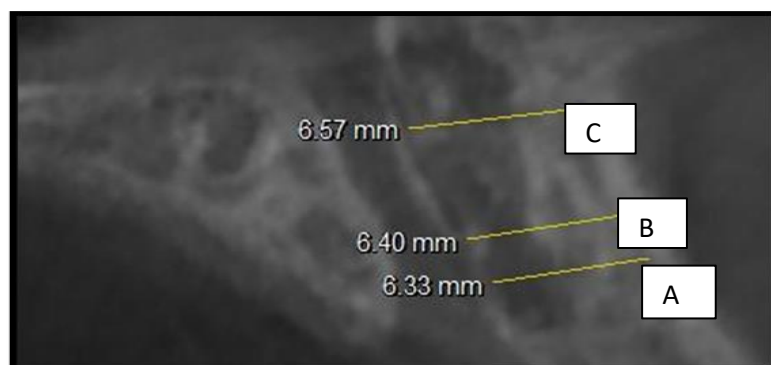


Nasal-palatine canal's length was measured using the sagittal section, as shown in Figure 11, the measurement began at the oral entry of the canal and proceeded along the curvature of the hard palate to the nasal floor.



**Figure12: Showing measurement of diameter of the Stensons foramen in sagittal section**

To figure out the buccal bone thickness in the sagittal section, three points were used: BBT1, which is in the middle of the nasopalatine canal; BBT2, which is at the cortical border level of IF on palatine bone; and BBT3, section of the alveolar bone that arises from the SF.



**Figure 13: Measurement of buccal bone thickness at level A-BBT1 level B-BBT2 at level C-BBT3**

## **DIFFERENT SHAPES OF NASOPALATINE CANAL DIFFERENT NASPALATATINE CANAL SHAPES**

Various morphologies of NPC were recorded in the sagittal Plane” of the CBCT, as illustrated below:1. Cylindrical: The walls are parallel on the labial and palatal aspects (1a).

2. Funnel: The anteroposterior dimensions increase as one moves from the rhinal passage to the anterior palate (1b)

3. Hourglass: Anteroposterior dimensions at the mid-level are smaller than those at the hard palate level (1c) and nasal fossa.

4. Cone: The mid-level anteroposterior dimension is the broadest (1d) when compared to the measurements taken at the nasal fossa to level of anterior maxillary palate. Banana: The canal's width increases along the remaining length (1e) and is narrowest at the third point in the canal.

**STATISTICAL TESTS:** SPSS 21.0 was used to enter and evaluate the data that was obtained.

- All measurements were calculated with mean and standard deviations.
- To compare the differences in measurement among males and females & gender an independent t-test was done.
- Location of incisive foramen was compared among age groups using analysis of variance (ANOVA).
- A chi-square test was used to compare the divergence in canal course and direction.

## RESULTS

Descriptive statistics was used to evaluate the age distribution of the participants among the three groups, show that although the mean age increased across all groups ( $P = 0.2550$ ), no statistically significant differences were found.

Groups		Group 1	Group 2	Group 3	Total	P-value
<b>Gender<sup>a</sup> n (%)</b>	Male	16(47.06)	21(63.64)	22 (64.71)	59(58.42)	0.2550
	Female	18(52.94)	12(36.36)	12 (35.29)	42(41.58)	
	Total	34 (100.00)	33(100.00)	34(100.00)	101(100.00)	
<b>Age (Mean ± SD)</b>		24.41 ± 4.45	46.36 ± 7.33	66.47 ± 2.74	45.74 ± 18.09	-

*Values are expressed as frequency with percentages (in parentheses) and mean ± SD (Standard Deviation); The statistical test used: <sup>a</sup>Chi-square test; Level of significance: \* $P \leq 0.05$  is considered statistically significant*

The various morphologies of incisive canal among males and females and in various age groups was observed in this study. All groups had a revealed cylindrical morphology, with group 2 showing hourglass and conical morphologies. Among various age groups, funnel-shaped canals were the least prevalent. As shown in Table 3. The statistical analysis showed no discernible variation between age group and canal form ( $P = 0.7400$ )

Shapes	Group 1 n (%)	Group 2 n (%)	Group 3 n (%)	Total n (%)	P-value
Cone	4 (11.76)	3 (9.09)	2 (5.88)	9 (8.91)	0.7400 <sup>a</sup>
Cylindrical	25 (73.53)	22 (66.67)	27 (79.41)	74 (73.27)	
Funnel	1 (2.94)	1 (3.03)	2 (5.88)	4 (3.96)	
Hour glass	4 (11.76)	7 (21.21)	3 (8.82)	14 (13.86)	
Total	34 (100.00)	33 (100.00)	34 (100.00)	101 (100.00)	

*Values are expressed as frequency with percentages (in parentheses) and mean ± SD (Standard Deviation); The statistical test used: <sup>a</sup>Chi-square test; Level of significance: \* $P \leq 0.05$  is considered statistically significant*

There is an important distinction in the distribution of forms based on gender ( $p = 0.0070$ , Chi-square = 12.1470). The most common form was cylindrical which was seen in 74.58% of males

and 71.43% of females. However, only 1.69% of men and 19.05% of females revealed a cone form, whereas remainder subjects revealed different shapes.

**Table 3 : Comparison of shape according to gender**

Shapes	Male n (%)	Female n (%)	Total N (%)	P- value
Cone	1 (1.69)	8 (19.05)	9 (8.91)	0.007*
Cylindrical	44 (74.58)	30 (71.43)	74 (73.27)	
Funnel	4 (6.78)	0 (0.00)	4 (3.96)	
Hour glass	10 (16.95)	4 (9.52)	14 (13.86)	
Total	59 (100.00)	42 (100.00)	101 (100.00)	

\*p<0.05

Gender differences were observed in the NPC with CBCT analysis. Despite results lack statistical significance (P = 0.6553 and P = 0.4386, respectively), men had bigger incisive foramina (IF) and superior foramina (SF) compared to females. Males had a much longer incisive canal on average (P = 0.001), whereas buccal bone thickness (BBT), BBT1 and BBT2 were significantly thicker in females, BBT3, showed no significant gender differences (P = 0.070, 0.6453, and 0.9789, respectively). Mean values of the observed parameters are described in the Table 5.

**Table 4: Comparison of mean SF score, IF scores, mean length, BBT 1, BBT 2 , BB3 in genders**

<b>Gender</b>	<b>Male</b>	<b>Female</b>	<b>Total</b>	<b>t value</b>	<b>P- value</b>
<b>SF score (Mean ± SD)</b>	2.52 ± 1.00	2.42 ± 1.06	2.48 ± 1.02	0.4477	0.6553
<b>IF score (Mean ± SD)</b>	3.15 ± 0.86	3.01 ± 0.95	3.09 ± 0.90	0.7778	0.4386
<b>Mean length (Mean ± SD)</b>	10.43 ± 2.52	8.15 ± 2.43	9.48 ± 2.71	4.5471	0.0001*
<b>BBT 1 (Mean ± SD)</b>	5.89 ± 1.15	5.97 ± 0.90	5.92 ± 1.05	-0.3770	0.7070
<b>BBT 2 (Mean ± SD)</b>	5.94 ± 1.27	6.04 ± 0.93	5.98 ± 1.13	-0.4617	0.6453
<b>BBT 3 (Mean ± SD)</b>	6.42 ± 1.46	6.42 ± 1.03	6.42 ± 1.29	0.0265	0.9789

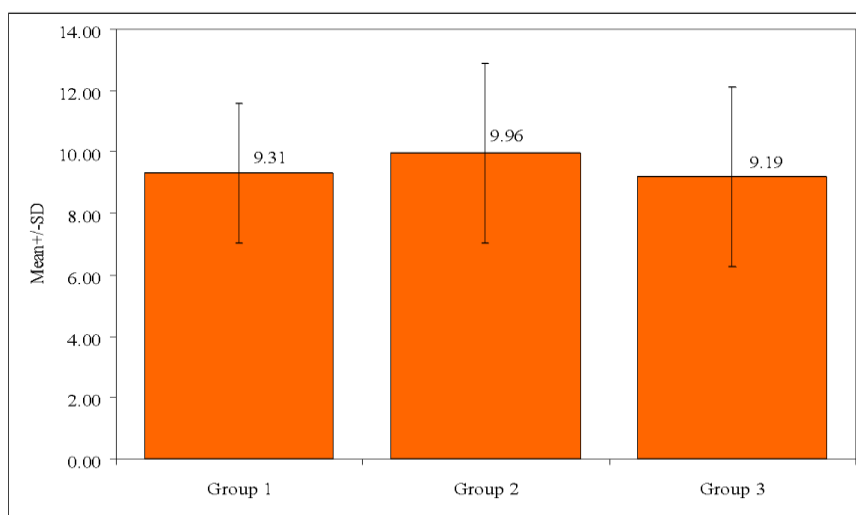
This study sought to compare buccal bone thickness (BBT), mean incisive canal length (L), (SF) and (IF) measurements among various age groups. Group ;1 SF diameter increased at a statistically significant rate ( $p = 0.0046$ ). Although results were statistically insignificant, there were dissimilarities within groups ( $p = 0.0576$  for IF and  $p = 0.4666$  for incisive canal mean length), with group 3 having the greatest IF diameter.

Furthermore, the buccal bone thickness exhibited a progressive decrease with increasing age group and statistically significant differences were observed for all three levels measured (BBT1:  $p = 0.0005$ , BBT2:  $p = 0.0001$ , and BBT3:  $p = 0.0014$ ).

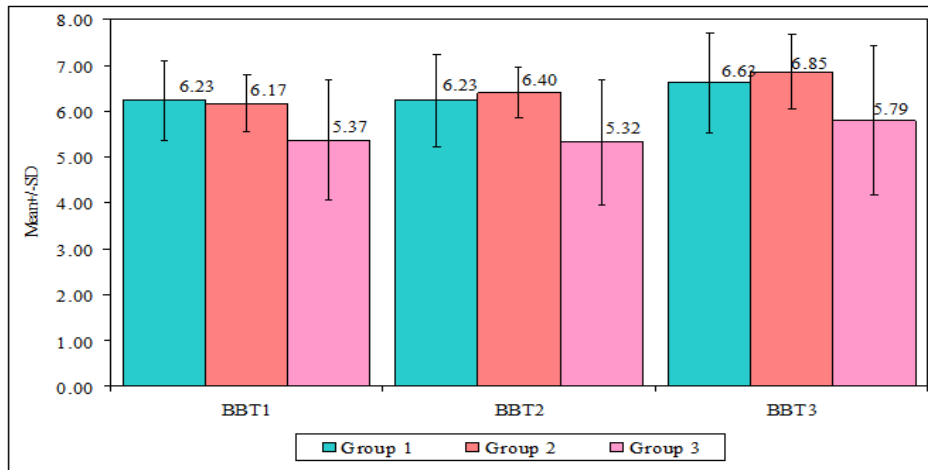
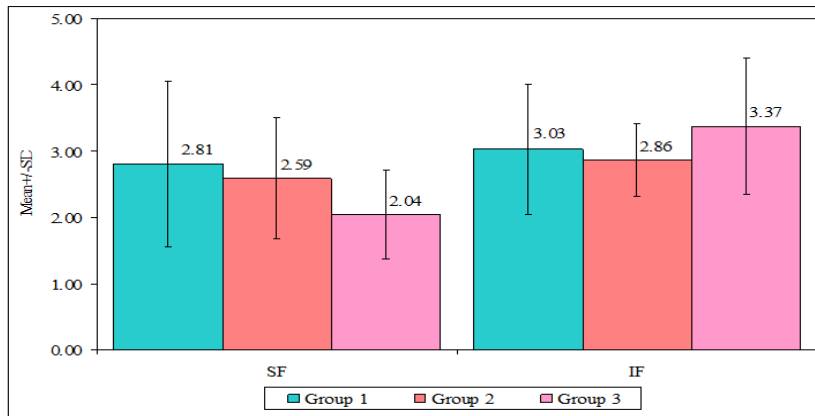
Statistically significant changes ( $p < 0.05$ ) in buccal bone thickness (BBT) were seen at all three measurement levels (BBT1, BBT2, and BBT3) when Group 3 was compared to Groups 1 and 2 using a post hoc test.

Groups	Group 1	Group 2	Group 3	Total	F value	P- value
<b>SF score (Mean ± SD)</b>	2.81 ± 1.25 <sup>γ</sup>	2.59 ± 0.92	2.04 ± 0.67 <sup>α</sup>	2.48 ± 1.02	5.6767	0.0046*
<b>IF score (Mean ± SD)</b>	3.03 ± 0.98	2.86 ± 0.55 <sup>γ</sup>	3.37 ± 1.03 <sup>β</sup>	3.09 ± 0.90	2.9386	0.0576
<b>Mean length (Mean ± SD)</b>	9.31 ± 2.27	9.96 ± 2.92	9.19 ± 2.92	9.48 ± 2.71	0.7683	0.4666
<b>BBT 1 (Mean ± SD)</b>	6.23 ± 0.86 <sup>γ</sup>	6.17 ± 0.62 <sup>γ</sup>	5.37 ±1.32 <sup>αβ</sup>	5.92 ± 1.05	8.1355	0.0005*
<b>BBT 2 (Mean ± SD)</b>	6.23 ± 1.02 <sup>γ</sup>	6.40 ± 0.55 <sup>γ</sup>	5.32 ± 1.37 <sup>αβ</sup>	5.98 ± 1.13	10.4391	0.0001*
<b>BBT 3 (Mean ± SD)</b>	6.63 ± 1.09 <sup>γ</sup>	6.85 ± 0.80 <sup>γ</sup>	5.79 ± 1.63 <sup>αβ</sup>	6.42 ± 1.29	6.9994	0.0014*

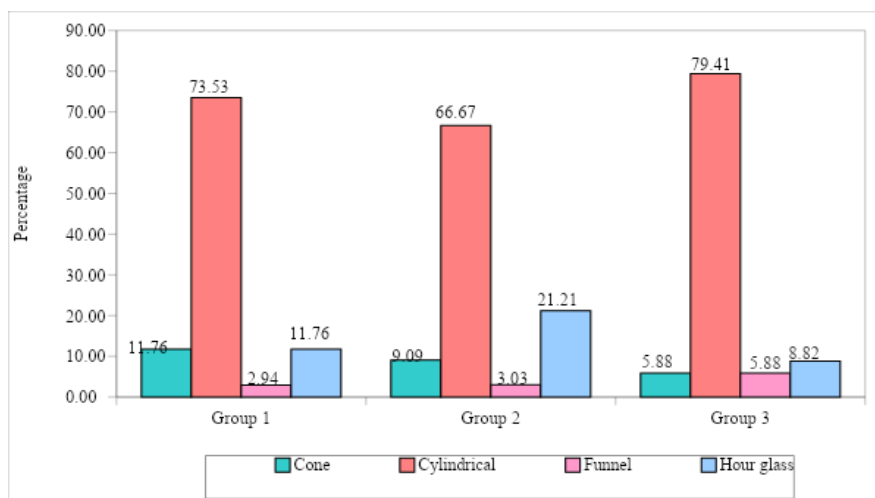
**Comparison of three groups with mean length scores**



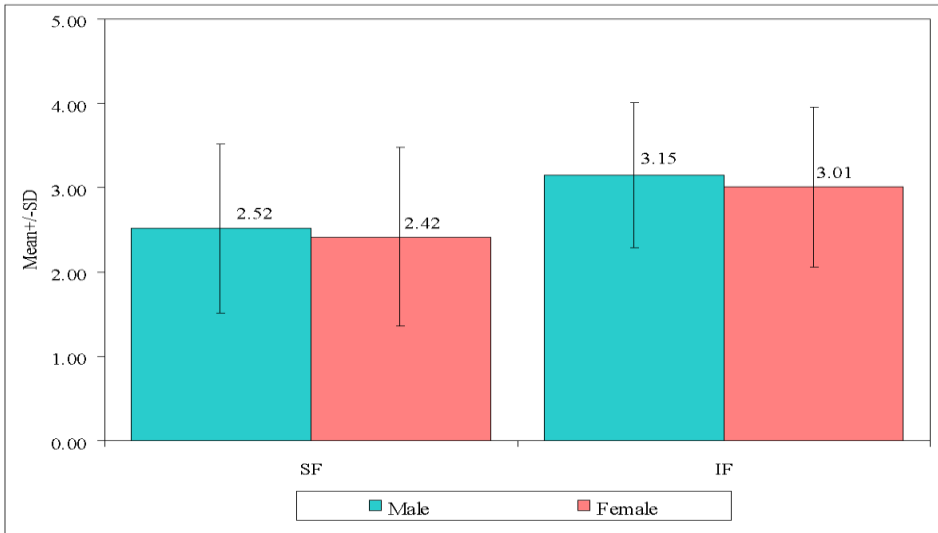
**Comparison of mean BBT1, BBT2, BBT3 with three age groups**



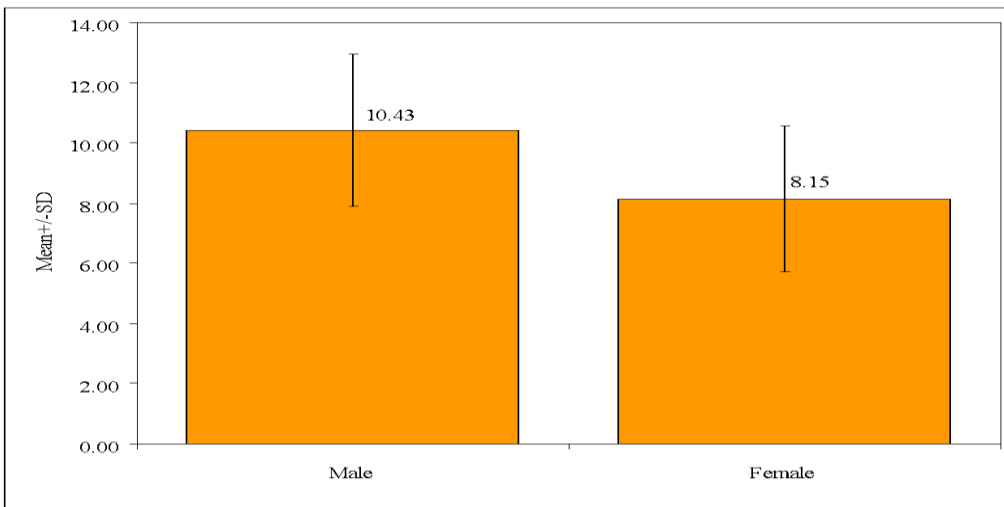
**Comparison of three groups with mean SF and IF scores**



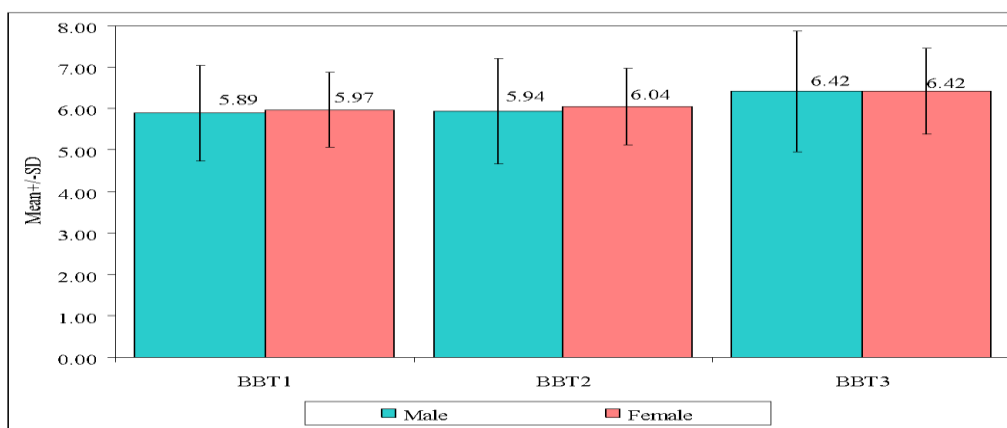
**Comparison of shape according to various age groups**



**Mean SF and IF scores of male and female**



**Mean length scores of in male and female**



**Comparing mean BBT1, BBT2 and BBT3 scores of male and female**

## DISCUSSION

In the procedures of dental treatment and maxillofacial surgeries involving premaxilla such as local sedation for invasive procedures concerning this region such as dental implant placement or apical root resection, being familiar with precise anatomical descriptions, dimensions, and the location of the NPC is vital. Surgical equipment and implants could come into contact with structures that traverse through or adjacent to the NPC as a consequence of anterior maxillary surgery. This condition could lead to poor osseointegration of implants, sensory impairment, and surgical complications.

Nasopalatine canal (NPC) vary significantly in size and shape. It has been found that the anatomy of the NPC differs among different population groups and age as well. Significance in studying these variations lies in the establishing the position and shape of NPC for performing any surgeries in the anterior maxilla or in the placement of implants <sup>[14]</sup>. Assessment of these anatomical structures preoperatively will reduce the risk of complications post-surgery such as bleeding and sensory impairment, thereby improving the quality of life of the patient [1, 12, 15].

The NPC and buccal bone thickness in the anterior maxillary region can be assessed using a variety of radiographic modalities, including computed tomography (CT) <sup>[16, 17]</sup>, micro-CT <sup>[18, 19]</sup>, multidetector computed tomography <sup>[20]</sup>, high resolution magnetic resonance imaging <sup>[21]</sup>, and cone-beam computed tomography (CBCT) <sup>[22]</sup>.

Owing to its reduced radiation dose and cost effectiveness, CBCT has become a popular imaging modality among many dental professionals for assessment of vital anatomical structures like NPC, incisive foramen (IF), and Stenson foramen (SF) [22, 23]. Hence, the present study used CBCT for assessing the NPC, IF, SF, and buccal bone thickness.

NPC morphology was compared in 3 groups with Group 1 consisted of participants aged 20–34, Group 2 of participants aged 35–59, and Group 3 of participants aged 60–69 were compared based on the NPC morphologies. The most prevalent form across all age groups was the cylindrical shape, with the second most common being the hourglass shape in Group 2. Similar percentages of people in Group 1 had NPCs shaped like cones and hourglasses (11.76%). When NPC form was compared in different age groups, no statistically significant differences was noted ( $p = 0.74$ ).

The results of this study demonstrated that there are anatomical differences in the size and form of the NPC. This study observed four different anatomical shapes: conical, cylindrical, funnel, and hourglass. The most frequent form of the canal was found to be cylindrical (73.27%), with an hourglass shape coming in a distant second (13.86%). Research by Mishra et al. (62%), Sudheer et al. (54%), and Tejasvi et al. (44%), all found similar outcomes. The findings are consistent with those of earlier research by Liang et al., [2] Mardinger et al., [5] Nassem et al., [15] Tozum et al., [27] and Fernández-Alonso et al., [28]. Contrary to this, conical and hourglass shape were comparatively more prevalent than cylindrical shape in a study carried out by Hakbilen et al., [11]. This study evaluated an average NPC length of  $9.48 \pm 2.71$  mm, with male samples having a length of  $10.43 \pm 2.52$  mm and female samples of  $8.15 \pm 2.43$  mm. This was similar to those reported by Thakur et al., [14] ( $10.96 \pm 1.99$  for males, and  $9.20 \pm 2.16$  for females, respectively), Mishra et al., [24] with mean values of 10.51 and 9.90 for males and females, respectively. Contrary to this, higher mean values of the canal were identified by Sudheer et al., [25] reported values of  $11.38 \pm 2.00$  and  $10.78 \pm 1.13$ , Magat et al., [32] with values of  $13.90 \pm 3.03$  and  $11.28 \pm 2.53$ , and Tejasvi et al., [26] with mean values of  $11.2 \pm 2.0$  and  $9.72 \pm 1.85$ , for males and females, respectively. Ridge resorption causes the canal's length to shorten. Following tooth loss from trauma or ageing, the incisive canal's length and breadth seem to vary greatly. Males often have longer and broader canals than females do. It has been proven that hormonal fluctuations cause more bone loss in women. There is evidence that bone loss happens more quickly in postmenopausal women, with decreased bone density and strength as well as altered bone architecture.

The current study found that the average IF dimension for males was  $3.15 \pm 0.86$  mm, while for females it was  $3.01 \pm 0.95$  mm, with an overall mean value of  $3.09 \pm 0.90$  mm. Similar values were obtained in research conducted by Rai et al.,<sup>[4]</sup> with mean values of  $3.21 \pm 1.03$  and  $2.83 \pm 0.85$  mm, Thakur et al.,<sup>[14]</sup> with mean values of  $3.47 \pm 0.89$  and  $3.76 \pm 0.97$  mm, Tejasvi et al.,<sup>[26]</sup> with mean values of  $2.82 \pm 0.94$  and  $2.08 \pm 0.57$ , Panda et al.,<sup>[33]</sup>  $3.62 \pm 0.77$  and  $3.61 \pm 0.80$ , respectively for males and females. On the other hand, higher values of IF were reported by Hakbilen et al,<sup>[11]</sup> with mean values of 6.21 and 6.01 for males and females, and a total value of  $6.08 \pm 1.51$  mm. The oral opening of the NPC is the incisive foramen. The NPC nerve and vessels exit through IF and supply anterior maxilla. Normal diameter of IF is less than 6mm. Diameter of IF increases following extraction of the maxillary anterior teeth due to alveolar bone resorption. If diameter is greater than 6mm pathology is suspected [8]. Additionally, the male, female, and overall samples of the SF showed mean values of  $2.52 \pm 1.00$ ,  $2.42 \pm 1.06$ , and  $2.48 \pm 1.02$ , respectively, on the dimensions. Tejasvi et al., [26] also found similar results, with an average of  $2.82 \pm 0.94$  mm for men and  $3.03 \pm 0.80$  mm for women. In contrast, a higher mean SF value of 3.54 for men, 3.47 for “females”, and 3.49 for overall samples was found by Hakbilen et al., [11]. As an alternative, Thakur et al. [14] found that the average SF for “male” was  $1.74 \pm 0.62$  mm while for females it was  $1.76 \pm 0.90$  mm.

Buccal bone thickness (BBT1) was evaluated at three separate locations in this investigation.

The present investigation found mean values of  $5.92 \pm 1.05$  mm for BBT1,  $5.98 \pm 1.13$  mm for BBT2, and  $6.42 \pm 1.29$  mm for BBT3, respectively. Contrary to what Hakbilen et al. [11] found, our data showed that BBT1 and BBT2 had lower mean values while BBT3 had a larger one ( $7.54 \pm 1.64$ mm) and  $6.41 \pm 1.64$  mm, respectively. Implant placement is always subject to anatomical constraints. Pre-operative assessment of the incisive canal region has come back into focus due to the growing necessity of Osseo integrated implant rehabilitation of the edentulous maxilla [7] [13]. It is widely

recognised that the high rate of maxillary resorption during post-extraction period may compromise the preparation of surgical osteotomy and retention of the prosthesis. The alveolar crest may approach vital anatomical structures as bone loss progresses, leading to unfavourable consequences.

Dimensions of IF, SF, NPC, and BBTs were compared between the three age groups that were included in this present study. Statistically significant differences were noted for SF dimension and BBT1, BBT2, and BBT3 thickness among included age groups. These findings suggest that differences exist between different age groups when compared to the dimensions of the assessed parameters, thereby warranting further investigation to assess age related changes.

**Limitations** of this present study include the inclusion of dentate subjects with relatively small sample size. Generalizability of these findings would be more reliable if the assessed parameters were carried out in a larger sample. It would be helpful to confirm these results in future research with a larger sample size and age group stratification. To further examine how these anatomical features change with age, longitudinal research might be undertaken.

#### **SUMMARY:**

The anterior maxilla contains the nasopalatine canal (NPC), when bone becomes diseased, it might distress the NPC. A thorough understanding of the front maxilla is necessary for surgical treatment planning. Given the considerable rise in surgical procedures in the NPC region, understanding the structural differences of the NPC is essential for prevention of injury to the neurovascular bundles.

We measured the length and diameter of the NPC at the oral and nasal openings as part of this investigation to assess typical anatomical changes of the nasopalatine canal. Also determining different shapes of NPC using CBCT. These metric variables were compared in different age groups and between male and female population.

101 CBCT scans of anterior maxilla of males and females belonging to age 20-69 years that fulfilled the inclusion and exclusion criteria were assessed for normal anatomical variations of NPC. According to the data, statistically significant increase in diameter of SF among Group 1 to Group 3 had the largest diameter of IF, and Group 2 had largest mean incisive canal. The buccal bone thickness exhibited a progressive decrease with increasing age group.

Thus it can be concluded that gender, age, and NPC's relationship to anterior maxillary teeth can all affect one another. CBCT is a well-regarded diagnostic method in the field of oral and maxillofacial imaging. CBCT may be used to evaluate the volume and topography of NPC, allowing surgeons to tailor their approaches to each patient in this delicate location.

### **CONCLUSION**

The upper central incisors are situated adjacent to the nasopalatine canal and its entrance, the IF. The neurovascular bundle within the canal may be harmed by any surgical treatment performed here. Therefore, it's essential to ascertain whether these structures have undergone any notable anthropological changes and whether such variations are relevant for forensic purposes.

According to the results of this study, which are limited in dimension, gender-based differences indeed exist since male had higher scores on the SF, IF, length of NPC, and BBT dimensions than females. The morphology of NPC also differs in males and females; however, the form is most often cylindrical. Buccal bone thickness decreases with age, indicating atrophic changes in the bone caused by aging. The results of this study highlight the need of evaluating the maxillary anterior area before surgery or implant implantation in order to avoid harm to important tissues during the procedure.

### **REFERENCES**

1. Al-Amery SM, Nambiar P, Jamaludin M, John J, Ngeow WC. Cone beam computed tomography assessment of the maxillary incisive canal and foramen: considerations of anatomical variations when placing immediate implants. *PloS one*. 2015 Feb 13;10(2):e0117251.
2. Surya LK, Patil K, Mahima VG, Sanjay CJ. The radioanatomization of the Nasopalatine canal on Cone Beam Computed Tomography—an eloquent study. *Eur J Anat*. 2023;27(3):317-30.
3. Jacobs R, Lambrichts I, Liang X, Martens W, Mraiwa N, Adriaensens P, Gelan J. Neurovascularization of the anterior jaw bones revisited using high-resolution magnetic resonance imaging. *Oral Surgery, Oral Medicine, Oral Pathology, Oral Radiology, and Endodontology*. 2007 May 1;103(5):683-93.
4. Rai S, Misra D, Misra A, Khatri M, Kidwai S, Bisla S, Jain P. Significance of morphometric and anatomic variations of nasopalatine canal on cone-beam computed tomography in anterior functional zone-A retrospective study. *Annals of Maxillofacial Surgery*. 2021 Jan;11(1):108.
5. Mardinger O, Namani-Sadan N, Chaushu G, Schwartz-Arad D. Morphologic changes of the nasopalatine canal related to dental implantation: a radiologic study in different degrees of absorbed maxillae. *Journal of periodontology*. 2008 Sep;79(9):1659-62.
6. Artzi Z, Nemcovsky CE, Bitlitum I, Segal P. Displacement of the incisive foramen in conjunction with implant placement in the anterior maxilla without jeopardizing vitality of nasopalatine nerve and vessels: a novel surgical approach. *Clinical Oral Implants Research: Novel Development*. 2000 Oct;11(5):505-10.
7. Xu D, Wang Z, Sun L, et al. Classification of the root position of the maxillary central incisors and its clinical significance in immediate implant placement. *Implant Dent*. 2016;25:520–4.

8. Lake S, Iwanaga J, Kikuta S, Oskouian RJ, Loukas M, Tubbs RS. The incisive canal: a comprehensive review. *Cureus*. 2018 Jul 30;10(7).
9. Keith DA. Phenomenon of mucous retention in the incisive canal. *Journal of oral surgery (American Dental Association: 1965)*. 1979 Nov 1;37(11):832-4.
10. Liang X, Jacobs R, Martens W, Hu Y, Adriaensens P, Quirynen M, Lambrichts I. Macro-and micro-anatomical, histological and computed tomography scan characterization of the nasopalatine canal. *Journal of clinical periodontology*. 2009 Jul;36(7):598-603.
11. Hakbilen S, Magat G. Evaluation of anatomical and morphological characteristics of the nasopalatine canal in a Turkish population by cone beam computed tomography. *Folia morphologica*. 2018;77(3):527-35.
12. Etoz M, Sisman Y. Evaluation of the nasopalatine canal and variations with cone-beam computed tomography. *Surgical and Radiologic Anatomy*. 2014 Oct;36:805-12.
13. Van der Weijden F, Dell'Acqua F, Slot DE. Alveolar bone dimensional changes of post-extraction sockets in humans: a systematic review. *Journal of clinical periodontology*. 2009 Dec;36(12):1048-58.
14. Thakur AR, Burde K, Guttal K, Naikmasur VG. Anatomy and morphology of the nasopalatine canal using cone-beam computed tomography. *Imaging Sci Dent* 2013;43:273-81.
15. Nasseh I, Aoun G, Sokhn S. Assessment of the nasopalatine canal: An anatomical study. *Acta Inform Med* 2017;25:34-8.
16. Bornstein MM, Balsiger R, Sendi P, et al. Morphology of the nasopalatine canal and dental implant surgery: a radiographic analysis of 100 consecutive patients using limited cone-beam computed tomography. *Clin Oral Implants Res*. 2011; 22(3): 295–301.

17. Mraiwa N, Jacobs R, Van Cleynenbreugel J, et al. The nasopalatine canal revisited using 2D and 3D CT imaging. *Dentomaxillofac Radiol*. 2004; 33(6): 396–402.
18. Song WC, Jo DI, Lee JY, et al. Microanatomy of the incisive canal using three-dimensional reconstruction of microCT images: an ex vivo study. *Oral Surg Oral Med Oral Pathol Oral Radiol Endod*. 2009; 108(4): 583–590.
19. Fukuda M, Matsunaga S, Odaka K, et al. Three-dimensional analysis of incisive canals in human dentulous and edentulous maxillary bones. *Int J Implant Dent*. 2015; 1(1): 12.
20. Gönül Y, Bucak A, Atalay Y, et al. MDCT evaluation of nasopalatine canal morphometry and variations: An analysis of 100 patients. *Diagn Interv Imaging*. 2016; 97(11): 1165–1172.
21. Jacobs R, Lambrechts I, Liang X, et al. Neurovascularization of the anterior jaw bones revisited using high-resolution magnetic resonance imaging. *Oral Surg Oral Med Oral Pathol Oral Radiol Endod*. 2007; 103(5): 683–693.
22. Teughels W, Merheb J, Quirynen M. Critical horizontal dimensions of interproximal and buccal bone around implants for optimal aesthetic outcomes: a systematic review. *Clin Oral Implants Res*. 2009; 20 Suppl 4: 134–145.
23. Pohlenz P, Blessmann M, Blake F, et al. Clinical indications and perspectives for intraoperative cone-beam computed tomography in oral and maxillofacial surgery. *Oral Surg Oral Med Oral Pathol Oral Radiol Endod*. 2007; 103(3): 412–417.
24. Mishra R, Thimmarasa VB, Jaju PP, Mishra R, Shrivastava A. Influence of gender and age on nasopalatine canal: A cone-beam computed tomography study. *Journal of Dental Implants*. 2017 Jan 1;7(1):15-9.
25. Sudheer A, Rani K, Kumari A, Singh AK, Anand K, Singh K. Morphological variation of the nasopalatine canal: A cone-beam computed tomography study. *Journal of Indian Academy of Oral Medicine and Radiology*. 2020 Jan 1;32(1):27-30.

26. Tejasvi MA, Devi CK, Rachel MJ, Sowmya C, Mekala MR, Reddy VK. A Retrospective Pilot Study Using Cone-Beam Computed Tomography to Assess the Morphology and Anatomy of the Nasopalatine Canal. *Journal of Indian Academy of Oral Medicine and Radiology*. 2023 Oct 1;35(4):532-6.
27. Tözüm TF, Güncü GN, Yıldırım YD, Yılmaz HG, Galindo-Moreno P, Velasco-Torres M, Al-Hezaimi K, Al-Sadhan R, Karabulut E, Wang HL. Evaluation of maxillary incisive canal characteristics related to dental implant treatment with computerized tomography: a clinical multicenter study. *Journal of periodontology*. 2012 Mar;83(3):337-43.
28. Yaser S, Mahkameh M, Sepideh R, Mahtab K, Maryam E. Assessment of nasopalatine canal anatomic variations using cone beam computed tomography in a group of Iranian population. *Iran J Radiol* 2017;14:e37028.
29. Asaumi R, Kawai T, Sato I, Yoshida S, Yosue T. Three-dimensional observations of the incisive canal and the surrounding bone using cone-beam computed tomography. *Oral Radiology*. 2010 Jun;26:20-8.
30. Panjnoush M, Norouzi H, Kheirandish Y, Shamshiri AR, Mofidi N. Evaluation of morphology and anatomical measurement of nasopalatine canal using cone beam computed tomography. *Journal of Dentistry (Tehran, Iran)*. 2016 Aug;13(4):287.
31. Fernández-Alonso A, Antonio Suárez-Quintanilla J, Muínelo-Lorenzo J, Varela-Mallou J, Smyth Chamosa E, Mercedes Suárez-Cunqueiro M. Critical anatomic region of nasopalatine canal based on tridimensional analysis: cone beam computed tomography. *Scientific reports*. 2015 Aug 6;5(1):12568.
32. Magat G, Akyuz M. Are morphological and morphometric characteristics of maxillary anterior region and nasopalatine canal related to each other?. *Oral Radiology*. 2023 Apr;39(2):372-85.

33. Panda M, Shankar T, Raut A, Dev S, Kar AK, Hota S. Cone beam computerized tomography evaluation of incisive canal and anterior maxillary bone thickness for placement of immediate implants. *The Journal of the Indian Prosthodontic Society*. 2018 Oct;18(4):356.
34. Demiralp et al, Evaluation of Anatomical and Volumetric Characteristics of the Nasopalatine Canal in Anterior Dentate and Edentulous Individuals: A CBCT Study, *Journal of Implant Dent*. 2018 Aug;27(4):474-479.
35. Lake et al. (July 30, 2018) The Incisive Canal: A Comprehensive Review. *Cureus* 10(7): e3069. DOI 10.7759/cureus.3069

ANNEXURES- I

ETHICAL CLEARANCE CERTIFICATE



Research and Ethics Committee  
KLE VK INSTITUTE OF DENTAL SCIENCES

A Constituent Unit of KLE Academy of Higher Education & Research  
Accredited 'A' Grade by NAAC Placed in Category 'A' by MHRD (GoI)

Nehru Nagar, Belagavi - 590 010, Karnataka State

☎: 0831-2470362  
FAX: 0831-2470640

Web: <http://www.kledental-bgm.edu.in>  
E-mail: [principal@kledental-bgm.edu.in](mailto:principal@kledental-bgm.edu.in)



**CERTIFICATE**

Sl. No. : 1572

EC/NEW/INST/2021/2435  
Research & Ethics Committee

*This is to Certify that the synopsis titled*

*Radiographic assessment of anatomical variation of nasopalatine canal in patient attending tertiary care centre using CBCT - A Prospective Study Submitted by Dr. SURAYYA KRESUR P. G. Student / Staff, Guided by DR. ARVIND SHETTI from Department of Oral Medicine and Radiology has been critically evaluated by committee members and granted ethical clearance to conduct the above mentioned study*

Date : 11/3/24

**Member Secretary**  
Research and Ethical Committee  
KLEVK Institute of Dental Sciences  
Belagavi  
**MEMBER SECRETARY**  
Research & Ethical Committee  
KLEVK Institute of Dental Sciences  
BELAGAVI.

**Chairman**  
Research and Ethical Committee  
KLEVK Institute of Dental Sciences  
Belagavi  
**Chairman**  
Research & Ethical Committee  
KLEVK Institute of Dental Sciences  
Belagavi

**ANNEXURES- II**  
**CONSENT FORM**

**DEPARTMENT OF ORAL MEDICINE AND RADIOLOGY**  
**KAHER'S KLE'S V.K. INSTITUTE OF DENTAL SCIENCES, BELAGAVI**  
**RADIOGRAPHIC ASSESSEMENT OF ANATOMICAL VARIATION OF NASOPALATINE**  
**CANAL IN PATIENTS ATTENDING TERTIARY CARE CENTRE**  
**PRINCIPAL INVESTIGATOR: DR. SURAYYA KIRESUR**

I, \_\_\_\_\_, aged \_\_\_\_\_ years have been informed about my involvement in the study.

- I agree to give my personal details like Name, Age, Gender, Residential Address, Previous and Present dental history and any other details if required for the study to the best of my knowledge.
- I will co-operate with the dentist.
- I will follow the instructions given by the dentist during study.
- I permit the dentist to utilize the information given and results obtained from this study for presentation and publication without disclosing my identity.
- I have understood the nature of the study and permit the dentist to collect radiographic samples.
- I will not claim any returns for co-operation in this study, even if it is being sponsored by any agency. I am participating with my own will and wish.
- In my full consciousness and presence of mind, after understanding all the procedures and related complications if any, in my vernacular language, I am willing and give my consent to participate in this study.

Date:

Address & Ph. No:

Signature:

### GROUP I (20-34 ) YEARS

Sl No	Gender/ years	SF	IF	Canal length	Shape	BBT1	BBT2	BBT3
1	M/21	4.17mm	1.06mm	10.21mm	cylindrical	7.26mm	7.31mm	8.08mm
2	F/32	1.70mm	3.40mm	13.35mm	cylindrical	6.69mm	6.43mm	7.30mm
3	F/28	4.36mm	3.37mm	10.80mm	cylindrical	4.26mm	3.68mm	3.92mm
4	F/22	2.65mm	3.33mm	12.94mm	cylindrical	6.52mm	7.20mm	7.68mm
5	F/20	3.93mm	2.98mm	7.74mm	cylindrical	4.73mm	5.08mm	5.70mm
6	M/30	4.93mm	4.27mm	13.73mm	cylindrical	4.90mm	5.34mm	5.53mm
7	F/23	4.19mm	3.16mm	12.70mm	Hourglass	4.32mm	4.66mm	4.84mm
8	F/20	4.80mm	4.88mm	6.62mm	cylindrical	4.96mm	5.64mm	5.95mm
9	F/21	4.53mm	3.70mm	10.32mm	cylindrical	5.10mm	5.16mm	5.23mm
10	F/22	2.41mm	2.99mm	5.31mm	cylindrical	8.65mm	8.29mm	8.26mm
11	M/24	2.59mm	2.60mm	9.43mm	cylindrical	5.59mm	6.49mm	7.68mm
12	M/27	2.01mm	2.25mm	6.90mm	cylindrical	5.21mm	6.44mm	5.68mm
13	F/31	1.08mm	2.86mm	10.46mm	cone	2.26mm	3.07mm	6.08mm
14	M/23	5.27mm	3.27mm	9.91mm	cylindrical	2.80mm	3.56mm	3.90mm

15	M/29	1.97mm	2.49mm	7.85mm	cylindrical	3.50mm	3.86mm	4.36mm
16	F/28	1.34mm	3.31mm	9.60mm	cylindrical	3.77mm	3.02mm	4.00mm
17	F/23	1.48mm	3.15mm	9.18mm	cone	3.64mm	3.55mm	4.32mm
18	F/21	1.14mm	1.74mm	7.83mm	cone	3.89mm	4.77mm	4.07mm
20	F/24	2.71mm	3.00mm	10.67mm	cylindrical	3.90mm	3.58mm	5.76mm
21	F/20	3.17mm	2.98mm	11.09mm	cylindrical	5.48mm	5.75mm	6.09mm
22	F/21	2.85mm	4.03mm	9.18mm	cylindrical	4.19mm	3.81mm	4.65mm
23	F/20	1.72mm	2.30mm	6.93mm	cylindrical	5.38mm	5.68mm	6.30mm
24	M/25	5.05mm	3.44mm	10.37mm	cylindrical	7.82mm	8.30mm	8.41mm
25	M/23	1.03mm	5.36mm	5.58mm	Hourglass	4.83mm	4.83mm	5.39mm
26	M/20	1.44mm	3.54mm	6.67mm	Hourglass	5.11mm	5.52mm	6.44mm
27	M/33	1.64mm	5.20mm	12.38mm	cylindrical	4.67mm	4.97mm	5.93mm
28	M/20	2.93mm	1.96mm	5.76mm	cylindrical	7.37mm	7.71mm	7.83mm
29	F/24	1.75mm	1.75mm	5.76mm	cylindrical	4.55mm	4.39mm	5.13mm
30	M/20	2.03mm	1.39mm	9.68mm	cylindrical	6.34mm	6.76mm	9.02mm
31	M/20	3.92mm	3.50mm	12.55mm	cylindrical	3.64mm	3.74mm	4.21mm
32	M/24	3.61mm	2.28mm	8.99mm	Funnel	3.59mm	2.56mm	3.35mm
33	F/23	1.25mm	3.84mm	10.68mm	cylindrical	4.07mm	4.02mm	5.07mm
34	F/34	3.68mm	3.53mm	11.23mm	cylindrical	6.09mm	6.48mm	6.53mm

### GROUP II (35-59) YEARS

Sl No	Gender /age	SF	IF	Length	shape	BBT1	BBT2	BBT3
1	M/58	1.34mm	3.02mm	14.61mm	funnel	5.33mm	5.23mm	4.56mm
2	M/48	3.99mm	3.43mm	12.1mm	hourglass	6.19mm	6.47mm	7.21mm
3	F/39	4.08mm	2.63mm	7.81mm	cylindrical	5.26mm	5.32mm	5.00mm
4	F/47	2.61mm	1.87mm	11.22mm	cylindrical	7.47mm	7.84mm	8.91mm
5	M/47	3.74mm	3.56mm	7.32mm	cylindrical	5.74mm	6.11mm	6.77mm
6	M/39	1.84mm	2.45mm	9.21mm	cylindrical	3.81mm	3.72mm	3.70mm
7	M/43	2.31mm	3.25mm	13.56mm	cylindrical	5.40mm	5.33mm	4.65mm
8	M/49	3.12mm	2.88mm	9.53mm	cylindrical	4.12mm	5.50mm	6.22mm
9	F/53	5.14mm	2.20mm	13.46mm	cylindrical	6.73mm	7.20mm	7.55mm
10	F/55	3.19mm	2.60mm	11.28mm	Cylindrical	5.59mm	6.49mm	7.68mm
11	M/54	1.56mm	2.59mm	13.36mm	Hourglass	4.05mm	4.29mm	4.30mm
12	M/55	2.69mm	2.93mm	12.74mm	Cylindrical	3.07mm	3.85mm	4.94mm
13	F/41	3.00mm	4.00mm	7.43mm	Cylindrical	5.24mm	4.61mm	6.92mm

14	M/45	1.93mm	3.15mm	10.25mm	Hourglass	3.98mm	4.31mm	4.44mm
15	F/49	1.63mm	3.79mm	7.77mm	Cylindrical	3.96mm	4.03mm	4.75mm
16	F/57	3.49mm	3.42mm	8.01mm	funnel	4.24mm	5.55mm	6.21mm
17	M/55	1.94mm	2.94mm	13.33mm	Cylindrical	4.66mm	4.44mm	4.72mm
18	F/55	1.71mm	2.59mm	6.51mm	Cylindrical	6.80mm	6.74mm	6.99mm
19	M/50	3.70mm	3.42mm	6.51mm	Cylindrical	5.96mm	6.29mm	6.57mm
20	F/45	2.46mm	2.25mm	7.83mm	Cylindrical	3.68mm	3.74mm	5.43mm
21	M/40	2.52mm	2.95mm	7.15mm	Cylindrical	5.52mm	5.37mm	5.78mm
22	M/46	3.37mm	3.37mm	8.53mm	Cylindrical	6.56mm	7.29mm	8.53mm
23	F/40	1.78mm	2.84mm	11.09mm	Cylindrical	5.25mm	5.27mm	6.14mm
24	M/44	2.51mm	2.90mm	7.45mm	Cylindrical	5.35mm	5.42mm	5.68mm
25	M/41	1.95mm	2.85mm	10.42mm	Cylindrical	5.35mm	5.14mm	5.65mm
26	M/42	4.05mm	2.45mm	13.76mm	Cylindrical	6.39mm	6.90mm	6.90mm
27	F/56	3.31mm	3.34mm	12.23mm	hourglass	4.50mm	4.89mm	3.25mm
28	F/39	2.68mm	2.54mm	9.10mm	Cylindrical	6.45mm	6.97mm	6.75mm
29	M/50	3.65mm	3.50mm	8.51mm	Hourglass	6.96mm	6.29mm	6.40mm
30	M/57	2.49mm	4.19mm	7.16mm	Cylindrical	5.35mm	5.41mm	5.23mm
31	F/43	3.72mm	3.34mm	10.72mm	Cylindrical	4.34mm	4.55mm	5.21mm
32	F/55	1.71mm	2.59mm	6.51mm	Cylindrical	6.80mm	6.74mm	6.99mm
33	M/54	3.70mm	3.24mm	9.72mm	Cylindrical	5.60mm	5.20mm	5.50mm
34	F/56	2.71mm	3.59mm	12.42mm	Cylindrical	5.23mm	5.35mm	5.50mm

### GROUP 3 (59-69) YEARS

Sl No	Gender / Age	SF	IF	Length	Shape	BBT1	BBT2	BBT3
1	M/68	2.81m m	4.48m m	7.22mm	cylindrical	4.71m m	3.27m m	4.47m m
2	F/65	1.38m m	3.82m m	8.07mm	cylindrical	5.07m m	5.08m m	5.98m m
3	M/66	1.42m m	3 .97mm	12.59mm	Funnel	4.11m m	3.52m m	2.72m m
4	F/69	1.51m m	1.35m m	3.91mm	cylindrical	5.73m m	5.54m m	4.98m m
5	M/69	1.94m m	2.51m m	12.59mm	cylindrical	4.11m m	3.52m m	2.72m m
6	M/60	2.09m m	2.50m m	15.52mm	cylindrical	5.63m m	4.96m m	5.15m m
7	M/69	2.35m m	3.98m m	10.31mm	cylindrical	3.35m m	3.88m m	4.77m m
8	M/65	2.30m m	2.93m m	13.61mm	cylindrical	6.03m m	6.01m m	6.39m m
9	M/67	1.97m m	4.28m m	5.86mm	cylindrical	5.61m m	5.77m m	6.15m m
10	F/66	1.81m m	2.44m m	7.89mm	Hourglass	4.46m m	4.54m m	4.22m m
12	M/63	1.64m m	2.02m m	5.78mm	cylindrical	4.62m m	5.31m m	6.56m m
13	F/62	1.63m m	2.09m m	7.81mm	cylindrical	4.64m m	4.93m m	6.31m m

14	F/67	1.15m m	2.39m m	6.51mm	cylindrical	5.87m m	6.01m m	4.70m m
15	M/68	2.71m m	2.82m m	10.62mm	cylindrical	4.53m m	3.96m m	3.20m m
16	M/64	1.80m m	2.72m m	8.71mm	cylindrical	6.52m m	7.12m m	7.94m m
17	F/69	1.29m m	2.56m m	8.26mm	cylindrical	6.20m m	6.90m m	8.26m m
18	M/63	2.11m m	3.83m m	7.30mm	cylindrical	7.01m m	6.95m m	8.41m m
19	M/64	0.99m m	2.53m m	4.44mm	Cylindrica l	6.07m m	6.50m m	6.25m m
20	M/69	2.96m m	2.68m m	7.24mm	Cylindrica l	6.43m m	7.67m m	7.51m m
21	M/69	1.44m m	4.17m m	7.68mm	Cylindrica l	8.38m m	6.76m m	7.68m m
22	M/65	1.21m m	2.67m m	6.81mm	hourglass	4.52m m	5.18m m	5.99m m
23	F/63	2.72m m	3.53m m	15.75mm m	Cylindrica l	4.81m m	4.81m m	4.67m m
24	M/65	1.71m m	3.30m m	10.57mm	Cylindrica l	4.72m m	4.80m m	4.82m m
25	M/66	2.09m m	4.31m m	6.98mm	Cylindrica l	5.49m m	6.02m m	7.16m m
26	M/67	2.27m m	3.68m m	11.02mm	Cylindrica l	7.73m m	7.26m m	7.95m m
27	M/69	2.76m m	3.53m m	11.34mm	hourglass	2.65m m	3.12m m	3.22m m
28	M/68	1.78m m	3.21m m	9.37mm	Cylindrica l	6.43m m	6.09m m	6.54m m

29	M/64	3.47m m	1.96m m	5.27mm	Cylindrica l	6.47m m	5.81m m	6.56m m
30	F/69	1.98m m	4.41m m	5.19mm	Cylindrica l	3.47m m	3.06m m	3.81m m
31	M/61	3.82m m	3.44m m	12.72mm	Cylindrica l	5.73m m	5.30m m	6.50m m
32	M/69	2.59m m	4.24m m	8.16mm	Cylindrica l	5.65m m	5.91m m	5.32m m
33	M/63	1.38m m	4.35m m	10.88mm	Cylindrica l	3.41m m	3.39m m	6.69m m