

INTRODUCTION

Lateral epicondylitis was previously thought as having an inflammatory etiology. The current consensus is that, it is because of micro-tears at the beginning of extensor carpi radialis brevis¹. Micro-tears may also be observed involving the origins of the tendons of extensor digitorum and extensor carpi radialis longus¹. Lateral epicondylitis is one of the common musculoskeletal condition distressing the upper limb occurring in 1-3% of the common population².

Lateral epicondylitis has an incidence of 4-7 persons per 1000 general population per year, and highest age ranges between 35-54 years. Thus approximate mean age was 42 years^{3,4,5}. With respect to gender prevalence various results have been published in the literature, however no significant prevalence is evident^{5,6}. Lateral epicondylitis affects dominant arm more frequent than non dominant. An epidemiologic study reported which shows an actual rate of 87% of the lateral epicondylitis cases involving the dominant arm⁷.

The patient with tennis elbow present with complains of discomfort at the starting point of ECRB[Extensor carpi radialis brevis] tendon. The pain and tenderness at the lateral epicondyle is the characteristic presentation of tennis elbow. Tenderness is present over midpoint and 5mm distal to lateral epicondyle¹. Lateral epicondylitis is extremely common these days due to active lifestyle and have been reported to be the consequence of overdo, predominantly of the dominant hand. Though lateral epicondylitis is called tennis elbow, it commonly affects people not involved in sports activity than those involved in excess physical activity like sports^{8,9}.

Pathophysiology has many controversies and there is not sufficient scientific evidence for definitive method of treatment for tennis elbow. In 1873 this condition first reported by Runge, after that 30 other conditions have been explained as causes. Some of the studies have proposed that few individuals may have a genetic tendency to develop tennis elbow. Although it is narrated as an inflammatory pathology, the present agreement is that lateral epicondylitis begins as a micro-tears in ECRB[extensor carpi radialis brevis] tendon. Undeveloped reparative tissue seen in microscopic examination, that make one think of angiofibroblastic hyperplasia¹.

Lateral epicondylitis is treated either operatively or non operatively. Non-operative treatment modalities like rest, injections, ice and physical therapy with ultrasound therapy, transcutaneous electrical stimulation and etc¹.

Most conservative modalities like one or two local corticosteroid injections at an area of highest tenderness have an aim on suppressing inflammatory process that surprisingly is not present. In short term outcomes statistically significant difference was shown with corticosteroid injection when compared with local anaesthetics, placebo and other conservative treatment¹⁰. While in long term and intermediate term there is no statistically important difference observed with corticosteroid injection. Hence effectiveness of local steroid injection will not show a firm inference in lateral epicondylitis management^{11,12,13}. In recent studies platelet rich plasma injection has been reported to be effective in both long term and intermediate term outcome and noticed that there is sufficient decrease in pain. Platelet procure growth factor is a mitogen which stimulates chemotactic polypeptides and fibroblastic mitosis like transforming growth factor cause migration of fibroblast and leads to angiogenesis. A healing in tendinosis promoted by humoral mediated immunity. Stem cell recruitment

activated by growth factors, increase local blood supply by increasing vascularity and stimulate fibroblasts of tendon sheath for collagen synthesis¹⁴.

The reason Platelet rich plasma was selected was (1) Minimal trauma at application site (2) Possibility of immune-mediated non-acceptance are reduced (3) Not related with complications like skin atrophy, tendon tears and hypoglycemia.

To consider platelet rich plasma as treatment modality of lateral epicondylitis there are only few studies. The potency of platelet rich plasma is compared with local corticosteroid injection.

Principal motive of this dissertation is to assess the role and effectiveness of platelet rich plasma in tennis elbow by using regional corticosteroid injection as comparison group.

OBJECTIVE

To compare the efficacy of Platelet Rich Plasma with corticosteroid in treatment of lateral epicondylitis / tennis elbow

REVIEW OF LITERATURE

Lateral epicondylitis as a clinical entity was initially narrated in 1873 and was attributed to extended use of arm in writing¹⁵. Later, symptoms of lateral epicondylitis in workers in a variety of occupations including carpenters, plumbers, violinists etc were documented.

In 1982, tennis elbow was attributed as sprain in the pronator radii due to aggressive backstroke whereby the forearm is bring into quick and forceful pronation¹⁶.

In 1936, it was described as a state, the signs and symptoms of which are 25 persistent as those of lateral epicondylitis. The pathology of lateral epicondylitis is mysterious. There are 26 different pathological causes documented, concluding that the data is overpowering in favour of a distinctive tennis elbow caused mainly by damage between the tendinous origin of the ECRB from the lateral epicondyle periosteum¹⁷. This view was later supported by other study in 1979¹⁸.

A study in 1955, stated that the orbicular ligament pathological changes was the important cause for the symptoms and signs of lateral epicondylitis and proposed a surgery to increase linear measurement of the ECRB as a surgical relief¹⁹.

A study in 1973 gave specific examples of force overload (due to an ineffective lever system the elbow has a mechanical predisposition to force overload) at the elbow causing lateral epicondylitis. They were: 1) Intrinsic overload could result from insufficient forearm extensor strength and stamina to withstand the force positioned on the forearm 2) Extrinsic overload from insufficient forearm extensor

elasticity and 3) Extrinsic and intrinsic overload due to overpowering moments of force or duplication in an individual with reasonable muscle flexibility, strength and endurance²⁰.

In 1979, a study mentioned 88 surgical elbows were connected with tennis players and golf players[in the non-dominant arm] with diagnosis lateral epicondylitis, but it might occurs people who do not play tennis²¹.

"Overuse" was defined in 1990 as the intensity of rhythmic micro trauma adequate to overpower the tissues ability to acclimatize, hence leading to injury²².

In 1990, a report directed to the Industrial Injuries Advisory Council echoed these views and stated "The source and natural history of tennis elbow are still topic for speculation"²³.

In 1993, a study reported that the eventual reason of lateral epicondylitis is a mixture of the time interval and overall strength of limb use. It is identified as the common extensor origin pathology, specifically the ECRB, as the most frequently implicated structure responsible for lateral epicondylitis²⁴.

In 1993 a study describing 63 surgical elbow cases, in 57 patients the extensor origin was grossly normal. There was vascular growth in 46%, mucin like substance disintegration in 27% and no documentation of inflammatory effect. Unstructured white steroid material was found in 5 patients²⁵.

More recently in 2002, a study observed "Lateral epicondylitis as a universal situation that has been broadly researched however not yet completely understood. It is not easy to assertively decide the site of pathology causing pain". Changes in

extensor digitorum muscle were responsible for tennis elbow and noted positive Maudsley's test²⁶.

In a randomized control trial study by Varshney A & Maheshwari R et al. in 2017 on 83 patients to evaluate the role of autologous platelet rich plasma versus corticosteroid in the management of lateral epicondylitis, concluded that single injection of autologous platelet rich plasma improved pain and function more than steroid in case of elbow epicondylitis and these improvements were sustained over a long period of time with no complications²⁷.

In a multicenter randomized controlled trial study by Mishra AK & Skrepnik NV et al. in 2013 on 230 patients to determine the clinical significance of tendon provoking by needling with platelet rich plasma in lateral epicondylitis patient compared with an active control group, they found that there was remarkable improvements in clinical outcome in a group treated with leukocyte-enriched platelet rich plasma when compared with an active control group²⁸.

In a multicenter randomized controlled trial study by Kaux JF & Crielaard JM in 2013 concluded that PRP may signify a fresh curative choice for chronic tendinopathies. Platelets discharge a variety of growth factors and cytokines that supports neovascularization and healing of wound.

Through their study Choudhury S & de La Lama M et al. concluded that PRP therapy for lateral epicondylitis improves the extensor tendon morphology as seen by ultrasonographic assessment of vascularity after PRP injection³⁰.

According to Campbell's Operative Orthopedics, nowadays PRP is more efficacious than injection of corticosteroid in the treatment of lateral epicondylitis³¹.

Mishra A & Pavelko T concluded that treatment of tennis elbow with buffered platelet rich plasma reduces the pain significantly in patients with tennis elbow & further it should be considered before surgical intervention³².

According to Harrington's surveillance case definitions published in 1998, the main symptom is pain in the region of lateral epicondyle which radiates into forearm with the predominant sign being tenderness 1.0 cm distal to lateral epicondyle³³.

Although originally described as inflammatory process much controversy has been there over the treatment and pathophysiology of this disorder. Accepted theory is that there are microscopic or large enough to visible by naked eye (macroscopic) tears in the ECRB and other extensor tendon^{34,35}.

Microscopic finding demonstrate immature tissue that resemble angiofibroblastic hyperplasia²¹.

In a randomized control trial conducted by Tonks and colleagues in 2007, comparing the potency of physiotherapy alone, steroid injection therapy alone, and steroid injection and physiotherapy combined. They concluded that steroid injection resulted in a statistically significant reduction in pain at follow-up and there was no statistically significant effect of physiotherapy alone or physiotherapy and injection³⁶.

Relevant Anatomy³⁷:

Elbow joint is a synovial joint including two articulations, namely the humero-ulnar and humero-radial joints. The humero-ulnar and humero-radial joints form complex hinge joint and enable flexion-extension of the forearm.

Humero-ulnar joint:

It is a complex hinge joint and is continuous with two pivot joints i.e humero-radial and proximal radio-ulnar joint.

Articulating surfaces:

Humeral distal part has two articulating surfaces: trochlea and capitulum. Trochlea is asymmetric, with a longer medial flange. Joint plane being 2cm away from the inter-epicondylar line and it is tilted infero-medially. Flexion-extension arc of elbow movement is not a simple hinge.

The trochlear notch is predominantly concave in transverse plane and in antero-posterior plane it is convex. Bare area between olecranon and coronoid areas of trochlear notch is devoid of hyaline cartilage but is covered by fibro fatty tissue and synovium.

The humerus is reciprocally convex with the concavity of the radial head articulating surface. Prominent head of the radius rests on the furrow between the trochlea and capitulum . The contact between the capitulum and the radial head is maximal when elbow is in half flexion and the mid-pronation condition of forearm.

Fibrous capsule:

Fibrous capsule is slender and broad anteriorly. The capsule is attached to humerus superior to the coronoid and radial fossae, and front of medial epicondyle. Distally it joins ulnar coronoid process and the orbicular ligament. The capsule is thinner posterior with relation to triceps brachii tendon and anconeus tendon. It joined proximally to capitulum of the humerus, the posterior surface of olecranon fossa and medial epicondyle. Except for the lowest portion, the entire olecranon fossa has a capsular attachment. Inero-medially, capsule reaches the lateral and superior border of olecranon. Laterally attaches deep to the orbicular ligament, it is continuous with the superior radio-ulnar capsule.

Bursa that lies inbetween of the capsule of elbow and triceps insertion is acknowledged as olecranon bursa

Ligaments:

Ulnar collateral ligament:

Triangular ligament has thick inferior, anterior and superior bands that connected by thinner tissue. Anterior band is stiffest and strongest that joins to the humerus medial epicondyle over anterior aspect and it has broad base that attaches to a proximal tubercle on the conoids medial border. The anterior band provides strength to the joint by being taut great extent of flexion. Posterior band of ulnar collateral ligament becomes taut between 90 degree and full flexion at the elbow. The anterior and posterior bands are that runs on either side of the olecranon and coronoid processes which is joined by inferior oblique band.

Radial collateral ligament:

It joins orbicular ligament to lateral epicondyle . This ligament merges with the bony attachments of supinator and ECRB. It is stretched during flexion and responsible for strength of the joint.

Synovial membrane:

Extends from the articular border of the humerus, coronoid lines, olecranon fossae and radius, the flat area of the trochlea(medially), the downward plane of the elbow capsule and the distal area of annular ligament.

Vascular supply:

The articular arteries of elbow joint are derived from numerous small periarticular anastomoses.

Innervations:

Posterior aspect of ulna is supplied by the ulnar nerve and medial cutaneous nerve of forearm. Anterior aspect of ulna is supplied by the median and musculocutaneous nerves. The radial posterior part is solely supplied by the radial nerve and the radial anterior part is by both radial and musculocutaneous nerves.

Movements:

Flexion and extension:

Elbow joint has relatively stable semi-congruent articular surfaces that are assisted by strong static and dynamic stabilizers which allow a flexion-extension arc of approximately 150 degree. In an extended and supinated elbow, the forearm forms

a carrying angle of approximately 17 degree with the humerus. It exists because the medial edge of the trochlear projects distally by 6.0 mm and due to the superior articular surface of the coronoid being oblique. In flexion when the humerus and ulna are in same plane, the carrying angle is not present. In pronation of the extended forearm there is lining up of the arm, forearm and hand masking the carrying angle.

Pronation and supination:

Movements at the humero-radial, proximal and distal radio-ulnar joints pronate and supinate the hand. During pronation, radius bone turns over the ulnar in oblique direction and antero-medial direction. Proximal portion of radius lies lateral to the ulna while its distal end lies medially and the interosseous membrane becomes spiralled. During supination, radius bone falls back to its original location, parallel and lateral to the ulna and the interosseous membrane unwinds. With the elbow extended, the hand can be twisted through 140-150 degree and this can be improved to virtually 360 degree by humeral rotary motion and actions of the scapula.

Muscles producing movements at elbow joint:

Flexion: brachialis, biceps brachii and brachioradialis are the flexors.

Other flexors are pronator teres, longus and brevis, flexor carpi radialis and ulnaris and extensor carpi radialis .

Extension: anconeus and triceps brachii.

Pronation: pronator quadratus aids in pronation and pronator teres against resistance.

Supination: Supinator muscle acts as supinator in extension, while biceps helps in supination in flexed position.

Pathophysiology-

Acute injuries of tendon were usually due to trauma.

Tendinosis is due to disruption of tendon internal structures, which occur as a cause of micro traumatic condition in the tendon. Usually this injury seen in chronic overuse

Tendons which participate in ballistic performance and locomotion, transmit loads under eccentric conditions and are elastic are vulnerable to injury. Tendon which pass two joints, scant vascular supply and those which are involved in repetitive movement are susceptible to chronic overuse injury^{38, 39,40,41,42}.

Repetitive small injury leads to further tendon degeneration. Chronic overuse injuries are due to micro-traumatic episodes occurring multiple times. This leads to tendon internal structure disruption and cells and matrix degeneration, leading to tendinosis.

Demonstration reveals that the early lesion is because of hypoxic degeneration process than inflammatory, which can be normal part of aging or to reaction of stress of overwork or overuse⁴³. It has been also postulated that a partial healing cascade indicated by fibrous and vascular proliferation happen in the place of less vascularity. Tendon intra-substance proliferates, leads to degeneration in the poorly vascularised area with histology showing cellular atrophy, diminished protein synthesis and formation of cyst⁴⁴. As the degenerated area enlarges the tendon weakens and eventually micro rupture which initiate the classic inflammatory response and healing cascade.

Tendinosis is not completely understood. Even though the term tendinitis is used often indiscriminately and frequently, histopathology finding from the overuse tendon site do not contain large number of macrophage, neutrophil or lymphocytes^{38,43,45}. Few authors have explained tendinosis as a degenerative sequence and few as immature repair of tendon^{32,38,45,46,47,48,49,50}. This findings has been termed angiofibroblastic hyperplasia. Though it is called so, but it is due to tendon fail to heal after repetitive microtrauma.

In lateral epicondylitis, origin of extensor carpi radialis is the chief site of injury and it is consistently associated with pathological changes^{43, 51,52,53}. Histopathological studies have described that lateral epicondylitis is not because of inflammation; preferably, it is a vascular response and fibroblastic changes hence called angiofibroblastic degeneration, now it is called as tendinosis⁵⁴. Therefore, the condition tendinitis and epicondylitis are misnomers⁵¹. Although it is commonly hypothesize that any painful structure that is inflamed, connective-tissue pain can be recognized by the patient as the result of nociception and a noxious chemical environment³⁸.

Gross examination of that region characteristically shows greyish, gelatinous, friable immature scar tissue that appears edematous and shiny.

Microscopy-

In normal tendon microscopy, collagen is arranged in long axis of the tendon and collagen bundles are parallel to each other and uniform. The matrix contains mainly glycosaminoglycans, water and proteoglycans. There is visible vascular structure in the tendon.

One of the study described an invasion of round cells, fibroblasts and vessel tufts as being pathognomonic of epicondylitis⁵³.

"Tendinosis" can be described as break in orderly arrangement of fibers of tendon with invasion of fibroblast and atypical granulation tissue^{51,54}. It is also described as focal hyaline degeneration with immature reparative process⁴³.

ELECTRON MICROSCOPY

Fibroblast on examination in electron microscopy shows open nuclear chromatin, large quantity producton of collagen at periphery of the cell, fibroblast and contractile elements. Fibroblasts seen are of two types in this condition: Those without contractile elements within cell and those with them. Fibroblasts of both types had fatty vacuolation and lysosomes with abundant endoplasmic reticulum^{55,45}.

The progressive stages with micro trauma in lateral epicondyle tendinosis are-

Stage-I inflammatory probably due to injury, there is no associated pathological alterations and usually resolve.

Stage-II injury is linked with pathological changes like angiofibroblastic degeneration or tendinosis.

Stage-III injury that is related with total structural failure or rupture and pathological changes or tendinosis .

Stage-IV injury which manifest the character of a stage-I or II injury and is related with other changes like fibrosis, calcification of soft tissue and bony hard calcification. Stage-IV injury also linked to the use of cortisone⁵⁶.

Clinical Presentation:

Patient complains of lateral elbow region and forearm pain that increases on activity. Symptoms typical present in a woman or man aged 30-55 years who either one who engages in rigorous daily activities and is a recreational athlete.

Classically, tennis elbow patient complains of pain over the lateral epicondyle. The pain often extends into the dorsal forearm, it may also extend proximally. It increases by gripping and lifting. The patient gives a history of pain that can be elicited with simple activities of daily living such as lifting pots and pans or gripping a container of water.

The single most important diagnostic finding is the location and reproducibility of pain^{57,58}. Upon examination, in the area of the ECRB muscle the patient has a maximal point of tenderness i.e. just distal to 5mm to 10mm of lateral epicondyle.

A number of clinical tests have been suggested for the evaluation of Tennis elbow of which Cozen's test and Mill's manoeuvre are the commonest to be practiced.

Chair raise test- Patient stands behind the chair and try to lift the chair by putting hand on back of the chair, patient who has tennis elbow complains of pain in lateral elbow region.

Cozen's test- When patient makes firm fist ask him to passively flex the wrist, patient with lateral epicondylitis complains of pain in lateral elbow region.

Mill's manoeuvre- Ask patient to keeps elbow straight, wrist flexed in pronated forearm, this initiates pain in lateral epicondylar region.

Chair test- Ask patient to get up from chair by keeping both of his or her hand over arms of the chair, that induces pain in lateral epicondylar region.

Jug Test-Ask patient to lift jug full of water that produces pain in lateral epicondylar region.

Wringing Test: When patient wring a towel; pain is felt at lateral epicondylar region.

Diagnosis

Diagnosis is based on clinical tests and further investigations are usually done only to rule out when other pathologies are suspected.

Imaging Studies: whenever necessary

Radiographs to rule out intra articular pathology like osteophyte and osteochondral loose body and calcification in ECRB muscle origin.

Magnetic resonance imaging (MRI) help to check degenerative pathology in ECRB muscle. On MRI sequences it shows smooth well defined uniform structure. Low to intermediate signal change is seen in early stage on T1 weighted image. T2 weighted sequences shows increase signal with fat suppression cystic changes seen in late stages.

Ultrasonography (USG) shows calcification in the common extensor tendon, thickening of tendon, adjacent bone irregularity, focal hypoechoic regions in the tendon and diffuse tendon heterogeneity.

Other Tests:

When suspecting neural pathology by clinical examination, electromyography (EMG) can be helpful to rule out posterior interosseous nerve compression syndrome.

On injection of local anaesthetic at the origin of ECRB muscle, there will be relief in pain which help in confirming diagnosis.

DIFFERENTIAL DIAGNOSIS

Differential diagnosis of this condition is to include other conditions that can produce pain in this general vicinity like, radial tunnel syndrome, osteochondritis dissecans of the capitellum (Panner's disease), lateral compartment arthrosis, varus instability and cervical radiculopathy.

Treatment

Lateral epicondylitis can be taken care either surgically or non-surgically. The different treatment modalities act by decreasing inflammation, altering biomechanics and at regenerating tendinopathy⁶¹. Non-operative treatment is successful in 95% of patients⁶². Most cases of the lateral epicondylitis are managed conservatively^{63,64}.

Non-operative treatment like avoid work[rest], local ice application, local injections and using ultrasound physical therapy, electrical stimulation, manipulation, mobilization of soft tissue, stretching, bracing counterforce and friction massage.

Old studies have shown good results for ESWL[extracorporeal shock wave lithotripsy], but conflicting results were found with recent studies. In one study there was no difference between treatment with forearm stretching alone and forearm

stretching combined with ESWL⁶². A double-blind, randomized, placebo-controlled trial found that ESWL was not productive in reducing pain or improving function⁶².

In some patients, one to two steroid injections to the location of maximum tenderness is discovered to be helpful. In some patient beneficial results were obtained with autologous whole blood injection. PRP[platelet rich plasma] local injections have reported to have better results than local corticosteroid injections in improving function and relieving pain. A recent systematic review reported that PRP injection and autologous blood injection both may improve pain but more number of complication are associated with autologous whole blood injection⁶². A direct comparison of PRP injections (28 patients) and surgery (50 patients) for recalcitrant tennis elbow found equal results⁶². A controlled randomized clinical trial determined that two ultrasound guided PRP injections were not potent than saline injections⁶². From the current literature, no firm conclusions can be made about the potency of PRP or autologous whole blood injections or the superiority of one method over the other.

Operative treatment is thought of only with failure of conservative methods for 6-12 months^{36,62}. Most commonly used techniques are-

- Intra articular- Boyd, McLeod procedure and Almquist procedure (anconeus interposition).
- Extra articular- Debridement, excision, lengthening of ECRB and reattachment⁶⁵.
- Open fasciotomy and release of extensor aponuerosis.
- Percutaneous lateral release of extensor origin.
- Lateral epicondylectomy.
- Arthroscopic release.

In 1991 one study concluded "Corticosteroid has only short duration potency in case of tennis elbow"⁶⁶.

A systematic review done in 1992, to assess the potency of different treatments for lateral epicondylitis. The study contained five (randomized) clinical tests on injection of corticosteroid reported between year 1966 to 1990 in English. Due to poor standard of procedure and the conflicting results, they came to a conclusion that there is insufficient scientific proof for any specific way of treatment for tennis elbow⁶⁷.

In 1996 methodical analysis of effectiveness and consequence of RCT of injections of corticosteroid for tennis elbow was done. Pain score was used to assess outcome of treatment. Pooled analysis was applicable only while checking outcome in short term (2to6 weeks). At more than 6week follow up, no difference between other treatment and injection of corticosteroid was found. No inference could be made concerning the most appropriate corticosteroid, injection volume, dose and interval between injection⁶⁸.

In 1999, a RCT conducted in more than one centre on 164 individuals with a new onset of tennis elbow, evaluating oral non-steroidal anti-inflammatory (NSAID), analgesics and corticosteroid injection. At 4 weeks, 82% of patients were "better" in the corticosteroid group when compared with 48% in NSAIDS and 50% in other pain relieving group. But after one year of the study, same results were obtained in all the groups⁶⁹.

In one study which conducted in 2002 came to inference that for short duration results (>6 weeks), injection of corticosteroid compared with placebo,

statistically remarkable and clinically applicable differences were seen on global improvement ,pain and grip strength for local anaesthetic and conservative treatment. For long-term or intermediate term follow-up there is no important effects were found. More, better study, conducted and published RCTs with long-term and intermediate duration follow-up are needed⁷⁰.

A study in 2006 concluded that corticosteroid injection provided good results at 6 weeks. In long term, poor outcomes were seen compared to physiotherapy or wait and see policy so they were not significantly different from each other⁷¹.

Intratendinous injection of corticosteroid injection causes unfavourable effects on the movement and structural properties of tendons noted in animal studies. Formation of adhesions and granulation is inhibited by corticosteroid injection so that it reduces the bulk of the tendon which reduces the quantity of load and biomechanical integrity^{72,73}. The consequence of corticosteroid injection around the tendon on human tendon rupture after local corticosteroid injection are common and have been noted in many case reports^{74,75}.

Side effects are associated with injection of corticosteroid. One in 17 soft tissue or intra-articular steroid injection are associated with Sepsis⁷⁶. Additional side effects are post injection pain (11-58%). In 17to 40 percentage, local skin shrinkage or atrophy, facial flushing, flare post injection site, hyperglycemia and hypersensitivity reactions^{20,62,70,75,77}. Resuscitation equipments should be accessible if patients have a severe reaction⁷⁷.

Contraindications to corticosteroid injection for soft tissue lesions^{77,78}.

- Young patients
- Systemic infection or local infection
- Tendon tear
- Coagulopathy

In 2003 study was conducted on 28 people cured with conservative treatment. The study established 79%(22 of 28) of the tennis elbow patients had a diminish in pain intensity within 9.5 months subsequent to autologous blood infiltration. More often, this happened after single injection. One of the hypothesis is activation of transforming growth factors, fibroblastic mitosis and chemo-attractant polypeptides through mitogens like as platelet derived growth factor which results in angiogenesis. Hence healing sequence in tendinosis is stimulated by specific humoral mediator^{79,80}.

Another study explained that there was gross reduction in pain in patient of tennis elbow after injecting muffled platelet rich plasma. One hundred and fourty patients with elbow pain due to tennis elbow were evaluated. 20 patients underwent surgery for pain relief. These patients then underwent one percutaneous injection of PRP or bupivacaine anus (control group). At 8 weeks after therapy, the authors demonstrated 60% pain improvement while the control group demonstrated 16% pain improvement. At six months and at the last follow-up (mean 25.6 months), the group who had received the platelet-rich plasma continued to report significant reduction in pain⁸¹.

Clinical outcomes are better with sonography guided blood injection and that has been useful to assess changes in common extensor origin⁸².

MATERIALS AND METHODS:

One year Randomized case-control study was done in Department Of Orthopaedics at the KLE'S Dr. Prabhakar Kore hospital & MRC, Belagavi.

Patients belonged to age group of 30 -55 years of either sex presenting to the out patient department of orthopaedics with typical features of lateral epicondylitis / tennis elbow of either limb were included.

30 cases in each of the two categories who are fulfilling the Inclusion/Exclusion criteria were selected. These patients were subjected to either platelet rich plasma or corticosteroid injection. Outcomes were measured using VAS score and NIRSCHL staging.

Source of data:

The 30-55years patients age group, of either sex presenting to the out patient department of orthopaedics with typical features of lateral epicondylitis/ tennis elbow of either limb.

Method of collection of data:

a. Study design : A Randomized Control Trial

A randomization coding system derived from a computer generated randomization table was followed. After a proper clinical diagnosis patient were selected into two groups according to randomization table.

b. Study Period: The study was conducted from January 2018 to December 2018.

c. Sample size - It was a hospital based study of 30 cases in each of the two categories who are fulfilling the Inclusion/Exclusion criteria.

Mean difference =44.1-56.3=12.2

$$SD= \frac{16.2+17.7}{2} = 16.95$$

$$n= \frac{2(Z_{\alpha} + Z_{\beta})^2 \times S^2}{d^2}$$
$$= \frac{2(1.96+0.84)^2 \times 16.95^2}{12.2^2}$$

= 30 in each group

Sample will be collected from January 2018 to December 2018.

(d) Selection criteria:

Inclusion criteria:

1. Patients of either sex presenting with typical symptoms of lateral epicondylitis with patient diagnosed clinically as suffering from Lateral epicondylitis.
2. Patients belonging to age group of 30-55 years.

Exclusion criteria:

1. Patients more than 55 years or less than 30 years old.

2. Other causes leading pain in lateral elbow such as osteochondritis dissecans, crystal arthropathies, like gout, radial tunnel syndrome, cervical lesions, shoulder pathology and rheumatoid arthritis.
3. Already patient treated with local steroid injection.
4. Already patient undergone surgical intervention.
5. Injection site local skin pathology.

(e) Procedure:

- Ethical clearance obtained from the institutional ethical review board.
- The purpose of the study was explained and written or informed consent will be obtained from all the participants.
- The subjects were selected based on inclusion and exclusion criteria.
- Study will be conducted over a period of 1 year.
- Once the patients signed the informed consent .History and examination was recorded as per the proforma. Patient with typical symptoms of lateral epicondylitis with patient diagnosed clinically as suffering from Lateral epicondylitis..
- The patients were randomized into two groups according to the randomization software. First group of patients was given autologous PRP and the second group was given 1.0 ml of steroid triamcinolone.
- The site of injection was 5 mm distal to the lateral epicondyle in the extensor tendons, particularly extensor carpi radialis brevis tendon.
- The skin was painted with povidone-iodine and ethyl alcohol. One ml of 2% lignocaine with adrenaline was injected at the injection site after giving test dose.

- After 10 mins, the proposed injection was injected. The injection was given in and around the tendon and not inside the tendon. If any resistance was felt during the injection, the needle is withdrawn a bit and again injected.
- Patients were advised regarding post injection care. The pain might increase during initial 2 weeks which was explained to the patient. Paracetamol was prescribed for pain relief
- Patients were advised for rest during initial 2 weeks in the form of refraining from strenuous activities by the upper extremity under study after the injection. Bilateral cases were injected simultaneously, and the post injection protocol was same.
- Procedure to be done under aseptic precautions with antibiotic cover.
- Follow ups to be done at 2 weeks, 6 weeks, 3months and 6 months.
- The results were recorded by visual analogue scale (VAS) score and NIRSCHL staging. The scores were recorded in the prepared proforma on the day of injection before giving the injection, then after 2weeks, 6weeks, 12weeks and after 24 weeks.
- The results were analyzed using nonparametric tests such as Kruskal–Wallis test and Mann–Whitney U test. After giving injection, patients were given paracetamol for the initial pain relief in all the two groups.

Preparation of platelet rich plasma:

- 15 mL of patient's blood was obtained by drawing blood through a vein.
- The PRP was prepared using differential centrifugation technique with two spins.
- The blood was collected in three citrate tubes having 0.9% sodium citrate as anticoagulant. The first spin was performed at 1500 rpm for 15 min using

laboratory centrifuge. This spin separated the red blood cells from the rest of the components.

- The upper half of the supernatant was discarded. The lower halves of the supernatant from all the three tubes are transferred into another plain tube for the second spin. The second spin was performed at 2500 rpm for 10 mins.
- The upper half of the supernatant was discarded. One ml of lower half was taken into a 1 mL syringe having 0.1 mL of calcium chloride.
- At the end of preparation of platelet rich plasma the samples were sent for platelet count and the count compared with patient's platelet count.

Outcome measured using VAS and NIRSCHL staging of lateral epicondylitis

PAIN SCORE:

Visual Analogue Score:

It consists 10 centimeters line striking with one end has worst pain ever and the other end with no pain. Ask where the pain belongs to in that line. Numerical value given where the patient mark on the scale from the no pain to worst pain ever.

No pain 1—2—3—4—5—6—7—8—9—10 Worst pain ever

NIRSCHL STAGING

Phase I: After exercise patient complains minimal pain, within 24hrs pain resolve

Phase II: After exercise complains pain, pain exceeds 48hrs

phase III: Pain with exercise activity, does not alter activity

phase IV: Pain with exercise activity, pain alters the activity

phase V: At rest intermittent pain, light pain with light activity

Phase VI: Pain even at the rest, disturbed sleep

Statistical analysis :

Outcomes were analysed using SPSS program.

Data was computed by statistical methods.

Method of Statistical data analysis:

1. Mean
2. Standard deviation
3. t-test
4. Mann whitney test

RESULTS

This study was performed on 60 patients. Patients were examined with pre-procedure VAS score and NIRSCHL staging. Cases were treated with platelet rich plasma and controls with corticosteroid. Patients were followed-up at 2 weeks, 6 weeks, 12 weeks and 6 months. Analgesics were prescribed for severe pain.

Table 1: Mean Age distribution in both the groups.

	Group				P value
	CORTICOSTEROID		PLATELET RICH PLASMA		
	Mean (years)	Standard Deviation (years)	Mean (years)	Standard Deviation (years)	
Age	43.50	5.35	44.5	5.32	0.471

The mean age in this study was 43.5 years for corticosteroid group and 44.5 years for platelet rich plasma group

P value = 0.47, was not significant. Thus age of patients in both groups was comparable.

Figure 1: Graph wise distribution of Age in both the groups

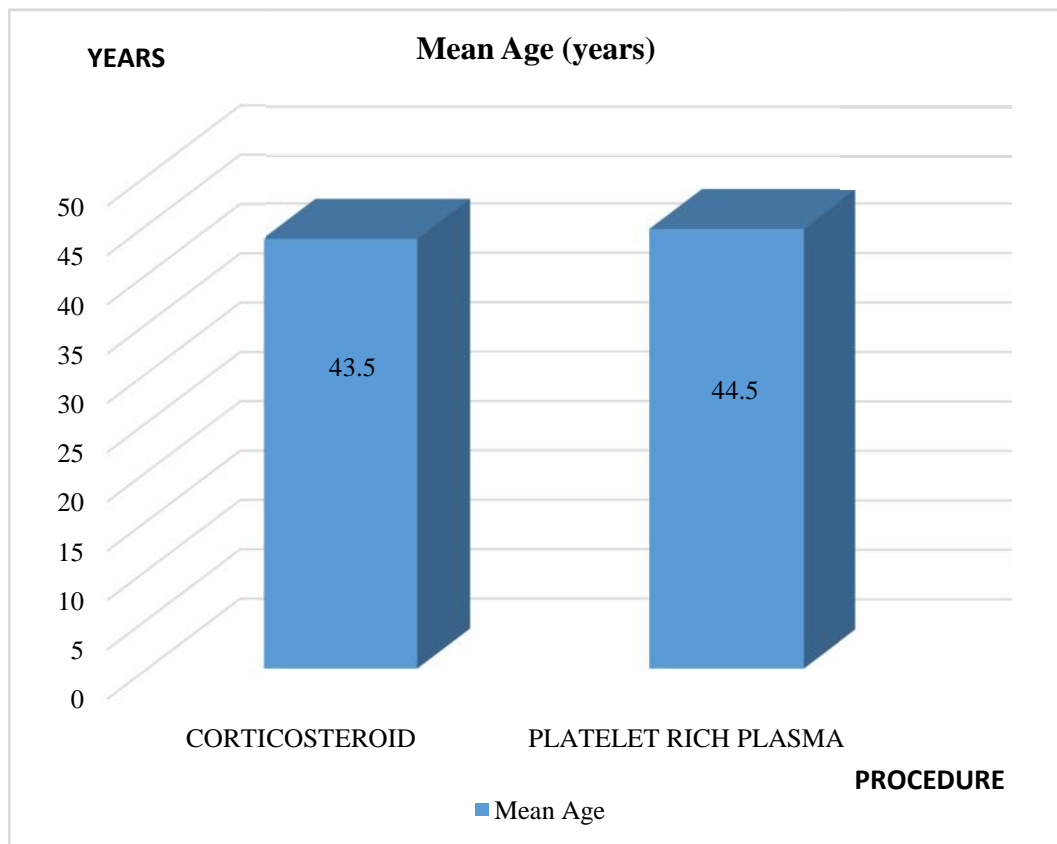


Table 2: Distribution of study subjects based on Age.

		Group				P value
		CORTICOSTEROID		PLATELET RICH PLASMA		
		Frequency	%	Frequency	%	
Age Group	Between 30-40 Years	11	36.7%	11	36.7%	Chi square = 0.000 P=1.00
	Between 41- 50 Years	16	53.3%	16	53.3%	
	More than 50 Years	3	10.0%	3	10.0%	

In our study most common age group affected was between 41 to 50 years.

Table 3: Distribution of study subjects based on gender.

		Group				P value
		CORTICOSTEROID		PLATELET RICH PLASMA		
		Frequency	%	Frequency	%	
Sex	Female	14	46.7%	15	50%	Chi square = 0.67 P= 0.796
	Male	16	53.3%	15	50%	

Out of 60 patients, 29 were females and 31 were males.

In corticosteroid group, 14 were females and 16 were males.

In platelet rich plasma group, 15 were females and 15 males.

P value = 0.796, which is not significant. Thus both the groups are comparable.

Figure 2 : Graph wise distribution of Gender in both the groups.

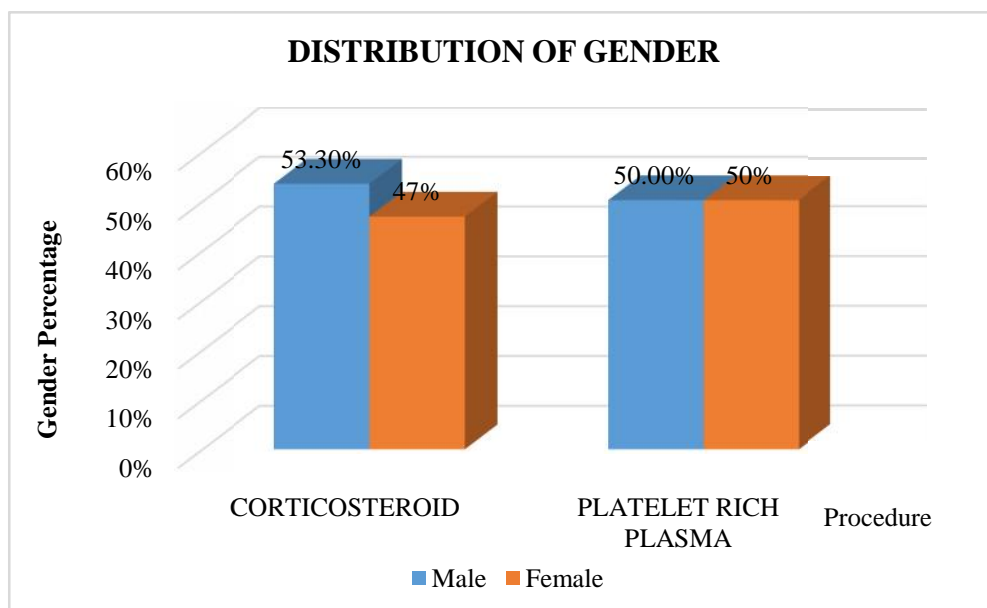


Table 4 : Distribution of study subjects based on the side involved.

		group				P value
		CORTICOSTEROID		PLATELET RICH PLASMA		
		Frequency	%	Frequency	%	
Side	Left	9	30.0%	11	36.7%	Chi square = 0.300 P= 0.584
	Right	21	70.0%	19	63.3%	

Out of 60 patients, 40 patients had their right side involved and 20 had their left side involved.

P value = 0.584, which is not significant. Thus both groups were comparable in terms of side.

Figure 3 : Graph wise distribution of side involved in both the groups.

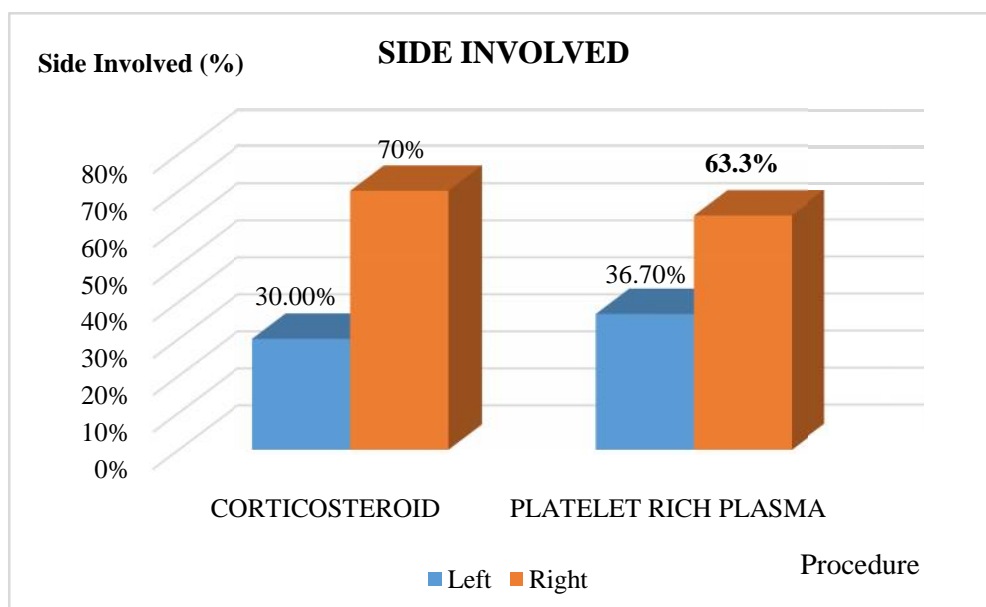


Table 5 : Distribution of Study subjects based on dominance of elbow involved.

		Group				P value
		CORTICOSTEROID		PLATELET RICH PLASMA		
		Frequency	%	Frequency	%	
Dominance	Dominant	27	90.0%	26	86.7%	Chi square = 0.162 P= 0.688
	Non Dominant	3	10.0%	4	13.3%	

Out of 60 patients, 53 patients had their dominant side involved and 7 had their non dominant side involved.

P value = 0.688, which is not significant. Thus both groups were comparable in terms of side.

Figure 4: Graph wise distribution of study subjects based on Dominance of elbow involved.

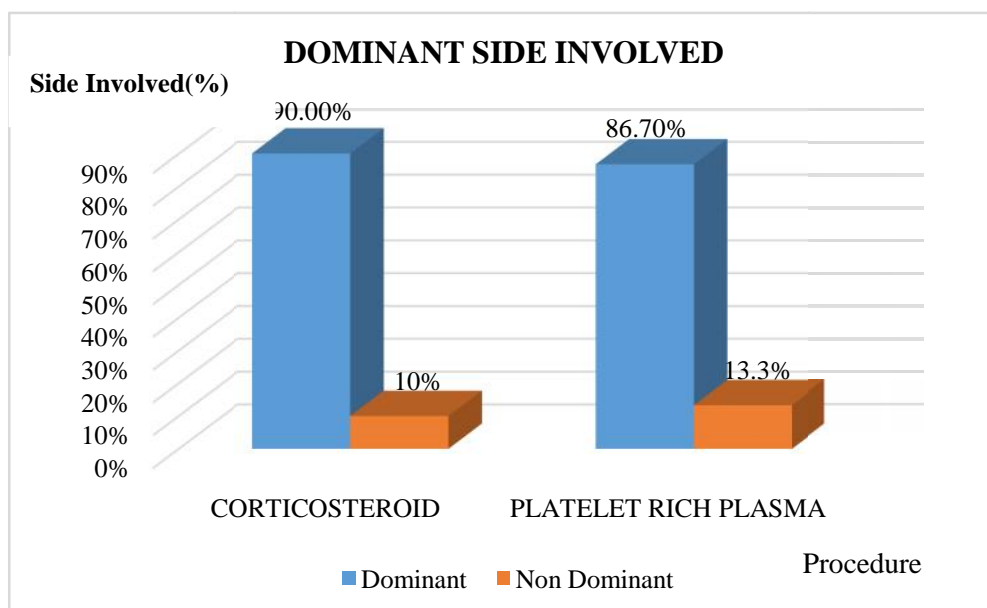


Table 6: Comparison of duration of condition in both the groups.

	Group				P value
	CORTICOSTEROID		PLATELET RICH PLASMA		
	Mean	Standard Deviation	Mean	Standard Deviation	
Duration of condition (wks)	6.53	2.24	6.57	2.30	0.955

The mean duration of the condition in corticosteroid group was 6.53.

The mean duration of the condition in platelet rich plasma group was 6.57.

P value = 0.955, which is not significant. Thus both the groups were comparable.

Figure 5 : Graph wise distribution of Study subjects based on Duration of the condition.

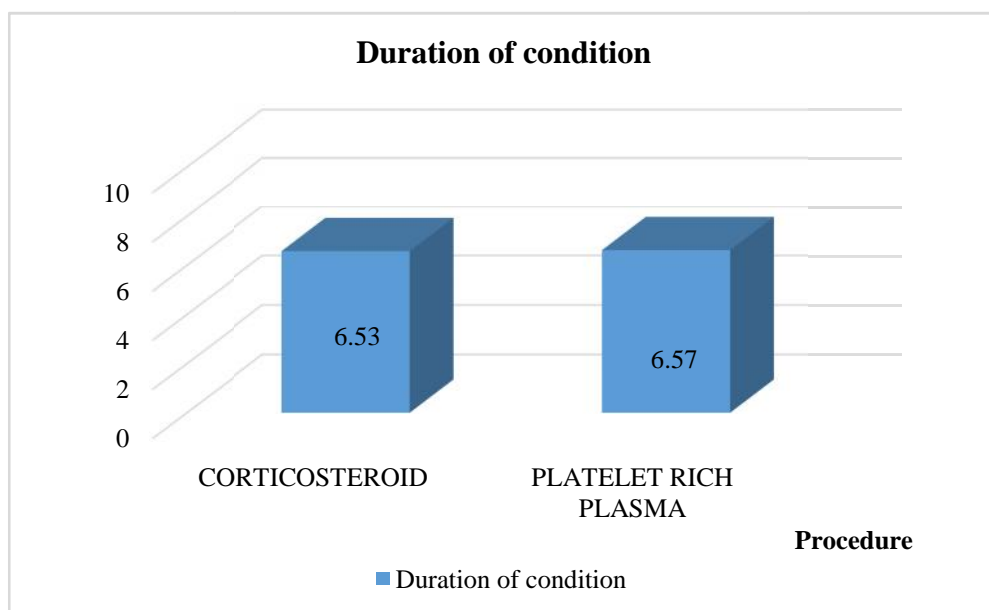


Table 7 : VAS Score and NIRSCHL staging at the time of Presentation in both the groups.

	Group						P value
	CORTICOSTEROID			PLATELET RICH PLASMA			
	Mean	Standard Deviation	Median	Mean	Standard Deviation	Median	
VAS score @ Presentation	8.07	1.01	8.00	8.07	0.98	8.00	0.938
NIRSCHL score @ Presentation	6.03	0.85	6.00	6.00	0.91	6.00	0.950

P value for VAS score was 0.938 and for NIRSCHL staging was 0.950, which are statistically not significant. Hence the outcome values are comparable.

Figure 6: Graph wise distribution of mean VAS score and NIRSCHL staging score at presentation.

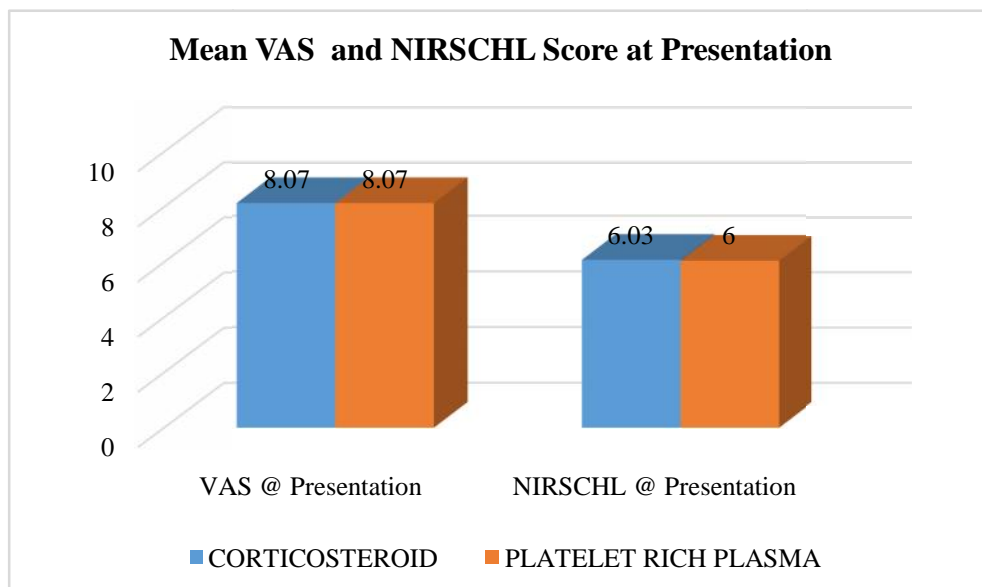


Table 8 : VAS score and NIRSCHL staging after 2 weeks of Injection in both the groups.

	Group						P value
	CORTICOSTEROID			PLATELET RICH PLASMA			
	Mean	Standard Deviation	Median	Mean	Standard Deviation	Median	
VAS @ 2 weeks	5.00	1.31	5.00	6.83	1.12	7.00	0.0001
NIRSCHL @ 2weeks	3.30	0.95	3.00	4.63	1.19	5.00	0.0001

P value for VAS score at 2 weeks post-injection is 0.0001 and for NIRSCHL staging is 0.0001, which are statistically significant.

The mean VAS score and NIRSCHL staging for corticosteroid group is 5.0 and 3.3.

The mean VAS score and NIRSCHL staging for platelet rich plasma group is 6.83 and 4.63.

Thus the decrease in pain is statistically significant in corticosteroid group.

Figure 7 :Graph wise distribution of Mean VAS score and NIRSCHL staging after 2 weeks

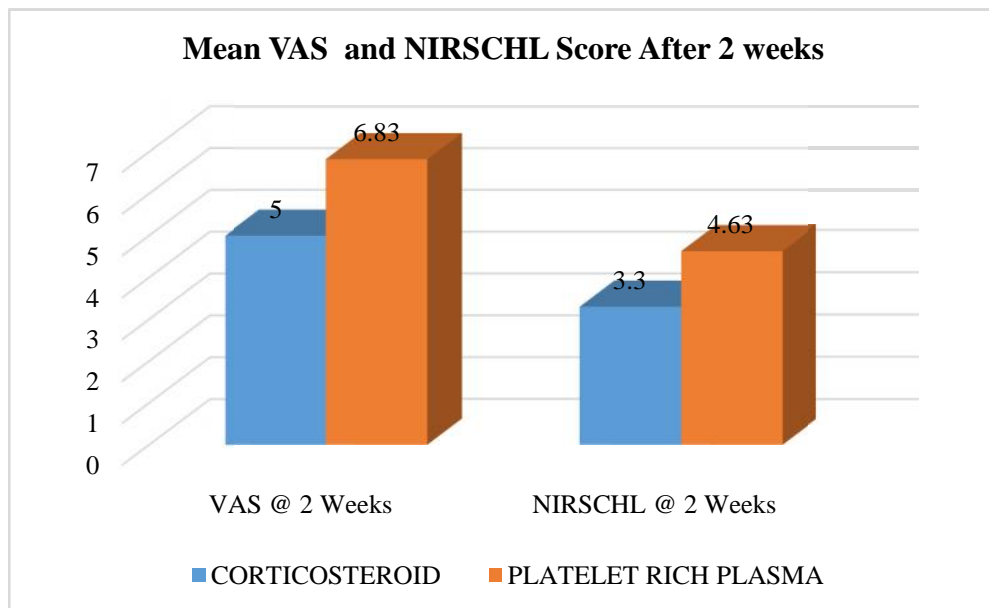


Table 9 : VAS score and NIRSCHL staging after 6 weeks of Injection in both the groups.

	Group						P value
	CORTICOSTEROID			PLATELET RICH PLASMA			
	Mean	Standard Deviation	Median	Mean	Standard Deviation	Median	
VAS @ 6weeks	2.23	1.22	2.00	2.17	.65	2.00	0.961
NIRSCHL score@ 6weeks	1.33	.71	1.00	1.40	.50	1.00	0.538

P value for VAS score at 6 weeks post-injection is 0.961 and for NIRSCHL staging is 0.538, which are not statistically significant.

The mean VAS score and NIRSCHL staging for corticosteroid group is 2.23 and 1.33.

The mean VAS score and NIRSCHL staging for platelet rich plasma group is 2.17 and 1.40.

Thus there is no statistically significant difference in decrease of pain in both the groups.

Figure 8 :Graph wise distribution of Mean VAS score and NIRSCHL staging at after 6 weeks.

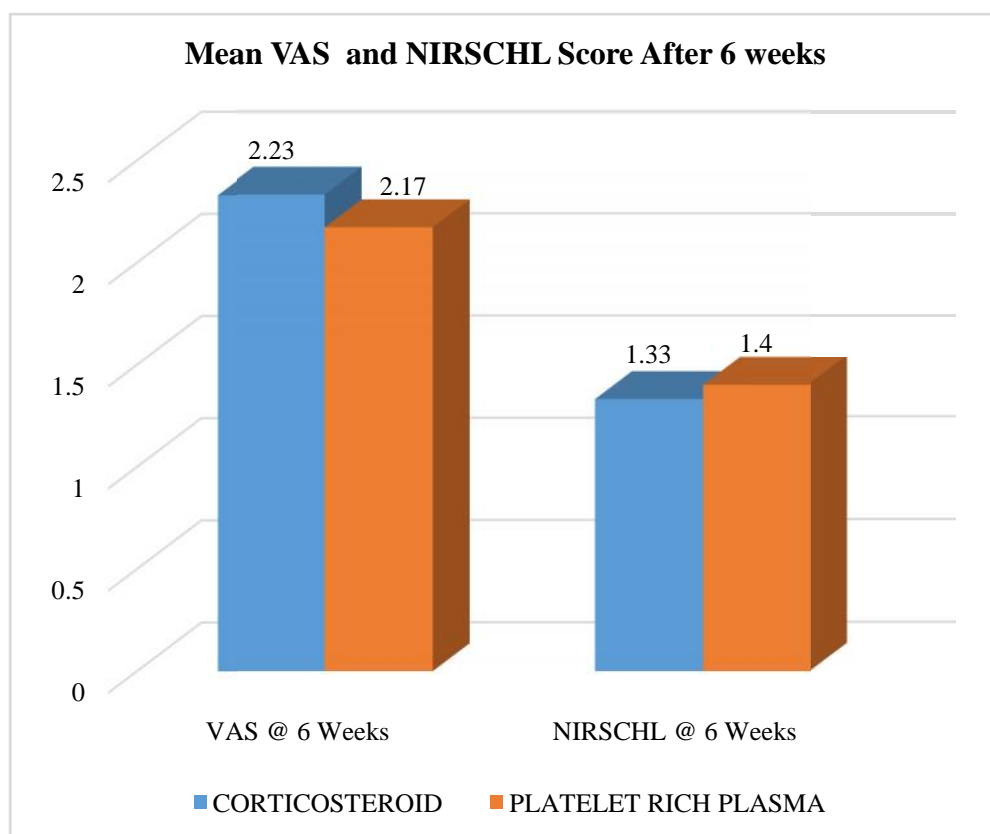


Table 10 : VAS score and NIRSCHL staging after 12 weeks of injection in both the groups.

	Group						P value
	CORTICOSTEROID			PLATELET RICH PLASMA			
	Mean	Standard Deviation	Median	Mean	Standard Deviation	Median	
VAS @ 12 weeks	1.53	1.01	2.00	0.80	1.13	.00	0.006
NIRSCHL score @ 12 weeks	0.87	0.57	1.00	0.57	.82	.00	0.027

P value for VAS score at 6 weeks post-injection is 0.006 and for NIRSCHL staging is 0.027, which is statistically significant.

The mean VAS score and NIRSCHL staging for corticosteroid group is 1.53 and 0.87.

The mean VAS score and NIRSCHL staging for platelet rich plasma group is 0.80 and 0.57.

Thus the decrease in pain is statistically significant in platelet rich plasma group.

Figure 9: Graph wise distribution of Mean VAS score and NIRSCHL staging at after 12 weeks.

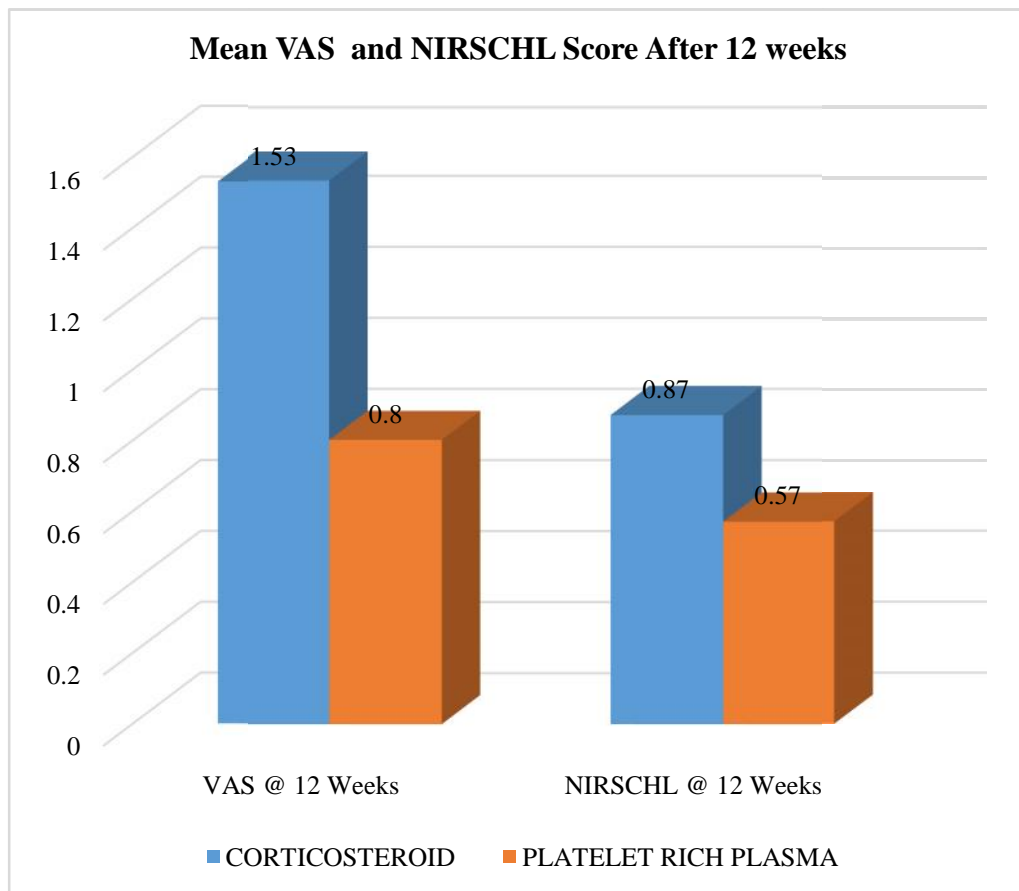


Table 11: VAS score and NIRSCHL staging after 24 weeks of injection in both the groups.

	Group						P value
	CORTICOSTEROID			PLATELET RICH PLASMA			
	Mean	Standard Deviation	Median	Mean	Standard Deviation	Median	
VAS @ 24 weeks	2.77	1.17	3.00	0.57	0.97	.00	0.0001
NIRSCHL @24 weeks	1.93	.91	2.00	0.47	0.73	.00	0.0001

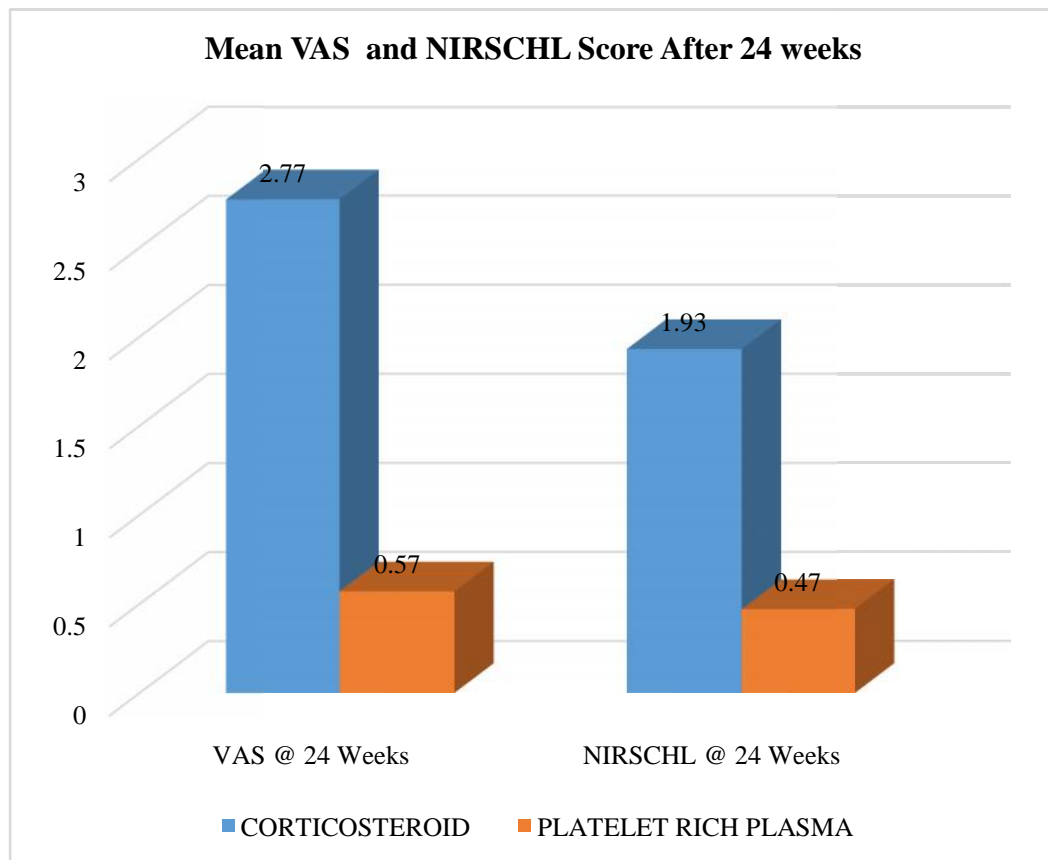
P value for VAS score at 6 weeks post-injection is 0.0001 and for NIRSCHL staging is 0.0001, which is statistically significant.

The mean VAS score and NIRSCHL staging for corticosteroid group is 2.77 and 1.93.

The mean VAS score and NIRSCHL staging for platelet rich plasma group is 0.57 and 0.47.

Thus the decrease in pain is statistically significant in platelet rich plasma group.

Figure 10: Graph wise distribution of mean VAS score and NIRSCHL staging after 24 weeks.



DISCUSSION

Lateral epicondylitis is the frequent problem presenting to the orthopaedic department. Numerous treatment methods are available, including operative and non-operative.

In this current study, the mean age of patients was 43.5 years (Range: 38.15 to 48.85 years) for corticosteroid group and 44.5 years (Range: 39.18 to 49.82 years) for platelet rich plasma group (p value 0.471). This was similar to a study done by Krogh and colleagues in 2013, where the mean age was 43.9 years in corticosteroid group and 47.6 years in platelet rich plasma group.

In the present study, out of 60 patients, 51.7% were males and 48.3% were females. In a study conducted by Krogh and colleagues there were same number of male and female patients. In two other studies conducted by Hay and colleagues and Verhaar J and colleagues, there were more number of male patients. The more number of male patients in this study was likely due to their profession leading to repetitive trauma on extensor carpi radialis brevis origin.

In this current study, out of 60 participants, 40 (66.6%) had right elbow affected and 20 (33.4%) had left elbow affected. Dominant elbow was affected in 53(88.3%) and non-dominant elbow was affected in 7 (11.7%). In another study conducted by Edwards SG and colleagues dominant limb was affected in 78.6 %. In a study conducted by Verhaar J dominant elbow was affected in 84% of the patients^{83,84}.

The mean VAS score and Nirschl staging before injection in both the group were recorded. At the time of presentation, mean VAS score of steroid group was 8.07 and for platelet rich plasma group was 8.07 (p value 0.938). Mean NIRSCHL score for steroid group was 6.03 and for platelet rich plasma group was 6.0 (p value 0.950).

At 2 weeks of follow-up, p value for VAS score is 0.0001 and for NIRSCHL staging is 0.0001, which are statistically significant. The mean VAS score and NIRSCHL staging for corticosteroid group was 5.0 and 3.3 respectively and for platelet rich plasma group was 6.83 and 4.63 respectively. Thus the decrease in pain was statistically significant in corticosteroid group.

After 6 weeks of follow up, no statistically significant difference was observed between the two groups in VAS scoring (p value 0.961) and Nirschl staging (p value 0.538). Mean VAS score and NIRSCHL staging in corticosteroid group was 2.23 and 1.33 respectively and in platelet rich plasma group was 2.17 and 1.40 respectively. Thus there was no significant difference in decrease in pain at 6 weeks in both the groups.

After 12 weeks of follow-up, there was statistically significant decrease in VAS score (p value 0.006) and NIRSCHL staging (p value 0.027) in both the groups. Mean VAS score and NIRSCHL staging in corticosteroid group was 1.53 and 0.87 respectively and in platelet rich plasma group was 0.80 and 0.57 respectively. Thus the decrease in pain was statistically significant in platelet rich plasma group.

The present study findings were similar to a study conducted by Peerbooms and colleagues⁸⁵. At 12 week follow-up there was statistically significant decrease in

VAS score in platelet rich plasma group when compared to corticosteroid group with PRP being better in pain relieving at 12 weeks. Mean VAS score in corticosteroid group was 4.4 and in platelet rich plasma group was 3.8.

The findings were also similar to another study conducted by Gosen and colleagues. The mean VAS score in their study was 32.3 for corticosteroid group and 21.3 for PRP group at a similar time interval.

At 6 months follow-up, there was statistically significant decrease in VAS score (p value 0.0001) and NIRSCHL staging (p value 0.0001) in both the groups. Mean VAS score and NIRSCHL staging in corticosteroid group was 2.77 and 1.93 respectively and in platelet rich plasma group was 0.57 and 0.77 respectively.

In platelet rich plasma group, increase in post intervention pain was observed in few patients which lasted for few days. In corticosteroid group 8 (26%) patients complained of pain after injection and in platelet rich plasma group 18 patients complained of post-injection pain. This was statistically significant with P value of 0.009. The post-injection pain was managed with oral analgesics.

The conclusion of this study is that, platelet rich plasma was beneficial in intermediate term and long term relief while steroid was beneficial in short term pain relief.

There are also less side effects like hypoglycaemia and skin atrophy with platelet rich plasma as compared with steroid injection.

CONCLUSION

- Lateral epicondylitis is one of the common upper limb condition presenting to the orthopaedic surgeon.
- The age most frequently affected with lateral epicondylitis was between 38 to 50 years.
- Male were more commonly affected in this study.
- There has been much debate in the earlier period concerning the underlying pathology of lateral epicondylitis.
- The present mechanism is a micro-tear at the origin of extensor carpi radialis brevis.
- According to microscopic observation, lateral epicondylitis is no longer inflammatory process. It is now considered as a degenerative etiology.
- There are two treatment modalities, conservative and surgical.
- The most commonly practiced conservative modalities are rest, ice application and injection of steroids.
- Steroids act by reducing the inflammatory process.
- Recently platelet rich plasma is also been used as a conservative modality for treatment.
- It acts by production of growth factors.

- In our study, corticosteroid demonstrated good short term outcomes at two weeks post-injection with poor long terms outcomes at 24 weeks.
- In the current study, platelet rich plasma could not demonstrate good short term outcome but had favorable intermediate and long term outcomes at 12 and 24 weeks.
- At 6 weeks post-injection both the groups had similar results.
- In our study, in steroid group 2 patients (6.66%) were completely relieved of pain at the end of 24 weeks and in platelet rich plasma group 19 patients (63.3%) were pain-free.
- Thus the present study concludes that steroid provide good short period pain relief and platelet rich plasma is better in intermediate and long term pain relief.

SUMMARY

- This study was a prospective randomized control study which included 60 patients. 30 cases and 30 controls were selected.
- Comparison of efficacy of injecting local platelet rich plasma with steroids was done.
- The patients were clinically assessed by VAS score and NIRSCHL staging.
- 30 cases were injected platelet rich plasma at the site of pain and 30 controls were injected steroids.
- Patients were followed-up at 2 weeks, 6 weeks, 12 weeks and 24 weeks for relief of pain.
- Outcomes were assessed by VAS score and NIRSCHL staging.
- T-test and Mann-whitney U test is applied for the pupose of calculating results.
- At 2 weeks follow-up, corticosteroid showed statistically significant decline in pain as compared to platelet rich plasma.
- At 6 weeks follow-up, no significant difference in pain relief was observed in both groups.
- At 12 weeks and 24 weeks, platelet rich plasma showed significantly decrease in pain as compared to corticosteroid group.

BIBLIOGRAPHY

1. Azar F M, Beaty J H, Canale S T. Campbell's Operative Orthopaedics. 13th ed. Churchill Livingstone; 2017, vol (II): 2330-34.
2. Gosens T, Peerbooms J C, Laar W V. Ongoing positive effect of platelet-rich plasma versus corticosteroid injection in lateral epicondylitis. *American J Sports Med* 2011;39(6):1200-08.
3. Hamilton PG . The prevalence of humeral epicondylitis: a survey in general practice. *J R Coll Gen Pract* 1986;36:464-65.
4. Verhaar JAN. Tennis elbow (Thesis). Maastricht: Maastricht University Press;1992.
5. Gruchow HW, Pelletier D. An epidemiological study of tennis elbow: incidence, recurrence, and effectiveness of prevention strategies. *Am J Sports Med* 1979;7(4):234-38.
6. Nirschl RP. Tennis elbow. *Primary care* 1977;4(2):367-82.
7. Bernhang AM. The many causes of tennis elbow. *NY J Med* 1979;79:1363-66.
8. Teitz CC, Garret J, Miniace WE, Lee A, Mann RA. Instructional course lectures. The American academy of Orthopaedic surgeons. Tendon problem in athletic individuals. *J Bone Joint Surg* 1997 Jan; 79(A):138-152.
9. Campbell WC, Christian CA, Terry CS. Campbell's Operative Orthopaedics. 9th ed.Churchill-Livingstone;1998,vol(II):1321-24.
10. Smidt N, Assendelft WJJ, Van der Windt DA, Hay EM, Buchbinder R, Bouter LM. Corticosteroid injections for lateral epicondylitis: a systematic review. *Pain* 2002;96(1-2):23-40.

11. Assendelft WJJ, Hay EM, Adshead R, Bouter LM. Corticosteroid injections for lateral epicondylitis: a systematic overview. *Br J Gen Pract* 1996;46:209-216.
12. Labelle H, Guibert R, Joncas J, Newman N, Fallaha M, Rivard CH. Lack of scientific evidence for the treatment of lateral epicondylitis of the elbow: An attempted meta-analysis. *J Bone Joint Surg Br* 1992;74(5):646-51.
13. Smidt N, Windt van der DAWM, Assendelft WJJ, Deville W, Korthals-de Bos I, Bouter LM. Corticosteroid injections, physiotherapy or a wait-and-see policy for lateral epicondylitis: a randomised controlled trial. *Lancet* 2002; 359:657-62.
14. Iwasaki M, Nakahara H, Nakata K, Kimura T, Ono K. Regulation of proliferation and osteochondrogenic differentiation of periosteum derived cells by transforming growth factor-B and basic fibroblast growth factor. *J Bone joint surg* 1995;77A:543-554.
15. Nirschl RP. Tennis elbow. *Orthop Clin North Am* 1973;4(3):787-800.
16. Morris H. The rider's sprain. *The lancet* 1882;11:133.
17. Cyriax JH. The pathology and treatment of tennis elbow. *J Bone Joint Surg.*1936;18(A):921-40.
18. Nirschl RO, Pettrone FA. Tennis elbow. *J Bone Joint Surg.* 1979;61(A):832-39.
19. Bosworth DM. The role of the orbicular ligament in tennis elbow. *J Bone Joint Surg.*1955;37(A):527-533.
20. Nirschl RP. Tennis elbow. *Orthop Clin North Am.*1973;4(3):787-800.
21. Nirschl RO, Pettrone FA. Tennis elbow. *J Bone Joint Surg.*1979;61(A):832-839.

22. Pitner MA. Pathophysiology of overuse injuries in the hand and wrist. *Hand Clin.* 1990;6:355-64.
23. Barton NJ, Hooper G, Noble J, Steele WM. Occupational disorders of the upper limb. *British Medical Journal.* 1992;304:309-11.
24. Nirschl RP. Sports and overuse injuries to the elbow. *The elbow and its disorders.* 2nd Ed. Toronto: Saunders; 1993;537-52.
25. Verhaar J, Walenkamp G, Kester A, Van der LT. Lateral extensor release for tennis elbow. A prospective long term follow-up study. *J Bone Joint Surg.* 1993;75:1034-43.
26. Fairbank SM, Corlett RJ. The role of the extensor digitorum communis muscle in lateral epicondylitis. *Journal of hand surgery.* 2002;27(B):405-09.
27. Varshney A, Maheshwari R, Juyal A, Agarwal A, Hayer P. Autologous platelet-rich plasma versus corticosteroid in the management of elbow epicondylitis: A randomized study. *Int J Appl Basic Med Res.* 2017;7(2):125-28.
28. Mishra AK, Skrepnik NV, Edwards SG, Jones GL, Sampson S, Vermillion DA, et al. Efficiency of platelet-rich plasma for chronic tennis elbow: a double blind, prospective, multicenter, randomized controlled trial of 230 patients. *Am J Sports Med.* 2014;42:463-71.
29. Kaux JF, Crielaard JM "Platelet rich plasma application in the treatment of chronic tendinopathies" *Acta Orthop Belg* Feb 2013 N^o 1 (Vol 79/1) Pages 10-15
30. Slama Chaudhury, de La Lama M, Adler RS, Gulotta LV, Skonieczki B, Chang A et al. "Platelet-rich plasma for the treatment of lateral epicondylitis :

- Sonographic assessment of tendon morphology and vascularity (pilot study)”
Skeletal Radiol Jan 2013 Vol.42 Issue 1 Pages 91-97.
31. S. Terry Canale, James H. Beaty in Cambell’s operative Orthopaedics in Treatment of Tennis Elbow 12th Edition Vol III Chapter 46 Page 2243
 32. Mishra A, Pavelko T “treatment of chronic elbow tendinosis with buffered platelet-rich plasma” Am J Sports Med Nov 2006 Vol.34 No.11 Pages 1774-1778.
 33. Harrington JM, Carter JT, Birrell L, Gompertz D. Surveillance case definitions for work related upper limb pain syndromes. Occup Environ Med. 1998;55:264–71.
 34. Greenbaum B, Itamura J, Vanggsness CT, Tibone J, Atkinson R. Extensor carpi radialis brevis-An anatomical analysis of its origin. J of bone and joint surgery. 1999;81(B):926-29.
 35. Cyriax JH. The pathology and treatment of tennis elbow. J Bone Joint Surg. 1936;18(A):921-40.
 36. Tonks JH, Pai SK, Murali SR. Steroid injection therapy is the best conservative treatment for lateral epicondylitis: a prospective randomised controlled trial. Int J Clin Pract. 2007;61(2):240–46.
 37. Grays H. Gray’s anatomy: The anatomical basis of clinical practice. 41st ed. Elsevier: Churchill livingstone;2016;843-52.
 38. Leadbetter WB. Cell matrix response in tendon injury. Clin Sports Med. 1992;11:533-578.
 39. Curwin S, Stanish WD. Tendinitis, its etiology and treatment. Lexington:Massachusetts: Collamore Press;1984.

40. Stanish WD, Rubinovich RM, Curwin S. Eccentric exercise in chronic tendinitis. *Clin. Orthop.* 1986;208:65-68.
41. Woo SLY, Gomez MA, Woo YK, Akeson WH. Mechanical properties of tendons and ligaments. The relationship of immobilization and exercise on tissue remodelling. *Biorheology.* 1982;19:397-408.
42. Woo SLY, An KN, Arnoczky SP, Wayne JS, Fithian DC, Myers BS. Anatomy, biology and biomechanics of tendon, ligament and meniscus. *Orthopaedic basic science: American academy of orthopaedic surgeons*;1994.45-87.
43. Regan W, Wold LE, Coonrad R, Morrey BF. Microscopic histopathology of chronic refractory lateral epicondylitis. *Am J sports Med.* 1992;20(6):746-749.
44. Kannus P, Jozsa L. histopathological changes preceding spontaneous rupture of a tendon: a controlled study of 891 patients. *J Bone Joint Surg.* 1991;73(A):1507.
45. Jozsa LG and Kannus P. Overuse injuries of tendons. In *human tendons: Anatomy, physiology and pathology. Human kinetics. Champaign: Illinois.* 1997, 164-253.
46. Garret J, Teitz CC, Miniace WE, Lee A, Mann RA. Tendon problem in athletic individuals. *Instructional course lectures. The American academy of orthopaedic surgeons J of Bone and Joint Surg.* 1997;79(A):138-152.
47. Jozsa L, Lehto M, Kvist M, Balint JB, Reffy A. Alterations in dry mass content of collagen fibers in degenerative tendinopathy and tendon rupture. *Matrix.* 1989(9):140-46.
48. Jozsa L, Reffy A, Kannus P, Demel S, Elek E. Pathological alterations in human tendons. *Arch Orthop and trauma surg.* 1990;110:15-21.

49. Kannus P, Jozsa L. Histopathological changes preceding spontaneous rupture of a tendon. A controlled study of 891 patients. *J Bone and Joint surgery.* 1991;73(A):1507-25.
50. Perugia L, Ricciardi PPT, Ippolito E. Ultrastructural aspects of degenerative tendinopathy. *Internet. Orthop.* 1978;1:303-07.
51. Nirschl RP. Tennis elbow tendinosis: Pathoanatomy, nonsurgical and surgical management. *Repetitive motion disorders of the upper extremity. American academy of orthopaedic surgeons.* Rosemont: Illinois.1995:467-479.
52. Coonrad RW, Hooper WR. Tennis elbow: is course, natural history, conservative and surgical management. *J of Bone and Joint Surgery.* 1973;55(A):1177-82.
53. Goldie I. Epicondylitis lateralis humeri. A pathological study. *Acta Chir: Scandinavica, Supplementum.* 1964:339.
54. Nirschl RP. Elbow tendinosis. *Clin Sports Med.* 1992;11:851-70.
55. Sarkar K, Uthoff HK. Ultrastructure of the common extensor tendon in tennis elbow. *Virchows Arch. A Pathol Anat and Histol.* 1980;386:317-330.
56. Nirschl RP. Patterns of failed tendon healing in tendon injury. *Sports-induced inflammation: Clinical and basic science concepts. American academy of orthopaedic surgeons.* Park Ridge: Illinois. 1990:609-618.
57. Hyland S, Nitschke J, Matya TA. The extension-adduction test in chronic tennis elbow: soft tissue components and joint biomechanics. *Aust J Physiother.* 1990: 36(3):147-53.
58. Gellman H. Tennis elbow (lateral epicondylitis). *Orthop Clin North Am.* 1992;23(1):75-82.

59. Harvey , Lick J, Stanish W, teirtz C. Tennis elbow: What's the best treatment?. *Physician Sportmed.* 1990;18(6):62-74.
60. Caldwell GL, Safran MR. elbow problems in the athlete. *Orthop Clin North Am.* 1995;26(3):465-85.
61. Gosens T. Lateral and medial epicondylitis. In: Stanley D, Trail I. *Operative elbow surgery.* Elsevier: Churchill livingstone;2012;533-44.
62. Robert H, Miller III, Azar FM, Throckmorton TW. Shoulder and elbow injuries. In: Azar FM, Beaty JH. Canale ST. *Campbell's operative orthopaedics.* 13th ed Elsevier; 2017: 2330-2333.
63. Kannus P, Jarvinen M, Niittymaki S. Long or short acting anesthetic with corticosteroid in local injections of overuse injuries?: A prospective, randomized, double-blind study. *Int J Sports Med.* 1990;11:397-400.
64. Campbell WC, Terry CS. *Campbell's operative orthopaedics.* 11th ed. Mosby: Elsevier;2008;3:1321-1324.
65. Nirschl RP, Pettrone FA. Tennis elbow. The surgical treatment of lateral epicondylitis. *J Bone Joint Surg.* 1979;61(A);832-839.
66. Boyer MI, Hastings H. Lateral tennis elbow: "Is there any science out there?". *J shoulder elbow surgery.* 1991;8:481-491.
67. Labelle H, Guibert R, Joncas J, Newman N, Fallaha M, Rivard CH. Lack of scientific evidence for the treatment of lateral epicondylitis of the elbow: An attempted meta-analysis. *J Bone Joint surgery.* 1992;74(5):646-51.
68. Assendelft WJ, Hay EM, Adshead R, Bouter LM. Corticosteroid injections for lateral epicondylitis: a systematic overview. *Br J Gen Pract.* 1996;46:209-216.
69. Hay EM, Paterson SM, Lewis M, Hosie G, Croft P. Pragmatic randomised controlled trial of local corticosteroid injection and naproxen for treatment of

- lateral epicondylitis of elbow in primary care. *British medical journal*. 1999;319:964-968.
70. Smidt N, Assendelft WJJ, Vand der windt DA, Hay EM, Buchbinder R, Bouter LM. Corticosteroid injections for lateral epicondylitis: a systematic review. *Pain*. 2002;96(1-2):23-40.
71. Leanne B, Elaine B, Gwendolen J, Peter B, Ross D, Bill V Mobilisation with movement and exercise, corticosteroid injection or wait and see for tennis elbow: randomized trial. *British medical journal*. 2006;333(7575):939.
72. Kapetanios G. The effect of the local corticosteroids on the healing and biomechanical properties of the partially injured tendon. *Clin Orthop*. 1982;163:170-179.
73. Ketchum LD. Effects of triamcinalone on tendon healing and function. *Plast Reconstr Surg*. 1971;47:471.
74. Unverfirth LJ, Olix ML. The effect of local steroid injections on tendon. *J Bone Joint Surg (Am)*. 1973;55:1315.
75. Gottlieb NL, Riskin WG. Complications of local corticosteroid injections. *JAMA*. 1980;240:1547-1548.
76. Haslock I, Macfarlane D, Speed C. Intra-articular and soft tissue injections: a survey of current practice. *Br J Rheum*. 1995; 34:449-452.
77. Consumers association. Articular and periarticular corticosteroid injections. *Drugs Ther Bull*. 1995;33:67-70.
78. Speed C A. Corticosteroid injections in tendon lesions. *British medical journal*. 2001;323:382-86.
79. Balasubramaniam P, Prathap K. the effect of injection of hydrocortisone into rabbit calcaneal tendons. *J Bone Joint Surg*. 1972;54(B):729-34.

80. Anitua E, Andia I, Sanchez M. Autologous preparations rich in growth factors promote proliferation and induce VEGF and HGF production by human tendon cells in culture. *J Orthop Res.* 2005;23:281-86.
81. Mishra A, Pavelko T. Treatment of chronic elbow tendinosis with buffered platelet-rich plasma. *American journal of sports medicine.* 2006;34:1774-78.
82. Krogh TP, Fredberg U, Stengaard-Pedersen K, Christensen R, Jensen P, Ellingsen T. Treatment of lateral epicondylitis with platelet-rich plasma, glucocorticoid, or saline: a randomized, double-blind, placebo-controlled trial. *Am J Sports Med.* 2013; 41(3): 625–635.
83. Verhaar J, Waln KG, Van MH, Kester A, Van DLA. Local corticosteroid versus cyriax-type physiotherapy for tennis elbow. *J Bone Joint Surg.* 1996;78(B):128-32.
84. Edwards SG, Calandruccio JH. Autologous blood injections for refractory lateral epicondylitis. *J Bone Joint Surg.* 2003;28(A):272-78.
85. Peerbooms JC, Sluimer J, Bruijn DJ, Gosens T. Positive effect of an autologous platelet concentrate in lateral epicondylitis in a double-blind randomized controlled trial platelet-rich plasma versus corticosteroid injection with a 1-year follow-up. *Am J Sports Med.* 2010; 38(2):255–262.

General physical examination:

a) Pulse Rate: beats per minute

b) Blood Pressure: / mm Hg

c) Respiratory Rate: cycles per minute.

d) Temperature: °F

1- Present 2- Absent

Pallor

Icterus

Cyanosis

Clubbing

Pedal edema

Lymphadenopathy

Systemic Examination:

1- Normal 2-Abnormal

CVS: If abnormal _____

R/S: If abnormal _____

P/A: If abnormal _____

CNS: If abnormal _____

LOCAL EXAMINATION:

Examination of elbow : 1- Right 2- Left

ON INSPECTION

ATTITUDE OF THE LIMB _____

LOCAL SWELLING _____

SKIN OVER THE ELBOW JOINT: _____

DEFORMITY: _____

MUSCLE WASTING: _____

PALPATION

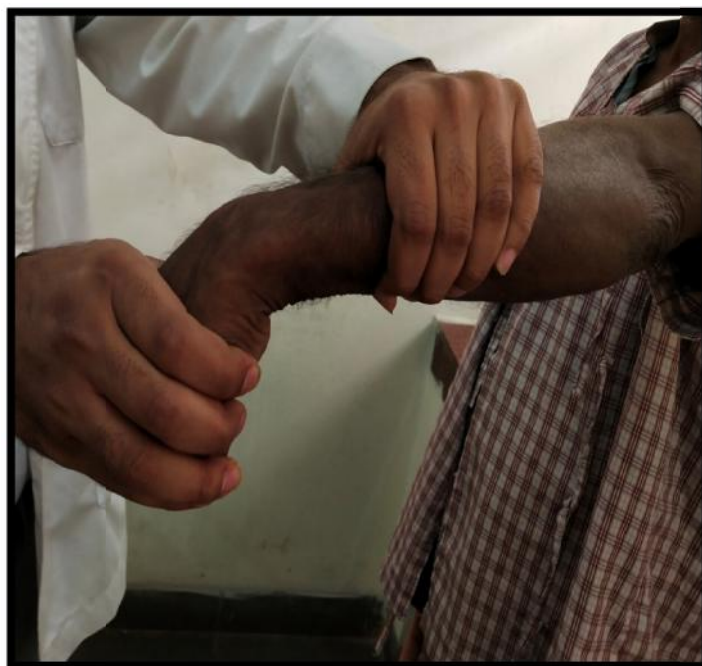OUTCOME MEASURE:-

1) Visual Analogue Scale (VAS):

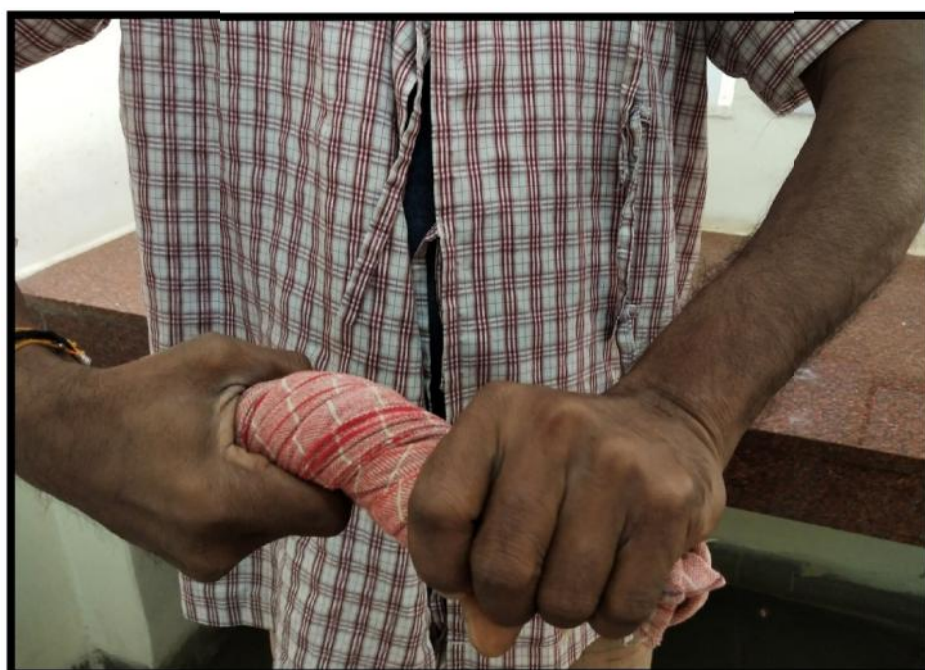	Pre Intervention	2Weeks	6 Weeks	3 months	6 months
<u>VAS</u>					

2) NIRSCHL staging:

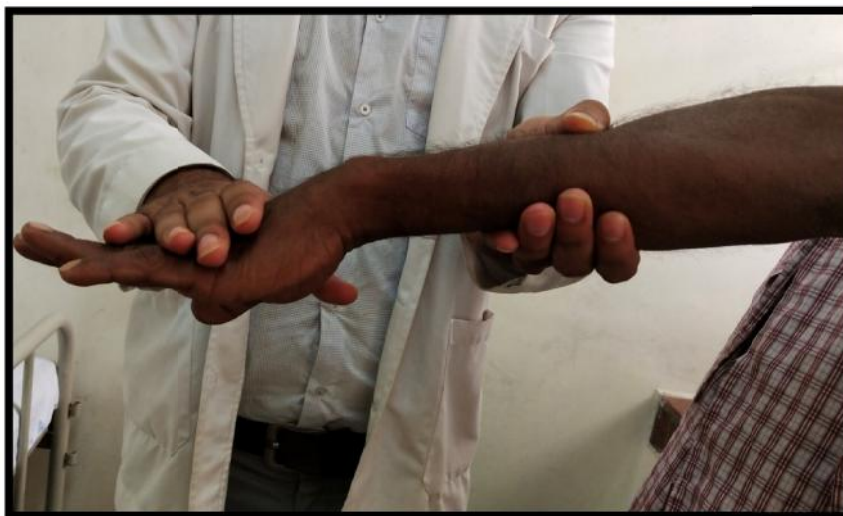ANNEXURE IV – PHOTOGRAPHS



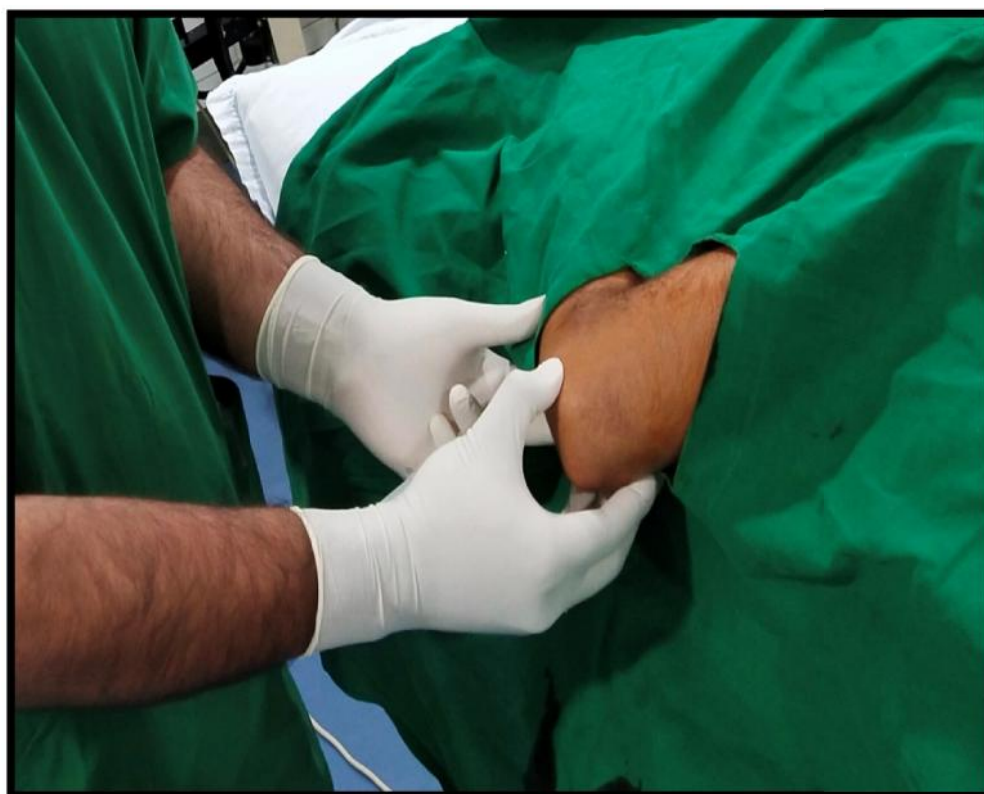Photographs 1: Cozen's test



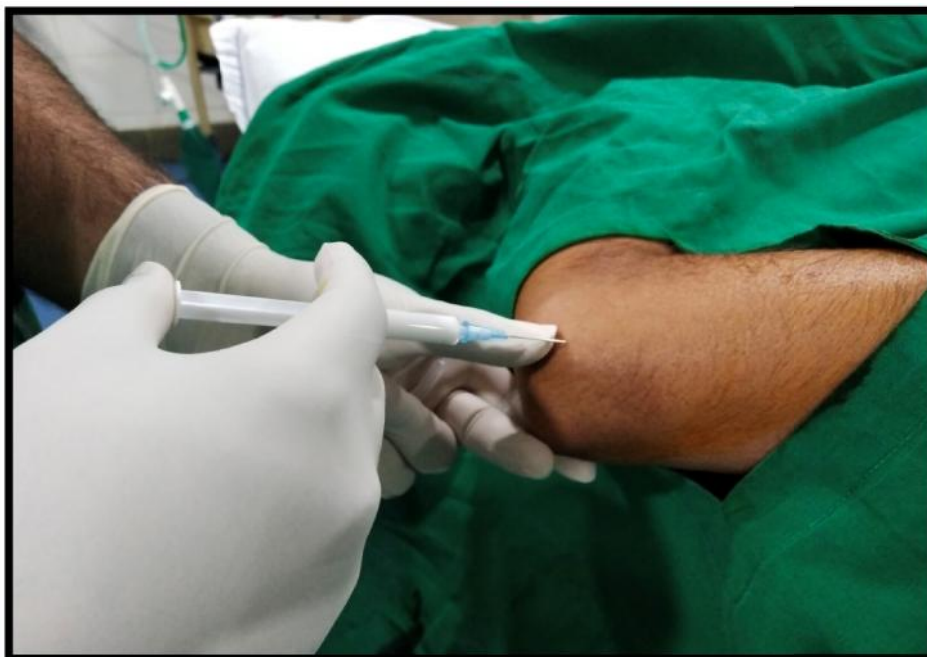Photographs 2: Wringing test



Photographs 3: Mill's manoeuvre



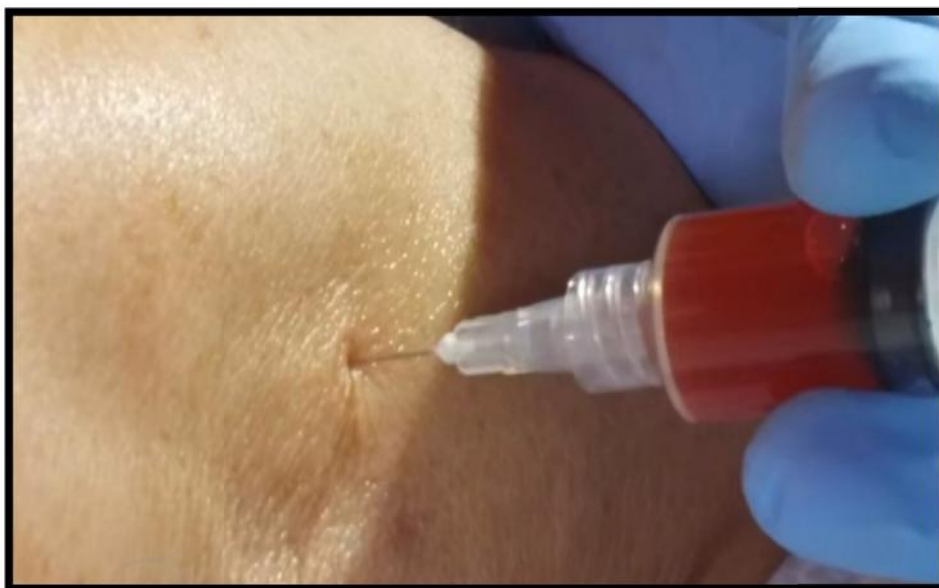Photographs 4: Elucidating tenderness around lateral epicondyle.



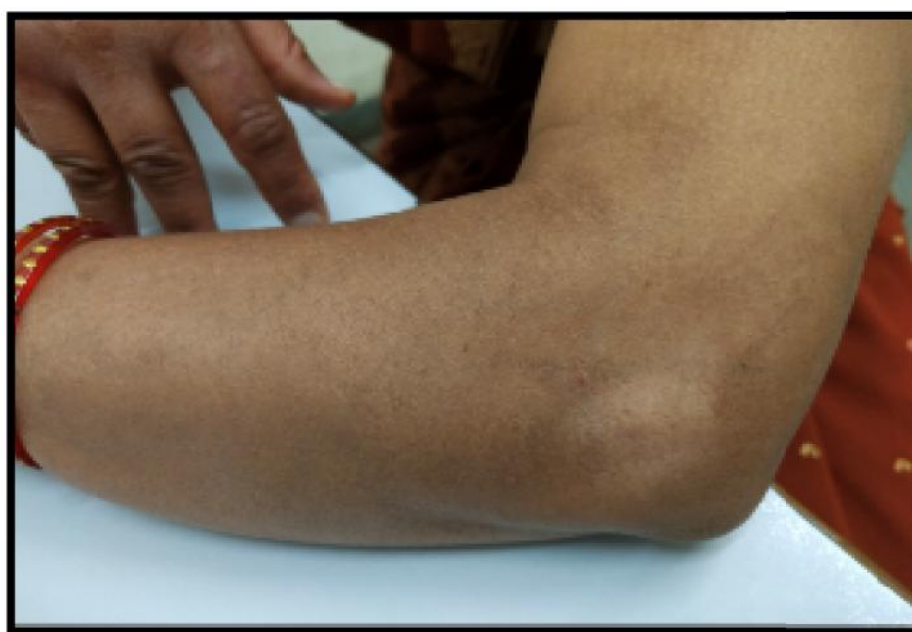Photographs 5: Injection of local corticosteroid



Photographs 6: Preparation of PRP



Photographs 7: Injection of PRP



Photographs 8: Complication of steroid injection (local depigmentation)

ANNEXURES V - MASTER CHART

CORTICOSTEROID																
Sl.No	OP No.	Age	Sex	Side	Dominance	Duration(wks)	VAS score (pre-procedure)	VAS score (post-procedure)				NIRSCHL (pre-procedure)	NIRSCHL (post-procedure)			
								2weeks	6weeks	12 weeks	24 weeks		2weeks	6weeks	12 weeks	24 weeks
1	4725564	36	M	R	D	8	8	5	3	3	4	6	3	2	2	3
2	4682095	51	F	R	D	6	8	5	2	2	3	6	3	1	1	4
3	4948993	40	M	R	D	4	9	6	3	0	1	7	4	2	0	1
4	4886958	38	F	R	D	7	10	7	2	2	4	7	4	1	1	3
5	4789926	41	F	R	D	9	8	7	6	0	3	6	4	3	0	2
6	4948987	40	M	R	D	12	7	2	3	3	4	5	1	2	2	3
7	4789935	43	F	R	D	3	8	5	2	2	3	6	3	1	1	2
8	4948992	39	F	R	D	4	7	4	3	0	0	5	3	2	0	0
9	4923168	45	M	R	N	6	9	6	1	2	3	7	4	1	1	2
10	4682111	50	M	R	D	6	10	6	2	3	5	7	4	1	2	3
11	5168687	52	M	R	D	6	8	4	2	2	2	6	3	1	1	1
12	4922878	53	M	R	D	5	9	6	5	2	4	7	5	3	1	3
13	4682104	45	F	R	D	8	7	6	0	1	2	5	4	0	1	2
14	4948990	38	F	R	D	7	6	4	3	2	3	5	3	2	1	2
15	4725564	36	M	L	N	6	8	6	2	2	3	6	4	1	1	2
16	4923153	35	F	L	D	5	9	7	1	1	3	7	5	1	1	2
17	4789932	39	F	R	D	6	9	6	2	2	3	7	4	1	1	2
18	4923150	38	M	L	N	6	8	5	3	2	4	6	4	2	1	3
19	4789928	36	M	R	D	6	7	6	2	3	4	5	4	1	1	2
20	4725503	46	M	R	D	8	9	6	2	2	3	7	4	1	1	2
21	4789949	42	F	L	D	3	8	4	2	0	2	6	2	1	0	1
22	4725620	49	M	L	D	4	8	3	3	2	2	6	2	2	1	1
23	5768740	48	F	L	D	6	7	3	0	0	1	5	2	0	0	1
24	5165256	46	F	R	D	5	8	3	1	1	3	6	2	1	1	2
25	4948989	45	M	L	D	4	8	4	2	2	3	6	2	1	1	2
26	4923020	43	M	R	D	9	7	4	2	2	3	5	3	1	1	2
27	4789727	48	M	R	D	10	6	4	1	1	3	4	3	1	1	2
28	4682097	44	F	L	D	11	9	5	2	0	2	7	3	1	0	1
29	4726657	49	M	R	D	8	9	6	2	0	0	7	4	1	0	0
30	5168671	50	F	L	D	8	8	5	3	2	3	6	3	2	1	2

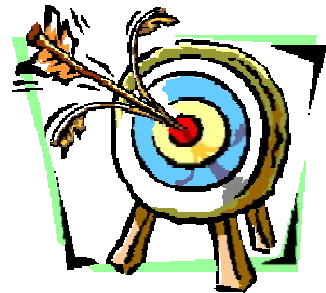
PLATELET RICH PLASMA																
Sl.No	Op.no.	Age	Sex	Side	Dominance	Duration(wks)	VAS score (pre-procedure)	VAS score (post-procedure)				NIRSCHL (pre-procedure)	Nirschl score (post-procedure)			
								2 weeks	6 weeks	12 weeks	24 weeks		2 weeks	6 weeks	12 weeks	24 weeks
1	4948995	35	F	R	D	9	9	8	2	0	0	7	6	1	0	0
2	5161827	49	M	R	D	6	9	8	2	0	0	7	6	1	0	0
3	4492716	41	F	R	D	4	9	8	3	4	4	7	6	2	3	3
4	5145905	40	F	L	D	8	10	7	2	2	3	7	5	1	1	2
5	4948997	45	F	R	N	4	9	7	3	0	0	7	5	2	0	0
6	4923159	41	M	L	D	11	8	3	1	1	1	6	2	1	1	1
7	4887127	42	M	L	D	3	8	6	2	0	0	6	4	1	0	0
8	4759118	40	F	R	D	4	7	7	3	3	2	5	5	2	2	1
9	4886969	49	M	R	D	6	9	8	2	1	1	7	4	2	1	1
10	4467928	51	M	R	D	7	7	6	2	0	0	5	4	1	0	0
11	4682094	53	M	R	D	6	8	7	2	2	1	6	5	2	1	1
12	4682101	54	M	L	D	5	9	7	3	0	0	7	5	2	0	0
13	5161584	46	F	R	D	6	7	6	3	0	0	5	4	2	0	0
14	5162381	40	F	R	D	5	6	5	3	2	1	4	3	2	2	1
15	4948985	38	M	R	D	6	8	7	2	0	0	6	5	1	0	0
16	4887131	36	F	L	D	5	8	7	2	1	1	6	5	1	1	1
17	4887124	39	M	R	D	8	9	8	2	0	0	7	6	1	0	0
18	4948996	40	M	L	N	6	8	7	3	2	1	6	5	2	2	1
19	4887011	37	M	R	D	6	7	6	2	2	1	5	4	1	1	1
20	4789959	45	F	R	D	8	9	8	2	0	0	6	1	1	0	0
21	5155930	43	F	R	D	4	8	7	2	0	0	6	5	1	0	0
22	511783	52	M	L	D	4	8	7	3	2	0	6	5	2	1	0
23	4725507	50	F	L	D	9	7	7	1	0	0	5	5	1	0	0
24	4886966	47	M	R	D	5	8	7	1	0	0	6	5	1	0	0
25	5161547	46	M	R	D	4	8	7	2	0	0	6	5	1	0	0
26	4923157	44	M	L	D	9	7	6	2	2	1	5	4	2	1	1
27	5161721	46	F	R	D	10	6	5	1	0	0	4	3	1	0	0
28	5161639	45	F	L	N	11	9	7	2	0	0	7	5	1	0	0
29	5195475	50	F	R	D	10	9	8	2	0	0	7	6	1	0	0
30	5155992	51	F	L	N	8	8	8	3	0	0	6	6	2	0	0

ANNEXURE-VI**KEY TO MASTER CHART**

R	Right
L	Left
M	Male
F	Female
NIRSCHL	NIRSCHL staging
VAS	Visual analogue scale
PRP	Platelet rich plasma
CS	Corticosteroid
Sl.no.	Serial number



Introduction



Objectives



Review of Literature



Methodology




Results



Discussion



Conclusion



Limitations




Recommendations



Summary




Bibliography



Annexure-I



Annexure-II



Annexure-III



Annexure-IV



Annexure-V
