
**“A STUDY OF ANATOMICAL
RELATIONSHIP OF POSTERIOR
AURICULAR ARTERY WITH FACIAL
NERVE TRUNK: A CADAVERIC STUDY”**

BY

REGISTRATION NO: BE0122005

Dissertation

*Submitted to the KLE Academy of Higher Education and
Research, Belagavi, Karnataka*

In Partial Fulfilment

of the Requirements for the Degree of

MASTER OF SURGERY

IN

OTORHINOLARYNGOLOGY

AND HEAD AND NECK SURGERY

**DEPARTMENT OF OTORHINOLARYNGOLOGY AND
HEAD AND NECK SURGERY**

**JAWAHARLAL NEHRU MEDICAL COLLEGE,
BELAGAVI, KARNATAKA**

SEPTEMBER/OCTOBER 2025

KLE ACADEMY OF HIGHER EDUCATION AND RESEARCH,
BELAGAVI, KARNATAKA.

**ENDORSEMENT BY THE HOD/ PRINCIPAL/ HEAD OF
THE INSTITUTION**

This is to certify that the dissertation entitled "A STUDY OF ANATOMICAL RELATIONSHIP OF POSTERIOR AURICULAR ARTERY WITH FACIAL NERVE TRUNK: A CADAVERIC STUDY" is a bonafide research work done by **REGISTRATION NO: BE0122005.**

Dr. R. B. Metgudmath
Professor & Head
Department of E.N.T.
J. N. Medical College
Belagavi

Dr. RAJENDRA B. METGUDMATH M.S.
Professor and Head,
Department of Otorhinolaryngology
and Head and Neck Surgery,
J. N. Medical College,
Nehru Nagar, Belagavi

Date: 29/3/2025

Place: Belagavi



Dr. (Mrs.) N. S. MAHANTASHETTI M.D.
Principal,
J. N. Medical College,
Nehru Nagar,
Belagavi

PRINCIPAL
Jawaharlal Nehru Medical College
Belagavi

Date:

Place: Belagavi

UNDERTAKING

I, **REG NO: BE0122005** hereby declare that the information and the data mentioned in my dissertation entitled “**A STUDY OF ANATOMICAL RELATIONSHIP OF POSTERIOR AURICULAR ARTERY WITH FACIAL NERVE TRUNK: A CADAVERIC STUDY**” belongs to me and is original. I am aware of the definition of plagiarism as detailed below:

- An act or instance of using or closely imitating the language and thoughts of another author without authorization and the representation of that author's work as one's own, as by not crediting the original author.
- A piece of writing or other work reflecting such unauthorized use or imitation.
- The deliberate or reckless representation of another's words, thoughts or ideas as one's own without attribution in connection with submission of academic work, whether graded or otherwise.

I hereby declare that the dissertation prepared by me is original one and does not involve plagiarism anywhere. In case at a later stage, it is found that I have indulged in plagiarism, then I am solely responsible for the same and the institution is at liberty to take any disciplinary action against me including cancellation of dissertation or any other penalties imposed by the University.

Date: 29/03/2025

Place: Belagavi



REG NO: BE0122005

PLAGIARISM CERTIFICATE



JAWAHARLAL NEHRU MEDICAL COLLEGE

(A constituent unit of KLE Academy of Higher Education & Research Deemed-to-be-University)

(Recognized by National Medical Commission, New Delhi)

Accredited 'A+' Grade by NAAC (3rd Cycle)

Placed in Category 'A' by MoE (GoI)

Nehru Nagar, Belagavi- 590 010, Karnataka, INDIA

0831 - 2471350

0831 - 2470759

www.lnmc.edu


Principal@lnmc.edu

Ref No: MDC/PG/



Date: 10-03-2025

"ACCEPTANCE LETTER"

The softcopy of thesis entitled: "A STUDY OF ANATOMICAL RELATIONSHIP OF POSTERIOR AURICULAR ARTERY WITH FACIAL NERVE TRUNK: A CADAVERIC STUDY" has been submitted for anti-plagiarism check through Turnitin software. The scan has been carried out and the scanned output reveals a match percentage of 06% which is within the acceptable limits of 10% as per the guidelines given by UGC.


Guide.




Dr. (Mrs.) N.S. Mahantashetti.
Chairperson-Antiplagiarism Committee &
Principal,
J. N. Medical College, Belagavi. 

To,
Reg. No. BE0122005
Postgraduate Student,
2022-23 Batch,
Department of E. N. T.
J. N. Medical College, Belagavi.

ETHICAL CLEARANCE CERTIFICATE



K.L.E. ACADEMY OF HIGHER EDUCATION AND RESEARCH
(Deemed – to- be- University)

Accredited 'A+' Grade by NAAC in (3rd Cycle) Placed in Category 'A' by MHRD (GoI)

JNMC INSTITUTIONAL ETHICS COMMITTEE
JAWAHARLAL NEHRU MEDICAL COLLEGE,
NEHRU NAGAR, BELAGAVI-590010 (KARNATAKA-INDIA)

Website: <http://www.jnmc.edu>
E-Mail : dome@jnmc.edu

Phone: (+ 91-(0)831 Office : 2472550
Principal: 2471701
Fax No. +91 (0)831 – 2470759

Ref No.MDC/JNMCIEC/ 40

Date: 05/04/2023

To,

BE0122005

PG Student in Otorhinolaryngology And Head And Neck Surgery
J. N. Medical College,
BELAGAVI.

Sub: Institutional Ethical Clearance for the study.

With reference to the above, we wish to inform you that your proposed research project titled "A STUDY OF ANATOMICAL RELATIONSHIP OF POSTERIOR AURICULAR ARTERY WITH FACIAL NERVE TRUNK : A CADAVERIC STUDY", is ethical and justifiable. The proposed research project has been cleared by the JNMC Institutional Ethics Committee.

(Dr. Smifa Sonoli)
Member Secretary

JNMC Institutional Ethics Committee
J.N.Medical College, Belagavi.

(Dr. Harsha Hegde)
Chairman,

JNMC Institutional Ethics Committee
J.N.Medical College, Belagav

LIST OF ABBREVIATIONS

GLOSSARY	ABBREVIATIONS
TMS	Tympanomastoid Suture
PAA	Posterior Auricular Artery
PBDM	Posterior Belly of Digastric Muscle
ECA	External Carotid Artery
IJV	Internal Jugular Vein
PAN	Posterior Auricular Nerve
IAC	Internal Acoustic Canal
GSPN	Greater Superficial Petrosal Nerve
SMAS	Superficial Musculoaponeurotic System
SMF	Stylomastoid Foramen
FN	Facial Nerve
CMAP	Compound Muscle Action Potential
EMG	Electromyography
MUAP	Motor Unit Action Potentials
SCM	Sternocleidomastoid
EAC	External Auditory Canal
EAM	External Auditory Meatus
MT	Mastoid Tip
FNT	Facial Nerve Trunk
ROC	Receiver Operating Characteristic
SD	Standard Deviation
CI	Confidence Interval

ABSTRACT

Background:

Despite good surgical knowledge of the anatomy of Parotid gland and meticulous surgical technique, the incidence of facial palsy in parotid surgeries is up to 26.7% transient and 1.7% complete facial palsy. Although several surgical landmarks to identify the facial nerve have been described in literature, their position is variable, inconsistent, and difficult to follow in some cases.

Objectives:

To study the relation between posterior auricular artery and facial nerve trunk and to determine the validity of using posterior auricular artery as a marker to identify facial nerve during parotid surgeries.

Methods:

All cadaveric hemifaces available during the study period at the Department of Anatomy was taken. Superficial parotidectomy was done in 20 cadaveric hemifaces in 10 cadavers. Posterior auricular artery was dissected and facial nerve trunk was identified in all cases. The relationship of posterior auricular artery (PAA) with the facial nerve trunk was studied and recorded.

Results:

Posterior auricular artery was found running inferior to the facial nerve trunk in 18 out of 20 cadaveric hemifaces and crosses the facial nerve trunk below and courses superiorly in 2 out of 20 cadaveric hemifaces. It was observed that the mean distance between the posterior auricular artery and facial nerve trunk was $3.74\text{mm} \pm 1.69$.

Conclusion:

Posterior auricular artery can be used as another potential landmark for identification of the main trunk of facial nerve in parotid surgeries.

Keywords: Posterior auricular artery, facial nerve trunk, external carotid artery, facial nerve.

TABLE OF CONTENTS

SL.NO.	CONTENTS	PAGE NO.
1	INTRODUCTION	1-2
2	OBJECTIVES	3
3	REVIEW OF LITERATURE	4-30
4	MATERIALS AND METHODS	31-34
5	RESULTS AND ANALYSIS	35-47
6	DISCUSSION	48-51
7	CONCLUSION	52
8	SUMMARY	53
9	BIBLIOGRAPHY	54-57
10	ANNEXURES	58-71
	Annexure I: Proforma	58-59
	Annexure II: Photographs	60-69
	Annexure III: Key to Master Chart	70
	Annexure IV: Master Chart	71

LIST OF FIGURES

FIGURE	TITLE	PAGE NO.
1.	Image depicting the superficial and deep cervical fascia of the neck	4
2.	Illustration depicting blood supply of the neck	7
3.	Branches of the external carotid artery	10
4.	Branches of facial nerve	13
5.	Diagram depicting different pointers to identify facial nerve	15
6.	Image illustrating the stylomastoid region	17
7.	Diagram depicting parotid gland along with facial nerve branches running through the parenchyma	23
8.	Structures emerging from the periphery of the parotid gland	24
9.	Relations of the parotid gland	25

LIST OF TABLES

SL.NO	TITLE	PAGE NO.
1.	Type of embalming wise distribution of cadaveric hemifaces	36
2.	Side wise distribution of cadavers	37
3.	Gender wise distribution of cadaveric hemifaces	38
4.	Normality of different parameters by Shapiro- Wilk test	39
5.	Comparison of mean scores among all the parameters	41
6.	Comparison of male and female with distance from Posterior auricular artery to Facial nerve in mm scores by t test	43
7.	Comparison of left and right side with distance from Posterior auricular artery to Facial nerve in mm scores by t test	44
8.	Relation of Posterior auricular artery to Facial nerve trunk	45
9.	Posterior auricular artery in relation to Mastoid tip	46
10.	Branch of Posterior auricular artery	47

LIST OF GRAPHS

SL.NO	TITLE	PAGE NO.
1.	Type of embalming wise distribution of cadaveric hemifaces	36
2.	Side wise distribution of cadavers	37
3.	Gender wise distribution of cadaveric hemifaces	38
4.	Comparison of mean scores among all the parameters	42
5.	Comparison of male and female with distance from Posterior auricular artery to Facial nerve in mm scores by t test	43
6.	Comparison of male and female with distance from Posterior auricular artery to Facial nerve in mm scores by t test	44
7.	Relation of Posterior auricular artery to Facial nerve trunk	45
8.	Posterior auricular artery in relation to Mastoid tip	46
9.	Branch of Posterior auricular artery	47

LIST OF PHOTOGRAPHS

FIGURE	TITLE	PAGE NO.
1.	Anterior skin flap elevation after Modified Blaire's incision	61
2.	SCM separated and retracted	61
3.	Relation of PAA with facial nerve trunk 3A – PAA running inferior to facial nerve trunk (Left) 3B – PAA running inferior to facial nerve trunk (Left)	62
4.	4A – PAA running inferior to facial nerve trunk (Right) 4B – PAA running inferior to facial nerve trunk (Right)	63
5.	5A – PAA crossing facial nerve trunk from below (Right) 5B – branch of PAA crossing facial nerve trunk (Right)	64
6.	Branching of posterior auricular artery 6A – stylomastoid branch of PAA (Right) 6B – stylomastoid branch of PAA (Right)	65
7.	Measurement using Vernier calipers	66
8.	Instruments 8A – Instruments 8B – Vernier calipers	67
9.	Cadaveric dissection	68--69

INTRODUCTION

Among all salivary gland tumours, 80% are attributed to parotid gland neoplasms. Surgical intervention is the treatment of choice for majority of the parotid gland tumours. The most untoward complication in case of a parotid surgery is facial nerve injury resulting in facial paralysis, which can affect the quality of life of the patient. Preserving the facial nerve is one of the key goal during parotidectomy¹.

The average risk of transient facial palsy was found to be 65% where as permanent palsy of about 5% even if utmost care is taken to confirm the position and safe guard it in case of a parotid surgery. Even in patients undergoing surgery for non-cancerous parotid gland neoplasm, the incidence of temporary and persistent facial nerve impairment has been noted to be around 26.3% and 1.7% respectively. To avoid iatrogenic facial nerve trauma amidst parotid surgery, early identification of the nerve using anatomical markers are essential.²

It is important to note that parotid gland tumours may cause the facial nerve to shift in various directions, including inward, outward, upward, or downward, depending on the tumour's location.³

Various publications have described a number of surgical landmarks with respect to this approach, which includes the tragal pointer, posterior belly of the digastric muscle (PBDM), styloid process, tympanomastoid suture (TMS) and posterior auricular artery (PAA).^{4,5} Multiple studies and meta – analysis have shown the inconsistency of these landmarks.²

In a study by Al Qatani et al, he mentioned that, between the bony-cartilaginous junction of the external auditory canal superiorly and the mastoid tip

inferiorly, an imaginary line of about 2 cm is drawn. At the middle of this line, the facial nerve's primary trunk is visible⁶.

According to Liu et al in 2018, he noted that posterior auricular artery (PAA) was useful in identification of the facial nerve trunk which arises from external carotid artery (ECA). It is a branch which supplies the seventh nerve at and near to the foramen of the stylomastoid.² Posterior auricular artery typically arises as a posterior branch of ECA above the occipital artery and travels in the direction of foramen stylomastoideum. Upon reaching the stylomastoid foramen, the PAA passes between the tip of the mastoid and pinna, moving toward apex, about 7.5 cm from the tip of the mastoid process.³ Posterior auricular artery, as it has a wider lumen, was better identified.²

The facial nerve has a smaller branch called the posterior auricular nerve (PAN). Before splitting into its two main branches, it emerges from the facial nerve directly beneath the stylomastoid foramen. The postauricular muscles are innervated by the PAN, which runs between the mastoid process and the auricle.⁷

Furthermore, PAA has distinct color features and is pulsatile in comparison to the Posterior Auricular Nerve (PAN). In order to identify the facial nerve after parotidectomy, we therefore thought of the PAA as a possible useful anatomic landmark.¹

Therefore, we are conducting this study to evaluate the association between posterior auricular artery and facial nerve trunk and to determine the validity of using posterior auricular artery as a marker to identify the facial nerve during parotidectomy.

AIMS AND OBJECTIVES

- To study the relation between posterior auricular artery and facial nerve trunk
- To determine the validity of using posterior auricular artery as a marker to identify facial nerve during parotid surgeries.

REVIEW OF LITERATURE

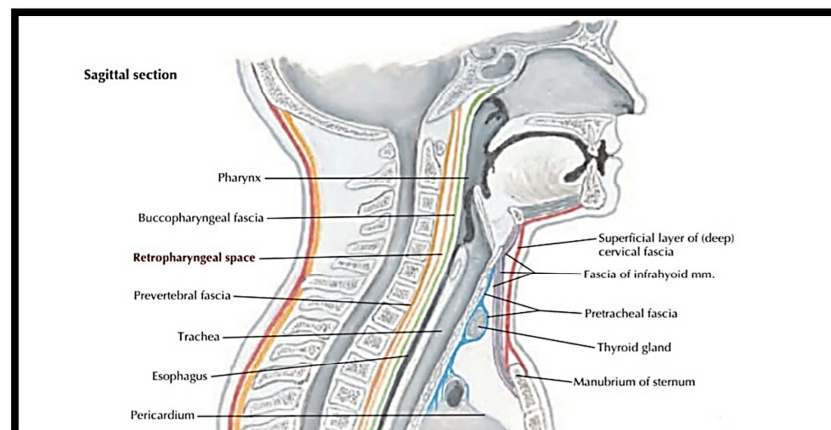
EMBRYOLOGY OF HEAD AND NECK

The head and neck comprises a complex anatomic structure. Considering its complicated nature, as well as the disease processes arising in that region, it requires the expertise of more medical and surgical specialties than any other part of the body.

During the fourth and fifth weeks, an outpouching of the pharyngeal gut occurs just behind the ruptured buccopharyngeal membrane, leading to the formation of five pharyngeal pouches. They extend laterally to form pharyngeal clefts or branchial grooves. Condensation of mesodermal tissue between adjacent pouches and clefts, gives rise to pharyngeal (or branchial) arches. Each of them, provides its own cartilage, vascular, muscular and nerve component.

SUPERFICIAL STRUCTURES OF THE NECK

The hypodermis or superficial fascia, made of fatty connective tissue, surrounds the neck, similar to the skin, along with platysma. The platysma arises from the fascia of the deltoid covering the anterior triangle and the lower part of the posterior triangle of the neck, inserting onto the inferior border of the mandible and into the skin and hypodermis of the face.



*Fig.1 Image depicting the superficial and deep cervical fascia of the neck*⁸

DEEP FASCIA:

The deep lamina of the neck is arranged into 3 main stratas: the investing, prevertebral and pretracheal fasciae. Additionally, the carotid sheath, formed from the layers of deep fascia.

INVESTING FASCIA:

The anterior and posterior triangles of the neck are covered by the investing fascia, which is the outermost coat of deep fascia. Furthermore, the investing fascia splits into two layers near the sternocleidomastoid muscle before reuniting into a single layer around the trapezius muscle. It envelops this muscle, then unites with its opposite side counterpart to form a single sheet again.

The lower portion of the mastoid process, the superior nuchal line, and the external occipital protuberance are the investing fascia's superior attachment points. The fascia divides at these locations to encircle the parotid gland and then continues upward as parotid lamina. The deep layer of the parotid lamina stretches along the temporal bone to the carotid canal, whereas the superficial layer adheres to the lower margin of the zygomatic arch. The stylomandibular ligament, which separates the parotid and submandibular glands, is formed when a portion of this deep layer thickens.

PREVERTEBRAL FASCIA:

Prevertebral lamina surrounds the vertebra and the deep cervical muscle masses, forming floor of the posterior cervical triangle.

PRETRACHEAL FASCIA:

This is a cylindrical fascial layer around the neck's viscera. The buccopharyngeal fascia is the name given to its posterior lamina. The deep strata of the pretracheal fascia envelops the larynx, trachea and lateral parts of the esophagus, forming a complete investment for the thyroid gland.

CAROTID SHEATH:

“Sheath enclosing the carotids is developed from consolidation of connective tissue from the three layers of the deep cervical fascia and encases the major neurovascular bundle in the neck that includes the common carotid artery, internal carotid artery, internal jugular vein and the vagus nerve. The ansa cervicalis, may also be on the surface, embedded within or just inside the carotid sheath”.⁸

CAROTID ARTERIES:

Common carotid artery gives the main supply of blood to the head and neck. Carotid sheath encloses this artery and is compartmentalised to include the common and internal carotid arteries, IJV and vagus nerve along with it.

The common carotid artery has different origins on either side: the right common carotid arises from innominate artery, while on the other side it originates from the aorta's arch. As a result, the left common carotid artery starts in the upper thorax and enters the neck close to the sternoclavicular joint, while carotid artery is completely contained within the neck.

Both carotid arteries typically divide around the thyroid cartilage's level into the external and internal carotid arteries. The internal carotid artery enters the cerebral cavity through the carotid canal of the temporal bone; it does not branch in the neck.

THE EXTERNAL CAROTID ARTERY:

It has 8 divisions which include 4 anterior, 2 posterior and 2 terminal branches. Anterior divisions are superior thyroid, ascending pharyngeal, lingual and facial arteries. Posterior divisions include occipital and posterior auricular artery. End branches comprises of superficial temporal and maxillary artery.

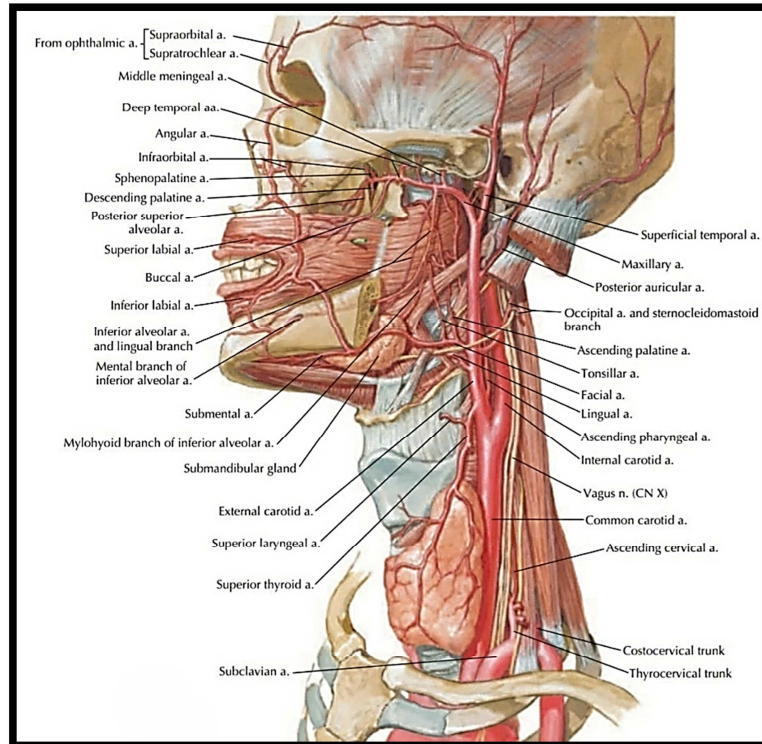


Fig.2 Illustration depicting blood supply of the neck⁹

SUPERIOR THYROID ARTERY:

This branch arises from the ECA, above the common carotid artery division. It descends in the neck, along with superior thyroid vein and external laryngeal nerve, entering the upper part thyroid gland and divides into its terminal branches.

The superior thyroid has 4 named branches such as “infrahyoid, sternocleidomastoid, superior laryngeal, cricothyroid as well as its terminal anterior, posterior and occasional lateral branches at the thyroid gland.”⁴

ASCENDING PHARYNGEAL ARTERY:

Smallest division of ECA, arising after the split of common carotid and passes between the internal carotid and pharynx. It has 3 named branches which include pharyngeal, meningeal and inferior tympanic.

LINGUAL ARTERY :

It originates along with facial artery forming facio-lingual artery. “It emerges close to the back of the greater cornu of the hyoid bone, travels deep to the hypoglossal nerve and then travels between the middle constrictor and hyoglossus muscles to supply the sublingual gland, tonsil, tongue, soft palate, epiglottis and floor of the mouth.”⁸

FACIAL ARTERY:

“The facial artery originates just above the lingual artery and ascends deep to the stylohyoid and posterior belly of the digastric muscles, running along a groove on the posterior side of the submandibular gland. It enters the face by crossing the lower border of the mandible, just in front of the masseter muscle, within the groove for the facial artery.

In the neck, the facial artery gives off several branches, including the ascending palatine, tonsillar, glandular and submental arteries. Upon reaching the face, it runs superficially beneath the platysma muscle. Following a tortuous course, it passes deep to the zygomaticus major, risorius and levator anguli oris muscles, reaching the corner of the mouth. From there, it ascends along the lateral side of the nose and ultimately terminates as the angular artery at the medial corner of the eye.

The main branches of the facial artery in the face include the inferior labial, superior labial, lateral nasal, and angular arteries.”³

OCCIPITAL ARTERY:

It begins on the external carotid artery's posterior part. It travels between the splenius capitis and semispinalis capitis muscles, lodges in the occipital artery groove on the medial face of the mastoid process and travels deep to the hypoglossal nerve and posterior division of the digastric muscle.

POSTERIOR AURICULAR ARTERY:

Deep to the parotid gland, a small branch from external carotid artery arises which originates superior to digastric and stylohyoid muscles which passes between the mastoid prominence and the cartilaginous EAC. It provides vascularisation to the parotid gland as well as the sternocleidomastoid, stylohyoid and digastric muscles.⁸

It has 3 named branches that consists of the stylomastoid branch that goes to the foramen stylomastoideum to innervate the facial nerve, tympanic cavity, mastoid antrum and semi-circular canals. It also provides oxygenated blood to the facial nerve. Additionally, it supplies the facial nerve with oxygenated blood. The medial side of the auricle, extrinsic auricular muscles and the anterior, superior, and posterior auricularis are all supplied by the auricular branch of the artery, which travels along the back of the ear. The skin superior to the posterosuperior area of auricle and the occipitalis muscle are supplied by the occipital branch. In young adults, the artery's posterior tympanic ramus creates an anastomosis around the interior portion of the tympanic membrane with anterior tympanic branch of the maxillary artery.¹⁰

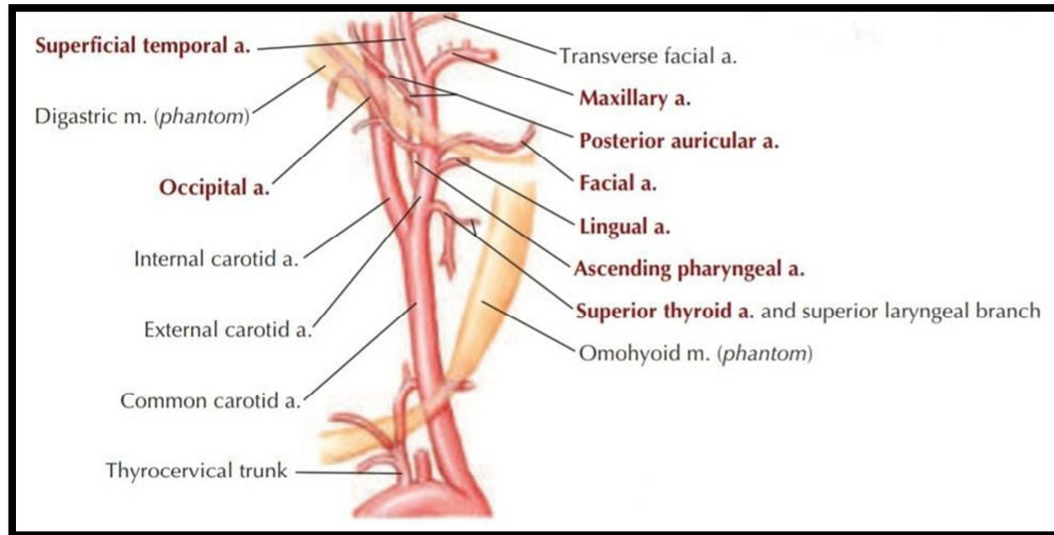


Fig. 3 Branches of the external carotid artery⁹

FACIAL NERVE:

The facial nerve originates from the second branchial arch and develops from a group of neural crest cells located near the otic placode, forming the facio-acoustic primordium, which first appears around the third week of gestation. This primordium then divides into two parts: a caudal main trunk and a rostral sensory trunk (chorda tympani), which extends into the first mandibular arch.

By the eighth week of development, as the second arch differentiates into distinct muscle groups, the peripheral motor branches begin to emerge. At this stage, the horizontal and vertical segments of the facial nerve are positioned anterior to the external auditory canal and start becoming defined. In the weeks following, the facial nerve undergoes significant branching, coinciding with the formation of the muscles responsible for facial expression.

By week 16, all pathways are established, though the nerve still lies superficial and anterior to the ear canal compared to its final position. The facial nerve exits the

stylomastoid foramen in its definitive location by the 30th week of gestation but remains superficial until the mastoid tip develops between 1 and 3 years of age.

The facial nerve is categorized based on anatomical regions into intracranial, intratemporal and extratemporal portions.

INTRATEMPORAL:

This segment passes within the fallopian canal (approximately measuring 30 cm) which is divided into parts according to the area within the temporal bone which consists of meatal, labyrinthine, tympanic (horizontal) and mastoid (vertical) before leaving the stylomastoid foramen. Some branches such as greater petrosal nerve from the geniculate ganglion, nerve to stapedius muscle and chorda tympani nerve arises from the nerve as it passes through the temporal bone.

“The meatal segment of the facial nerve, measuring ~ 1.5 cm enters the porus acousticus in an anterior, superior position. The nervus intermedius passes between the facial and vestibulocochlear.

The facial nerve and nervus intermedius travel in the IAC adjacent to the superior vestibular nerve posteriorly and the cochlear nerve inferiorly. The transverse (falciform) crest separates the facial nerve from the cochlear nerve inferiorly, and a small lateral ridge of bone, Bill bar, separates the facial nerve from the superior vestibular nerve posteriorly. The nerves of the IAC are surrounded by dura all the way to the fundus known as meningeal glove finger”.¹⁰

LABYRINTHINE:

After exiting the IAC at the fundus, it turns forwards and travels through the otic capsule bone for approximately 3 to 6 mm, between the cochlea and the superior semicircular canal.

At the lateral end of the labyrinthine segment, the nerve expands into the geniculate ganglion, carries taste sensations from the anterior two-thirds of the tongue via the chorda tympani nerve, as well as sensory fibers from the soft palate through GSPN.

GSPN provides innervation to the lacrimal gland and nasal mucosal glands, merges with the deep petrosal nerve from the carotid plexus. Together, these nerves form the nerve of the pterygoid (Vidian) canal, which enters the pterygopalatine (sphenopalatine) fossa.

TYMPANIC (HORIZONTAL):

The nerve turns around 180 degrees at the geniculate ganglion and enters the middle ear in the tympanic segment. This segment extends 8 to 11 mm and passes above the oval window.

MASTOID (VERTICAL):

As the facial nerve moves through the epitympanum and nears the inferior surface of the horizontal semicircular canal within the mastoid bone, it transitions into its mastoid segment, where it turns downward and travels towards the stylomastoid foramen, covering a distance of approximately 9 to 18 mm. Along this course, the nerve gives off a motor branch to the stapedius muscle.

The chorda tympani nerve arises variably from the mastoid segment of the facial nerve, with its origin ranging anywhere between the stylomastoid foramen and the pyramid, though it typically emerges about 6 mm above the stylomastoid foramen. Initially, the chorda tympani runs nearly parallel to the facial nerve but then angles forward as it enters the mesotympanum.

Within the mesotympanum, the chorda tympani runs between the incus (below) and the malleus (above) before exiting via the petrotympanic fissure, also known as the canal of Huguier. Once outside the skull, it joins the lingual nerve, where it carries taste sensation from the anterior two-thirds of the tongue and provides preganglionic parasympathetic fibers. These fibers synapse in the submandibular ganglion, from which postganglionic fibers extend to innervate the submandibular, lingual, and other minor salivary glands.

EXTRATEMPORAL:

Foramen stylomastoideum is the point of exit of facial nerve. “The nerve pierces the parotid gland and branches into the temporofacial and cervicofacial branches at the pes anserinus to supply motor innervation to the muscles of facial expression. Prior to which, the nerve gives off the posterior auricular nerve supplying general sensory innervation to the skin of the posterior ear canal and concha as well as motor innervation to the intrinsic muscles of the auricle and the occipitalis muscle”.⁸

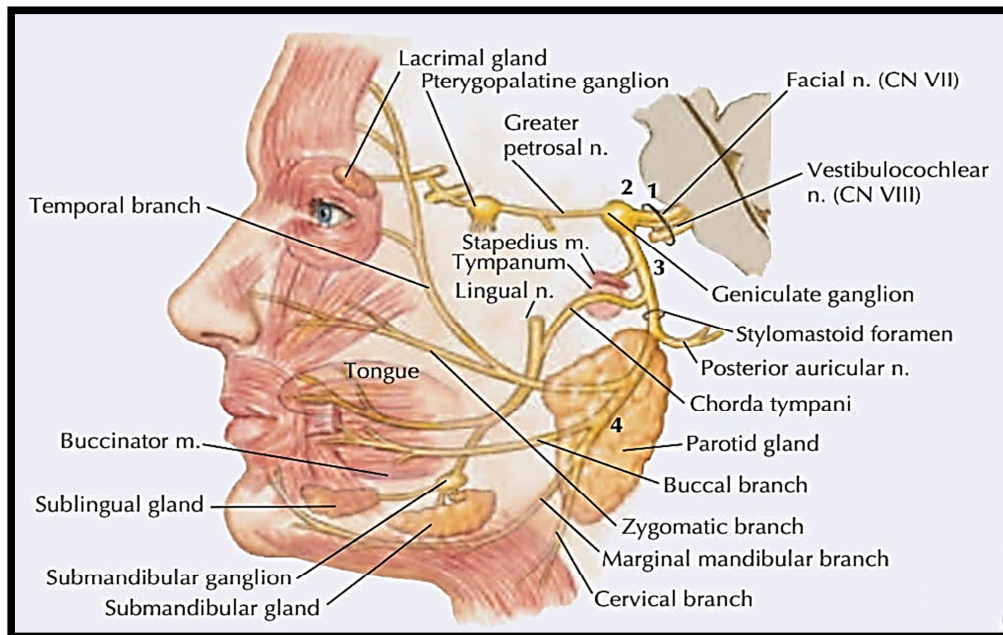


Fig. 4 Branches of facial nerve⁹

The digastric branch innervates the posterior belly of the digastric muscle and the stylohyoid branch innervates the stylohyoid muscle. Facial nerve has 5 terminal branches which supply the muscles of facial expression: temporal, zygomatic, buccal, mandibular and cervical. The facial nerve is positioned deep to the facial fascia, also known as the superficial musculoaponeurotic system (SMAS) and supplies the muscles of facial expression from their deep surface. The soft-tissue structure of the face is organized into a series of concentric layers, which include the skin, subcutaneous fat, superficial fascia, mimetic muscles, deep facial fascia (SMAS) and a deeper plane that houses the facial nerve, parotid duct and buccal fat pad¹⁰.

“The temporal division of the facial nerve consists of three to four branches that travel obliquely along the undersurface of the temporoparietal fascia after crossing the zygomatic arch, approximately 3–5 cm lateral to the lateral orbital margin. The lower branches pass beneath the upper portion of the orbicularis oculi muscle for about 3–4 mm before penetrating it to provide innervation. The upper two branches typically enter the frontalis muscle near the supraorbital ridge, extending up to 3 cm above the lateral canthus.

The zygomatico-buccal division of the facial nerve consists of five to eight branches that supply the lip elevators, as well as the lower portions of the orbicularis oculi, orbicularis oris and buccinator muscles.¹¹

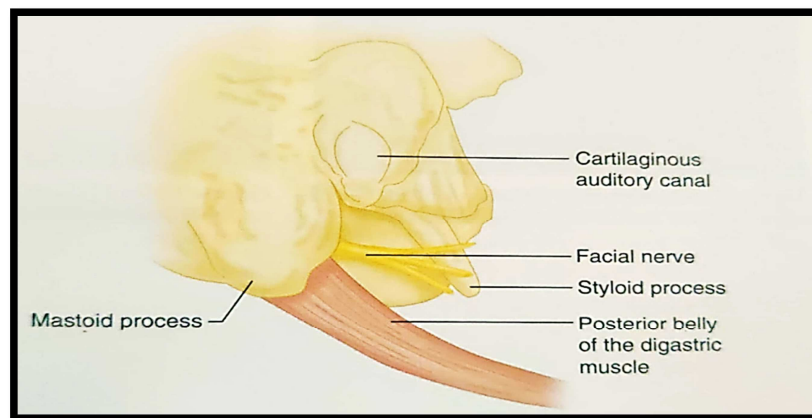
The marginal mandibular division of the facial nerve consists of one to three branches that emerge up to 2 cm below the mandibular ramus and follow an upward arc, crossing the mandible at a midpoint between the angle and the mental protuberance. These branches travel along the deep surface of the platysma and pass superficially over the facial vessels at a location approximately 3.5 cm from the edge of the parotid gland. Typically, distinct branches are present to innervate the depressor

anguli oris, depressor labii inferioris and mentalis muscles, along with a variable superior ramus that supplies the upper platysma and the lower orbicularis oris.

The cervical division of the facial nerve consists of a single branch that exits the parotid gland well below the mandibular angle and courses along the deep surface of the platysma. It provides innervation to the muscle by entering at the junction of its cranial and middle thirds, approximately 2–3 cm below the vascular pedicle of the platysma”.¹²

FACIAL NERVE POINTERS:

Facial nerve paralysis is a known complication during parotid surgery. Accidental injury to the nerve can lead to either temporary or permanent paralysis, corneal irritation due to loss of motor control, Frey syndrome, pain or changes in facial appearance. Therefore, safely identifying the main trunk of the facial nerve using surgical landmarks remains crucial, even when intraoperative facial nerve monitoring is used. “Key anatomical landmarks that help identify the location of the facial nerve's main trunk during surgery include the tragal pointer, styloid process, tympanomastoid suture, tip of the mastoid process, retromandibular vein, posterior auricular nerve and the posterior belly of the digastric muscle”.¹²



*Fig.5 Diagram depicting different pointers to identify facial nerve.*¹³

TYMPANOMASTOID SUTURE:

The tympanomastoid suture marks the boundary between the petrous and tympanic portions of the temporal bone, specifically where the tympanic part meets the mastoid. It becomes clearly visible after exposing the anteroinferior quadrant of the mastoid's lateral surface. Extending along the posteroinferior edge of the tympanic part, this suture has a forward-opening pitchfork shape, with its base housing the stylomastoid foramen (SMF), from which the facial nerve trunk emerges.

TRAGAL POINTER:

Lamina tragi or the tragal cartilage serves as a reference point for locating the facial nerve. At the junction between bone and cartilage, it forms a triangular projection known as the triangular process, initially described by the anatomist Schwalbe and referred to in literature as Schwalbe's line. It is positioned approximately 7.5 mm (± 2.5 mm) anterior and deeper to this point.

POSTERIOR BELLY OF DIGASTRIC:

The muscle should be dissected up to its insertion at the skull base, specifically in the digastric groove, which extends from the stylomastoid foramen. Tracing the muscle's anterior border in an inferosuperior direction reveals the emergence of the facial nerve approximately 1 cm superior to the upper border of posterior belly of the digastric muscle, at the point where it intersects with the angle formed by the muscle and the inferior margin of the tympanic part of the temporal bone. As this landmark is movable, the measurements might vary depending on the force of retraction.¹⁴

RETROMANDIBULAR VEIN:

Menelaos Zoulamoglou et al in his study stated that retromandibular vein can also be used as a pointer to identify facial nerve. It usually runs superficial to inferior branches of the facial nerve i.e. marginal mandibular and cervical divisions.¹⁵

POSTERIOR AURICULAR NERVE:

“Posterior auricular nerve arises from facial nerve trunk as the first branch before it enters the parotid gland and supplies superior auricular and posterior auricular muscles and occipitofrontalis muscle. A few recent studies have suggested the use of posterior auricular nerve as a potential surgical landmark for facial nerve trunk identification”.¹⁶

STYLOMASTOID REGION:

STYLOMASTOID FORAMEN:

Between the base of the styloid process and the mastoid process, on the lower aspect of the petrous part of the temporal bone, is a tiny opening known as the stylomastoid foramen.¹⁷

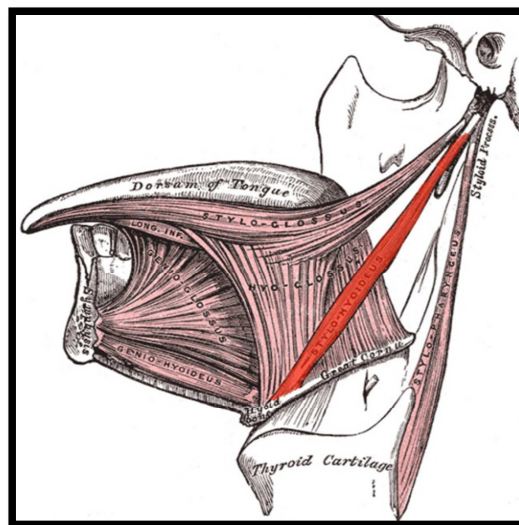


Fig. 6 Image illustrating the stylomastoid region¹⁸

This foramen marks the termination of the facial canal, connecting the internal acoustic meatus situated in the posterior cranial fossa to the skull base. It serves as a passage for the facial nerve and the stylomastoid branch of the posterior auricular artery. The primary motor portion of the facial nerve traverses the stylomastoid foramen. Upon exiting the cranial cavity through this opening, the facial nerve continues through the parotid gland, where it bifurcates into two main divisions: the temporofacial and the cervicofacial branches.¹²

STYLOID PROCESS:

“The styloid process is a slender, needle-like bony projection extending from the inferior aspect of the petrous part of the temporal bone. It serves as the attachment site for three muscles the stylopharyngeus, stylohyoid and styloglossus as well as the stylohyoid and stylomandibular ligaments.”⁸

Typically measuring between 2 to 3 cm in length, the styloid process narrows from its base to its tip. Although rare, variations such as curvature of this bony projection have been observed.

The styloid process is situated anatomically between the internal and external carotid arteries. Furthermore, a number of important landmarks are close by. It is located medially next to the internal jugular vein, the sphenomandibular ligament and the superficial temporal, lingual, facial, maxillary and internal carotid arteries. Laterally, it is close to the posterior belly of the digastric muscle, the facial and hypoglossal nerves, and the occipital artery.¹⁸

STYLOHYOID MUSCLE:

The stylohyoid muscle is a paired, narrow suprahyoid muscle of the neck that extends from the base of the skull to the hyoid bone. It is positioned close to the digastric muscle, running along the superior edge of its posterior belly.

Comprising a single belly, the muscle originates posterior to the styloid process and extends anteroinferiorly. It connects to the hyoid bone at the junction of its body and greater cornu, positioned just above the omohyoid muscle's insertion. Near this attachment, the muscle is pierced by the intermediate tendon of the digastric muscle and remains closely associated with the posterior belly of the digastric throughout its course.¹⁷

Together, the stylohyoid and styloglossus muscles create a pathway through which the external carotid artery courses superiorly and the facial artery passes inferiorly, transitioning from the retrostyloid to the prestyloid region.¹⁸

INTRA – OPERATIVE FACIAL NERVE MONITORING:

A recent evaluation by Sood et al. examined the effectiveness of intraoperative facial nerve monitoring during parotidectomies. The study found that “in cases where the patient had not previously undergone surgery, intraoperative facial nerve monitoring reduced immediate postoperative facial nerve weakness but did not prevent permanent nerve damage.”¹²

Intraoperative monitoring has greatly enhanced postoperative facial nerve (FN) function and has become an essential tool for surgeries involving the FN. However, it is crucial that this tool is used and maintained correctly to fully realize its benefits and prevent undesirable outcomes.¹⁹

Several intraoperative factors can heighten the risk of facial nerve (FN) injury. Direct trauma may occur through laceration during dissection or drilling near the nerve. Thermal damage is another concern, as electrocautery, laser energy, or excessive heat from a diamond drill can harm the nerve. Additionally, iatrogenic injury may result from excessive stretching during dissection, which can disrupt the myelin sheath, causing varying degrees of axonal damage or impair the nerve's blood supply. Another potential mechanism of FN injury is compression, which can lead to facial paralysis due to entrapment neuropathy.

A mild, temporary injury may occur when the myelin sheath surrounding the nerve is disrupted, leading to delayed latency in the recorded compound muscle action potential (CMAP) from the facial muscles. In contrast, a more severe injury involves axonal disruption, resulting in reduced CMAP amplitude. The extent of axonal loss can be roughly assessed by comparing the amplitude to a prior baseline measurement. When axonal damage occurs, the distal portion of the affected axons undergoes Wallerian degeneration approximately four days after the injury.

FACIAL NERVE MONITORING TECHNIQUES:

Various techniques for intraoperative facial nerve (FN) monitoring have been adopted in clinical practice, including intraoperative electromyography (EMG), compound nerve action potential (CNAP) recording, facial muscle F wave analysis, and video monitoring. Among these, EMG remains the most commonly utilized method.

There are two primary approaches for using intraoperative electromyography (EMG) to monitor the facial nerve (FN). The first involves monitoring mechanically evoked or spontaneous EMG activity, which is continuously recorded to detect

thermal, mechanical or electrical irritation of the FN caused by surgical manipulation. The second method utilizes electrical stimulation of the exposed FN to elicit an EMG response from the corresponding facial muscles, aiding in the identification and localization of the nerve.

Mechanically evoked or spontaneous EMG activity refers to motor unit activity triggered in facial muscles due to surgical manipulation of the FN. This activity, also known as neurotonic discharges, consists of high-frequency bursts of motor unit action potentials (MUAPs) generated in response to mechanical or metabolic irritation of the nerve supplying the muscle.

In contrast, electrical stimulation induces a synchronized composite electrical response in the target muscle, known as the compound muscle action potential (CMAP). Studies on intraoperative FN monitoring frequently analyze CMAP threshold, latency, and amplitude to assess prognostic value.

When the FN is stimulated, not all fibers respond equally at the same current intensity. Larger diameter fibers, which have lower internal resistance, are activated first. The minimal current required to generate a response is termed the threshold. As the stimulus intensity increases beyond the threshold, smaller diameter fibers are recruited, leading to an increase in CMAP amplitude as more motor units are activated. When all muscle fibers are engaged, the stimulation is considered suprathreshold.

CMAP amplitude reflects the total number of muscle fibers contributing to the response, provided they fire synchronously. Intraoperatively, amplitude is typically measured from the most negative peak to the most positive peak (peak-to-peak

amplitude). A reduction in CMAP amplitude is primarily due to fewer activated axons, though it can also result from partial conduction block.²⁰

DEVELOPMENT OF PAROTID:

The parotid gland originates from the ectoderm. During the 6th week of fetal development, the parotid primordium forms as a cord of cells from the ectodermal lining of the mouth's vestibule, near the angle of the developing oral fissure. This structure extends backward toward the ear and undergoes repeated branching. The parotid bud and its branches then hollow out to create the duct system and acini.

PAROTID BED:

“Area between the ramus of mandible, external acoustic meatus and mastoid and styloid process of temporal bone is the parotid bed. This bed is bounded medially by the posterior belly of digastric muscles and the muscles of styloid process. Inferior aspect of the bed is by the supero-anterior border of the sternocleidomastoid muscle which houses the parotid gland.”⁴

PAROTID GLAND

It is the largest of the 3 main salivary glands and is encased in a covering that is part of the deep cervical fascia. It is situated on either side of the face. The gland's superficial portion extends upwards over the masseter muscle to the zygomatic arch.

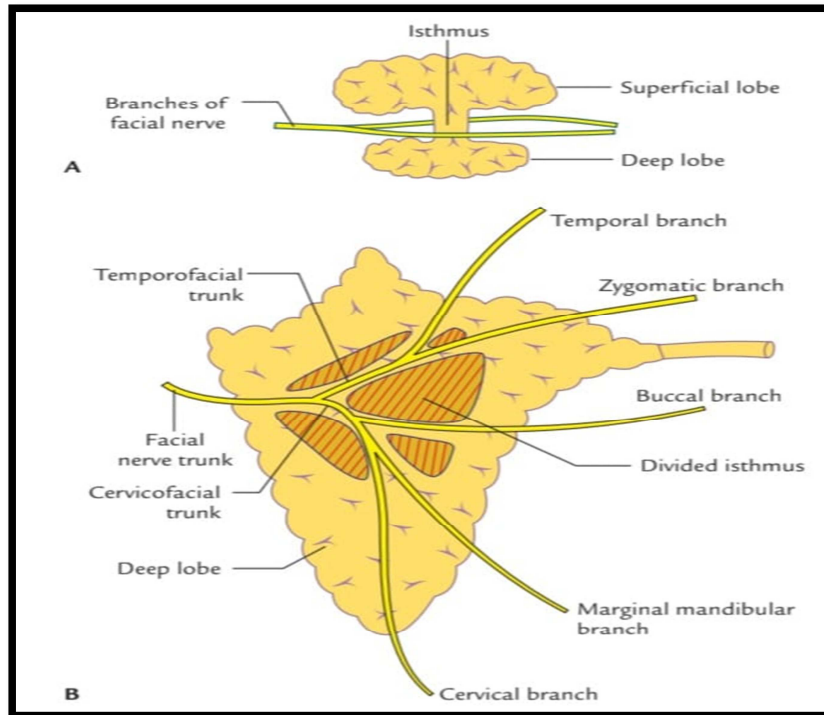


Fig 7. Diagram depicting parotid gland along with facial nerve branches running through the parenchyma.¹³

Inferiorly, it is situated between the mastoid process, the sternocleidomastoid muscle and the angle of the mandible, where it covers the posterior surface of the masseter muscle. Medially, the gland stretches deeper into the parotid bed, up to the styloid process.

From the anterior part of the superficial portion of the gland, the parotid duct (Stensen's duct) emerges, running forward above the masseter muscle. It then turns medially into the buccal pad of fat, piercing the buccinator muscle to reach the oral vestibule, where it opens at the parotid papilla, opposite the second maxillary molar, to deliver the parotid saliva.

On the superficial side of the gland, it is related to the branches of the greater auricular nerve from the cervical plexus and small lymph nodes that drain the superficial region. On the deep side, the gland is in proximity to the external and internal carotid arteries, the internal jugular vein and the vagus and glossopharyngeal nerves, as it sends projections medially toward the styloid process.

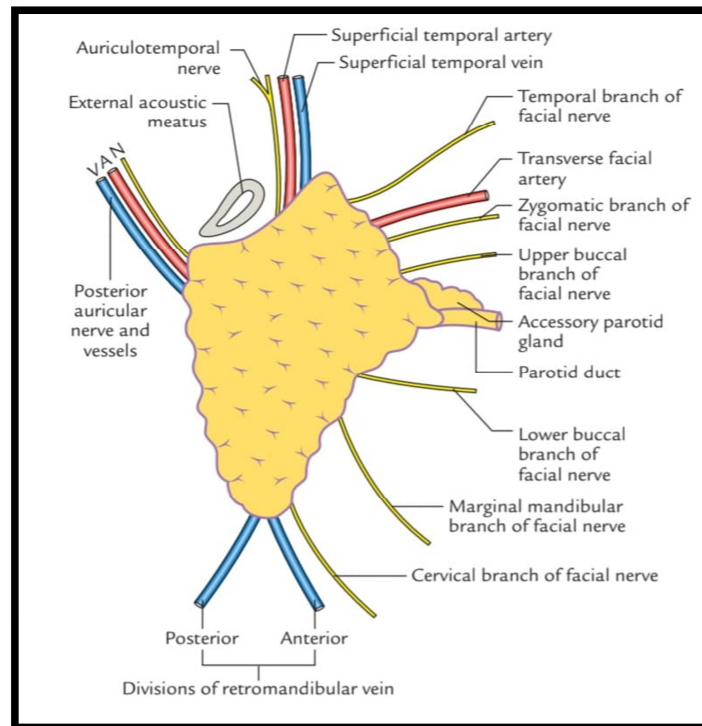


Fig.8 Structures emerging from the periphery of the parotid gland.¹³

Several key structures pass through the parotid gland. “The external carotid artery, along with its branches (posterior auricular, maxillary, and superficial temporal arteries), enters the gland. The retromandibular vein, as well as its tributaries, also passes through it. The facial nerve exits the stylomastoid foramen and enters the gland, where it forms a plexus before branching out to innervate the muscles of facial expression. Additionally, the auriculotemporal nerve, a branch of the mandibular division of the trigeminal nerve, enters the gland's deep side near the neck of the mandible and exits just below the root of the zygomatic arch.

Structures that enter the parotid gland and exit through its posterior, superior, inferior and anterior surfaces. The posterior auricular artery emerges from the gland's posterior aspect. At the superior margin, the superficial temporal artery and vein, auriculotemporal nerve and temporal branches of the facial nerve can be observed. Inferiorly, the retromandibular vein exits the parotid gland just before merging with the posterior auricular vein to form the external jugular vein.

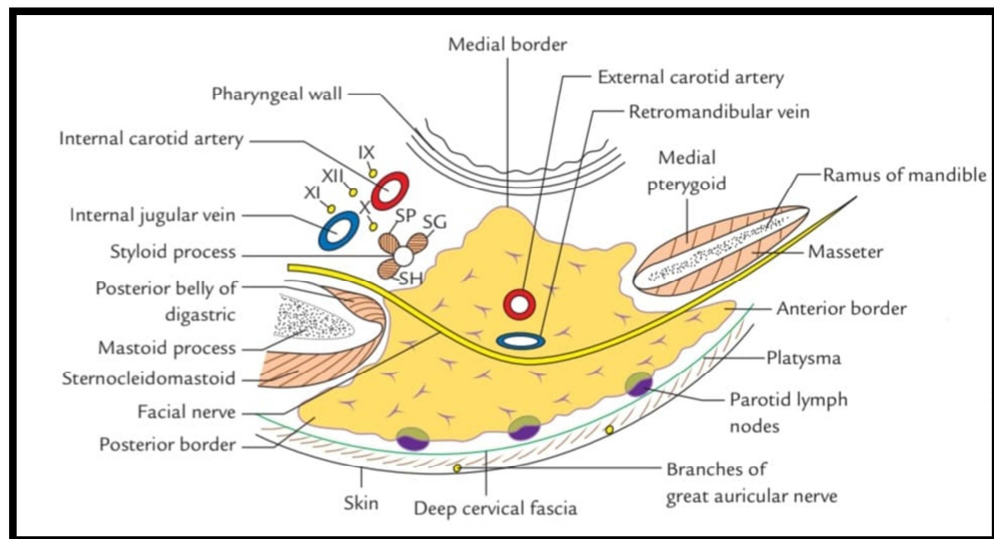


Fig.9 Relations of the parotid gland¹³

Emanating from the entire facial margin of the gland are the terminal branches of the facial nerve, which are grouped into the five major branches: Temporal, Zygomatic, Buccal, Mandibular and Cervical.”

BLOOD SUPPLY:

The posterior auricular artery supplies the parotid gland with vascular branches, while additional smaller glandular branches come from the superficial temporal and transverse facial arteries. Venous drainage is facilitated by tributaries that pass through the gland and ultimately drain into the external jugular vein.

LYMPHATIC DRAINAGE:

Lymphatic drainage occurs through lymph nodes located both superficially and within the gland itself, with the lymph being transported to the superficial and deep cervical lymph nodes.

NERVE SUPPLY:

“The parotid gland receives both sensory and autonomic innervation. General sensation is provided by branches of the great auricular nerve. The sympathetic innervation reaches the gland via postganglionic fibers from the carotid plexus, which travel along the external carotid artery and its branches within the gland.

Parasympathetic innervation is carried by the auriculotemporal nerve. Preganglionic parasympathetic fibers from the glossopharyngeal nerve travel through its tympanic branch to the otic ganglion, where they synapse with postganglionic neurons. These fibers then join the auriculotemporal branch of the mandibular division of the trigeminal nerve to reach the parotid gland, where they regulate secretomotor activity”.¹³

SUPERFICIAL PAROTIDECTOMY:

A carefully planned incision should be marked, extending from the preauricular region, curving around the earlobe toward the mastoid tip, and then continuing downward to blend with a natural neck crease below the mandibular angle. A single crosshatch should be marked near the lobule before making the incision.²¹

In the facial region, the anterior skin flap should be elevated superficial to the parotid fascia, ensuring that subcutaneous fat remains attached to the flap. Strong traction and countertraction, applied as deeply into the wound as possible, aid in defining the correct plane.

“In the neck, the flap can be elevated either superficial or just deep to the platysma. Throughout the procedure, it is critical to palpate the tumor continuously to prevent inadvertent entry. Posteriorly, the neck portion of the incision should be deepened until the sternocleidomastoid (SCM) muscle is reached, where the greater auricular nerve can be identified. This nerve is typically sacrificed, leading to some permanent numbness of the earlobe, although the posterior branch, which supplies the earlobe, may sometimes be preserved. The anterior border of the SCM should be delineated and followed up to the mastoid tip while ensuring the fascia is lifted anteriorly off the muscle. To expose the posterior belly of the digastric muscle—an important landmark—the deep cervical fascia should be incised. Around the ear, the incision should be deepened along the cartilage of the external auditory canal (EAC) with care to avoid damaging it. The ‘tragal pointer’ should be identified, as it serves as a useful landmark for locating the facial nerve”.¹³

At this stage, the surgeon should divide tissue anterior to the mastoid process to connect the dissection in the EAC region with that around the SCM. The depth of this dissection should remain superficial to the digastric muscle. The facial nerve exits the stylomastoid foramen just above the posterior belly of the digastric muscle and at a similar depth. The tragal pointer is situated approximately 1 cm superficial and superior to this point. The nerve runs in an anterior, superficial, and inferior direction.

Before attempting to locate the facial nerve, the surgeon should ensure that the posterior belly of the digastric muscle and the tragal pointer are well exposed. The nerve should be identified using Adson clamp or artery forceps, gently opening them in a direction parallel to the nerve to avoid inadvertent injury.

Once the facial nerve is identified, it should be traced to its bifurcation before any parotid tissue is divided. The branches should then be followed sequentially,

beginning either superiorly or inferiorly. To divide the parotid tissue safely, a clamp should be inserted along the nerve, lifted away and opened. The assistant should then cut the tissue between the tines of the clamp using the "insert-lift-spread-cut" technique. The surgeon should aim to divide some tissue with each maneuver to maintain steady progress.

As the branches are traced distally, they become more superficial, especially in the upper divisions. Dissection should begin over a branch that is clearly separate from the tumor and then proceed systematically. Parotid tissue should be divided in a manner that ensures a clear margin from the tumor. After two branches have been dissected, the tissue at the anterior portion of the gland can be divided, allowing the superficial lobe, containing the tumor, to be lifted either upward or downward. Dissecting from both superior and inferior approaches enhances mobilization of the superficial lobe before directly addressing the tumor.

For tumors located in either the upper or lower poles of the gland, it may not be necessary to remove the entire superficial lobe. Instead, the tumor can be excised with an adequate margin while only following either the upper or lower division branches. Frequently, the deep portion of the tumor capsule lies directly adjacent to the facial nerve branches. In such cases, the tumor should be meticulously separated from the nerve to avoid rupturing the capsule. If done carefully, this approach does not increase the risk of recurrence.

Before closure, a drain should always be placed to prevent postoperative accumulation of saliva and serous fluid, ideally remaining in place for at least 48 hours. Finally, the wound is closed in layers".³

TOTAL PAROTIDECTOMY:

“A modified Blair incision is outlined using a skin marker and a 2-0 silk suture is placed in the earlobe. The skin is then incised. Once the skin flap is fully elevated, an elliptical incision is made around the tract or calculus. The dissection proceeds through the platysma muscle down to the gland.

Both blunt and sharp dissection are performed along the sternocleidomastoid (SCM) muscle toward the mastoid tip. The greater auricular nerve is identified and transected. The mastoid tip is palpated, marking the first key landmark for locating the facial nerve. The posterior belly of the digastric muscle is then exposed.

The perichondrium of the external auditory meatus (EAM) is incised, and the anterior aspect of the EAM is accessed using the end of a scalpel handle. The main trunk of the facial nerve is typically located 1–2 cm anterior and inferior to the cartilaginous pointer. Since the nerve exits between the mastoid tip and the bony EAM, palpating the bony EAM just deep to the pointer enhances accuracy. The facial nerve trunk is a deep and consistent structure as it emerges from the stylomastoid foramen and enters the parotid gland. The dissection continues anteriorly, tracing the upper and lower divisions of the facial nerve.

The tissue between these two divisions, resting on the masseter muscle, represents the deep lobe of the parotid gland. When necessary, the deep lobe is sharply dissected from the masseter muscle while mobilizing the facial nerve, ideally keeping the deep lobe attached to the superficial lobe. At the anterior margin of the masseter muscle, Stenson’s duct is identified. Dissection follows the duct until the buccal mucosa is exposed. An incision is made in the buccal mucosa, and the papilla is excised along with the entire specimen.

All parotid-like tissue is carefully identified and removed, which often requires elevating various branches of the facial nerve. The wound in the buccal mucosa is closed with 3-0 chromic catgut sutures. After achieving meticulous hemostasis and irrigating the wound, a hemovac drain is placed. Before closing, all branches of the facial nerve are stimulated. If the nerves appear anatomically intact but do not respond strongly to stimulation, function is expected to return, though potentially at a slower rate. The wound is then closed in layers”.²²

MATERIALS AND METHODS

Source of Data: Wet cadaveric hemifaces both left and right available from the Department of Anatomy at Jawaharlal Nehru Medical College, K.L.E Academy of Higher Education and Research, Belagavi.

Study Design: Observational study

Study Period: 1 year study

Sample Size: 20

Sample size formula: The minimum sample size formula based on prevalence rate is:

$$n = \frac{z_{\alpha}^2 P(1-P)}{d^2}$$

Where P is the prevalence rate and d is the percentage likely difference in the prevalence.

Z α is linked with the level of significance. For 5% level of the significance $z_{\alpha} = 1.96$.

Ref: Feasibility of Using Posterior Auricular Artery as Landmark for Identification of Facial Nerve Trunk in Parotid Surgery: A Cadaver Study by Gontu Gopi Satya Sai Reddy et al.

The parameter considered in the calculation is the prevalence rate of the most common course of posterior auricular to be taking a curving loop superficially over the mastoid tip and was found in 71.42% of cadaveric dissections.

With P = 71.2% and d = 30% of P = 21.43% the sample size is 17.

Sampling technique: Wet cadaveric hemifaces both left and right available from the department of anatomy at Jawaharlal Nehru Medical College, K.L.E Academy of Higher Education and Research, Belagavi.

Inclusion Criteria: All cadaveric hemifaces available during the study period at the Department of Anatomy, JNMC, Belagavi.

Exclusion Criteria: Damaged and diseased cadavers.

Data collection procedure: A standard cervico-mastoid-facial incision was taken in the cadavers. The incision followed the anterior contour of the ear and then curved gently behind the auricle and extended anteriorly at least 2 cm beneath the lower border of the mandible.

The skin with superficial lamina was elevated to visualise the parotid gland and sternocleidomastoid muscle (SCM). Anteriorly, SCM was delineated from the parotid capsule by blunt dissection which was detached distally. The posterior division of digastric muscle was divided posteriorly from the gland.

PAA was identified at the medial border of the posterior belly of digastric muscle. The artery was traced till its origin from external carotid artery.

The artery was traced posteriorly till its termination into the terminal branches. Stylomastoid artery branch of posterior auricular artery was traced superiorly and its relation with facial nerve trunk was noted in all the cases.

The facial nerve trunk was identified using landmarks: tragal pointer, posterior belly of digastric muscle and tympanomastoid suture.

The relationship of the trunk of facial nerve and posterior auricular artery was explored and recorded. The distance between the posterior auricular artery at the point

of its branching and the facial nerve trunk was measured, facial nerve – posterior auricular artery (FN-PAA).

The distance between the tympanomastoid suture (TMS) and facial nerve trunk (TM-FN) and tympanomastoid suture and the posterior auricular artery at its branching (TM-PAA) was measured in all cases.

The distance between mastoid tip (MT) and facial nerve trunk (MT-FN) and mastoid tip and posterior auricular artery at its point of branching (MT-PAA) was measured. All measurements was made using calibrated Vernier calipers.

Data processing and analysis/statistical analysis: Since the study is of observational study, the plan of analysis will be as follows.

For the continuous quantitative variables mean and standard deviation were calculated. For the purpose of comparison, if the data is divided into two groups with respect to certain qualitative characteristic, the continuous variables were compared using suitable tools of statistics like student's unpaired t test. The pre and post treatment measures were compared using student's paired t test.

If required, Receiver operating characteristic (ROC) analysis, sensitivity, specificity, cut off value etc., were calculated.

Discrete variables were represented by median.

The categorical data were expressed in terms of rates, ratios and percentages. The association between the outcome, clinical and demographic characteristics will be tested using Chi-square test, test of proportion or Fisher's exact test.

For discrete variables non parametric tests were used.

Apart from the above suitable tools like ANOVA, correlation, regression etc., were used according to the need.

Suitable graphs were used to depict the comparison. For all the tests the value of p less than 5% (0.05) were considered significant

RESULTS

Twenty wet cadaveric hemifaces of different geographic areas of India including both genders belonging to the adult age group available in the department of Anatomy of KAHER'S Jawaharlal Nehru Medical College from June 2023 to May 2024 were studied on the anatomical location and variations of PAA and FNT along with its relation with respect to each other and their morphometric details. We also analysed few of the other facial nerve pointers which have been found to be helpful over the years. All observations recorded in the study are described under the following headings.

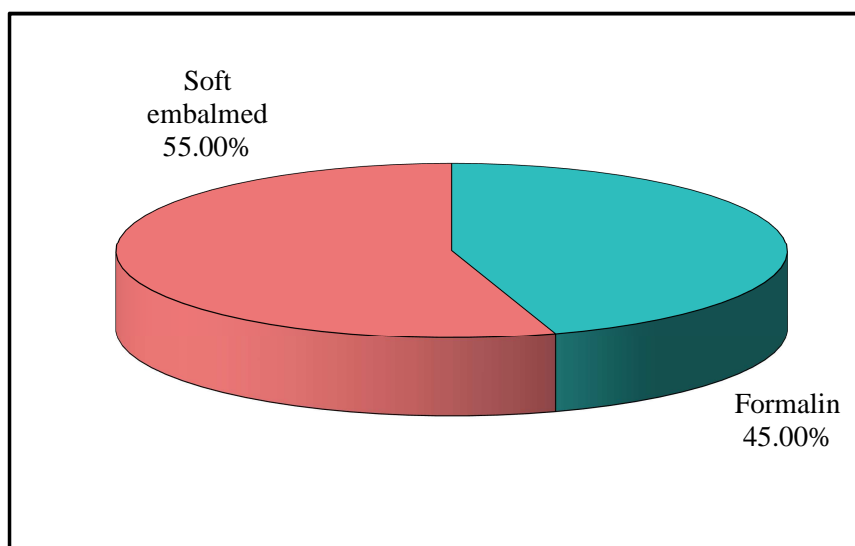
Type of embalming wise distribution:

Out of 20 cadaveric hemifaces, 9 (45%) were formalin based and 11 (55%) were soft embalmed. The embalming wise distribution is mentioned below (Table 1, Graph 1).

Table 1: Type of embalming wise distribution of cadaveric hemifaces

Type of Embalming	Number of cadaveric hemifaces	Percentage of cadaveric hemifaces
Formalin	9	45.00
Soft embalmed	11	55.00
Total	20	100.00

Graph 1: Type of embalming wise distribution of cadaveric hemifaces

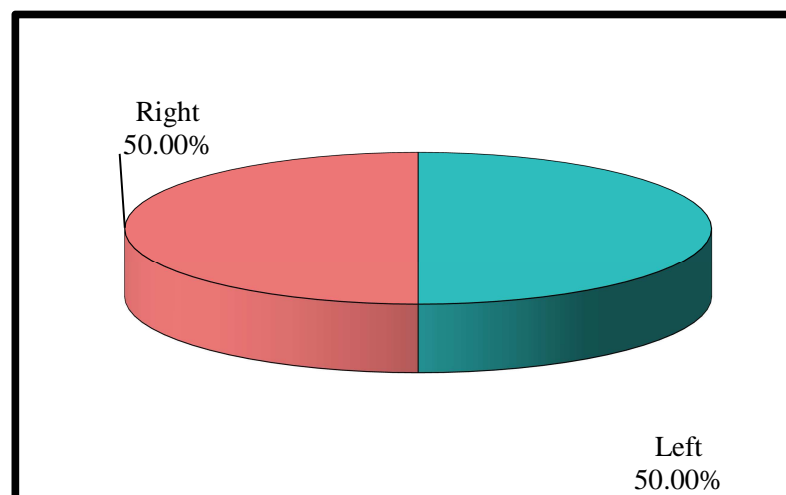


Side wise distribution:

Out of 20 cadaveric hemifaces, it was distributed equally with 10 left sided and 10 right sided hemifaces as shown in the table and graph below (Table 2, Graph 2).

Table 2: Side wise distribution

Sides of cadaveric hemifaces	Number of cadaveric hemifaces	Percentage of cadaveric hemifaces
Left	10	50.00
Right	10	50.00
Total	20	100.00

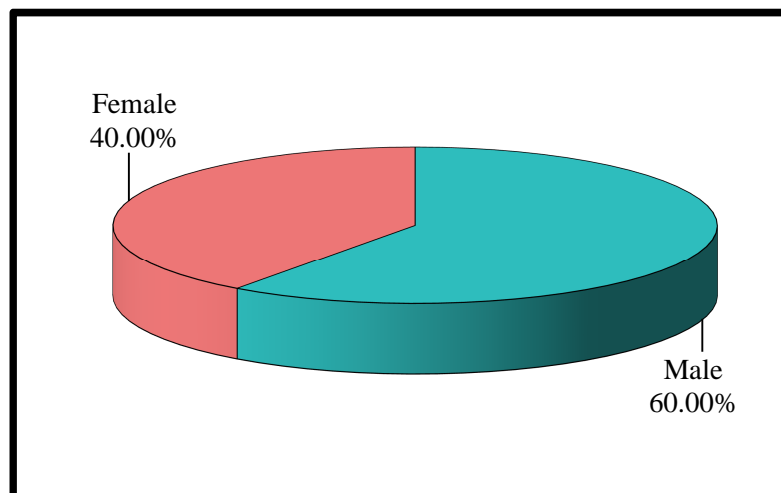
Graph 2: Side wise distribution

Gender wise distribution:

Out of 20 cadaveric hemifaces, there were 12 male and 8 female cadavers which were taken for dissection as mentioned in the table and graph below (Table 3, Graph 3).

Table 3: Gender wise distribution of cadaveric hemifaces

Gender	Number of cadaveric hemifaces	Percentage of cadaveric hemifaces
Male	12	60.00
Female	8	40.00
Total	20	100.00

Graph 3: Gender wise distribution of cadaveric hemifaces

Distance between different pointers of facial nerve with facial nerve:

20 cadaveric hemifaces were used in this study to assess the relation between posterior auricular artery and facial nerve trunk and measuring the distance between them. We also compared distances with other facial nerve pointers such as tympanomastoid suture line, tragal pointer and mastoid tip.

Table 4: Normality of different parameters by Shapiro-Wilk test

Parameters	Shapiro-Wilk	Df	p-value
Distance from PAA to FNT in mm	0.9420	20	0.2560
Distance from PAA to MT in mm	0.9000	20	0.0510
Distance from PAA to TP in mm	0.8280	20	0.0620
Distance from FN to TMS in mm	0.9390	20	0.2320
Distance from FN to MT in mm	0.9710	20	0.7660
Distance from FN to TP in mm	0.9340	20	0.1840

Df-Degree of freedom

Note that, the scores of all parameters follow normal distribution as shown in the table above (Table 4). Therefore, the parametric tests were applied.

Normality Test (Shapiro-Wilk):

The Shapiro-Wilk test assesses whether the data follows a normal distribution. The null hypothesis (H_0) of this test states that the data is normally distributed. If the p-value is greater than 0.05, we fail to reject H_0 , meaning the data is normally distributed.

- All parameters have p-values greater than 0.05, indicating that they follow a normal distribution.
- As a result, parametric tests were applied for further analysis.

Summary of Parameters:

The descriptive statistics summarize the different distances measured in the study:

- **Mean and Standard Deviation (SD):** These values represent the central tendency and dispersion of each distance.
- **95% Confidence Interval (CI):** The range within which the true mean is expected to lie with 95% confidence.

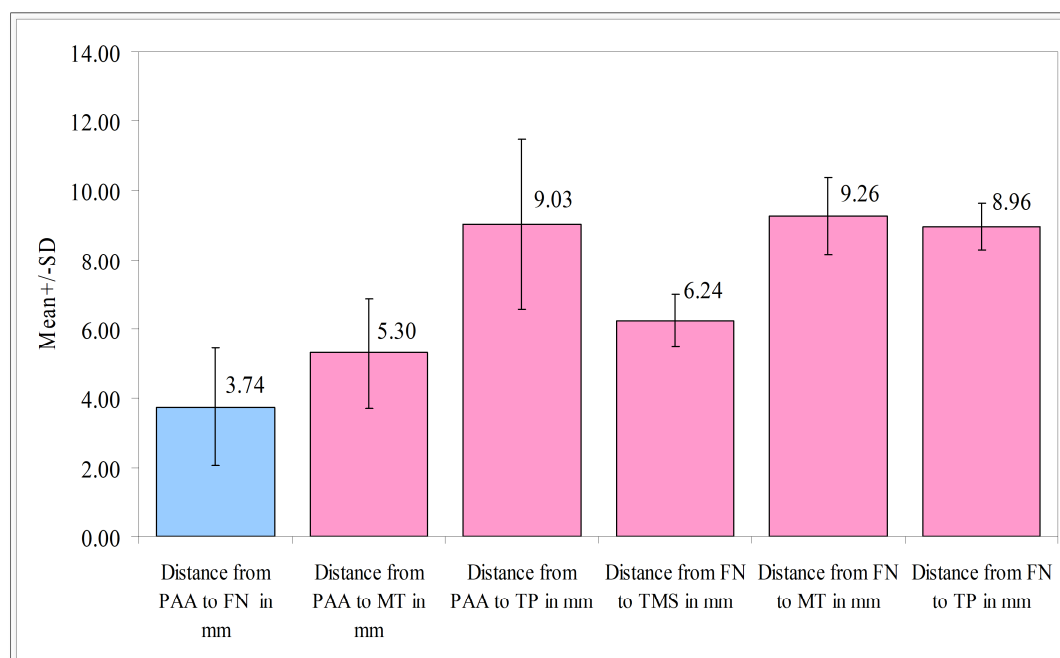
Distances between different parameters in relation to facial nerve and posterior auricular artery:

Below is a table and graph (Table 5, Graph 4) which shows the mean distances between different parameters. The main aim of our study is to measure the distance between posterior auricular artery (PAA) and facial nerve trunk (FNT) and to find a relation between them.

Table 5: Comparison of mean scores among all the parameters

Distances	Min	Max	Mean	SD	95% CI for mean	
					Lower	Upper
Distance from PAA to FNT in mm	1.30	7.00	3.74	1.69	2.95	4.53
Distance from PAA to MT in mm	3.00	9.00	5.30	1.58	4.56	6.04
Distance from PAA to TP in mm	6.00	13.00	9.03	2.46	7.88	10.18
Distance from FN to TMS in mm	4.80	7.50	6.24	0.76	5.88	6.59
Distance from FN to MT in mm	7.00	11.20	9.26	1.10	8.74	9.77
Distance from FN to TP in mm	7.80	10.00	8.96	0.67	8.65	9.27

*p<0.05

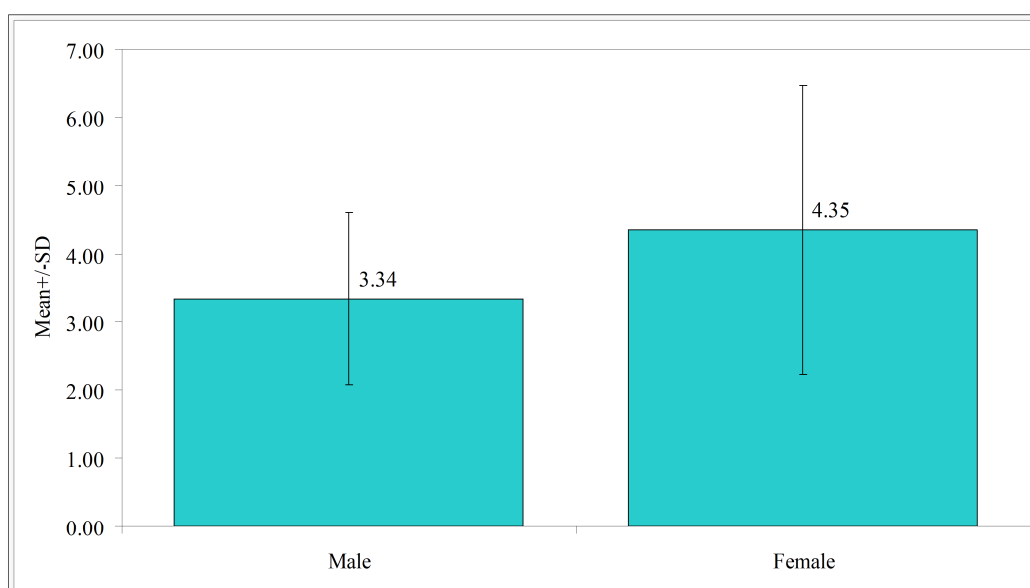
Graph 4: Comparison of mean scores among all the parameters

It was observed that the mean distance between the posterior auricular artery and facial nerve trunk was 3.74mm \pm 1.69. The artery was found to be in close proximity to the facial nerve trunk after it emerges from the stylomastoid foramen. The minimum distance obtained was 1.3mm whereas maximum distance was 7mm. Other facial nerve pointers such as mastoid tip which showed a mean distance of 9.26mm \pm 1.10 with facial nerve and distance between tympanomastoid suture with facial nerve trunk was found to be 6.24mm \pm 0.76.

Table 6: Comparison of male and female with distance from Posterior auricular artery to Facial nerve in mm scores by t test

Gender	Mean	SD	SE	t-value	P-value
Male	3.34	1.26	0.36	-1.3425	0.1961
Female	4.35	2.12	0.75		

Graph 5: Comparison of male and female with distance from Posterior auricular artery to Facial nerve in mm scores by t test

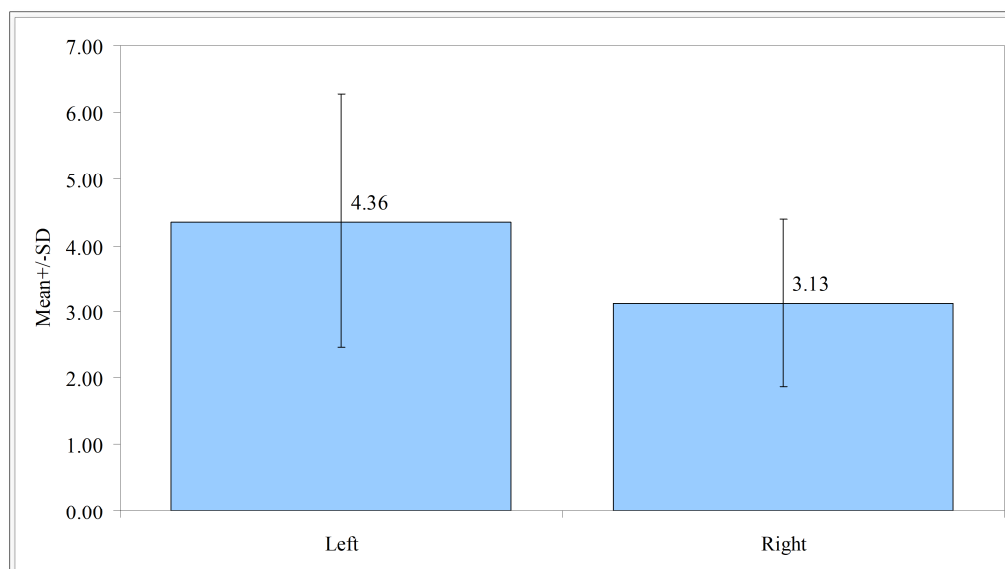


No significant difference was observed between male and female with distance from PAA to FN in mm scores ($t=1.7031$, $p=0.1058$) (Table 6, Graph 5). It means that, the mean distance from PAA to FN in mm scores are similar in male and females.

Table 7: Comparison of left and right side with distance from Posterior auricular artery to Facial nerve in mm scores by t test

Sides	Mean	SD	SE	t-value	P-value
Left	4.36	1.90	0.60	1.7031	0.1058
Right	3.13	1.26	0.40		

Graph 6: Comparison of male and female with distance from Posterior auricular artery to Facial nerve in mm scores by t test



No significant difference was observed between left and right side with distance from PAA to FN in mm scores ($t=1.7031$, $p=0.1058$) (Table 7, Graph 6). It means that, the mean distance from PAA to FN in mm scores are similar in left and right sides.

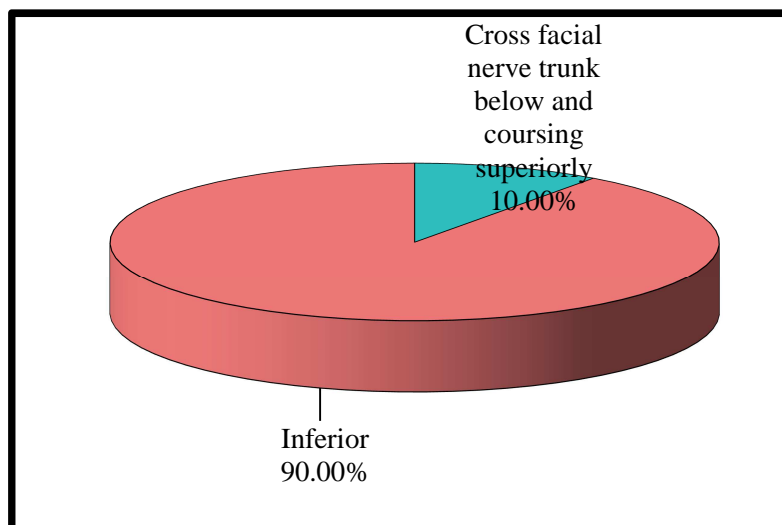
Relation of posterior auricular artery with respect to facial nerve trunk:

Among the 20 cadaveric hemifaces, variations were observed with respect to the course of posterior auricular artery (PAA) in relation to facial nerve trunk (FNT). It was noted that in 18 (90%) out of 20 cadaveric hemifaces, the posterior auricular artery was running inferior to the facial nerve trunk and 2 (10%) was found to run below the facial nerve trunk crossing it and coursing superiorly as depicted in the table and graph given below (Table 8, Graph 7).

Table 8: Relation of Posterior auricular artery to Facial nerve trunk

PAA in relation to facial nerve trunk	Number of cadaveric hemifaces	Percentage of cadaveric hemifaces
Cross facial nerve trunk below and coursing superiorly	2	10.00
Inferior	18	90.00
Total	20	100.00

Graph 7: Relation of Posterior auricular artery to Facial nerve trunk



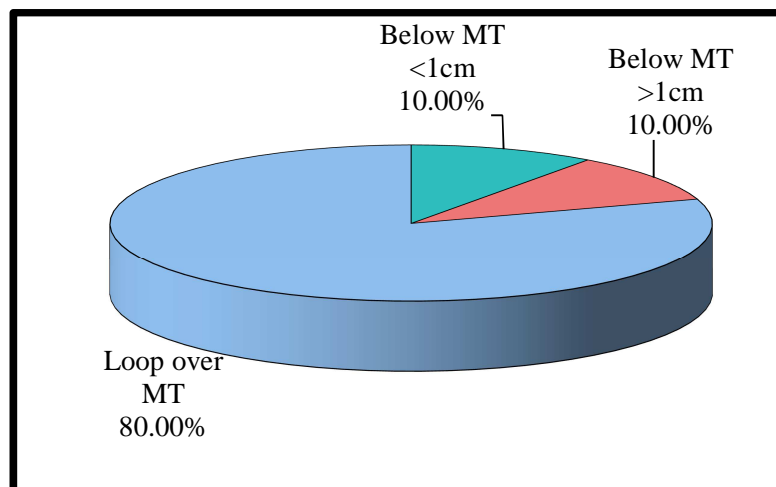
Relation of posterior auricular artery with respect to mastoid tip:

We also studied the course of posterior auricular artery (PAA) in relation to mastoid tip (MT). We observed that in majority of the samples, 16 (80%) out of 20 cadaveric hemifaces, it looped over the mastoid tip superficially, where as in 4 (20%) it was found to loop below the mastoid tip (MT), out of which 2 (10%) were greater than 1cm and 2 (10%) were less than 1cm, as mentioned in the table and graph given below (Table 9, Graph 8).

Table 9: Posterior auricular artery in relation to Mastoid tip

PAA in relation to MT	Number of cadaveric hemifaces	Percentage of cadaveric hemifaces
Below MT <1cm	2	10.00
Below MT >1cm	2	10.00
Loop over MT	16	80.00
Total	20	100.00

Graph 8: Posterior auricular artery in relation to Mastoid tip



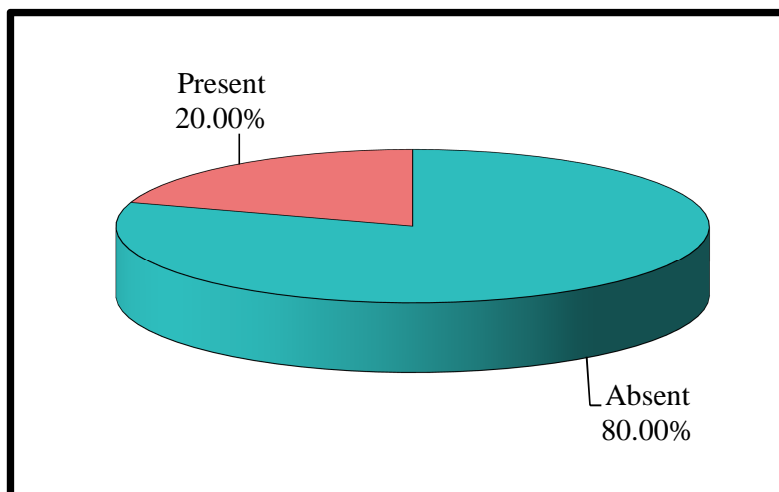
Branching patterns of posterior auricular artery:

The branching pattern of posterior auricular artery (PAA) was also studied and was observed that in 4 (20%) out of 20 cadaveric hemifaces there was a branching of the stylomastoid artery coursing towards the stylomastoid foramen. In 16 (80%) samples this branching was found to be absent as given in the table and graph below (Table 10, Graph 9).

Table 10: Branch of Posterior auricular artery

Branch of PAA	Number of cadaveric hemifaces	Percentage of cadaveric hemifaces
Absent	16	80.00
Present	4	20.00
Total	20	100.00

Graph 9: Branch of Posterior auricular artery



DISCUSSION

Parotid gland tumours account for 80-85% of all salivary gland tumours.²³ Benign parotid tumours are managed surgically with the aim of complete extirpation of the mass.² Parotid surgery is a complex and intricate procedure where in facial nerve injury is one of the dreaded complications as the main trunk of facial nerve and its extracranial branches are in close proximity.^{23,2} Therefore, identification of facial nerve and its dissection is one of the crucial steps of the surgery. Nerve injury can be a result of various mechanisms such as stretch, compression, ischemia, thermal injuries, and transection.²⁴ Facial nerve preservation during parotidectomy is of utmost importance as the nerve supplies the muscles of facial expression. Injury to the nerve damage can cause substantial morbidity leading to facial paresis or paralysis, corneal ulceration, dysphagia, dysarthria, Frey Syndrome and sialocele.²² Various surgical landmarks have been documented to identify the main trunk while avoiding damage to the facial nerve. However, various studies and meta-analyses have found these landmarks to be inconsistent. As a result, reports indicate a 26.3% rate of temporary facial palsy and a 1.7% incidence of permanent facial palsy. This variability in landmarks contributes to the challenges encountered during routine parotidectomy.² In this cadaveric study we aim at studying the relation between posterior auricular artery and facial nerve trunk and to determine the validity of using posterior auricular artery as a marker to identify facial nerve during parotid surgeries.

In our study, posterior auricular artery was found to originate as a posterior branch from the external carotid artery consistently in all 20 cadaveric hemifaces. Similar observations were made by Satya Sai et al in his study where “all 14 cadaveric hemifaces showed posterior auricular artery (PAA) arising from external carotid artery, which was also proven in the study conducted by Liu et al”.^{1,2}

Although in majority of the cadaveric dissections this is the pattern that has been seen, in 10% to 15% cases, it was noticed that posterior auricular artery (PAA) could also arise from occipital artery.²⁵ It was observed that there was no significant variation in the origin of PAA based on the gender or the side of dissection.

The course of posterior auricular artery was noted in relation to the mastoid tip. In our study, it was observed that in 16 out of 20 (80%) cadaveric hemifaces, PAA was found to loop superficial to the mastoid tip. In 2 out of 20 cadaveric dissection (10%) the artery loops more than 1cm below the mastoid tip and in another 2 samples (10%) PAA passes less than 1cm below the mastoid tip. This was compared with study done by Satya Sai Reddy et al wherein a similar picture was documented. Majority of their samples 71.42% was found to loop over the surface of mastoid tip.²

The branching pattern of posterior auricular artery was also studied, where we identified the stylomastoid artery which originated from posterior auricular artery in 4 out of 20 cadaveric dissections (20%) and runs below the facial nerve trunk to the stylomastoid foramen. This observation was in contrast to the study conducted by Satya Sai Reddy et al where all 14 cadaveric hemifaces showed stylomastoid artery branching from PAA, whereas Upile et al stated that origin of stylomastoid artery was more commonly seen from the occipital branch of external carotid artery.^{2,26}

The relation of posterior auricular artery (PAA) with respect to course of facial nerve trunk (FNT) was studied in our dissection study. In majority of our cadaveric hemifaces, 18 out of 20 (90%), it was observed that posterior auricular artery (PAA) ran inferior to the facial nerve trunk (FNT). In 2 out 20 hemifaces (10%), it was found that posterior auricular artery ran below the facial nerve trunk crossing it and passing

superiorly. Similar observation was made by Satya Sai Reddy et al in contrast to Liu et in his study found that PAA passes below the FNT as a common finding.^{1,2}

We measured the distance between the facial nerve trunk (FNT) with some of the landmarks used as facial nerve pointers in parotid surgeries such as mastoid tip, tympanomastoid suture and tragal pointer. The mean distance was measured and compared with the distance between posterior auricular artery (PAA) and facial nerve trunk (FNT) at the closest proximity. The mean distance between posterior auricular artery and facial nerve trunk was $3.74 \text{ mm} \pm 1.69$, with the minimum value of 1.5 mm and maximum value of 7 mm. The average distance between facial nerve trunk and mastoid tip was found to be $9.26 \text{ mm} \pm 1.10$. We also measured the mean distance between facial nerve trunk (FNT) and tympanomastoid suture which was calculated to be $6.24 \text{ mm} \pm 1.76$. Comparing the average distance between these pointers it can be noted that posterior auricular artery has a substantial location and with its close proximity to the facial nerve trunk (FNT) it can be used as a surgical landmark for identification along with the other known pointers. In the study conducted by Satya Sai Reddy et al “the distance between PAA – facial nerve was consistently within 6 to 8 mm in 70% of cadaveric dissection. Also, the diameter of the posterior auricular artery was found to be approximately 2 mm which helped in identification”.^{2,27}

Liu et al in his study had mentioned that “Posterior auricular artery (PAA) is considered to have a more consistent location with a larger diameter and it is easier to trace the course of the artery to estimate the location of facial nerve trunk (FNT) while keeping a safe distance from the nerve thereby reducing the chances of nerve injury”.¹

Few of the limitations of the study was that further clinical correlation is required to gauge the feasibility of using posterior auricular artery (PAA) as a suitable anatomic landmark for locating the position of facial nerve trunk as the present study was aimed at assessing the anatomic evidence for clinical application. Another drawback is that this method can only be used in case of anterograde dissection where the main trunk of facial nerve is identified first and traced further. This approach might be difficult in case of large parotid tumours infiltrating the main trunk, which may also displace the position of the artery or the trunk. Another issue regarding the cadaveric dissection is considering the fact that identification of different structures becomes strenuous.

CONCLUSION

Parotid surgeries are delicate procedures which require expertise and adequate knowledge regarding the anatomy and course of facial nerve to avoid complications associated with it.

20 cadaveric hemifaces of variable age and gender were studied where in different pointers of facial nerve were identified with an aim of finding a relation between posterior auricular artery and facial nerve trunk, its variations with respect to facial nerve trunk was observed and documented.

It was noted that posterior auricular artery was a useful surgical landmark in identifying the facial nerve trunk. This surgical landmark alone or along with other surgical landmarks will help in early identification of the facial nerve during parotid surgeries thereby preventing the cosmetic and functional deformity which can result with facial nerve injuries. Hence understanding the anatomical details of the posterior auricular artery and its relation to facial nerve and surrounding structures is of paramount importance.

We also observed that the type of embalming of cadavers presented a significant role in proper identification of the structures during dissection. Fresh cadavers that were soft embalmed portrayed a better representation and understanding of normal tissue than cadavers that had been preserved with formaldehyde, which may significantly alter the nature of the tissues.

This study was useful in assessing the various morphologic and anthropometric variation of the facial nerve trunk and posterior auricular artery and its surrounding relation with respect to parotid surgeries, that can exist in Indian cadavers.

SUMMARY

This study was conducted by performing neck dissection in view of finding a relation between the posterior auricular artery and facial nerve trunk in 20 cadaveric hemifaces.

We assessed different variations of the course of posterior auricular artery, its origin and branches along with facial nerve trunk and its branches. The mean distance between the posterior auricular artery and facial nerve trunk was 3.74 ± 1.69 and posterior auricular artery was commonly seen running inferior to the facial nerve trunk.

This technique of using posterior auricular artery to identify facial nerve trunk will ensure a safe parotidectomy operation with preservation of the facial nerve avoiding paralysis.

The posterior auricular artery can be better identified as the structure has a large diameter, color, pulsatile and proximity to the facial nerve trunk and parotid.

This landmark can be used along with other pointers such as mastoid tip, tympanomastoid suture line, posterior belly of digastric muscle and other newly discovered pointers such as retromandibular vein, posterior auricular nerve and stylomastoid artery to identify facial nerve trunk. In addition, newer modalities like intra operative nerve monitoring and use of surgical loops have been a great tool in identifying and preserving the facial nerve during surgeries.

The anatomic variations may be minor in degree but are important as they may affect the outcome of the surgery and the quality of life of patients. Hence, the anatomic variations and course of key surgical landmarks of facial nerve is necessary to safeguard the integrity and protection of important structures. .

BIBLIOGRAPHY

1. Liu M, Wang SJ, Benet A, Meybodi AT, Tabani H, EI-Sayed IH. Posterior auricular artery as a novel anatomic landmark for identification of the facial nerve: a cadaveric study. *Head & neck*. 2018 Jul;40(7):1461-5.
2. Reddy GG, Verma RK, Devarapalli NS, Sahni D, Bakshi J, Panda NK. Feasibility of Using Posterior Auricular Artery as Landmark for Identification of Facial Nerve Trunk in Parotid Surgery: A Cadaver Study. *Journal of Craniofacial Surgery*. 2021 Jul 1;32(5):1832-5.
3. Yang WY. STELL & MARAN'S TEXTBOOK OF HEAD AND NECK SURGERY AND ONCOLOGY, 5th edn J C Watkinson, RW Gilbert, eds Hodder Educational, 2012 ISBN 978 0 34092 916 2 pp 1156 Price £ 195. *The Journal of Laryngology & Otology*. 2012 Jul;126(7):761-2.
4. Watkinson J, Clarke R, editors. *Scott-Brown's otorhinolaryngology and head and neck surgery*: 3 volume set. CRC Press; 2018 Jul 17.
5. Al-Qahtani KH, AlQahtani FM, Muqat MM, AlQahtani MS, Al-Qannass AM, Islam T, Alharbi J, Sebah H, Alqarni M, Hakami H. A new landmark for the identification of the facial nerve during parotid surgery: A cadaver study. *Laryngoscope Investigative Otolaryngology*. 2020 Aug;5(4):689-93.
6. Al-Qahtani KH, AlQahtani MS, Baqays AA, Islam T. An improved and simplified approach to identify the facial nerve during parotid surgery. *Journal of Craniofacial Surgery*. 2020 Jun 1;31(4):e371-2.
7. Smith OJ, Ross GL. Variations in the anatomy of the posterior auricular nerve and its potential as a landmark for identification of the facial nerve trunk: a cadaveric study. *Anatomical science international*. 2012 Jun;87:101-5.

8. Hiatt JL. Textbook of head and neck anatomy. Jones & Bartlett Learning; 2020 Mar 18.
9. Netter FH. Netter Atlas of Human Anatomy: Classic Regional Approach-Ebook. Elsevier Health Sciences; 2022 Feb 19.
10. Trzeciak M, Ostrowski P, Bonczar M, del Carmen Yika A, Gładys K, Elsaftawy A, Wojciechowski W, Koziej M, Walocha J, Pasternak A. The topographical anatomy of the posterior auricular artery: a computed tomography angiography analysis with implications for reconstructive surgery. *Folia Morphologica*. 2024;83(3):647-55.
11. Viterbo F, William H. Slatery III and Babak Azizzadeh (eds.): The Facial Nerve: Thieme Publishers, New York, Stuttgart, 2014, 222 pp., 62 illus, Hardback, ISBN 9781604060508.
12. Righini CA. Facial nerve identification during parotidectomy. *European annals of otorhinolaryngology, head and neck diseases*. 2012 Aug 1;129(4):214-9.
13. Singh V. General Anatomy-e-book. Elsevier Health Sciences; 2015 Sep 15.
14. Ji YD, Donoff RB, Peacock ZS, Carlson ER. Surgical landmarks to locating the main trunk of the facial nerve in parotid surgery: a systematic review. *Journal of Oral and Maxillofacial Surgery*. 2018 Feb 1;76(2):438-43.
15. Zoulamoglou M, Zarokosta M, Kaklamanos I, Piperos T, Flessas I, Kakaviatos D, Kalles V, Bonatsos V, Sgantzos M, Mariolis-Sapsakos T. Anatomic variation of the relation between the facial nerve and the retromandibular vein during superficial parotidectomy: A rare case report. *International journal of surgery case reports*. 2017 Jan 1;41:124-7.
16. Kikuta S, Iwanaga J, Watanabe K, Kusukawa J, Tubbs RS. Anatomical study of the posterior auricular branch of the facial nerve: application to parotid surgery. *Journal of Craniofacial Surgery*. 2020 Jan 1;31(1):300-2.

17. Singh R. Morphological study of stylomastoid foramen at the base of skull and its role in facial nerve palsy. *Journal of Craniofacial Surgery*. 2023 Jul 1;34(5):1584-6.
18. Tewari S, Gupta C, Palimar V. A morphometric study of stylomastoid foramen with its clinical applications. *Journal of Neurological Surgery Part B: Skull Base*. 2022 Feb;83(01):033-6.
19. Rathee M, Jain P. Anatomy, Head and Neck, Stylohyoid Muscle. InStatPearls [Internet] 2023 Jan 30. StatPearls Publishing.
20. Ashram YA, Yingling CD. Intraoperative facial nerve monitoring. *Handbook of Clinical Neurophysiology*. 2008 Jan 1;8:371-83.
21. Rodriguez ED, Losee JE, Neligan PC, Van Beek AL. *Plastic Surgery: Volume 3: Craniofacial. Head and Neck Surgery and Pediatric Plastic Surgery*, 3rd ed. Philadelphia, PA: Saunders. 2012.
22. Myers EN. Conventional Surgery for Salivary Inflammatory Diseases. *Surgery of the Salivary Glands*. 2019 Nov 2:91.
23. Zoulamoglou M, Zarokosta M, Kaklamanos I, Piperos T, Flessas I, Kakaviatos D, Kalles V, Bonatsos V, Sgantzos M, Mariolis-Sapsakos T. Anatomic variation of the relation between the facial nerve and the retromandibular vein during superficial parotidectomy: A rare case report. *International journal of surgery case reports*. 2017 Jan 1;41:124-7.
24. Hansen JT. *Netter's Clinical Anatomy-E-Book: Netter's Clinical Anatomy-E-Book*. Elsevier Health Sciences; 2021 Dec 2.
25. Graf E, Petruzzelli GJ. Identification and dissection of the facial nerve during parotidectomy. *Operative Techniques in Otolaryngology-Head and Neck Surgery*. 2018 Sep 1;29(3):144-9.

26. Wong WK, Shetty S. The extent of surgery for benign parotid pathology and its influence on complications: A prospective cohort analysis. *American Journal of Otolaryngology*. 2018 Mar 1;39(2):162-6.
27. Sajisevi M. Monitoring During Parotidectomy. *Modern Approach to the Salivary Glands, An Issue of Otolaryngologic Clinics of North America, E-Book: Modern Approach to the Salivary Glands, An Issue of Otolaryngologic Clinics of North America, E-Book*. 2021 Jun 11;54(3):489.

ANNEXURE – I**PROFORMA FOR DATA COLLECTION**

**A STUDY OF ANATOMICAL RELATIONSHIP OF POSTERIOR
AURICULAR ARTERY WITH FACIAL NERVE TRUNK: A CADAVERIC
STUDY**

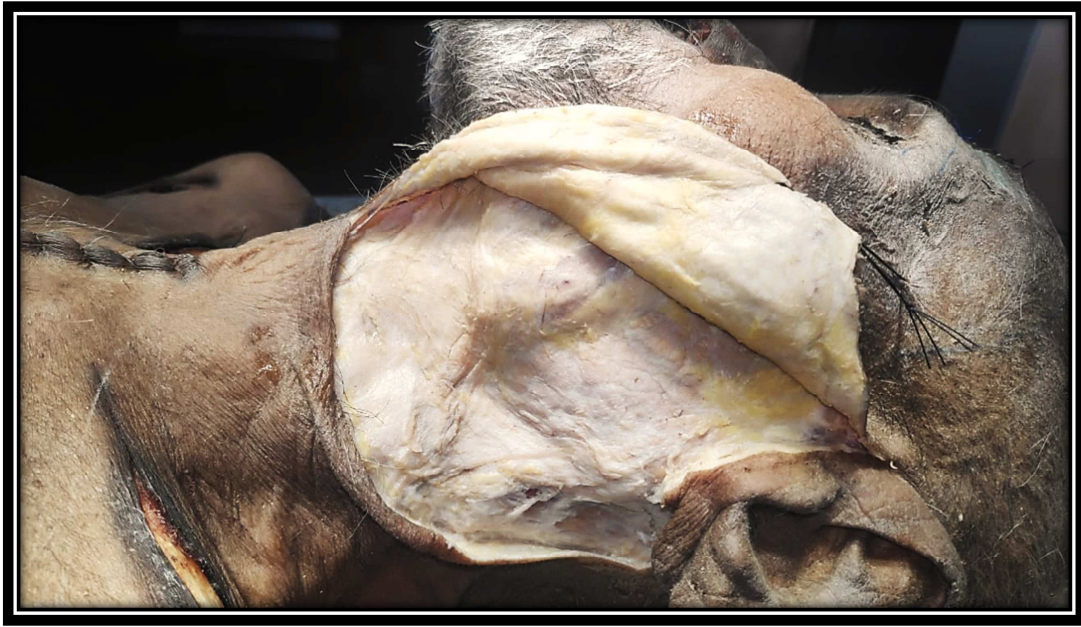1.	DATE:				
2.	SPECIMEN NUMBER:				
3.	TYPE OF EMBALMING				
4.	CHILD/ADULT: AGE (IF KNOWN):				
4.	SIDE:	RIGHT (R) / LEFT (L)			
5.	EXTERNAL EAR:	PINNA PRESENT/ABSENT:		P	A
		PREAURICULAR ANOMALIES: (PRESENT/ABSENT)	REGION	P	A
		POSTAURICULAR ANOMALIES: (PRESENT/ABSENT)	REGION	P	A

<p>6.</p> <p>7.</p> <p>8.</p>	<p>FACE: INSPECTORY FINDINGS</p> <p>CERVICAL REGION: INSPECTORY FINDINGS</p> <p>MASTOID REGION:</p>	<p>FRONTAL: ZYGOMATIC: MAXILLARY MANDIBULAR MENTAL MASTOID TIP:</p>	<p>A. PROMINENT B. NOT- PROMINENT</p>
<p>9.</p> <p>10.</p>	<p>PAROTID REGION</p> <p>REMARKS</p>	<p>POSTERIOR AURICULAR ARTERY RELATIONS: DISTANCE BETWEEN POSTERIOR AURICULAR ARTERY AND FACIAL NERVE: DISTANCE BETWEEN POSTERIOR AURICULAR ARTERY AND MASTOID TIP: DISTANCE BETWEEN FACIAL NERVE AND MASTOID TIP DISTANCE BETWEEN TYMPANOMASTOID SUTURE AND FACIAL NERVE</p>	<p>ANTERIOR: POSTERIOR: MEDIAL: LATERAL:</p>

ANNEXURE II

PHOTOGRAPHS

1. Parotid gland
2. Internal jugular vein
3. External carotid artery
4. Internal carotid artery
5. External jugular vein
6. Sternocleidomastoid
7. Facial nerve trunk
8. Posterior auricular artery
9. Posterior belly of digastric
10. Hypoglossal nerve
11. Common carotid artery
12. Mastoid tip
13. Branches of facial nerve
14. Stylomastoid branch of posterior auricular artery



**IMAGE 1: ANTERIOR SKIN FLAP ELEVATION AFTER MODIFIED BLAIRE'S
INCISION**

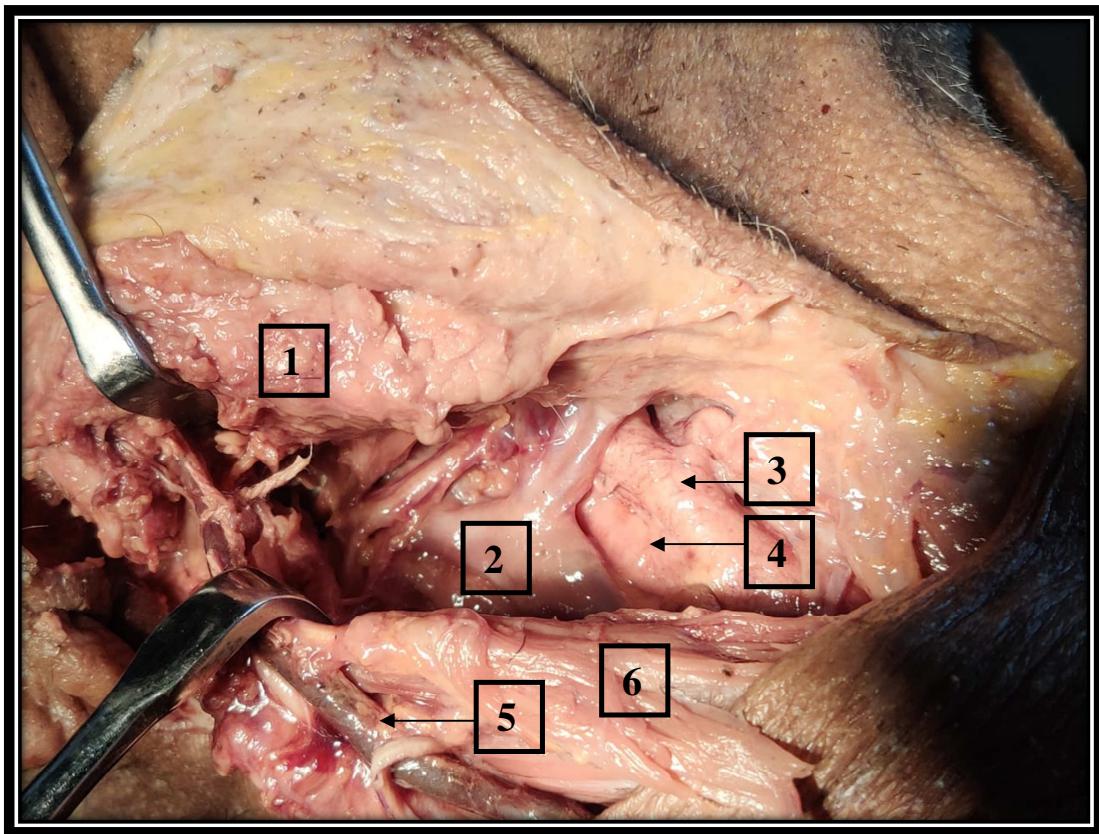


IMAGE 2: SCM SEPARATED AND RETRACTED

RELATION OF PAA WITH FACIAL NERVE TRUNK

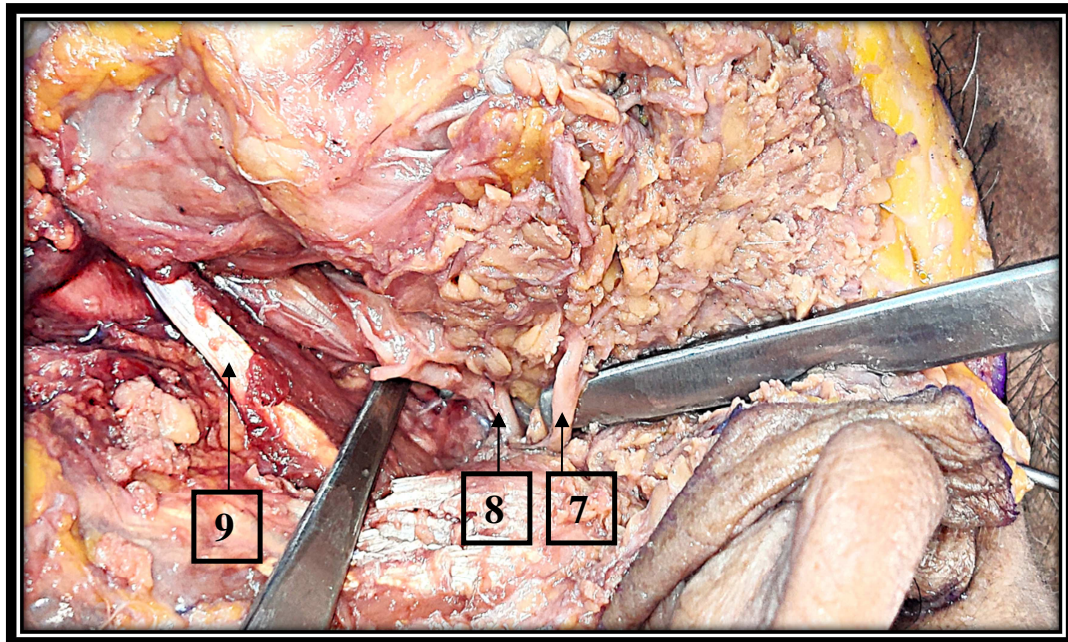


IMAGE 3A: PAA RUNNING INFERIOR TO FACIAL NERVE TRUNK (LEFT)

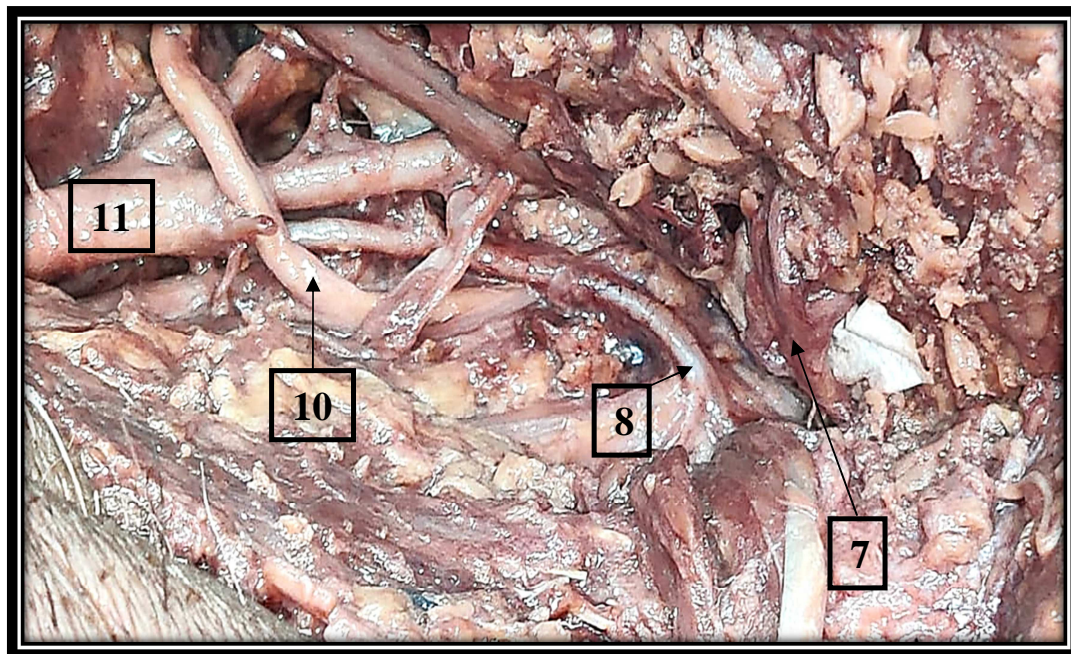


IMAGE 3B – PAA RUNNING INFERIOR TO FACIAL NERVE TRUNK (LEFT)

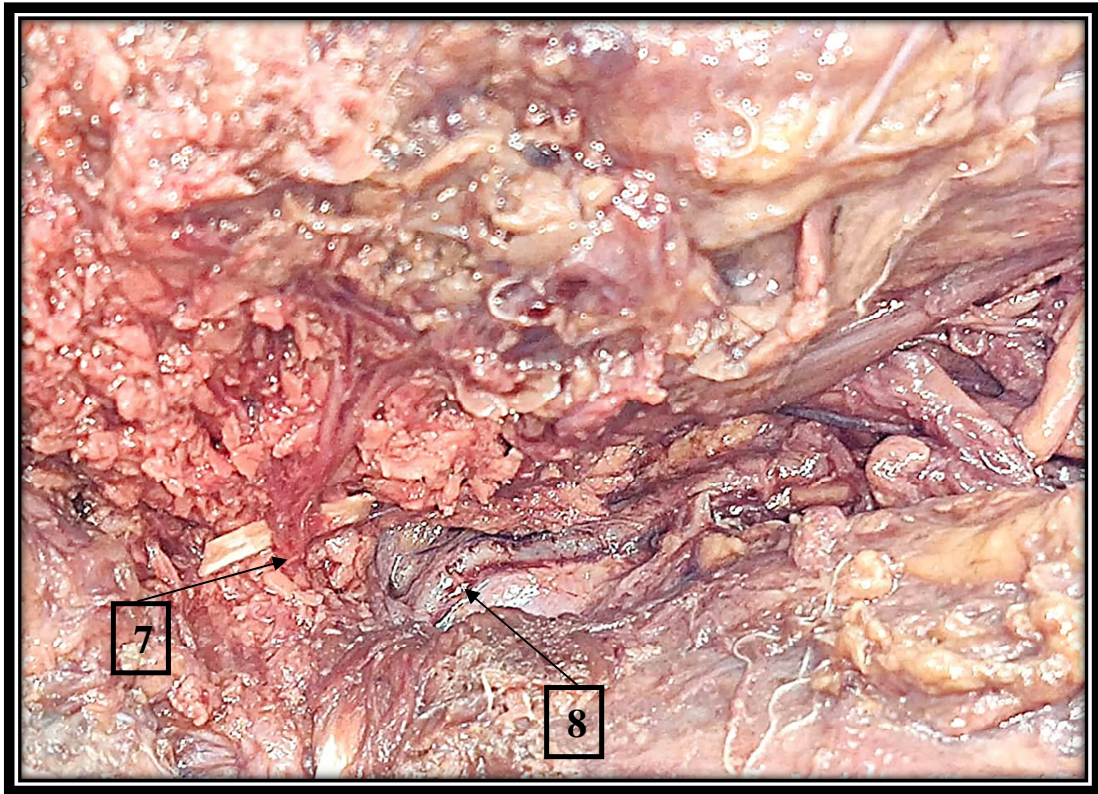


IMAGE 4A – PAA RUNNING INFERIOR TO FACIAL NERVE TRUNK (RIGHT)

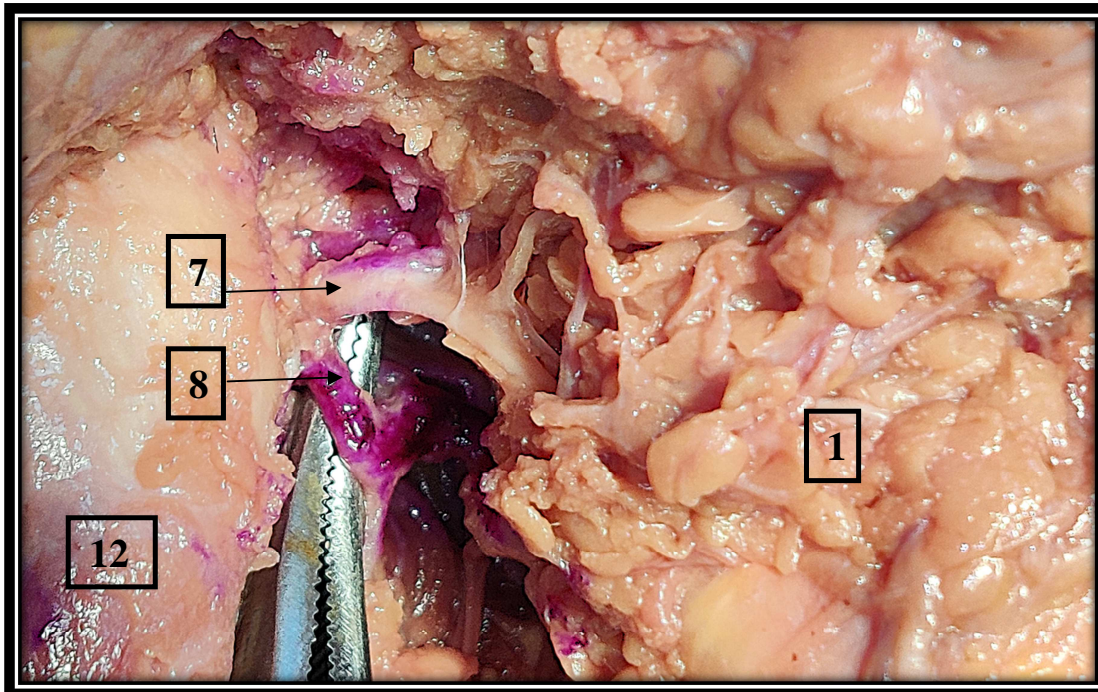


IMAGE 4B – PAA RUNNING INFERIOR TO FACIAL NERVE TRUNK (RIGHT)

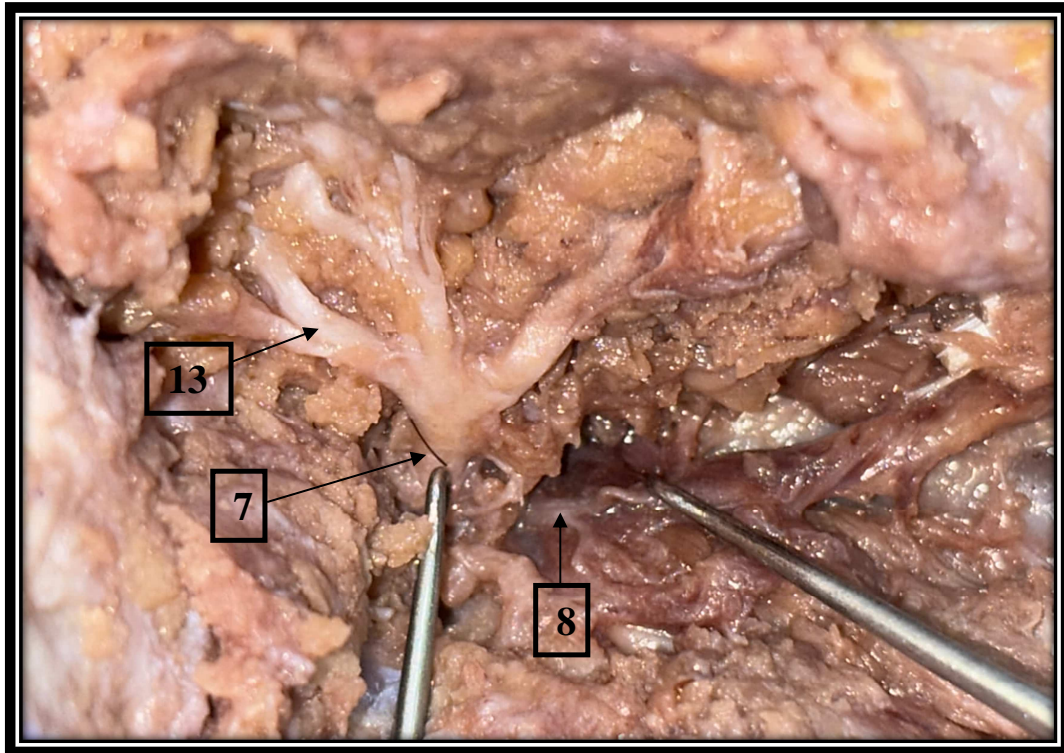


IMAGE 5A – PAA CROSSING FACIAL NERVE TRUNK FROM BELOW (RIGHT)

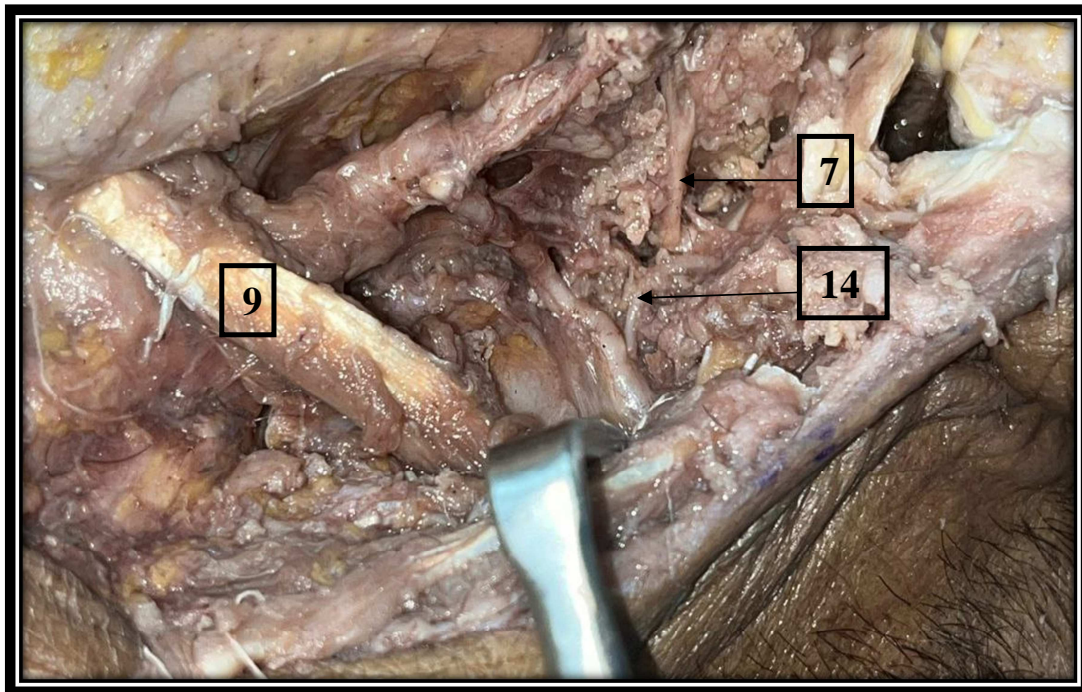


IMAGE 5B – BRANCH OF PAA CROSSING FACIAL NERVE TRUNK (RIGHT)

BRANCHING OF POSTERIOR AURICULAR ARTERY

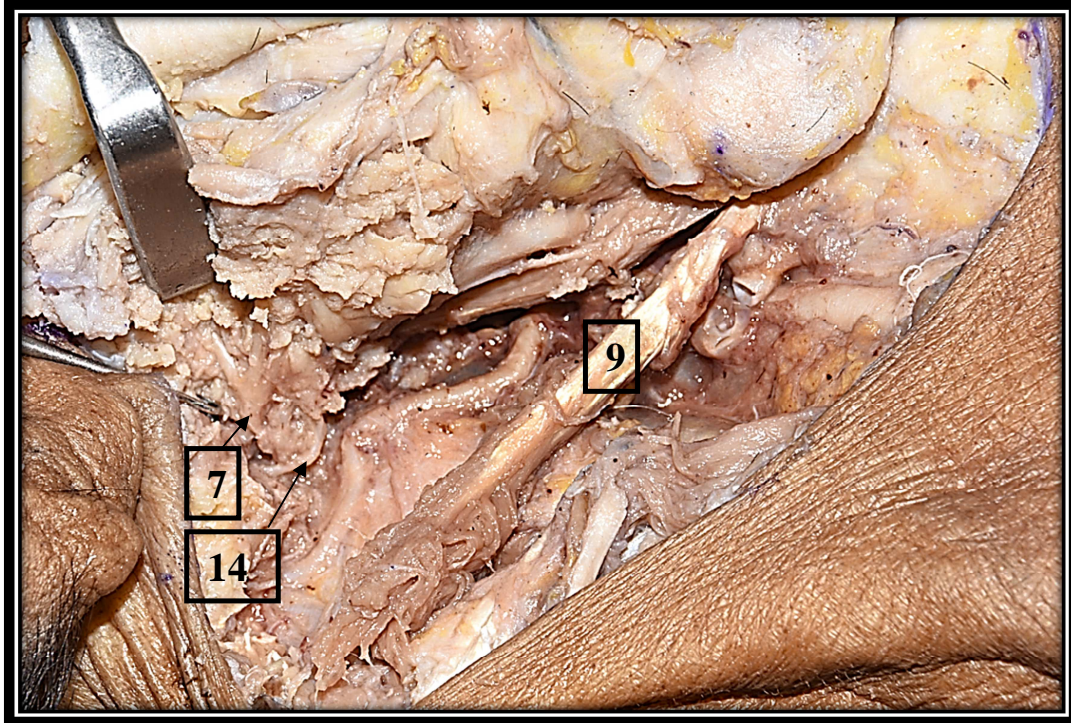


IMAGE 6A – STYLOMASTOID BRANCH OF PAA (RIGHT)

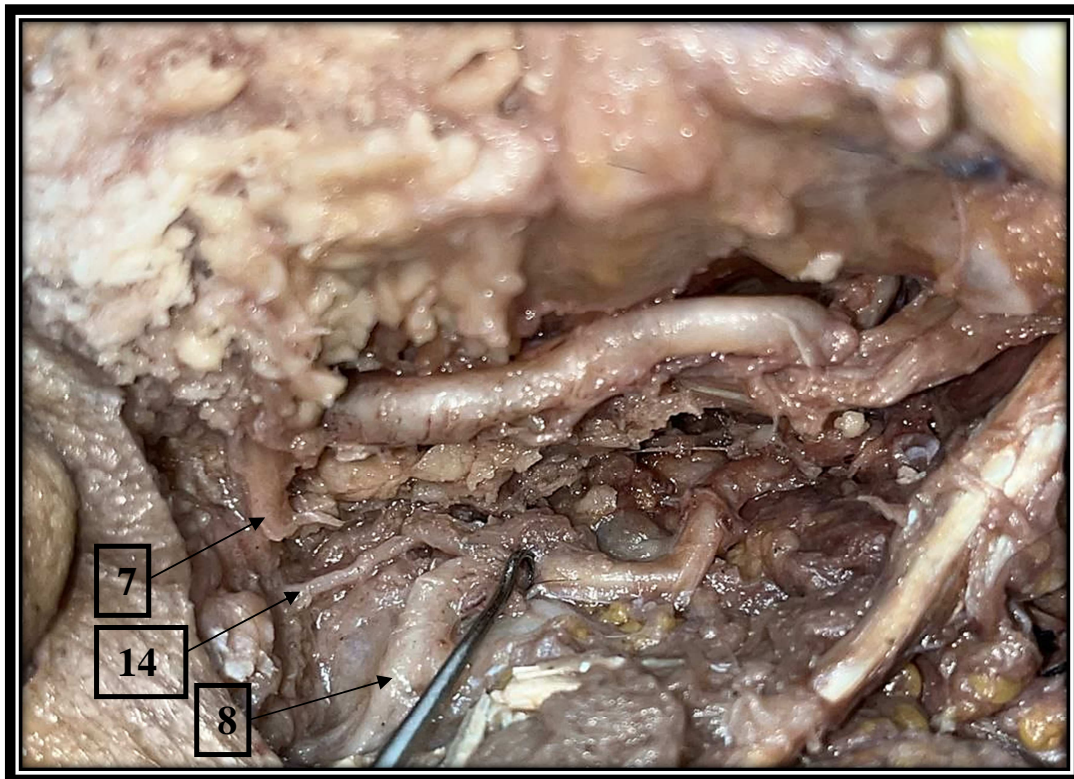


IMAGE 6B – STYLOMASTOID BRANCH OF PAA (RIGHT)

MEASUREMENT USING VERNIER CALIPERS

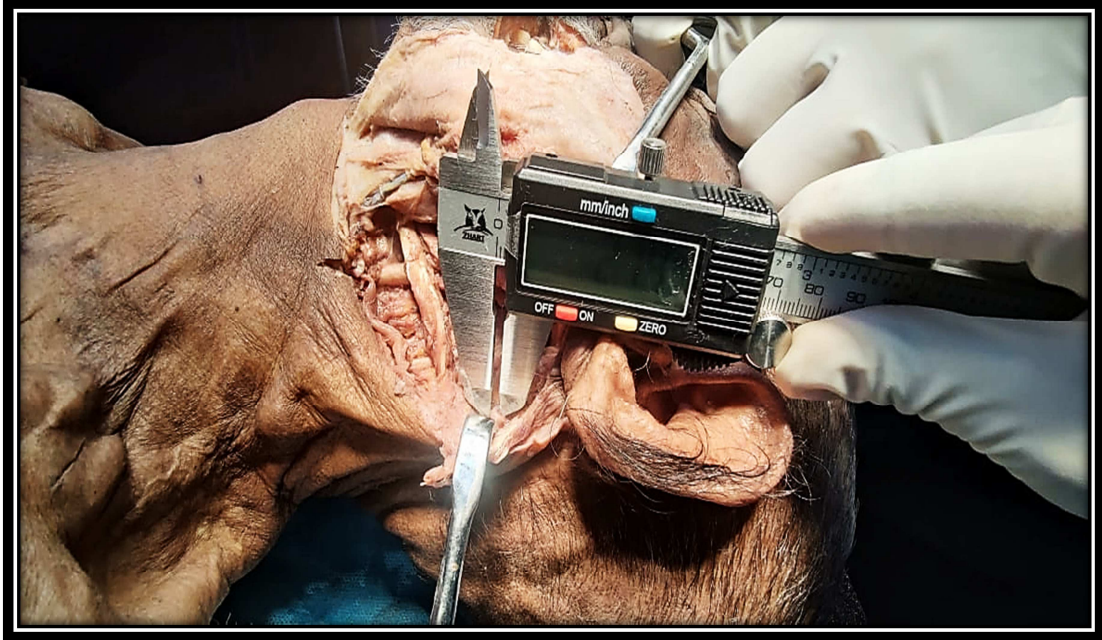


IMAGE 7A

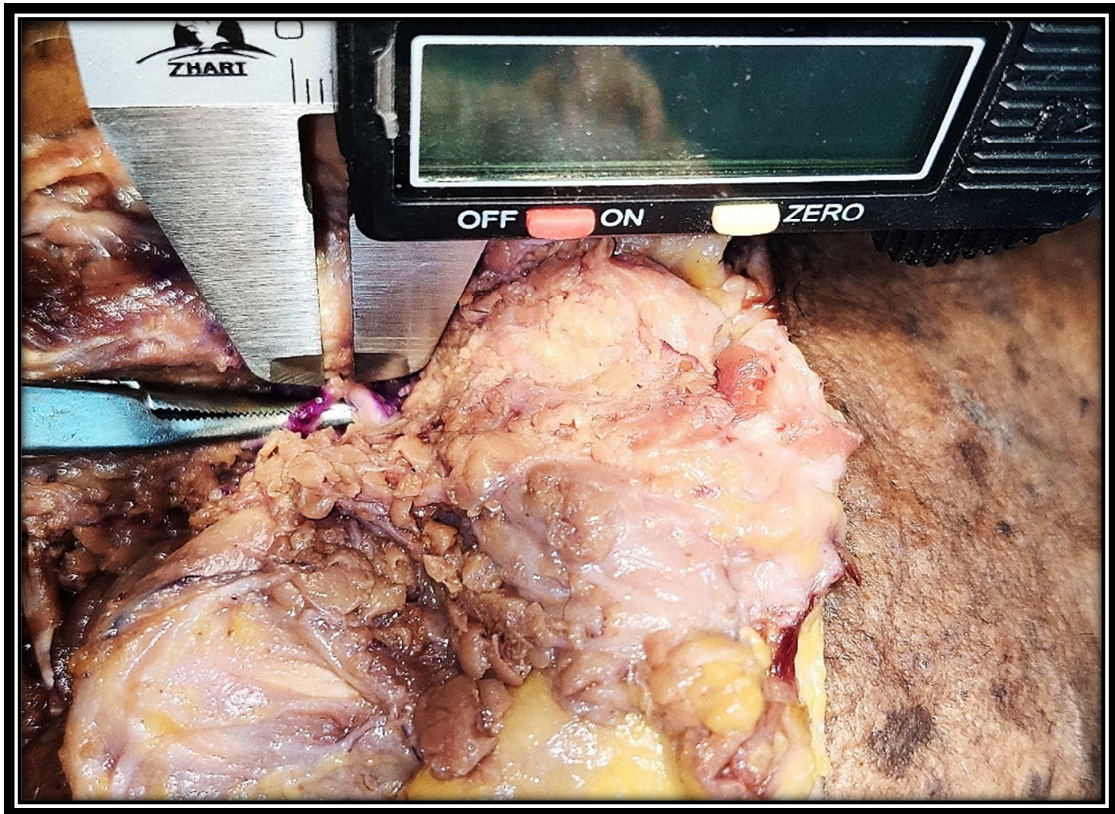

IMAGE 7B

CADAVERIC DISSECTION

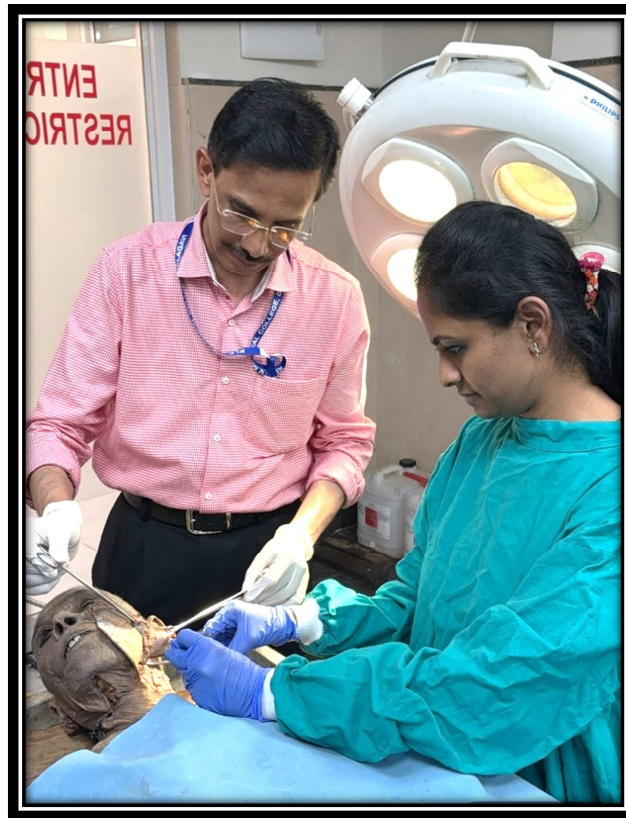

IMAGE 9A




IMAGE 9B




IMAGE 9C

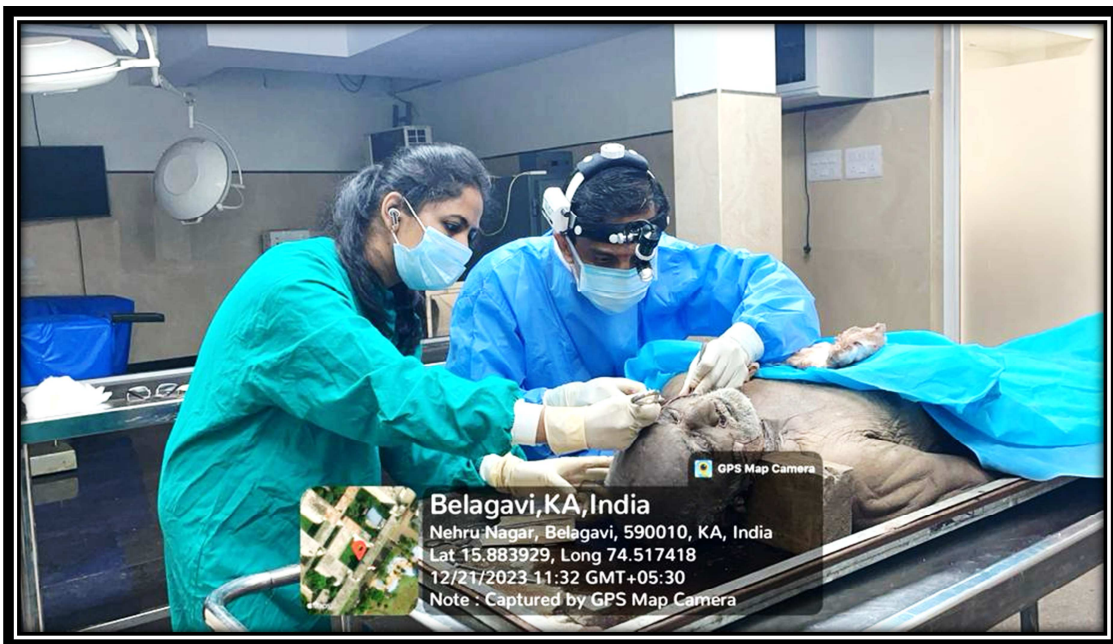


IMAGE 9D

ANNEXURE III: KEY TO MASTER CHART

PAA	POSTERIOR AURICULAR ARTERY
MT	MASTOID TIP
TMS	TYMPANOMASTOID SUTURE
TP	TRAGAL POINTER
DT	DISTANCE
FNT	FACIAL NERVE TRUNK

ANNEXURE IV: MASTER CHART

S.NO	TYPE OF EMBALMING	AGE	GENDER	SIDE	DT (PAA - FNT)	DT (PAA - MT)	DT (PAA - TP)	DT (FNT - TMS)	DT (FNT -MT)	DT (FN-TP)	PAA IN RELATON TO MT	BRANCH OF PAA
1	SOFT EMBALMED	ADULT	MALE	RIGHT	3 mm	6mm	13mm	7mm	9.5mm	9mm	LOOP OVER MT	PRESENT
2	SOFT EMBALMED	ADULT	MALE	LEFT	2.5 mm	5.5mm	12.27	6.5mm	9.5mm	8.5mm	LOOP OVER MT	PRESENT
3	FORMALIN	ADULT	FEMALE	LEFT	6 mm	7 mm	12.5mm	6.4mm	10mm	10mm	LOOP OVER MT	ABSENT
4	FORMALIN	ADULT	FEMALE	LEFT	7 mm	9mm	12.5	7.5mm	10.3mm	9mm	LOOP OVER MT	ABSENT
5	SOFT EMBALMED	ADULT	MALE	LEFT	2 mm	5.5mm	6mm	7.0mm	9mm	8mm	LOOP OVER MT	ABSENT
6	SOFT EMBALMED	ADULT	MALE	RIGHT	2 mm	5mm	6.5	5.5mm	8.8mm	7.8mm	LOOP OVER MT	ABSENT
7	SOFT EMBALMED	ADULT	MALE	RIGHT	3 mm	5mm	7mm	6.2mm	9mm	9.5mm	BELOW MT >1CM	PRESENT
8	SOFT EMBALMED	ADULT	MALE	LEFT	5 mm	7mm	9mm	6mm	10.5mm	9.5mm	BELOW MT >1CM	PRESENT
9	FORMALIN	ADULT	MALE	LEFT	5 mm	8mm	7mm	6.8mm	11mm	10mm	LOOP OVER MT	ABSENT
10	FORMALIN	ADULT	MALE	RIGHT	4 mm	7mm	8mm	7mm	9mm	9.5mm	LOOP OVER MT	ABSENT
11	FORMALIN	ADULT	FEMALE	LEFT	6 mm	4mm	12.5mm	7mm	11.2mm	9.5mm	LOOP OVER MT	ABSENT
12	FORMALIN	ADULT	MALE	LEFT	5 mm	4mm	12mm	6.2mm	9.7mm	9.5mm	LOOP OVER MT	ABSENT
13	SOFT EMBALMED	ADULT	FEMALE	RIGHT	1.3 mm	4mm	7mm	5mm	10mm	8.3mm	BELOW MT <1CM	ABSENT
14	FORMALIN	ADULT	FEMALE	RIGHT	6 mm	4mm	10mm	4.8mm	8mm	9.5mm	BELOW MT <1CM	ABSENT
15	SOFT EMBALMED	ADULT	MALE	LEFT	1.3 mm	3mm	7.5mm	6mm	9mm	8.3mm	LOOP OVER MT	ABSENT
16	FORMALIN	ADULT	FEMALE	RIGHT	2.5 mm	4mm	7mm	5mm	9.6mm	8.5mm	LOOP OVER MT	ABSENT
17	FORMALIN	ADULT	FEMALE	RIGHT	3 mm	5mm	8mm	5.8mm	8mm	9mm	LOOP OVER MT	ABSENT
18	SOFT EMBALMED	ADULT	MALE	RIGHT	3.5mm	4mm	7.8mm	6mm	7mm	8mm	LOOP OVER MT	ABSENT
19	SOFT EMBALMED	ADULT	MALE	LEFT	3.75mm	4mm	8mm	7mm	8mm	8.8mm	LOOP OVER MT	ABSENT
20	SOFT EMBALMED	ADULT	FEMALE	RIGHT	3mm	5mm	7mm	6mm	8mm	9mm	LOOP OVER MT	ABSENT