

INTRODUCTION

Appendicitis is the inflammation of the appendix. Since Reginald H. Filz, anatomopathologist at Harvard, first described the disease and first introduced the term appendicitis in 1886,¹ acute appendicitis remained the most common general surgical emergency seen in most hospitals and the most common cause of acute abdomen requiring surgical intervention.² More than 250,000 cases of appendicitis are diagnosed in the United States each year, and appendectomy is the most frequent emergent surgery performed worldwide.^{3,4}

In industrialized countries, individuals have a 7% lifetime risk of developing appendicitis, with the highest frequency occurring at ages from 10 to 30 years. The risk gradually decreases until age 50, when it stabilizes.^{2,5} In the past 30 years, the incidence has fallen dramatically in these countries, such that the individual lifetime risk of appendicectomy is 8.6% and 6.7% among males and females respectively.⁶

Obstruction of the lumen is the dominant factor for acute appendicitis and fecoliths are the usual cause of obstruction. Other causes of obstruction could be lymphoid hyperplasia, intestinal worms, tumors, or other conditions.⁷

This condition is common, yet notoriously difficult to diagnose. It can be associated with a variety of severe consequences and should be regarded as a clinical emergency. Typical uncomplicated cases of acute appendicitis are easy to diagnose. Typical cases present classically with para-umbilical pain (visceral pain) migrating to the right lower quadrant of the abdomen (RLQ). Pain usually is associated with nausea, vomiting and low-grade fever. Localized irritation and inflammation of the

peritoneum results in pain with cough (Dunphy's sign), tenderness and muscle guarding on palpation in the RLQ over McBurney's point and rebound tenderness elicited by deep palpation with quick release (Blumberg sign).²

Unfortunately, 20-33% of the patients suspected of having acute appendicitis present with atypical findings.^{2,8} Variation in the position of the appendix, age of the patient and degree of inflammation make the clinical presentation of appendicitis atypical. Females during childbearing age present diagnostic difficulty and the incidence of misdiagnosis is common.⁹

A misdiagnosis might result in negative exploration, while a delayed diagnosis may lead to progress of disease with complications like perforation and abscess formation. Therefore, surgeons have been more inclined to operate, when diagnosis is doubtful than to wait until it is certain, resulting in relatively high rate of negative appendicectomies. Negative exploration has its own complications.¹⁰ The rate of unnecessary laparotomies is still high: to balance an acceptable positive laparotomy rate with minimal delayed or missed diagnoses, the clinician must take into account all the available historical and physical findings, laboratory data, and appropriate imaging method.⁴

However, in recent years with the advent of various imaging techniques like, ultrasonography, spiral CT and MRI, false positive diagnosis of acute appendicitis has reduced. The overall accuracy of cross-sectional imaging techniques in diagnosing acute appendicitis varies from 87%-98%.¹¹

Histopathology reporting is considered the gold standard in diagnosis. So final diagnosis will be made on the basis of HPR and those patients who have got

histopathological proof will be finally diagnosed to have acute appendicitis and those in whom HPR is not suggestive of acute appendicitis will be finally diagnosed to be disease negative. Considering all the above factors, this study is undertaken to find out the accuracy of USG alone in the diagnosis of acute appendicitis by comparing with laparotomy/laparoscopy and histopathology findings.

Among imaging methods currently used in the clinical practice, Ultrasound (US) is a valuable tool. It was first introduced by Puylaert in 1986, who described the "graded compression" technique to visualize the inflamed appendix;¹² by using the graded compression technique, a linear high-frequency transducer is placed on the right lower quadrant and gradually increasing pressure is applied while imaging, displacing overlying gas-filled loops of bowel. Moreover, this noninvasive test is repeatable, avoids the exposure to nonionizing radiation and is less expensive as compared to Computed Tomography (CT). At US, findings suggestive of appendicitis include, a thickened wall, a noncompressible lumen, outer appendiceal diameter greater than 6 mm, absence of gas in the lumen, appendicoliths, echogenic inflammatory periappendiceal fat change, and increased blood flow in the appendiceal wall . If compared to other diagnostic tests, US is inferior to CT in sensitivity; due to its low negative predictive value for appendicitis, it may not be as useful for excluding appendicitis. More recently, color and power Doppler examination of the appendix have proven to be a useful adjunct to improve the sensitivity by demonstrating increased blood flow in an inflamed appendix.⁴

However; many factors have prevented this modality from becoming standard of care in the diagnostic work-up of appendicitis. Its limitations were further highlighted in 1994 when Balthazar reported on 100 cases of appendicitis,

comparing ultrasound with computed tomography (CT) scanning; the study showed better accuracy, negative predictive value (NPV), and sensitivity with CT scanning.¹³ However, while CT scanning has become the standard of care in the diagnosis of appendicitis in both children and adults, its liberal use has come under fire recently because of the risk of malignancy due to its ionizing radiation.¹⁴ Advantage of USG over other radiological investigations like CT is that it is easily available, cost effective, absence of radiation exposure, no known side effects, non-invasive and requires minimal patient preparation. In addition a large number of people can only afford USG and not CT.

However, there are only limited studies where in the accuracy of ultrasound alone is considered in the diagnosis of acute appendicitis. Accordingly, this study was planned to assess the diagnostic accuracy of the US method in the diagnosis of acute appendicitis in the adult patient.

OBJECTIVES

To find out the sensitivity, specificity, positive and negative predictive values of ultrasound in acute appendicitis in comparison with laparotomy/laparoscopic findings and histopathological report.

REVIEW OF LITERATURE

Historical review

Claudius Amyand in 1735 performed first appendicetomy on a boy of 11 years of age who had an inguinal hernia combined with an acutely inflamed appendix. This situation, where the appendix is included in the hernial sac, is known as an Amyand's hernia.¹⁵

Heister in 1755 recognized that appendix might be a site of primary inflammation. Hamock in 1848 successfully drained an appendix abscesses in a pregnant female during her eighth month of pregnancy. Lawson Tait in 1880 performed first abdominal appendicectomy.¹⁵

Reginald Fitz in 1886 first described acute appendicitis. He was also the first to use the term appendicitis. McBurney in 1889 improved the clinical diagnosis and removed the first unruptured appendix through the muscle splitting incision named after him.¹⁵

Two hundred years after its anatomical description, the appendix was observed to be the site of inflammatory disease. This was not widely accepted until the publication by Fitz 120 years later.¹ American surgeons demonstrated that early appendectomy was safe and life saving. Perforation of the appendix with peritonitis continues to be a significant problem, but the mortality rate has dramatically declined.¹⁶

Anatomy

The vermiform appendix is a narrow, vermian (worm shaped) tube, arising from posteromedial caecal wall, 2 cm or less below the end of the ileum. It can be found in any of the following position:¹⁷

1. Retrocaecal (12 O'clock) position – directed upwards in the retrocaecal recess. If the length is greater it may be retrocolic or sub hepatic.
2. Right Paracaecal (11 O'clock) position: lies on right side of caecum.
3. Left Paracaecal (1 O'clock) position: lies on left side of caecum. It may be preileal or postileal.
4. Splenic (2 O'clock) position: directed towards spleen.
5. Promontoric (3 O'clock) position: directed towards sacral promontory.
6. Pelvic (4 to 5 O'clock) position: Crosses the pelvic brim and lies in true pelvis.
7. 6 O'clock position: Appendix in mid inguinal position.

The location of appendix as follows.¹⁷

Retrocaecal and retrocolic	:	74%
Pelvic	:	21%
Sub caecal	:	1.5%
Preileal	:	1%
Post ileal	:	0.5%

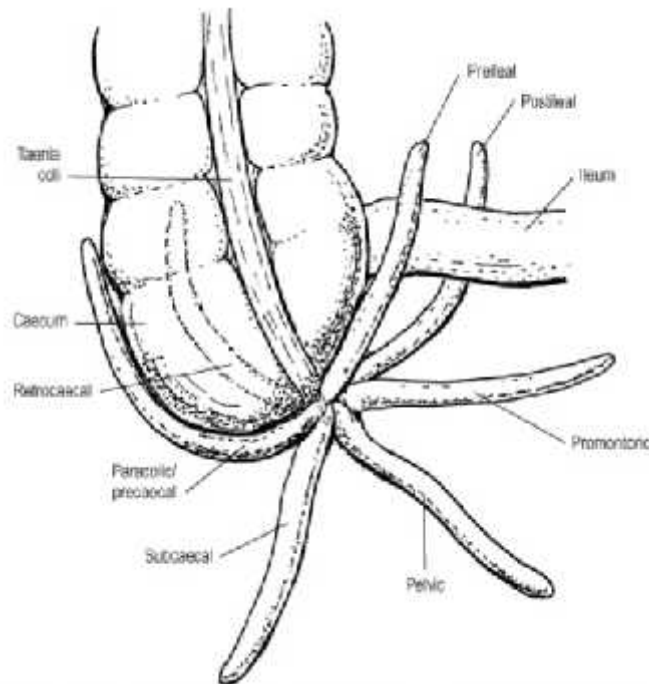


Figure 1. Anatomic variation in the position of the appendix¹⁸

The length varies from 2 to 20 cm with an average of 9 cm. It is longer in children than adults. The diameter is about 5 mm. The lumen is quite narrow and may be obliterated after mid-adult life. The appendicular orifice is situated at the posteromedial aspect of the caecum 2 cms below the ileocaecal orifice. The appendicular orifice is occasionally guarded by an indistinct semilunar fold of mucous membrane known as valve of Gerlach.¹⁷

The appendix is suspended by a small triangular fold of peritoneum, called mesoappendix. The appendicular artery often runs in its free edge, but may run closer to the base of the appendix.

Blood supply

The caecum is supplied by the anterior and posterior caecal branches of the ileocolic artery which is a branch of superior mesenteric artery.

The appendicular artery, a branch of ileocolic artery reaches the appendix through the mesoappendix. There may be an accessory appendicular artery (artery of Seshachalam) arising from the posterior caecal artery. If the meso appendix is incomplete, the artery lies on the wall of appendix in its distal part and may be thrombosed in acute appendicitis.¹⁹

Venous drainage

Venous drainage is through the appendicular, ileocolic and superior mesenteric veins into the portal vein.

Lymphatic drainage

The lymph vessels from caecum and appendix terminate in ileocolic nodes situated close to the ileocolic artery. Small appendicular nodes usually lie close to the meso-appendix.

Nerve supply

A plexus of nerves consisting of both sympathetic and parasympathetic fibres accompany the arteries to reach the caecum and appendix. The plexus is an offshoot from the superior mesenteric plexus. The sympathetic fibres are derived from T10 – T11 segment of the cord and the parasympathetic fibres are derived from vagi.

Development

The caecum and appendix develop from the caecal bud of the midgut. Agensis of the appendix is extremely rare. A study reported an incidence of one in 1,00,000 laparotomies for suspected appendicitis.²⁰

Histology

The structure of the appendix resembles that of large intestine. The lamina propria is extensively infiltrated with lymphocytes and the details of the mucosa are often obscured by the many lymphatic nodules that may fill the mucosa and submucosa. This profusion of lymph tissue has prompted the term of “abdominal tonsil” for the appendix, and draws attention to this features as relevant to the causes of appendicitis.

Duplication of the appendix

Duplication of the appendix is an anomaly of extreme rarity, classified into three types.

- Type A: Partial duplication of the appendix on a single caecum.
- Type B: Single caecum with two completely separate appendices.
- B1 : Bird like appendix where there are two appendices symmetrically placed on either side of ileocaecal valve.
- B2 : Along with the usual appendix another rudimentary appendix arises from the caecum along the line of one of the teniae coli.
- Type C: There are two caeca, each of which bears an appendix.

Tinkler described a unique case of a triple appendix, associated with double penis and ectopia vesicae.²¹

Epidemiology

Acute Appendicitis forms an important emergency in the day-to-day surgical practice. It affects human beings irrespective of age, nationality and religion.

In United States, 250,000 cases of appendicitis are reported annually. The incidence of acute appendicitis has been declining steadily since the late 1940s, and the current annual incidence is 10 cases per 100,000 population.²²

In Asian and African countries, the incidence of acute appendicitis is probably lower because of dietary habits of the inhabitants of these geographic areas.²³

The incidence of appendicitis gradually rises from birth, peaks in the teen age and gradually declines in the geriatric years. It is most prevalent in the 10-19-year age group.²⁴

In recent years, the number of cases in patients aged 30-69 has increased to 6.3%.²⁵

There are limited Indian studies regarding epidemiology of acute appendicitis. However, Recently Lohar HP et al.²² reported 3-year epidemiological trend of acute appendicitis in a rural setup. Occurrence of appendicitis is the highest in the 11-20 years age group which contributes 44.6%, followed by 21-30 years age group, which contributes 36.1%. The age group 31 to 40 years contributes 11.5% 0 to 10 years age group it is 3%. 41-50 years and 51-75 years of age group contributes

2.3% each. The youngest case recorded was 8 years of age and the oldest 65 years of age. In this study occurrence of appendicitis in both male and female was almost equal. Nonvegetarians were affected more than vegetarians. The occurrence of appendicitis was highest in the spring and low in the summer. Authors concluded that, acute appendicitis should be suspected irrespective of age, sex and socioeconomic status of individual. Age-specific occurrence, sex ratio of appendicitis indicate that epidemiologic features of acute appendicitis are different in different countries. It is difficult to diagnose appendicitis in young children, young women and elderly people. Total leukocyte count, urine microscopy, ultrasonography and computed tomography of abdomen should be used as a diagnostic aid in doubtful cases in association with physical findings, but they do not replace the clinical judgment of a general surgeon.

Pathogenesis

Appendicitis is commonly associated with obstruction of the appendiceal lumen due to fecalith. Obstruction may also be secondary to hypertrophy of lymphoid tissue, inspissated barium, gallstones, worms (ascaris), foreign bodies, or tumor.¹¹

Following obstruction of the appendiceal lumen, continued mucus secretion and inflammatory exudation leads to distension, mucosal edema and mucosal ulceration along with translocation of bacteria to the submucosa. The swelling of appendix stimulates the nerve endings of visceral afferent fibers and the patient perceives visceral periumbilical or epigastric pain.¹¹

With increasing intraluminal pressures, further distension results in obstruction of lymphatic and venous drainage and results in vascular congestion of the appendix. The inflammatory process soon involves the serosa. When the inflamed serosa of the appendix comes in contact with the parietal peritoneum, patients typically experience the classic shift of pain to the right lower quadrant. Intramural venous and arterial thromboses ensue, resulting in gangrenous appendicitis.¹¹

Unrelenting ischemia results in appendiceal infarction and perforation. Rupture of the appendix with spillage of pus into the peritoneal cavity results in localized or generalized peritonitis. More commonly, inflamed or perforated appendix can be walled off by the adjacent greater omentum and loops of small bowel resulting in phlegmonous mass or paracecal abscess.¹¹

This sequence is not inevitable and some episodes of acute appendicitis may resolve spontaneously if the obstruction is relieved. Rarely, appendiceal inflammation resolves leaving a distended mucus-filled appendix termed mucocele of the appendix.¹¹

History and Physical Examination

Abdominal pain is the most common symptom of appendicitis.²⁶ In multiple studies,²⁶⁻²⁸ specific characteristics of the abdominal pain and other associated symptoms have proved to be reliable indicators of acute appendicitis. A thorough history of the abdominal pain and of the patient's recent genitourinary, gynecologic and pulmonary history should be obtained.

Common Symptoms of Appendicitis^{26,28}

Common symptoms	Frequency (%)
Abdominal pain	~100
Anorexia	~100
Nausea	90
Vomiting	75
Pain migration	50
Classic symptom sequence (vague periumbilical pain to anorexia/nausea/unsustained vomiting to migration of pain to right lower quadrant to low-grade fever)	50

Onset of symptoms typically for the past 24 to 36 hours

Anorexia, nausea and vomiting are symptoms that are commonly associated with acute appendicitis. The classic history of pain beginning in the periumbilical region and migrating to the right lower quadrant occurs in only 50 percent of patients. Duration of symptoms exceeding 24 to 36 hours is uncommon in nonperforated appendicitis.²⁹

A careful, systematic examination of the abdomen is essential. While right lower quadrant tenderness is the most important physical finding, other signs may help confirm the diagnosis. The abdominal examination should begin with inspection followed by auscultation, gentle palpation (beginning at a site diagonally opposite to the site of pain) and, finally, abdominal percussion. The rebound

tenderness that is associated with peritoneal irritation has been shown to be more accurately identified by percussion of the abdomen.²⁹

Common Signs of Appendicitis²⁹

- Right lower quadrant tenderness (the single most important sign)
- Low-grade fever (38°C [or 100.4°F])—absence of fever or high fever can occur.
- Peritoneal signs.
 - Localized tenderness to percussion
 - Guarding and rigidity
- Other signs (absence of these signs does not exclude appendicitis)
 - Psoas sign - pain on extension of right thigh (retroperitoneal retrocecal appendix)
 - Obturator sign - pain on external rotation of right hip (pelvic appendix)
 - Rovsing's sign - pain in right lower quadrant with palpation of left lower quadrant
 - Dunphy's sign - increased pain with coughing
 - Patient maintains hip flexion with knees drawn up for comfort

When the appendix is hidden from the anterior peritoneum, the usual symptoms and signs of acute appendicitis may not be present. Pain and tenderness can occur in a location other than the right lower quadrant. A retrocecal appendix in a retroperitoneal location may cause flank pain. In this case, stretching the iliopsoas muscle can elicit pain. The psoas sign is elicited in this manner: the patient lies on

the left side while the examiner extends the patient's right thigh. In contrast, a patient with a pelvic appendix may show no abdominal signs, but the rectal examination may elicit tenderness in the cul-de-sac. In addition, an obturator sign (pain on passive external rotation of the flexed right thigh) may be present in a patient with a pelvic appendix.²⁶

The differential diagnosis of appendicitis is broad, but the patient's history and the physical examination may clinch the diagnosis. Because many gynecologic conditions can mimic appendicitis, a pelvic examination should be performed on all women with abdominal pain. Given the breadth of the differential diagnosis, the pulmonary, genitourinary and rectal examinations are equally important. Studies have shown, however, that the rectal examination provides useful information only when the diagnosis is unclear and, thus, can be reserved for use in such cases.²⁸

The accuracy (likelihood ratio) of the history and physical examination in the diagnosis of appendicitis in adults and children is as shown below.³⁰

Clinical finding	Adults	Children
Right lower quadrant pain	8.4	–
Migration (periumbilical to right lower quadrant)	3.6	1.9–3.1
Initial clinical impression of the surgeon	3.5	3.0–9.0
Psoas sign	3.2	2.5
Fever	3.2	3.4
Pain before vomiting	2.7	–
Rebound tenderness	2	3
Rectal tenderness	–	2.3

Diagnosis

The diagnosis of appendicitis can be challenging even for the most astute clinician, and is predominantly a clinical one. Accurate medical history and physical exam are important to prevent unnecessary surgery and avoid complications. The probability of appendicitis depends on patient age, clinical setting, and symptoms.^{31,32}

The overall accuracy for diagnosing acute appendicitis is approximately 80%, which corresponds to a mean false-negative appendectomy rate of 20%. Diagnostic accuracy varies by sex, with a range of 78%–92% in male and 58%–85% in female patients.³⁰

For the majority of patients who present to the emergency department with acute appendicitis, abdominal pain will be their chief complaint. Those presenting within the first few hours of onset often describe a poorly defined, constant pain referred to the periumbilical or epigastric region. Nausea, vomiting, and anorexia occur in varying degrees, though are usually present in more than 50% of cases in all studies. With disease progressing as previously outlined, pain becomes well defined and localises in the right lower quadrant near McBurney's point.³³

Accordingly, the clinician should not consider it the *sine qua non* for the diagnosis of acute appendicitis. A failure to recognize other presentations of acute appendicitis will lead to a delay in diagnosis and increased patient morbidity. Patients with a retrocaecal appendix or those presenting in the later months of pregnancy may have pain limited to the right flank or costovertebral angle. Male patients with a retrocaecal appendix may complain of right testicular pain. Pelvic or

retroileal locations of an inflamed appendix will refer to the pelvis, rectum, adnexa, or rarely, the left lower quadrant. Pelvic, suprapubic pain and urinary frequency may predominate.³⁰

Sensitivity and specificity of symptoms and signs on the diagnosis of acute appendicitis.^{31,32,34}

Symptoms and signs	Sensitivity	Specificity
Hyporexia	58%–91%	37%–40%
Nausea and vomitings	40%–72%	45%–69%
Diarrhoea	9%–24%	58%–65%
Fever	27%–74%	50%–84%
Rebound pain	80%–87%	69%–78%
Leukocytosis	42%–96%	53%–76%
C-reactive-protein	41%–48%	49%–57%

Localized irritation and inflammation of the peritoneum results in pain with cough (Dunphy’s sign), tenderness and muscle guarding on palpation in the RLQ over McBurney’s point and rebound tenderness elicited by deep palpation with quick release (Blumberg sign). Unfortunately, 20-33% of the patients suspected of having acute appendicitis present with atypical findings.^{2,8}

If the patient's history and the physical examination are indeterminate, laboratory and radiologic evaluations may be helpful. A clear diagnosis of appendicitis obviates the need for further testing and should prompt immediate surgical referral.

Scoring Systems

The diagnosis of acute appendicitis can be difficult and any delay in definitive treatment with surgery can lead to an increase in mortality and morbidity as the disease may progress to appendiceal perforation. This increase in morbidity and mortality has been used to justify the high rates of negative appendectomy which range from 14 to 75%.³⁵

A drive, therefore, has been there to improve the accuracy of diagnosis of appendicitis using clinical scoring systems. These systems have been based on symptoms, signs and laboratory findings. In some instances they have been part of a computer-aided diagnostic algorithm. The most widely cited score in the diagnosis of adults with acute appendicitis is the Alvarado score.³⁵

A number of studies have also used computer aided diagnosis in patients with acute abdominal pain in an attempt to improve the management of patients presenting with acute abdominal pain. These systems have reported a diagnostic accuracy of 97.2% in acute appendicitis, improvement in time to surgery, with a reduction in the number of perforations over a 2 year period. They have, however, not been introduced into routine clinical practice. In an aid to further improve diagnosis artificial neural networks have been suggested as adjuncts to diagnosis but this remains an area of research with only a small number of patients having had diagnoses made in this way.^{36,37}

*Alvarado Score or MANTRELS Score*³⁵

	Variable	Value
Symptoms	Migratory RIF pain	1
	Anorexia	1
	Nausea – Vomiting	1
Signs	Tenderness (RIF)	2
	Rebound tenderness	1
	Elevation of temperature > 37.3 °C	1
Laboratory	Leukocytosis > 10.0 x 10 ⁹ /L	2
	Shift to the left > 75%	1

The score was originally developed by Alfredo Alvarado in 1986 as an aid to the diagnosis of patients with appendicitis. The score was based on a cohort of 305 patients based at the Nazareth Hospital in Philadelphia in the United States of America who presented with suspected appendicitis. The charts of these patients were reviewed retrospectively and the sensitivity and specificity of a number of symptoms, signs and laboratory variables were assessed with those with the greatest diagnostic value being used to form a scoring system. This resulted in the formation of a simple score consisting of three symptoms, three signs and two laboratory markers of inflammation weighted as either one or two based on their importance in diagnosis. These variables could be recalled using the pneumonic MANTRELS. The maximum total score achievable is, therefore, 10. A score of 5 or 6 is compatible with a diagnosis of acute appendicitis, with a score of 7 or 8 indicating probable

appendicitis and a score of 9 or 10 indicating a very probable acute appendicitis. It has been suggested that score can be used as a guide to determine which patients require further observation and which patients require surgery. Those with a score of 5 or 6 required observation while those with a score of 7 or above needed to proceed to surgery as it was likely that they had appendicitis.

The Alvarado score is the best performing of the clinical scoring systems in current use. The score, however, is not based on a formal mathematical model which has accounted for the variables independent ability to predict a diagnosis. It was also based on retrospective data. These factors have resulted in a number of authors proposing multiple other scoring systems including a variety of other clinical, laboratory and imaging findings.³⁸

Other Scoring Systems

All of the described clinical scoring systems have attempted to aid the clinician in the diagnosis of the patient with acute appendicitis. The systems use a variety of signs, symptoms and investigations to form their respective scores. None has been adopted into wide spread clinical practice. They remain only as an aid to clinical diagnosis but do alert the clinician to all probable variables that should be considered in making a diagnosis of appendicitis.³⁸

The Tzanakis scoring system incorporated ultrasound scanning along with clinical and laboratory findings to predict the diagnosis of appendicitis. Following a multivariate logistic regression analysis four variables formed the scoring system (Ultrasound positive for acute appendicitis, tenderness in the right lower quadrant, rebound tenderness and a leukocyte count[12,000/IL]).³⁸

The Appendicitis Inflammatory Response Score was constructed from eight independent predictive variables (right lower quadrant pain, rebound tenderness, muscular defense, WBC count, proportion of neutrophils, CRP, body temperature and vomiting) and performed better than the Alvarado score in a sample of 229 patients suspected of appendicitis (Sensitivity 0.97 vs. 0.92, $p=0.0027$ and Specificity 0.93 vs. 0.88, $p=0.0007$).³⁹

The Ohmann score was developed in Germany and was subject to a before and after intervention study and used computer – aided diagnosis. The variables completing the score are tenderness in the right lower quadrant, rebound tenderness, no micturition difficulties, steady pain, leukocyte count $[10.0 \pm 9 \text{ } 10^9/\text{L}]$, age ≤ 50 years, relocation of the pain to right lower quadrant and rigidity.⁴⁰

The score was developed using stepwise logistic regression analysis of a German database and confirmed on a Dutch database. Following introduction of the score over a 4 month period the rates of delayed appendicectomy (2 vs. 8%) and delayed discharge (11 vs. 22%) decreased significantly ($p < 0.02$), however, there were no changes in the number of perforations or complications.³⁸

The Lintula score was developed from 35 symptoms and signs recorded for 131 Finnish children with abdominal pain which were modeled using logistic regression for their predictive value for a diagnosis of acute appendicitis. The score was then validated on a cohort of prospectively collected children with abdominal pain. The score uses gender, intensity of pain, relocation of pain, vomiting, pain in the right lower quadrant, fever, guarding, bowel sounds and rebound tenderness to form a score which if greater than 21 appendicectomy was advocated.⁴¹

The Lintula score was developed for use in children but has subsequently been validated in adults.⁴² The Fenyo-Lindberg scoring system was developed using a prospectively collected sample of 1,167 patients with suspected appendicitis. The system uses nine clinical and one laboratory variable to form a score. Each variable is given a weight between -15 and +15.⁴³ The authors initially reported a reduction in the rate of negative laparotomies associated with the use of the score.

The Pediatric Appendicitis Score (PAS) was first described by Madan Samuel in 2002. It was based on an analysis of a prospectively collected cohort of 1,170 children aged 4–15 years.⁴⁴ The symptoms, signs and laboratory findings were evaluated for sensitivity, specificity, predictive value and joint probability. A diagnostic index/weight for each clinical feature and investigation was calculated. A stepwise multiple linear regression analysis was then performed on the best independent predictors to develop a scoring system based on eight variables. The variables were given a score of one except for physical signs which were assigned a score of 2 to give a total score of 10. The variables in order of diagnostic index are, cough/percussion tenderness in the right lower quadrant of the abdomen, anorexia, pyrexia, nausea and emesis, tenderness over the right iliac fossa, leukocytosis, polymorphonuclear neutrophilia and migration of pain. The score was then validated on the cases and was found to have a sensitivity of 1, specificity of 0.92, positive predicted value of 0.96 and negative predictive value of 0.99.³⁸

The PAS has been evaluated in other cohorts of paediatric patients. It has been suggested that it is useful in stratifying the clinical risk of acute appendicitis in those children presenting to the emergency department with abdominal pain and classifying them as low, medium and high risk of acute appendicitis.⁴⁵ A score of

less than or equal to 2 was found to have a high validity of ruling out acute appendicitis while a score greater than or equal to 7 was found to have a high validity of predicting acute appendicitis.

Laboratory tests

White blood cell count

The white blood cell (WBC) count is elevated (greater than 10,000 per mm³ [100 × 10⁹ per L]) in 80% of all cases of acute appendicitis. Unfortunately, the WBC is elevated in up to 70% of patients with other causes of right lower quadrant pain.²⁹ Thus, an elevated WBC has a low predictive value. Serial WBC measurements (over 4 to 8 hours) in suspected cases may increase the specificity, as the WBC count often increases in acute appendicitis (except in cases of perforation, in which it may initially fall).²⁸

Neutrophils

In addition, 95% of patients have neutrophilia and, in the elderly, an elevated band count greater than 6 percent has been shown to have a high predictive value for appendicitis. In general, however, the WBC count and differential are only moderately helpful in confirming the diagnosis of appendicitis because of their low specificities.²⁹

C-reactive protein

A more recently suggested laboratory evaluation is determination of the C-reactive protein level. An elevated C-reactive protein level (greater than 0.8 mg per

dL) is common in appendicitis, but studies disagree on its sensitivity and specificity.^{27,28}

An elevated C-reactive protein level in combination with an elevated WBC count and neutrophilia are highly sensitive (97 to 100 percent). Therefore, if all three of these findings are absent, the chance of appendicitis is low.²⁸

Urine analysis

In patients with appendicitis, a urinalysis may demonstrate changes such as mild pyuria, proteinuria and hematuria, but the test serves more to exclude urinary tract causes of abdominal pain than to diagnose appendicitis.²⁹

Radiologic evaluation

Radiologic evaluation may be done only in patients in whom a clinical and laboratorial diagnosis of appendicitis cannot be made.

Accuracy of the images for the diagnosis of acute appendicitis^{30,34,46-51}

Exams	Sensitivity	Specificity	Predictive values	
			Positive	Negative
Abdominal radiographya	97.05%	85.33%	78.94%	98.08%
Ultrasound	44%–90%	47%–95%	89%–94%	89%–97%
Computed tomography	72%–97%	91%–99%	92%–98%	95%–100%
Scintigraphy	91%–98%	91%–99%		

Conventional Radiography

Though plain films are reported to reveal abnormalities in 50% of patients with appendicitis, they are not specific, not cost effective, and can be misleading. Plain films are indicated for the evaluation of a patient with suspected appendicitis only when other diagnostic probabilities (e.g., perforation, intestinal obstruction, ureteral calculus) are also considered.

The various plain film findings that have been described in appendicitis are as follows:^{52,53}

- Appendicolith.
- Right lower quadrant gas
- Increased soft tissue density of the right lower quadrant
- Separation of the cecum from right extraperitoneal fat planes
- Deformity of the cecal and ascending colon gas shadow occurring due to adjacent inflammatory mass
- Localized ileus with gas in the cecum, ascending colon and terminal ileum
- Effacement of the right extraperitoneal fat line
- Gas in peritoneum and retroperitoneum
- Gas filled appendix

Barium enema examination may be helpful in selected patients. Barium enema is performed on an unprepared bowel gently without any external pressure. Complete filling of a normal appendix effectively excludes the diagnosis of appendicitis. Nonfilling or incomplete filling of the appendix along with mass effect on the cecum suggests appendicitis,⁵² the mass effect being due to abscess/

inflammatory reactions surrounding the inflamed appendix. The terminal ileum may be displaced or narrowed by the adjacent inflammatory mass and there may be thickening of the mucosal folds of the terminal ileum. However, non-filling of appendix may be seen in as many as 10-20% of normal patients.¹¹

It has been shown by Sehey that appendix fills in 92% of normal children and hence failure of the appendix to fill in symptomatic children is a significant finding.¹¹

Barium enema examination may also be useful in evaluating complex colonic abnormalities detected with cross-sectional imaging.⁵⁴

Ultrasonography

US is rapid, non-invasive, inexpensive, and requires no patient preparation or contrast material administration.^{55,56} Although operator skill is an important factor in all US examinations, it has particular importance in the examination of the patient with right-lower-quadrant pain. In experienced hands, US has reported sensitivities of 75%–90%, specificities of 86%–95%, accuracies of 87%–96%, positive predictive values of 91%–94%, and negative predictive values of 89%–97% for the diagnosis of acute appendicitis.^{56,57}

The appendix appears on ultrasound as a lamellated, elongated, blind-ending structure. Unlike normal bowel, the inflamed appendix is fixed, non-compressible, and appears round on transverse images. Measurements of appendix are performed with full compression. Traditionally, the diagnosis of appendicitis is made when the diameter of the compressed appendix exceeds 6 mm. In contrast, the thick-walled and non-compressible appendix, maintained in a fixed position by the compressing

transducer, will show circumferential colour doppler when inflamed. Appendiceal perforation can be diagnosed when the appendix demonstrates irregular contour or when periappendiceal fluid collections are identified.^{34,46,55,56,57}

Doppler US examination usually reveals increased vascularity in and around the acutely inflamed appendix. This examination is useful as an adjunct sign of appendicitis when the appendiceal measurement is equivocal, in which it is uncertain as to whether the imaged appendix is normal or inflamed.^{34,46,56,57}

Ultrasonography (US) is valuable in the diagnosis of doubtful cases of appendicitis and is a cost-efficient adjunct to the clinical evaluation.⁵⁸ US is inexpensive, safe, and widely available. Because US involves no ionizing radiation and excels in the depiction of acute gynecologic conditions, it is recommended as the initial imaging study in children, in young women, and during pregnancy.

Use of preoperative ultrasonography is also associated with overall lower negative appendectomy rate.⁵⁸

Graded compression technique described by Puylaert¹² is the standard method for sonographic evaluation of acute appendicitis. Graded compression US, with slow and gentle maintained pressure, allows for a lengthy and successful evaluation of the area of interest and shows obstructed appendix as a noncompressible loop.⁵⁴

Recently Baldisserotto et al.⁵⁹ has described the use of the noncompressive technique before the graded compression study. This may successfully establish the diagnosis in some cases, thereby avoiding compression in patients with abdominal pain. Change of the patient's position to displace the bowel gas may also help in

visualization of the appendix deeply set in the abdominal cavity without compression. Compression study is however, useful in identifying the cases of appendicitis not visualized at the noncompressive examination.¹¹

It is very important to standardize the examination technique for identification of appendix and thereby avoiding false negative diagnosis. Baldisserotto has suggested an excellent routine for the actual US examination of the right lower quadrant, which is found very useful in daily practice. The US examination of the right lower quadrant should start in the transverse plane from the tip of the liver and proceed towards the pelvic brim. The ascending colon usually is appreciated by its gas content and haustral pattern. In the region of the cecum, careful attention should be paid to inflammatory changes in the perienteric fat and the appendix itself. Sagittal and oblique images should then be obtained until the entire region of interest has been scanned. Detailed images are obtained of the appendix, if it is seen. The examination is generally begun with a curvilinear transducer appropriate for the patient: a 3.5-MHz transducer for large patients and a 5-MHz transducer for thin patients. The linear transducer is used latter for more detailed study. The retrocecal appendicitis is best studied by the examination through the right flank.⁵⁹

The inflamed appendix is seen as a blind-ended, aperistaltic, noncompressible, tubular structure that arises from the base of the cecum having a diameter greater than 6 mms. Presence of a fecalith may aid in arriving at a positive diagnosis.

The ovoid shape⁶⁰ of appendix in transverse section on US over the entire appendiceal length reliably rules out acute appendicitis while in acute inflammation the appendiceal wall thickening causes an increase of the outer appendiceal diameter and a rounding of the shape.

In early acute appendicitis (catarrhal stage) five layers can be identified

1. Central, thin hyperechoic line representing the collapsed lumen and superficial lining of the mucosa of the appendix
2. Hypoechoic layer (2-3mms) representing edematous lamina propria and muscularis mucosa.
3. Hyperechoic submucosa (2-3 mms).
4. hypoechoic muscular layer (2-3-mms).
5. outer thin hyperechoic line representing the serosa.

In late (suppurative) stage the lumen of the appendix is distended with pus/fluid and there is increased thickening of the submucosa and muscular wall in the range of 3-6 mms.

Circumferential color in the wall of the inflamed appendix on color Doppler US images is strongly supportive evidence of active inflammation.⁵⁴

Loculated pericecal fluid, phlegmon or abscess, prominent pericecal fat and circumferential loss of the submucosal layer of appendix are associated with appendiceal perforation.

A significant disadvantage of sonography is that it is operator dependent. Difficulties with ultrasonography also include the fact that a normal appendix must be identified to rule out acute appendicitis. Visualization of a normal appendix is more difficult in patients with a large body habitus and when there is an associated ileus, which produces shadowing secondary to overlying gas-filled loops of bowel. It may also be not possible on US to differentiate between appendiceal phlegmon from an abscess and CT may be helpful in this setting.

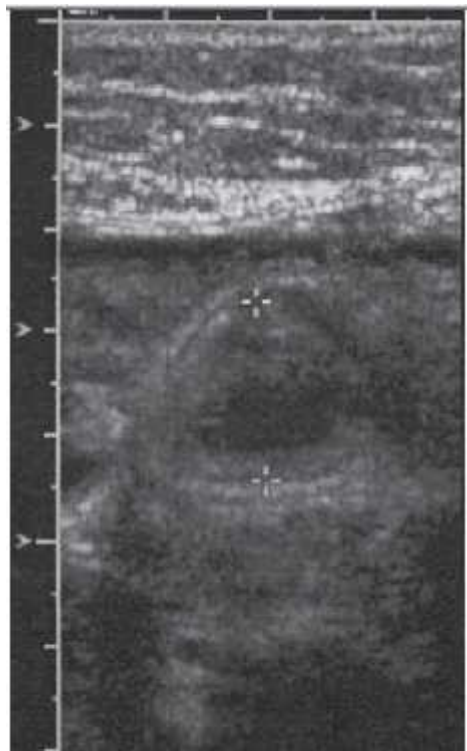


Figure 2. Appendiceal ultrasound showing distended non compressible appendix measuring 1.7 cms in transverse dimension¹¹

Computed Tomography

CT represents an excellent diagnostic alternative in diagnosing acute appendicitis. CT is complementary to US and is recommended whenever US results

are suboptimal, indeterminate, or normal in patients with acute abdominal pain. US is also complementary to CT and may be particularly useful in thin patients in whom the results of initial CT, no matter how it is performed, are equivocal. Analysis of the data for CT and US revealed higher sensitivity (96% vs 76%), accuracy (94% vs 83%), and negative predictive value (95% vs 76%) for CT.^{30,55,56,61}

Helical CT has reported sensitivities of 90%–98%, specificities of 91%–98%, accuracies of 94%–98%, positive predictive values of 92%–98%, and negative predictive values of 95%–98% for the diagnosis of acute appendicitis.^{30,55,56,61}

The inflamed appendix appears as an enlarged blind-ending tubular structure, frequently associated with inflammatory stranding in the surrounding fat. Traditionally, the threshold diameter of 6 mm was used for diagnosis of appendicitis. However, studies of healthy adults revealed that the normal range of appendiceal size in an adult patient is 3–10 mm. Thus, using an appendiceal threshold size of 9 mm is more accurate for diagnosis of appendicitis. The same radiographic image of faecal loading inside a dilated caecum may be visualised at CT in presence of acute appendicitis.^{47,48}

CT has become increasingly popular as an effective cross-sectional imaging technique for diagnosing and staging acute appendicitis. It is a quick and accurate examination that is operator-independent, is relatively easy to perform and provides images that are easy to interpret.¹¹

Its use has decreased the rate of negative appendectomies and has decreased the number of cases of appendiceal perforation.⁶²

Disadvantages of CT include possible iodinated-contrast-media allergy, patient discomfort from administration of contrast media (especially if rectal contrast media is used), exposure to ionizing radiation, and cost. However, the cost is considerably less than that of removing a normal appendix or hospital observation.⁵²

Magnetic Resonance Imaging

MR imaging is emerging as an alternative to CT in pregnant patients and in patients who have an allergy to iodinated contrast material. MR imaging has a limited role in the work-up of suspected appendicitis. Although the use of MR imaging avoids ionising radiation, it has several disadvantages, including high cost, long duration of studies, and limited availability on an emergent basis. According to some authors, the use of MR imaging is limited to pregnant patients in whom ultrasound is inconclusive. On MR imaging, the appendix is identified as a tubular structure with intraluminal T1 and T2 prolongation. Appendicitis is diagnosed using thresholds of the size used for CT. Inflammatory changes are visualized as T2 hyperintensity in the periappendiceal fat.³⁰

There are no known adverse effects of MR imaging in human pregnancy, but the safety of MR imaging has not been proven unequivocally. Although tissue heating from radiofrequency pulses, acoustic stimulation potentially harm the foetus. The gadolinium remains there for an indefinite amount of time, excreted by the foetal kidneys and subsequently swallowed by the foetus with amniotic fluid. Although there is no evidence of mutagenic or teratogenic effects of gadolinium in

humans, mutagenic effects were seen in animal studies. Therefore a conservative approach avoids using gadolinium when possible in the first trimester.³⁰

MRI may also be used in the diagnosis of appendicitis in cases where either CT is contraindicated like in pregnancy or in children where it is advisable to avoid radiation. T1-weighted and T2-weighted turbo spin-echo sequences and fat-suppressed inversion recovery turbo spin-echo sequences as well as post contrast T1 weighted sequences can be used. On T2-weighted images, inflamed appendix show markedly hyperintense center and a slightly hyperintense thickened wall with markedly hyperintense periappendiceal tissue.¹¹

On post contrast study, intense contrast enhancement of the inflamed appendiceal wall indicates the presence of appendicitis. There is also significant enhancement of surrounding fat on gadolinium-enhanced T1-weighted fat-suppressed spin-echo images. Mild enhancement can however be seen in the normal appendix and gut. Using fat-saturation technique, contrast differences between the inflamed appendix and the surrounding fat is better appreciated. However, MRI has inherent limitation in detecting appendicolith.¹¹

Inflammatory diseases of the gut, such as ileal diverticulitis and Crohn's disease may mimic appendicitis and may be cause for false-positive diagnosis of acute appendicitis.¹¹

False-negative results usually depend on technique-related limitations, such as inefficient fat saturation causing appendiceal wall enhancement to be obscured by mesenteric fat.¹¹

Fat-suppressed gadolinium enhanced MRI images are sensitive (97%) and accurate (95%) in the detection of acute appendicitis.¹¹

Incesu, et al.⁶³ found MR imaging superior to sonography in revealing appendicitis. Despite some disadvantage, MR imaging can also be used after suboptimal or nondiagnostic sonography in cases of suspected acute appendicitis.

Scintigraphy

An inflamed bowel has strong chemotactic properties, and leukocytes actively invade the appendix in acute appendicitis. The migration and accumulation of radioactive tagged leukocytes in the appendix is the basis for this study in patients believed to have acute appendicitis. Indium-111-labelled leukocyte scanning had a sensitivity of 86% and specificity of 93% for the diagnosis of acute appendicitis. Although the majority of these scans were performed at 2 h after injection, occasionally delayed images up to 17–24 h were required.³⁰

Technetium-99 m-albumin-colloid-labelled leukocyte (TAC-WBC) scanning appears to be superior to indium-111 because it is less expensive, requires shorter preparation time, requires less delay in time to positive scan (within 2 h), and has a lower radiation-absorbed dose, compared with indium-111. The overall sensitivity of this method is of 89% and its specificity is of 92%. It is not reliable in diagnosing appendicitis in women, with only a 75% sensitivity and 43% positive predictive value in this subgroup. Limitations of radionuclide-labelled leukocyte scanning include cost, delay in diagnosis, exposure to radiation, relatively large percentage of indeterminate scans and decreased sensitivity and specificity in women.³⁰

Diagnostic Laparoscopy

Several authors have advocated the use of laparoscopy as a diagnostic modality in the evaluation of a patient suspected of having acute appendicitis. Diagnostic laparoscopy should be viewed as an invasive procedure requiring general anesthesia and having a risk similar to appendectomy. For this reason, it is not preferred as a diagnostic tool. There is a lot of debate whether to remove a normal-looking appendix during diagnostic laparoscopy or to leave it. Naturally, many surgeons prefer not to come out empty-handed regardless of the gross appearance of the appendix, especially if no other pathology is identified. Many authors advocate removal of appendix regardless of the gross appearance as they believe not all normal-looking appendices are not inflamed and the inflammation may be limited to the mucosa (endo-appendicitis); however, the routine removal of a normal appendix is not a complication-free technique even in laparoscopy.³

In a study authors reviewed the literature for the years 1978 to 1998 to analyze the negative appendectomy rates, complication rates, the accuracy of laparoscopic appendix assessment, and the incidence of false negative diagnosis of appendicitis, at surgical and gynaecological laparoscopy. He concluded that, contrary to general opinion, there is no substantial evidence to support the assumption that the macroscopic diagnosis of appendicitis is unreliable. High rates of conflicting diagnoses of excision specimens suggest that endo-appendicitis has little clinical significance. At present, negative appendectomy rates are considerably higher for laparoscopic appendectomy than for the open approach. The role of diagnostic laparoscopy in suspected appendicitis should be reconsidered. It may be

useful in particular subgroups of patients, but it is no substitute for good clinical judgement.⁶⁴

Another report stated that, 3.2% of the intra-operatively normal-appearing appendices demonstrated acute inflammation after pathological examination.⁶⁵

Furthermore, a prospective study evaluated 109 diagnostic laparoscopies for suspected appendicitis with normal-looking appendices in 100 cases. After a median follow-up of 4.4 years, only two patients had acute appendicitis and nine had some recurrent pain. Study suggested that it is safe to leave a normal-looking appendix in place when a diagnostic laparoscopy for suspected appendicitis is performed, even if another diagnosis cannot be found at laparoscopy.⁶⁶

Diagnostic laparoscopy may be helpful in equivocal cases or in women of childbearing age, while therapeutic laparoscopy may be preferred in certain subsets of patients (e.g., women, obese patients, athletes), but it should not be advocated as a routine diagnostic procedure to replace the classical pre-operative work-up usually performed for clinically suspected appendicitis, because it has its own morbidity and in most cases requires general anesthesia.²

Despite technologic advances, the diagnosis of appendicitis is still based primarily on the patient's history and the physical examination. It has been estimated that the accuracy of the clinical diagnosis of acute appendicitis is lying between 76% and 92%, with values correlating with the surgeon's experience.²

Scoring Systems and the Use of Radiological Investigations

None of the scoring systems described have been able to replace the clinical diagnosis of acute appendicitis, however, they do act as an adjunct to diagnosis. Several studies have detailed their possible use in determining the need for further investigation in patients with abdominal pain. The authors of a prospective evaluation of 849 children with abdominal pain suggested that those with a paediatric appendicitis score (PAS) score of between 3 and 6 should go on to have further investigation such as ultrasound or computed tomography or a period of further evaluation.⁴⁵

The accuracy of clinical diagnosis of suspected cases of acute appendicitis can further be improved by repeated clinical examination and adoption of what is called active observation. Patients under active observation are kept fasting and re-evaluated for progression or regression of their symptoms and signs by repeated clinical examination every 2-3 hours (preferably by the same physician) and repeated estimation of white blood count and C-reactive protein.³⁴

Active observation confirms intraperitoneal pathology which requires surgical intervention or further investigation in a small group of patients. It also excludes those found to have medical illness, e.g., UTI. In 30-40% of patients, a firm diagnosis is not possible; those patients can benefit from a further period of active observation with or without further investigation depending on whether the symptoms are persisting or improving. Active observation results in a substantial fall in negative appendectomy rate and is widely considered as safe and effective

approach to the management of patients with equivocal features of acute appendicitis.²

Diagnostic difficulties

Accurate and timely diagnosis of atypical cases remains clinically challenging and one of the most commonly missed problems in the emergency departments. Precaution appendectomy or misdiagnosis of presumed appendicitis is an adverse outcome that leads to unnecessary surgery,⁶⁷ serious interruption of patient's daily activities and considerable waste of hospital resources⁶⁸ in addition to the recognized postoperative complications. On the other hand, delay in diagnosis may increase the morbidity and cost.²

Statistics reported that 1 of 5 cases of appendicitis is misdiagnosed; however, a normal appendix is found in 15-35% of patients who have emergency appendectomy.^{2,69}

Variation in the position of the appendix, age of the patient and degree of inflammation make the clinical presentation of appendicitis inconsistent. Females during childbearing age present diagnostic difficulty and the incidence of misdiagnosis is increased for women of the reproductive age.²

Variable Anatomical Positions

The base of the appendix is fairly constant and is located at the posteromedial wall of the caecum about 2.5 cm below the ileocecal valve where the taeniae converge, whereas the position of the tip varies. It is retrocaecal in 65% of

the patients, pelvic in 30%, and paracaecal or post-ileal/pre-ileal in the remaining 5%.²

Inflammation of a retrocaecal appendix is difficult to diagnose. Rigidity is often absent and even on deep pressure, tenderness may be lacking (silent appendix), the reason being that the cecum distended with gas prevents the pressure exerted by the hand from reaching the appendix.⁷⁰ The clue to diagnosis is hip flexion that results from irritation of the psoas muscle by the inflamed appendix. Hyperextension of the hip may induce abdominal pain (psoas sign).²

Inflammation of a pelvic appendix associated with early diarrhoea results from the contact between the inflamed appendix and the rectum. When the appendix lies entirely within the pelvis, there is usually complete absence of abdominal rigidity and often tenderness over McBurney's point is lacking as well. Rectal examination is crucial for the diagnosis. Spasm of the obturator internus muscle can be sometimes demonstrated by flexion and external rotation of the hip (obturator sign).²

Postileal appendicitis presents a great diagnostic difficulty because the pain starts in the right lower abdomen and remains there (not migratory) and is usually associated with diarrhea leading to confusion with enterocolitis.²

Inflammation of a maldescended or subhepatic appendix is sometimes mistaken as acute cholecystitis.²

Extreme Age

The highest incidence of acute appendicitis is during the second and third decade of life.²

While appendicitis is uncommon in young children, it poses special difficulties in this age group because it is difficult to obtain the history and elicit clinical signs in young children, non-specific abdominal pain and mesenteric lymphadenitis are common in this age group and sometimes these are impossible to be differentiated from acute appendicitis on clinical grounds. These factors contribute to a perforation rate as high as 50% in this age group.²

Acute appendicitis in the elderly is associated with significant morbidity. There is usually delay in the diagnosis because abdominal laxity may hide the clinical signs. Progression to perforation is rapid with significant increase in morbidity and mortality.²

It was estimated that the perforation rate is about 50% in infancy, 10% between 10 and 40 years and 30% at 60 years of age.²

Overall, in spite of disturbances associated with the right side abdominal pain having been described since centuries ago under many different names and presumable pathophysiologies, the appendicitis is still a disease full of mysteries. Many thousands researches have been developed on all fields related to the appendix, but it is still not known the role of this organ and what is the exact pathophysiology of appendicitis. All theories are controversial and no symptom or sign may be ascribed to acute appendicitis as patognomonic. Thus the diagnosis of this inflammatory disease continues to be a medical challenge.²

Treatment

Surgical management

Appendectomy is the only curative treatment for acute appendicitis. Typical cases should be operated without unnecessary delay for time-consuming or expensive investigations.²

Open appendectomy (OA) has withstood the test of time for more than a century since its introduction by McBurney. Since its initial description by Semm in 1983, laparoscopic appendectomy (LA) has struggled to prove its superiority over the open technique.² Recent prospective randomized trials have suggested that laparoscopic removal of an inflamed appendix may have benefits over open surgery.^{75,76} Laparoscopic appendectomy has been claimed to reduce postoperative pain, length of hospitalisation, analgesic doses and surgery-associated complications. However, unlike laparoscopic cholecystectomy, LA has not yet gained popularity, most probably because most of the cases are dealt with by junior surgical staff on an emergency basis outside the working hours.²

Medical management

The standard treatment for acute appendicitis is appendectomy, but in isolated environments where there are no surgical capabilities, medical management is required until surgical resources become available.²

A Swedish multicenter study randomized 252 men aged 15-50 to surgery or antibiotic treatment alone, excluding patients with a high suspicion of major perforation or complications. The findings suggest that if there are reasons to

postpone surgery, antibiotics alone are a satisfactory way to treat mild to moderate appendicitis without complications. The study concluded that acute non-perforated appendicitis can be treated successfully with antibiotics. However, there is a risk of recurrence, and this risk should be compared with the risk of complications after appendectomy.⁷¹

Hansson et al. randomized 369 consecutive adults with presumed appendicitis to either antibiotics or surgery as primary treatment. Their conclusion is that antibiotics are an appropriate first-line treatment for adults with appendicitis without obvious signs of intra-abdominal perforation;⁷¹ However this had some limitations and it seems that more studies are needed to establish the role of antibiotic as a primary treatment of non-complicated appendicitis.

Complications

Appendiceal rupture accounts for a majority of the complications of appendicitis. Factors that increase the rate of perforation are delayed presentation to medical care, age extremes (young and old) and hidden location of appendix. A brief period of in-hospital observation (less than six hours) in equivocal cases does not increase the perforation rate and may improve diagnostic accuracy.³⁸

Diagnosis of a perforated appendix is usually easier (although immediately after rupture, the patient's symptoms may temporarily subside). The physical examination findings are more obvious if peritonitis generalizes, with a more generalized right lower quadrant tenderness progressing to complete abdominal tenderness. An ill-defined mass may be felt in the right lower quadrant. Fever is

more common with rupture, and the WBC count may elevate to 20,000 to 30,000 per mm³ (200 to 300 × 10⁹ per L) with a prominent left shift.²⁶

A periappendiceal abscess may be treated immediately by surgery or by nonoperative management. Nonoperative management consists of parenteral antibiotics with observation or CT-guided drainage, followed by interval appendectomy six weeks to three months later.³⁸

Studies on ultrasound in acute appendicitis

A prospective randomized study on Accuracy of ultrasonography in the diagnosis of acute appendicitis was carried in the Dept. of Radiology and Imaging, Tribhuvan University, Teaching Hospital, Maharajgunj, Kathmandu, Nepal. A total of 120 patients, who were clinically diagnosed as acute appendicitis were subjected to ultrasonography of the abdomen. Ultrasonographic, intra-operative and histopathological findings were statistically insignificant (P 0.05). The sensitivity, specificity, positive predictive value, negative predictive value and accuracy percentage of ultrasonography in the diagnosis of acute appendicitis was 85.7%, 100%, 100%, 6.7% and 85.9% respectively.⁷³

A study was conducted in Fr. Muller Medical College, Kankanady, Mangalore over a period of 2 years from March 2000 to February 2002 to evaluate the role of ultrasonography in the diagnosis of acute appendicitis and to study the correlation between clinical signs, laboratory investigations and ultrasonographic findings in the evaluation of the diagnosis of acute appendicitis. A total number of 100 patients (52 men and 48 women) over a period of 2 years, with the clinical suspicion of appendicitis, were subjected to abdominal ultrasonographic

examination. Ultrasound positive cases were subjected to surgery. Out of 100 cases that underwent ultrasonography, 58 cases were sonographically positive for appendicitis and 3 cases were appendicular masses. The overall specificity of ultrasound was 88.09% and the sensitivity was 91.37% in the diagnosis of acute appendicitis.⁷⁴

In yet another study conducted in Tehran University of Medical Sciences about diagnostic values of ultrasound and the Modified Alvarado Scoring System in acute appendicitis. 75 patients with right lower quadrant pain were enrolled in the study for a period of 9 months and underwent abdominal ultrasonography and appendectomy, with pathological evaluation of the appendix. 55 male and 20 female patients were assessed. Of these patients 89.3% had acute appendicitis. The sensitivity, specificity, PPV, NPV and accuracy rate of ultrasonography was 71.2%, 83.3%, 97.4%, 25% and 72.4%, respectively.⁷⁵

A randomised controlled trial was conducted at John Hunter Hospital and John Hunter Children's Hospital, NSW, Australia comparing clinical diagnosis with a diagnostic protocol incorporating ultrasonography and the Alvarado score. Patients were considered for inclusion in the study if they were referred to Hospital with a provisional diagnosis of acute appendicitis between October 1997 and October 1998. Sensitivity and specificity of ultrasonography were measured at 94.7% and 88.9%, respectively. Patients in the intervention group who underwent therapeutic operation had a significantly shorter mean time to operation than patients in the control group (7.0 v 10.2 hours, $P=0.016$). There were no differences between groups in mean duration of hospital stay (53.4 v 54.5 hours, $P=0.84$), proportion of patients

undergoing a nontherapeutic operation (9% v 11%, $P=0.59$) or delayed treatment in association with perforation (3% v 1%, $P=0.45$).⁷⁶

Yet another study was conducted in Japan to study the utility of abdominal ultrasonography in both the clinical management of patients clinically suspected of having acute appendicitis and in reducing expenditure of hospital resources. Among the 200 patients suspected of having acute appendicitis, 57 actually had acute appendicitis. Interpretation of appendiceal ultrasonographic results was 98.5% accurate. The ultrasonographic result led to changes in the treatment of 103 patients. Moreover, ultrasonography led to the prevention of unnecessary appendectomy in 25 patients.⁷⁷

METHODOLOGY

The present study was conducted in the Department of General Surgery, KLES Dr. Prabhakar Kore Hospital and Medical Research Centre, Belagavi from January 2014 to December 2014.

Study design

The study design was hospital based study.

Study period and duration

The present one year study was conducted from 1st January 2014 to 31st December 2014.

Place

This study was conducted in the Department of General Surgery, KLES Dr. Prabhakar Kore Hospital and Medical Research Centre, Belagavi a tertiary care teaching hospital attached to KLE University's Jawaharlal Nehru Medical College, Belagavi.

Source of Data

Patients clinically diagnosed to have acute appendicitis and undergoing emergency appendicectomy in the Department of General Surgery, KLES Dr. Prabhakar Kore Hospital and Medical Research Centre, Belagavi during the study period were included in the study.

Sample size

A total of 70 patients were included in the study.

Sampling procedure

The sample size was determined based on the following formula.

$$n = Z^2_{(1-\alpha/2)} \times p \times q \div (d)^2$$

Where, n = Sample size
 Z = Constant 1.96
 p = Sensitivity
 q = 1 – p
 d = Standard error that is, 10% of p

Therefore,

$$\begin{aligned} n &= (1.96^2 \times 15) \div (0.01 \times 85) \\ &= 67.7 \sim \mathbf{70} \end{aligned}$$

Hence the sample size of 70 was considered for the present study.

Selection criteria

Inclusion

- Patients with clinical features suggestive of acute appendicitis who will eventually undergo laparotomy / laparoscopy irrespective of age and sex.

Exclusion

- Patients requiring conservative management.
- Patients with h/o recurrent pain in right iliac fossa.
- Patients with appendicular mass

Ethical clearance

The study was approved from the Institutional Ethical Committee, Jawaharlal Nehru Medical College, Belagavi prior to the commencement.

Informed Consent

The patients fulfilling selection criteria were informed in detail about the nature of the study and a written informed consent was obtained. In case of children, parents / caregivers were explained about the study details and written informed consent was obtained (Annexure I).

Method of collection of data

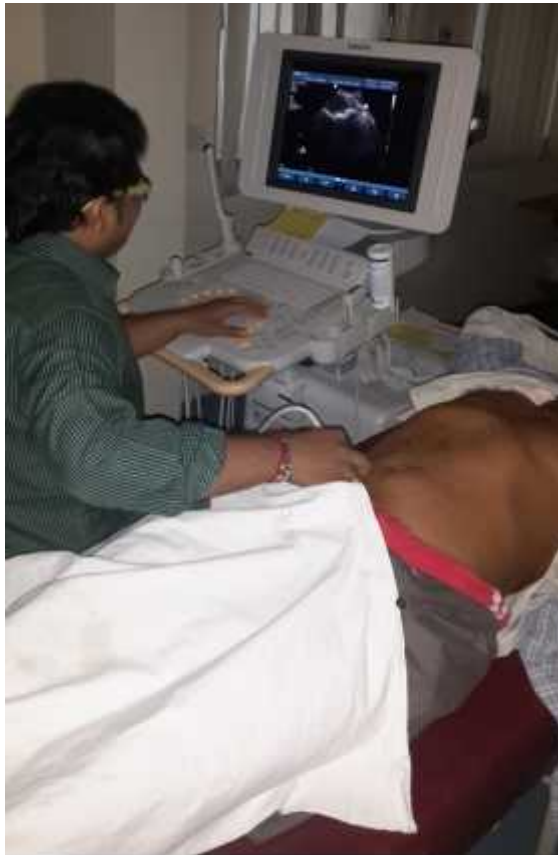Demographic data including age and gender was noted. Patients were interviewed for the past medical treatment and surgical history along with presenting complaints. Symptoms like, abdominal pain, vomiting, nausea, anorexia, fever were recorded. The patients were subjected to clinical examination. Clinical signs like RIF tenderness, rebound tenderness, guarding, rigidity, bowel sound were noted on a predesigned and pretested proforma (Annexure II).

Investigations

The following investigations were done.

- Hemoglobin
- Total leucocyte counts
- Neutrophils count

Ultrasound examination



Photograph 1. Ultrasound examination of right iliac fossa

Based on the clinical findings patient was advised for ultrasound examination. Graded compression USG was done using 3.5 - 7.5 MHz linear – array transducers according to the situation. The following accepted criteria were considered for the diagnosis of an inflamed appendix.

- Visualization of noncompressible appendix as a blind ending tubular aperistaltic structure.⁷⁸
- Target appearance of 6 mm in the total diameter on cross section and maximal mural wall thickness 2 mm).⁷⁹
- Diffuse hypoechogenesity (associated with a higher incidence of perforation).

- Lumen may be distended with anechoic / hyper echoic material.
- Loss of wall layers.
- Visualization of appendicolith.
- Localized peri-appendiceal fluid collection.
- Prominent hyper echoic mesoappendix / pericaecal fat.
- Free pelvic fluid.

Grebeldinger⁸⁰ has stated that the most reliable criteria for USG diagnosis was non-compressibility (97.67%). The second criterion was thickened wall (86.04%). It was kept in mind that a normal appendix is not visualized on USG examination and such a finding was taken as a negative test by USG in the diagnosis of appendicitis.

Accuracy of ultrasound

Following ultrasound examination, patients underwent laparotomy/laparoscopy. Final diagnosis was made on the basis of histopathological findings. The accuracy of USG was determined in comparison with Gold Standard, i.e. Histopathological Report and also with operative findings.

Statistical analysis

The data obtained was coded and entered in Microsoft Excel Spreadsheet. The categorical data was expressed as rates, ratios and percentages and comparison was done using chi-square test or fishers exact test. Continuous data was expressed as mean \pm standard deviation. A 'p' value of less than or equal to 0.05 at 95% confidence interval was considered as statistically significant. The accuracy of

ultrasound in determining the acute appendicitis was calculated by estimating sensitivity, specificity, positive predictive value (PPV), negative predictive value (NPV) and diagnostic accuracy as below.

	Disease+	Disease-
Test+	A	B
Test-	C	D

A – True positive C – False negative
B – False positive D – True negative

$$\text{Sensitivity} = A / (A+C) \times 100$$

$$\text{Specificity} = D / (B+D) \times 100$$

$$\text{PPV} = A / (A+B) \times 100$$

$$\text{NPV} = D / (C+D) \times 100$$

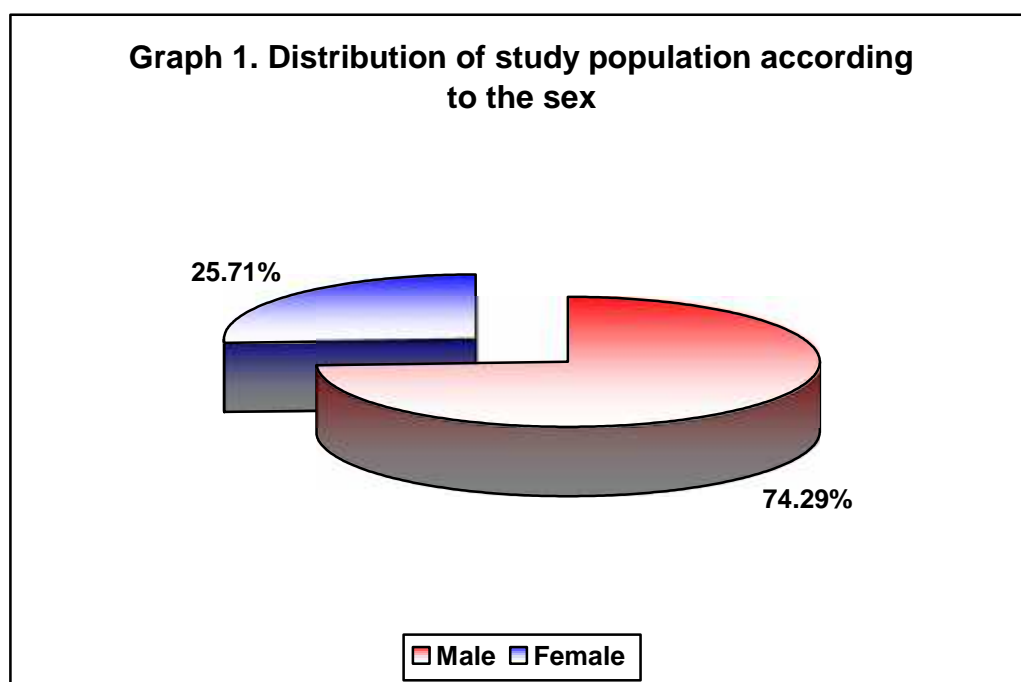
RESULTS

The present one year hospital based study was done under the Department of General Surgery, KLES Dr. Prabhakar Kore Hospital and Medical Research Centre, Belagavi. A total of 70 patients who presented with features suggestive of acute appendicitis from January 2014 to December 2014 were included in the study.

The data obtained was coded and the final results and observations were tabulated as below.

Table 1. Distribution of study population according to the sex

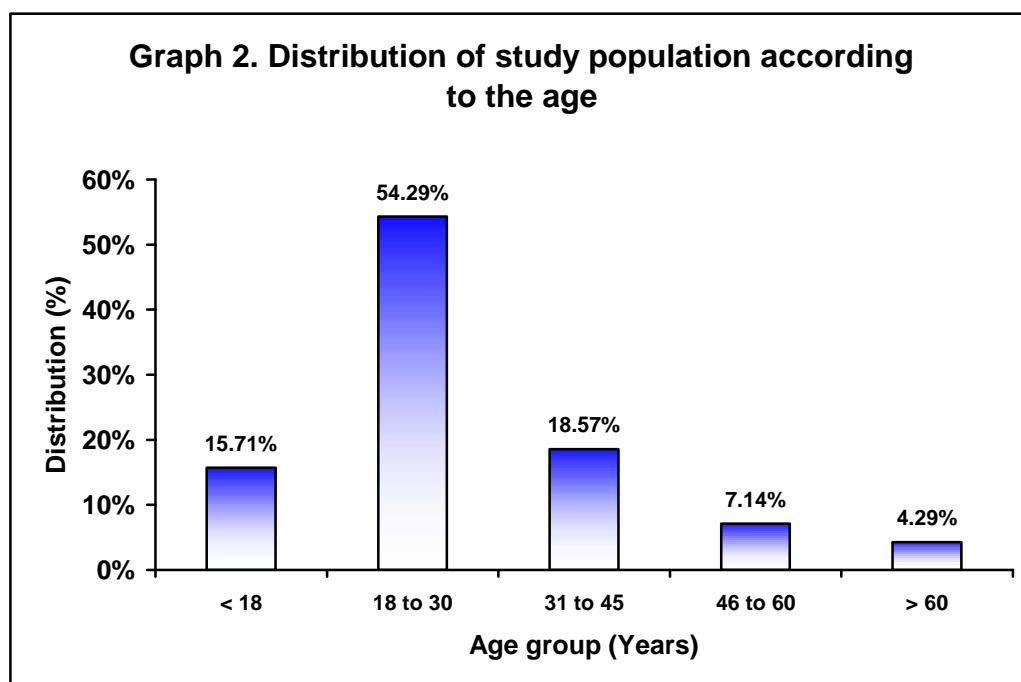
Sex	Distribution (n=70)	
	Number	Percentage
Male	52	74.29
Female	18	25.71
Total	70	100.00



In the present study 74.29% of the patients were males and 25.71% were females. The male female ratio was 2.88:1.

Table 2. Distribution of study population according to the age

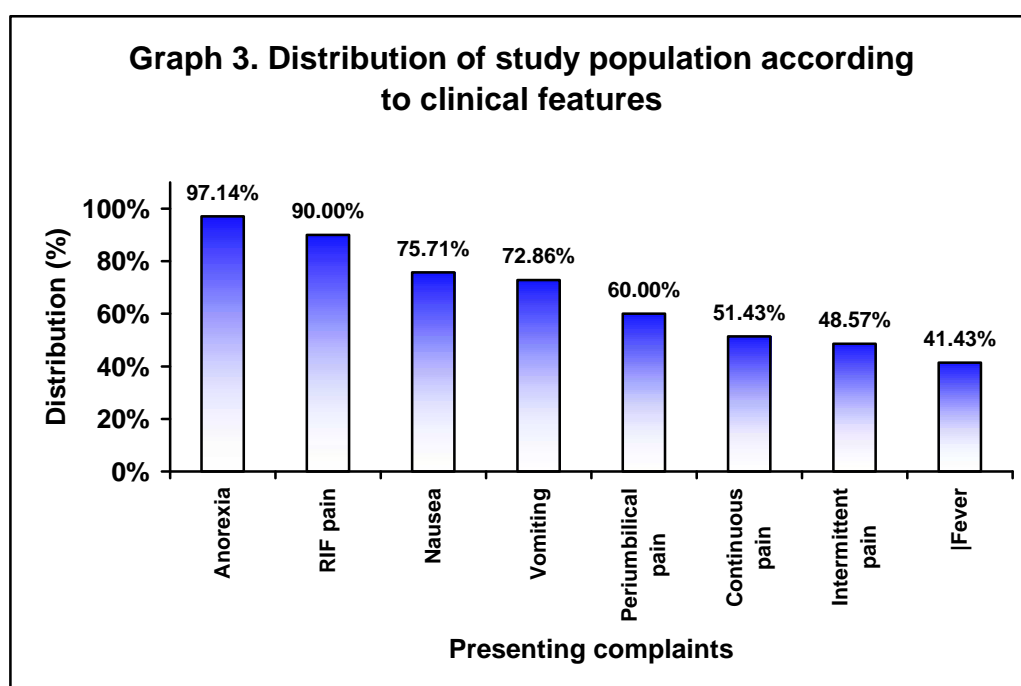
Age group (Years)	Distribution (n=70)	
	Number	Percentage
< 18	11	15.71
18 to 30	38	54.29
31 to 45	13	18.57
46 to 60	5	7.14
> 60	3	4.29
Total	70	100.00



In the present study the most of the patients presented with age between 18 to 30 years (54.29%) followed by 31 to 45 years (18.57%). The mean age was 28.32 \pm 13.15 years and median age was 25 years (Range 9 to 72 years).

Table 3. Distribution of study population according to clinical features

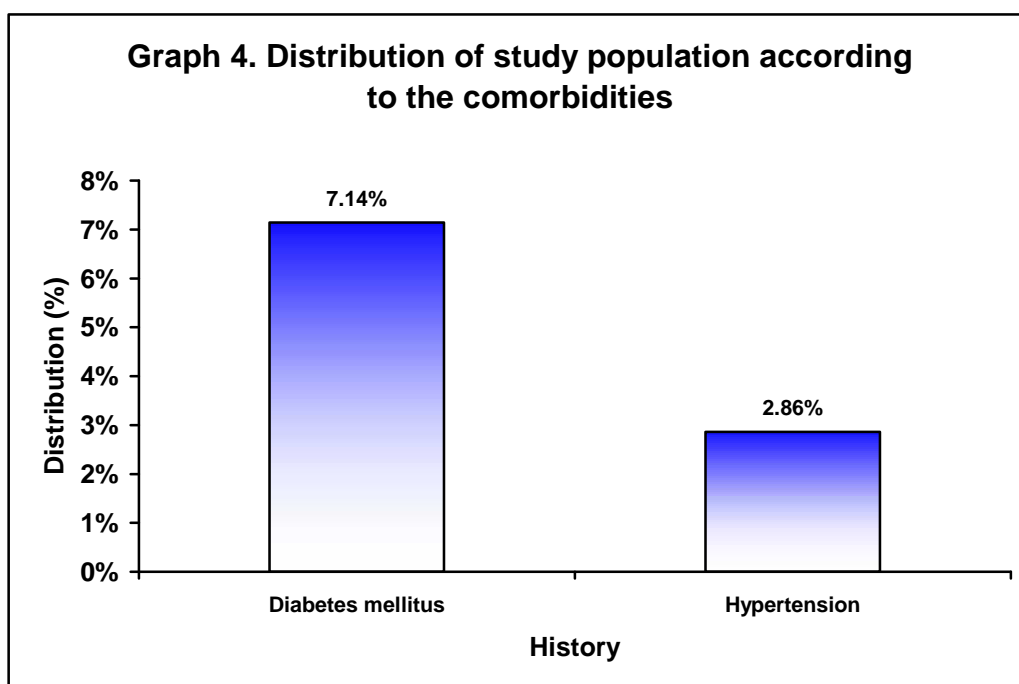
Clinical features	Distribution (n=70)	
	Number	Percentage
Anorexia	68	97.14
RIF pain	63	90.00
Nausea	53	75.71
Vomiting	51	72.86
Periumbilical pain	42	60.00
Continuous pain	36	51.43
Intermittent pain	34	48.57
Fever	29	41.43



In the present study the commonest clinical presentation was anorexia (97.14%) followed by RIF pain (90%), nausea (75.71%), vomiting (72.86%) and periumbilical pain (60%).

Table 4. Distribution of study population according to the comorbidities

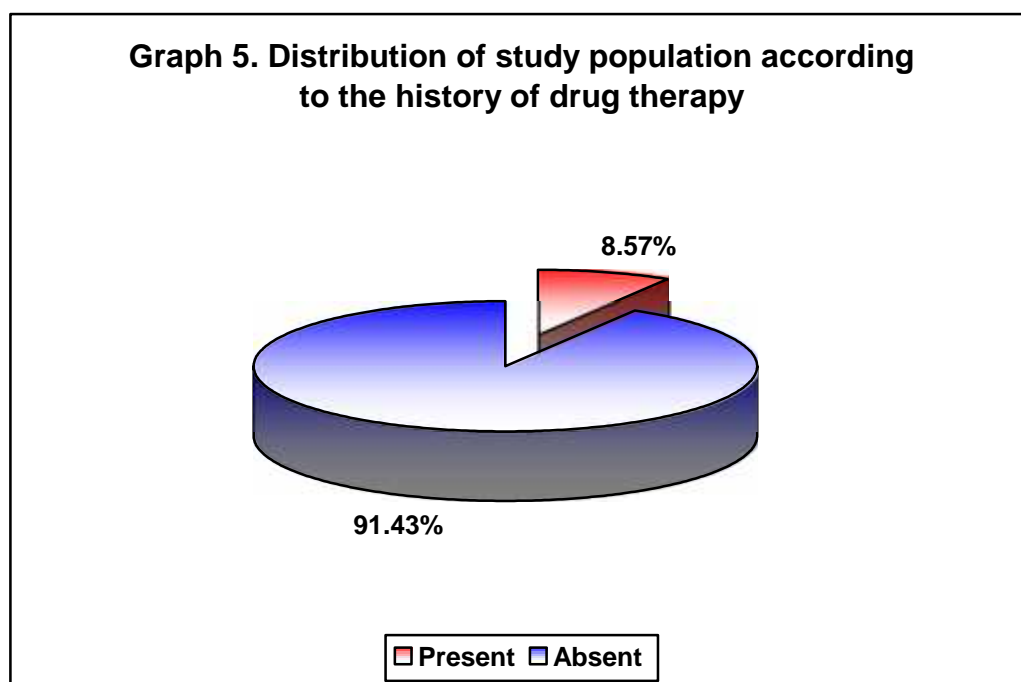
History	Distribution (n=70)	
	Number	Percentage
Diabetes mellitus	5	7.14
Hypertension	2	2.86



In this study history of diabetes mellitus and hypertension was present in 7.14% and 2.86% of the patients respectively.

Table 5. Distribution of study population according to the history of drug therapy

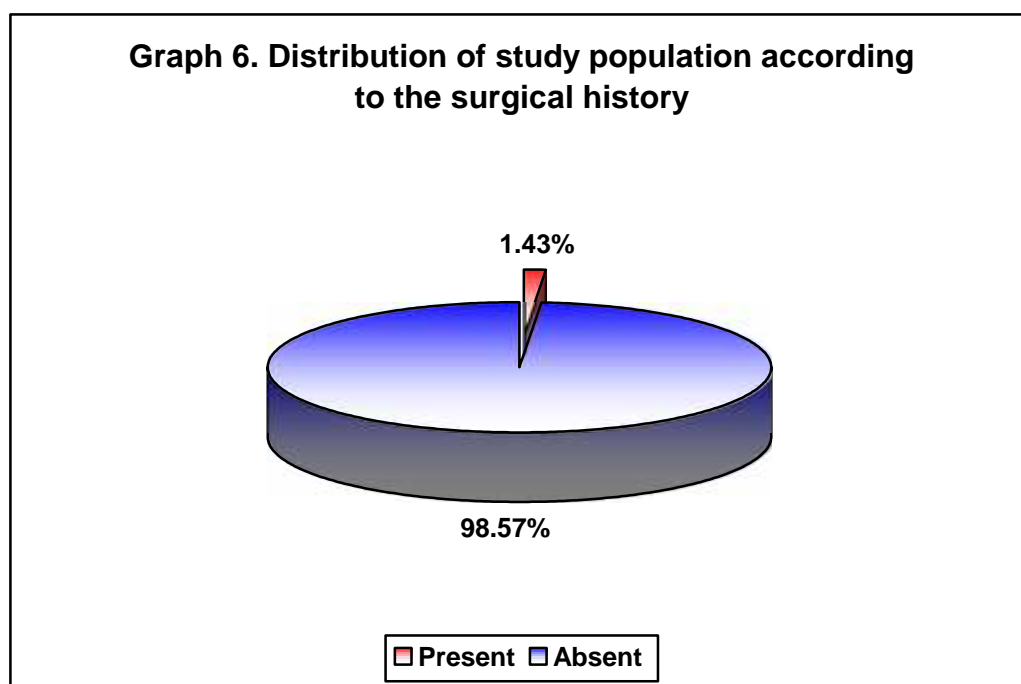
Drug therapy	Distribution (n=70)	
	Number	Percentage
Present	6	8.57
Absent	64	91.43
Total	70	100.00



In the present study the 8.57% of the patients reported treatment history of drug therapy.

Table 6. Distribution of study population according to the surgical history

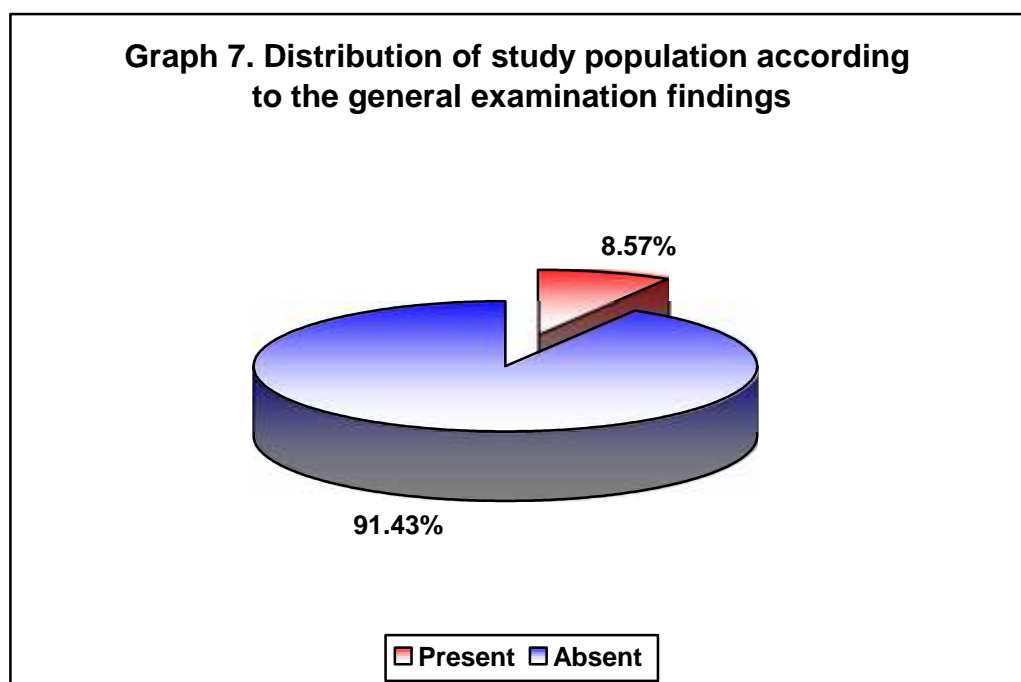
Surgical history	Distribution (n=70)	
	Number	Percentage
Present	1	1.43
Absent	69	98.57
Total	70	100.00



In this study, surgical history was present in 1.43% of the patients.

Table 7. Distribution of study population according to the general examination findings

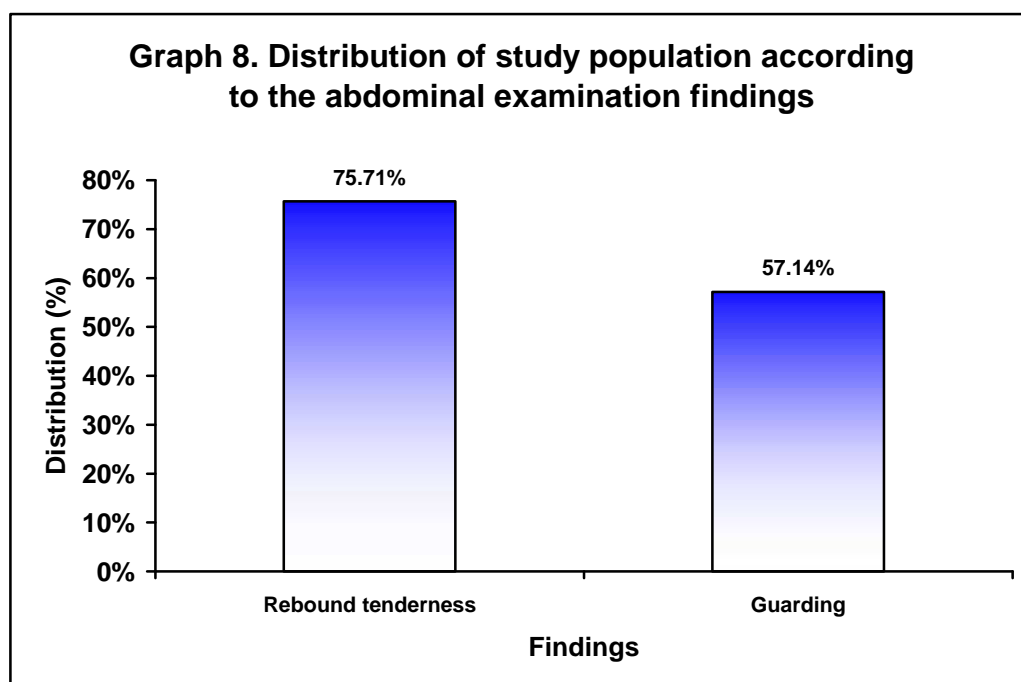
Pallor	Distribution (n=70)	
	Number	Percentage
Present	6	8.57
Absent	64	91.43
Total	70	100.00



In the present study, 8.57% of the patients had pallor.

Table 8. Distribution of study population according to the abdominal examination findings

Findings	Distribution (n=70)	
	Number	Percentage
Rebound tenderness	53	75.71
Guarding	40	57.14
Total	70	100.00



In this study on abdominal examination, rebound tenderness and guarding was observed among 75.71% and 57.14% of the patients respectively.

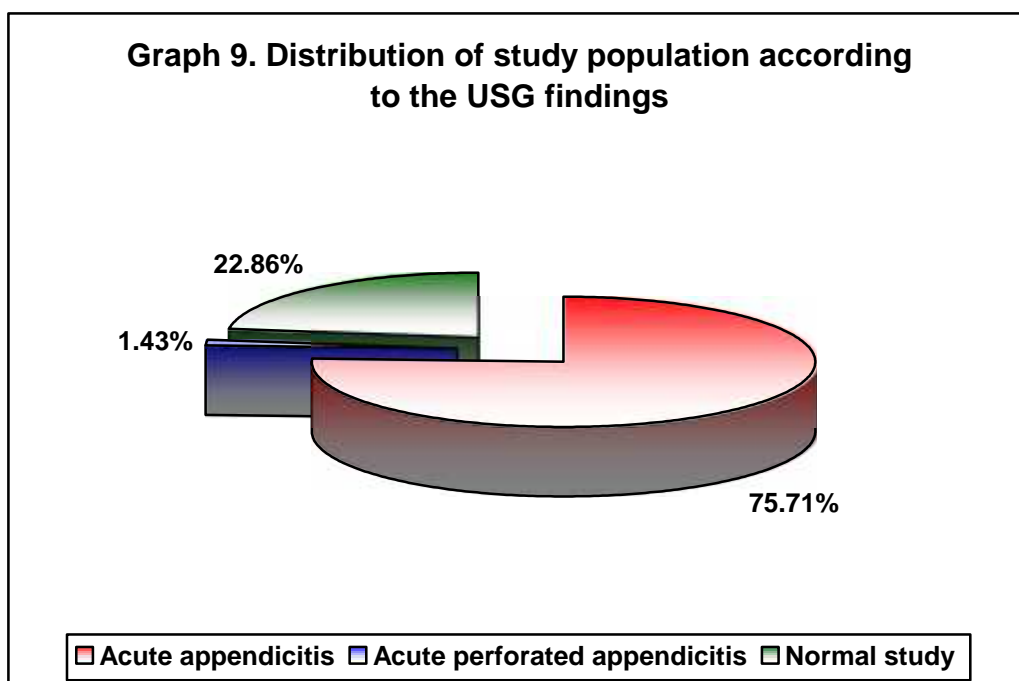
Table 9. Clinical profile of the patients

Variables	Mean (n=192)		Median	Range	
	No.	%		Minimum	Maximum
Age (Year)	28.33	13.15	25.00	9.00	72.00
Pulse rate (/Minute)	84.63	5.29	84.00	76.00	98.00
Respiratory rate (/Minute)	16.44	14.12	14.50	10.00	18.00
Temperature (⁰ C)	37.17	0.60	37.10	36.40	38.60
SBP (mm Hg)	118.23	10.08	118.00	98.00	148.00
DBP (mm Hg)	77.01	7.86	76.00	60.00	98.00
Haemoglobin (gm%)	12.72	2.27	12.90	7.30	18.20
Total count (/Cumm)	11489.00	4559.11	10620.00	5200.00	20700.00
Neutrophils (%)	71.74	14.42	72.50	30.00	95.00

The mean and median age, vitals, haemoglobin, total count and neutrophils of the study population are as depicted in Table 9.

Table 10. Distribution of study population according to the USG findings

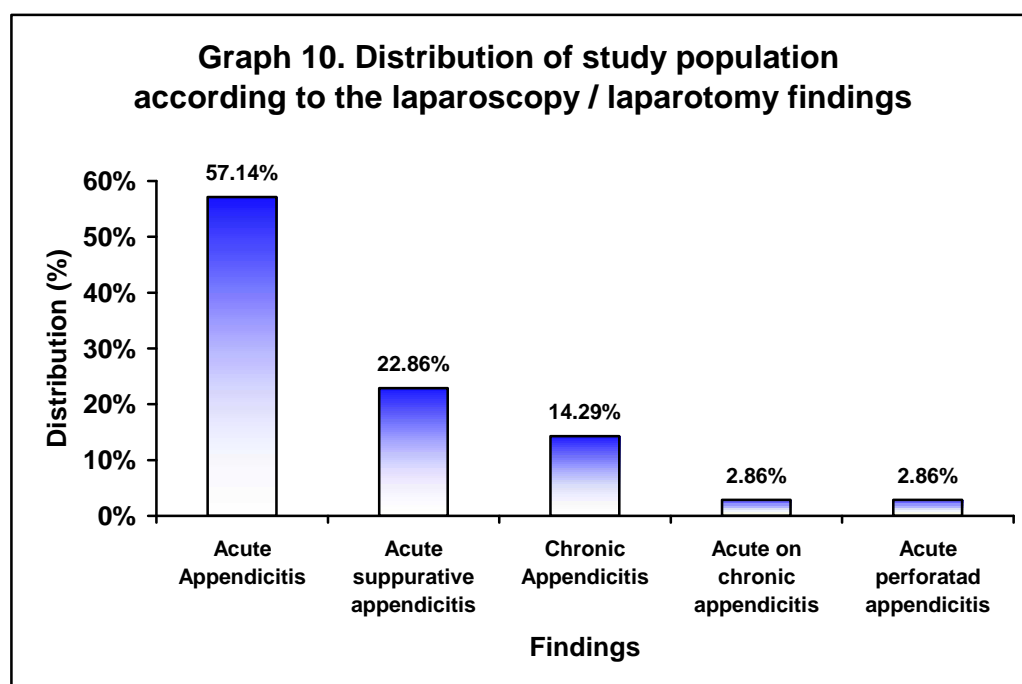
Findings	Distribution (n=70)	
	Number	Percentage
Acute appendicitis	53	75.71
Acute perforated appendicitis	1	1.43
Normal study	16	22.86
Total	70	100.00



In the present study, on USG, 75.71% of the patients had acute appendicitis and 1.43% of the patients were diagnosed to have acute perforated appendicitis.

Table 11. Distribution of study population according to the laparoscopy / laparotomy findings

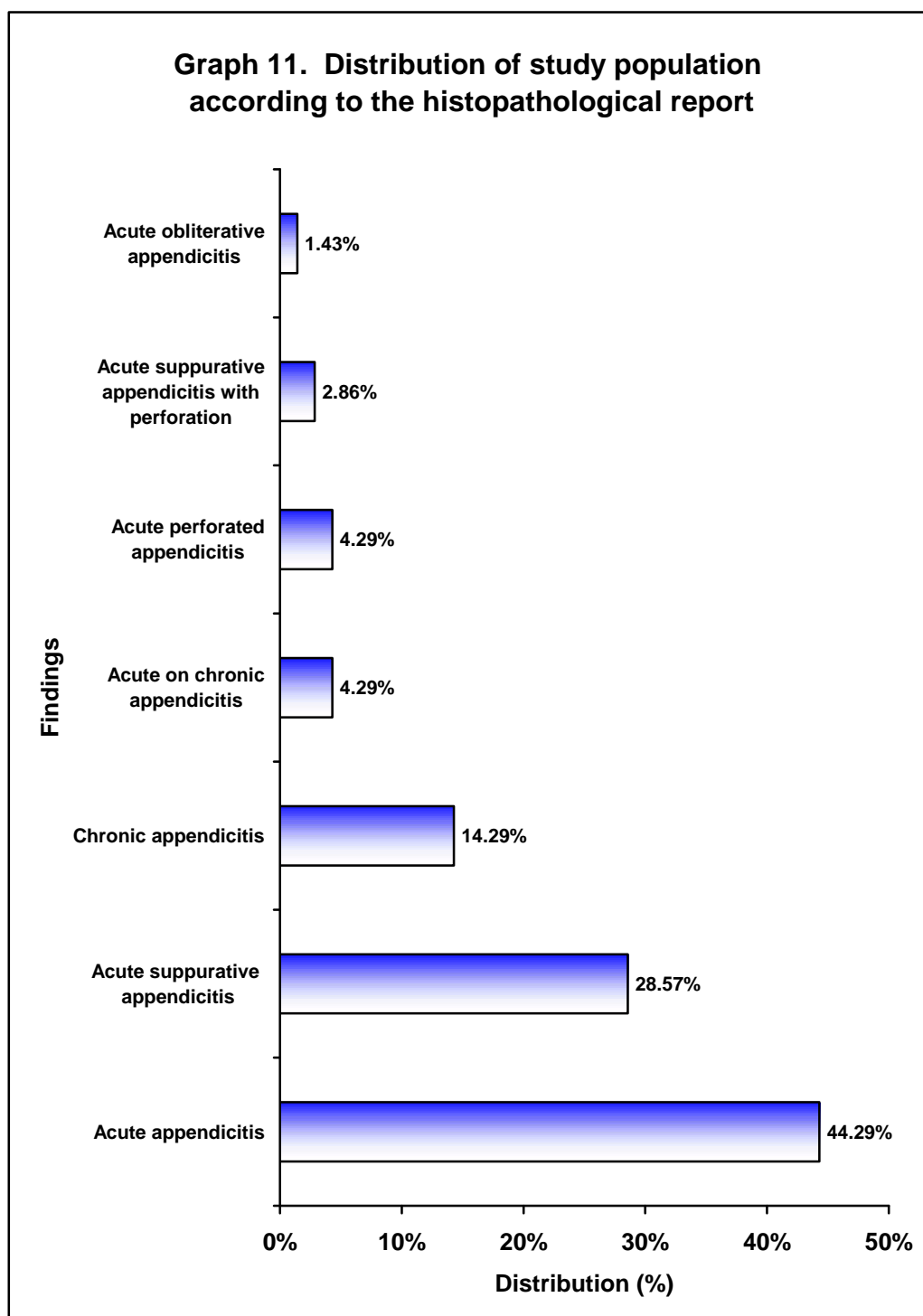
Findings	Distribution (n=70)	
	Number	Percentage
Acute Appendicitis	40	57.14
Acute suppurative appendicitis	16	22.86
Chronic Appendicitis	10	14.29
Acute on chronic appendicitis	2	2.86
Acute perforated appendicitis	2	2.86
Total	70	100.00



In this study, laparoscopy / laparotomy findings revealed acute appendicitis in 57.14% of the patients.

Table 12. Distribution of study population according to the histopathological report

Findings	Distribution (n=70)	
	Number	Percentage
Acute appendicitis	31	44.29
Acute suppurative appendicitis	20	28.57
Chronic appendicitis	10	14.29
Acute on chronic appendicitis	3	4.29
Acute perforated appendicitis	3	4.29
Acute suppurative appendicitis with perforation	2	2.86
Acute obliterative appendicitis	1	1.43
Total	70	100.00

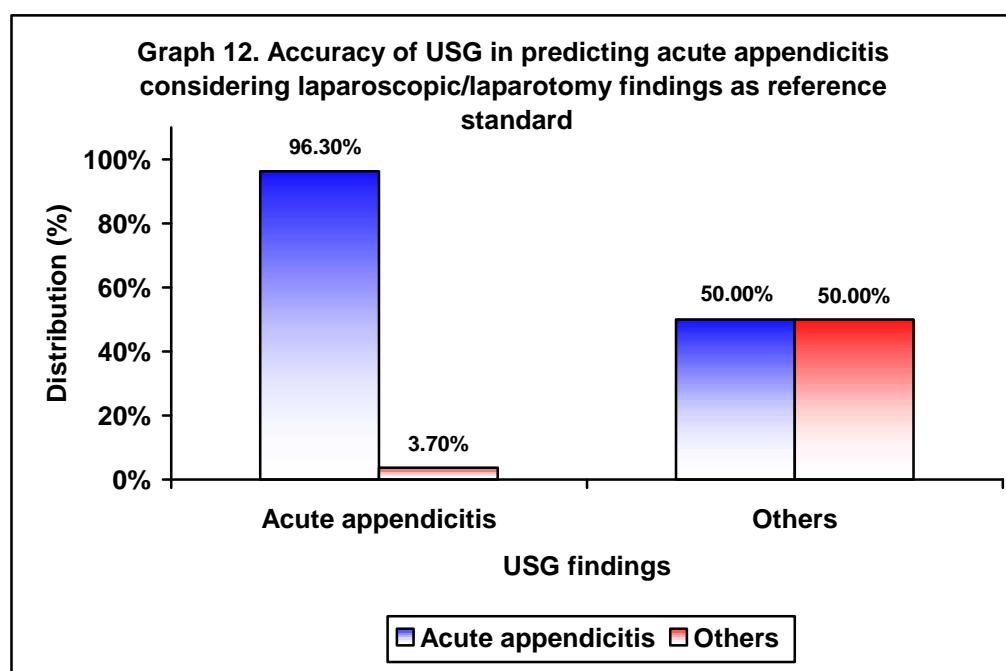


In this study, based on histopathological report the commonest diagnosis was acute appendicitis in 44.29% and acute suppurative appendicitis in 28.57% of the patients while diagnosis of chronic appendicitis was noted in 14.29% of the patients.

Table 13. Accuracy of USG in predicting acute appendicitis considering laparoscopic/laparotomy findings as reference standard

USG findings	Laparoscopic/laparotomy findings				Total	
	Acute appendicitis		Others		No.	%
	No.	%	No.	%		
Acute appendicitis	52	96.30	2	3.70	54	100.00
Other	8	50.00	8	50.00	16	100.00
Total	60	85.71	10	14.29	70	100.00

p<0.001

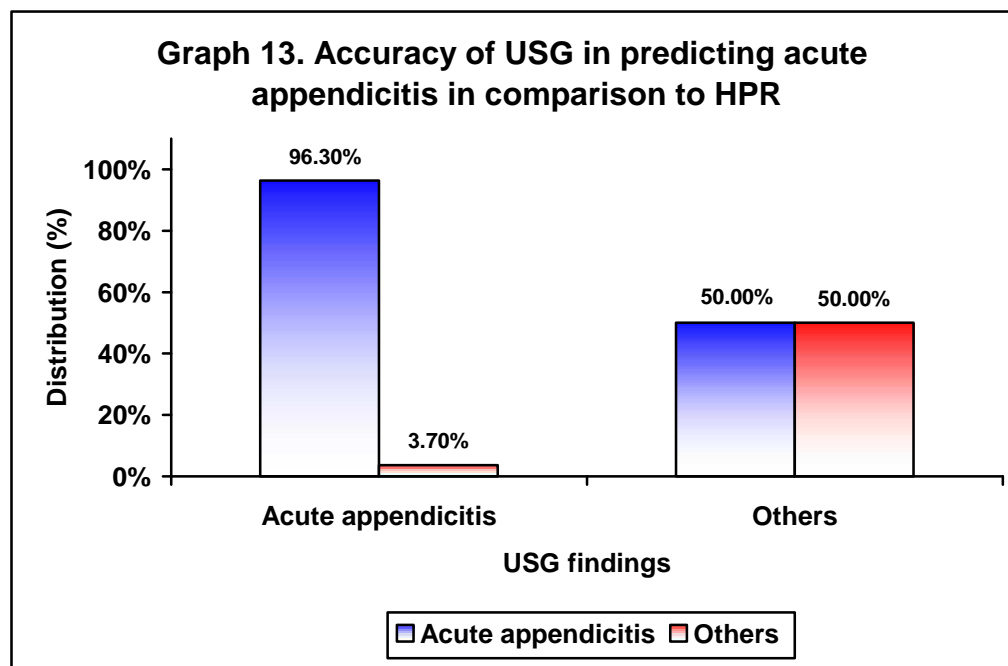


In the present study, based on USG, 54 patients had acute appendicitis which was confirmed in 52 (96.30%) patients on laparoscopic/laparotomy findings ($p<0.001$). The sensitivity of USG considering laparoscopic findings as reference standard was 86.87% with specificity of 80%, PPV of 96.30% and NPV of 50% and diagnostic accuracy was 85.71%.

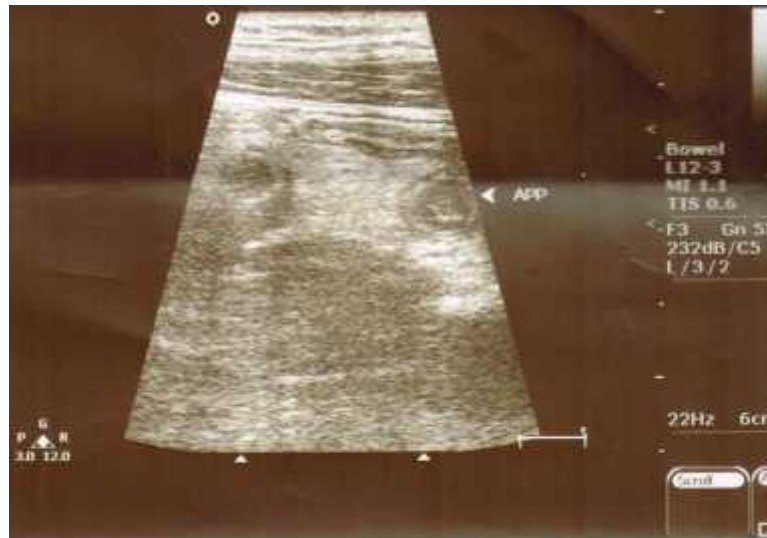
Table 14. Accuracy of USG in predicting acute appendicitis in comparison to HPR

USG findings	Histopathological findings				Total	
	Acute appendicitis		Others		No.	%
	No.	%	No.	%		
Acute appendicitis	52	96.30	2	3.70	54	100.00
Other	8	50.00	8	50.00	16	100.00
Total	60	85.71	10	14.29	70	100.00

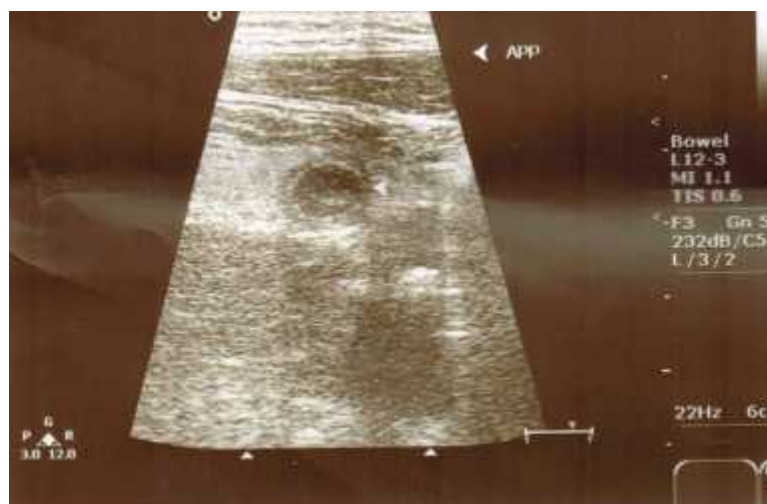p = <0.001



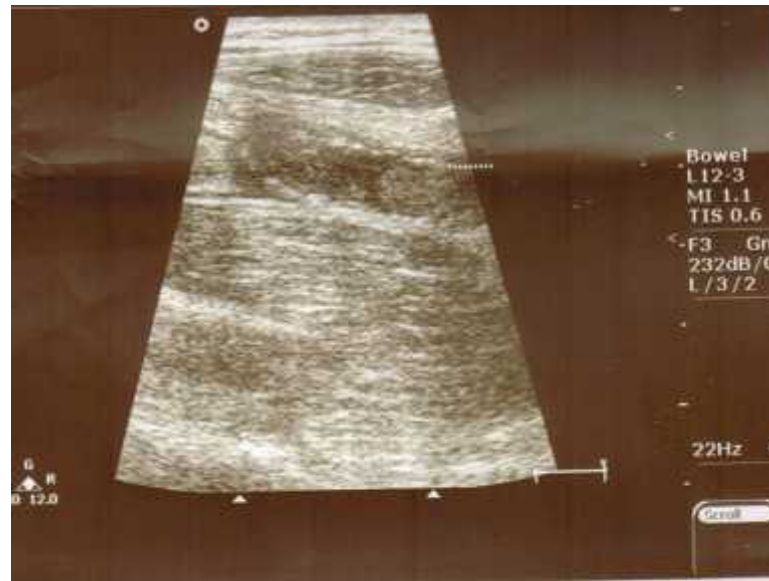
In this study 54 patients had acute appendicitis on USG. Among them the diagnosis of acute appendicitis was confirmed in 52 patients (96.3%) based on histopathological report ($p < 0.001$). The USG was 86.87% sensitive and 80%, specific in diagnosing acute appendicitis compared to HPR (PPV of 96.30%; NPV of 50%; Diagnostic accuracy of 85.71%).



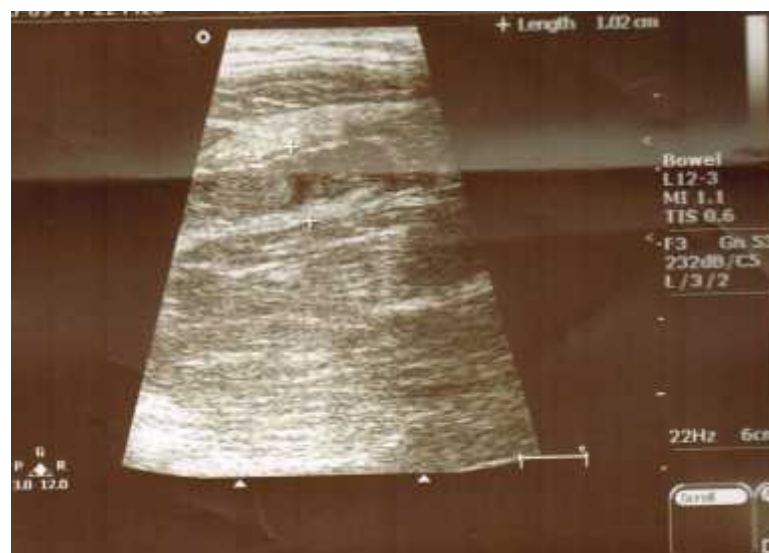Photograph 2. USG showing axial view of appendix



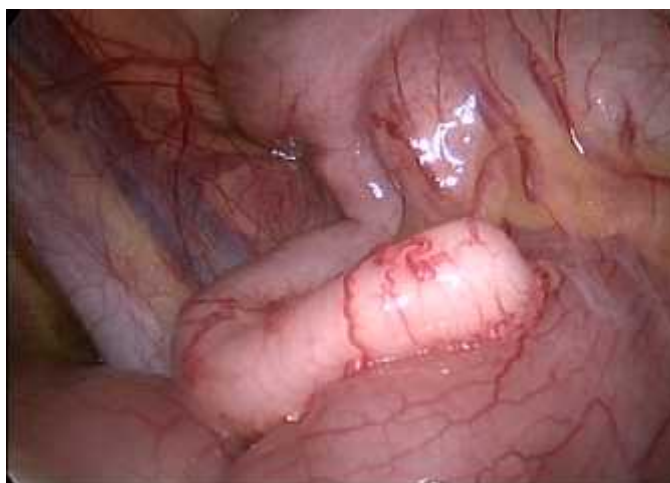Photograph 3. USG showing periappendicular fat stranding



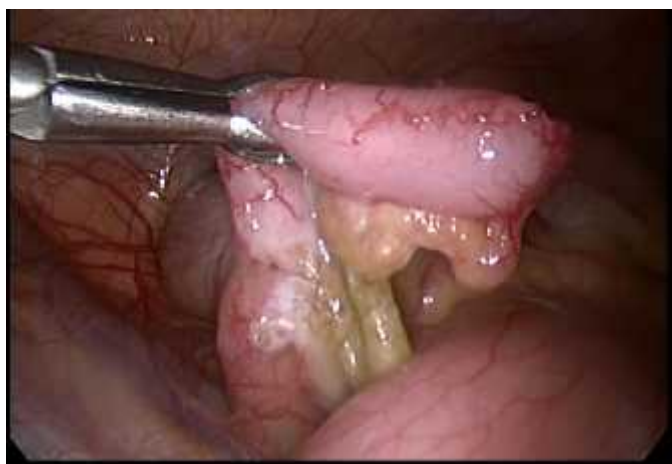Photograph 4. USG showing thickened edematous wall suggestive of inflammation



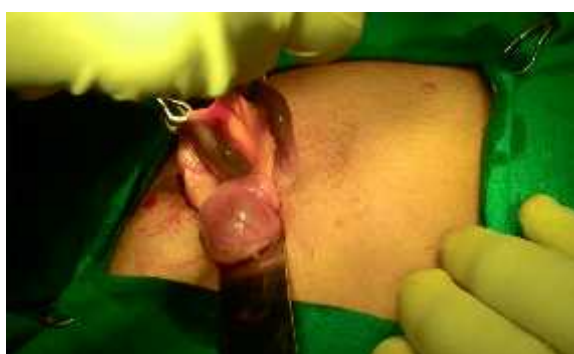Photograph 5. USG showing diameter of appendix 1.02 cms.



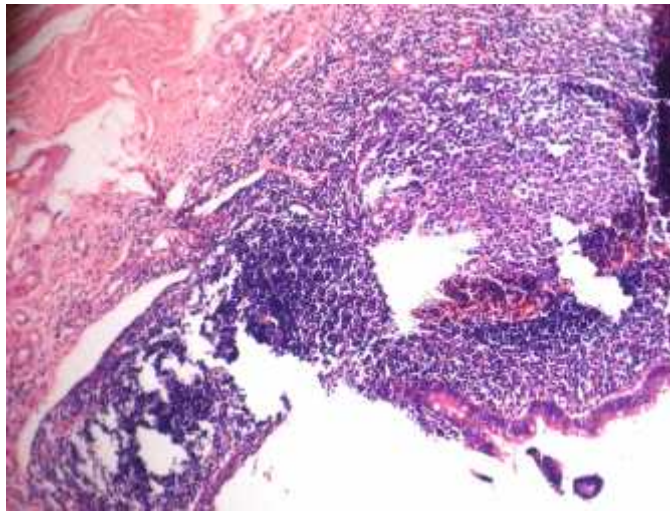
Photograph 6. Photograph showing laparoscopic view of inflamed appendix



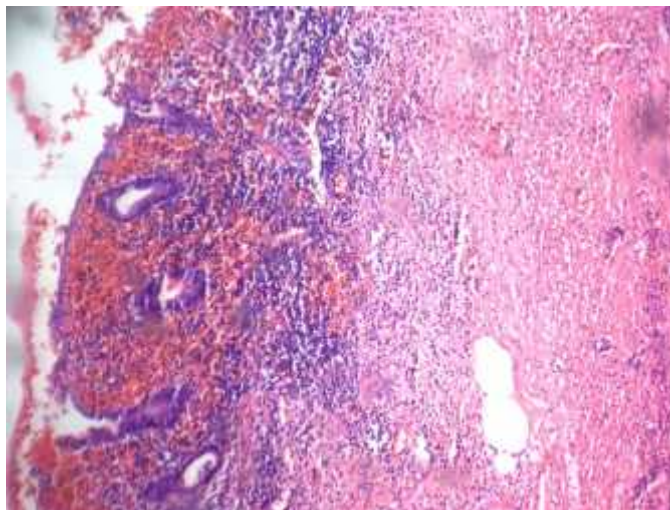
Photograph 7. Photograph showing laparoscopic view of inflamed appendix with mesoappendix



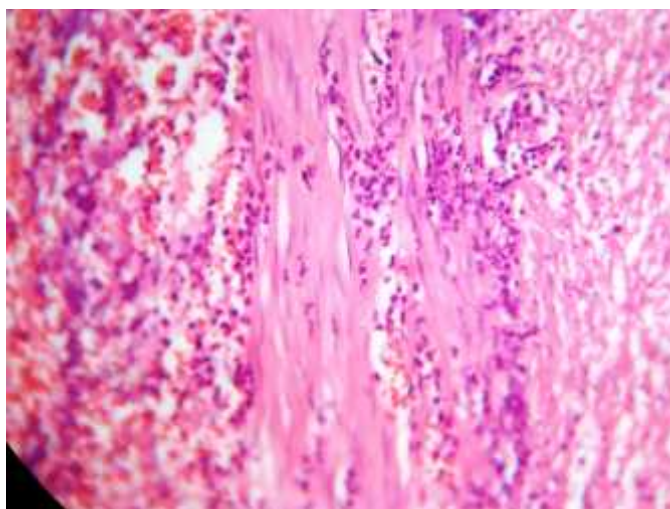
Photograph 8. Photograph showing inflamed appendix on open appendicectomy



Photograph 9. Appendix showing ulceration of mucosa



Photograph 10. Appendix showing dense inflammatory infiltrate



Photograph 11. High power(40x):showing dense inflammatory infiltrate of neutrophils in muscularis propria

DISCUSSION

Acute appendicitis (AA) is one of the most common causes of acute abdomen that warrants need for surgery. Although it is a very common pathology, its diagnosis still remains a challenge because clinically it mimics many other conditions. Differential diagnoses of AA are mesenteric lymphadenitis, gastroenteritis, constipation, right lower lobe pneumonia and a numbers of urologic or gynecologic diseases. Furthermore, the time from the onset of the disease to accurate diagnosis and treatment is critical in the management of patients with AA. Delay in diagnosis increases the risk of perforation and other complications.⁸¹

Imaging plays an important role in the modern evaluation of abdominal pain, although a consensus on the appropriate imaging protocol remains elusive. The ideal imaging test should be readily available, fast, inexpensive, reproducible, safe, and accurate. Radiographic findings are not specific, and as such, conventional radiographs are not considered cost-effective compared with CT. A radiopaque appendicolith may suggest the diagnosis of appendicitis on conventional radiography, but this finding is present in less than 5% of cases of appendicitis.⁸¹

Some studies recommend primarily ultrasonography as the imaging modality of choice in the diagnosis of equivocal patients, CT scan being reserved for those with inconclusive US.⁸²⁻⁸⁵ Ultrasound has many advantages; it can be done quickly, it is cheap, requires no preparation of the patient, does not need ionizing radiation nor any contrast.⁸¹ So in patients with equivocal signs of AA, it is the accessory modality needed to help the surgeon. However, to-date very few studies have been done to study the accuracy of ultrasound alone in the diagnosis of AA. Hence this

study is undertaken to investigate the diagnostic accuracy of the US in the diagnosis of AA.⁸¹

This one year hospital based study was carried out in the Department of General Surgery, KLES Dr. Prabhakar Kore Hospital and Medical Research Centre, Belagavi from January 2014 to December 2014. A total of 70 patients presenting with features suggestive of AA who underwent surgery were studied. The patients were subjected to ultrasound examination and the findings were compared with laparoscopy / laparotomy as well as histopathological report so as to find the accuracy.

In the present study, the occurrence of appendicitis in males (74.29%) was 2.88 times more than in females (25.71%) suggesting male preponderance. Similarly an earlier study conducted by Al-Omran, Mcleod Institute for Clinical Evaluative Sciences, Toronto in 1998 on epidemiological features of AA showed that appendicitis is more common in males and in the age group 11-20 years.⁸⁶ Recently Parsijani PJ. et al.⁸¹ also reported similar sex distribution pattern as seen in the present study (males 67.2% and females 32.8%).

In most of the studies,²² it is observed that appendicitis is common in the younger age group which we also observed. In the present study more than half of the study population was aged between 18 to 30 years (54.29%) and the next common age group was 31 to 40 years (18.57%). The mean (28.32 ± 13.15 years) and median (25 years) also indicated presence of younger age group. A recent study by Lohar HP. et al.²² in D Y Patil Medical College, Pune reported 44.65% of the cases in 11 to 20 years age group and 36.1% in 21 to 30 years age group. Previous

literature reported that, the incidence of appendicitis gradually rises from birth, peaks in the late teen years, and gradually declines in the geriatric years.⁸⁷

Anorexia, nausea and vomiting are symptoms that are commonly associated with AA.²⁶⁻²⁸ Same was true in the present study as majority of the patients presented with anorexia (97.14%) followed by RIF pain (90%), vomiting (72.86%) and periumbilical pain (60%). 7.14% and 2.86% of the patients reported history of diabetes mellitus and hypertension respectively. On abdominal examination, majority of the patients had rebound tenderness (75.71%) followed by guarding (57.14%).

USG is a valuable tool for clinically suspected appendicitis and it enhances the diagnostic accuracy. Normal appendix in ultrasound study is a compressible blind ended structure with the diameter of less than 5mm. On the other hand, inflamed appendix has an anteroposterior diameter of 6mm and is non-compressible. The existence of appendicolith in sonography also establishes the diagnosis of AA. Pathologic criteria that are in favor of tissue diagnosis of AA are infiltration of neutrophils in mucosa of the appendix and focal superficial ulceration of the mucosa. However, they are not specific for diagnosis of AA.⁸¹

In the present study, majority of the patients (77.14%) were diagnosed to have AA on USG. The other findings included acute perforated appendicitis in 1.43% of the patients. In 22.86% of the patients, USG was normal. Based on laparoscopy / laparotomy findings AA was noted in 85.71% of the patients. Of the 54 patients with AA on USG, diagnosis of AA was confirmed in 52 (96.30%)

patients on operative findings ($p < 0.001$) with 86.87% sensitivity, 80% specificity, 96.3% PPV and 50% NPV with diagnostic accuracy of 85.71%.

Further histopathological report showed AA as the commonest diagnosis (44.29%) followed by acute suppurative appendicitis (28.57%) while chronic appendicitis was diagnosed in few (14.29%) of the patients. Of the 54 patients who were diagnosed to have AA on USG, diagnosis of AA was confirmed in 52 patients (96.3%) based on histopathological report HPR ($p < 0.001$). The diagnostic accuracy of USG in diagnosing AA was 85.71% with 86.87% sensitivity, 80% specificity, 96.30% PPV and 50% NPV. These findings suggest that, that ultrasound is a useful tool in the diagnosis of AA, especially in adults. The comparison of reported range of sensitivity with the present study is as shown in table below.

	Sensitivity	Specificity	PPV	NPV
Literature ^{30,34,46-51}	44%–90%	47%–95%	89%–94%	89%–97%
Present study	86.87%	80%	96.30%	50%

The accuracy observed in the present study was well within the range that is reported in the literature except the NPV which was low. However, the sensitivity and specificity of ultrasound observed in the present study was strongly in agreement with a study by Terasawa et al.⁸⁸ who reported overall sensitivity of 86% and a specificity of 81%.

Another study by Taurolf PTS. et al.⁷⁴ from Mangalore Karnataka reported the overall specificity and sensitivity of 88.09% and 91.37% respectively.

Also the sensitivity rates were at par with the values drawn by Skanne et al,⁹⁰ Hahn et al,⁹¹ Tarzan Z et al.⁹² and Puylaert et al,⁹³ whose sensitivity ranges varied from 70 to 95%.

A large meta-analysis on the role of graded compression US in the diagnosis of acute appendicitis was carried out a few years ago, including 22 studies.⁹⁴ The overall sensitivity and specificity were 86.7% and 90.0%, respectively. The study suggested that US could be useful for the diagnosis of AA, especially when patients were younger males with a high index of suspicion.

However, there is wide variation in the accuracy of ultrasound in the literature. Several factors might be taken into account as the causes of these variations. First, because US is an operator-dependent technique, with a steep learning curve, individual skill may be an important factor to determine an extremely variable diagnostic accuracy of appendicitis.⁵⁴ Moreover, difficulties to scan populations of fertile age females may be related to the broad and frequent overlap of the symptoms of other acute abdominal conditions. In obese patients, and in post operative cases (after laparotomy) adequate compression of the right lower quadrant cannot be always achieved. Variability in the appendiceal location is a well known cause for clinical misdiagnosis, and US may show false negative finding; US may not show retrocecal appendix. Indeed, most of the false-negative diagnoses at US result from nonvisualization of the appendix or from inflammation limited to the appendiceal tip. Positive ultrasound findings have a relatively high positive-predictive value. Identification of a normal appendix is sometimes difficult. Excellent results have been achieved at select centers, with nonvisualization of the appendix being reported to have a negative-predictive value of 90%. Such results

require a great deal of skill and experience; in fact, in many centers nonvisualization of the appendix is considered equivocal.⁴

Overall the present study showed that, ultrasonography is a valuable tool in the diagnosis of AA. Though ultrasound does not replace clinical diagnosis, it is a useful adjunct in the diagnosis of AA which prevents negative explorations.

CONCLUSION

The present study showed high sensitivity, specificity and positive predictive value that is 86.87%, 80% and 96.30% respectively but low negative predictive (50%) for ultrasound in the diagnosis of AA. The overall diagnostic accuracy was 85.71%. Hence ultrasonography may be regarded as a valuable adjunct in the diagnosis of AA.

SUMMARY

Acute Appendicitis forms an important emergency in the day-to-day surgical practice. Despite the advances in medical diagnostic, the accurate diagnosis of appendicitis remains a clinical challenge. Ultrasonography has been widely used for the past two decades as an aid to clinical diagnosis of acute appendicitis. This study evaluated the sensitivity, specificity, positive and negative predictive values of ultrasound in acute appendicitis in comparison with laparotomy/laparoscopic findings and histopathological report.

This one year hospital based study was done in Department of General Surgery, KLES Dr. Prabhakar Kore Hospital and Medical Research Centre, Belagavi from January 2014 to December 2014. A total of 70 patients who presented with features suggestive of acute appendicitis who underwent surgery were studied. These patients were investigated for the diagnosis of acute appendicitis by ultrasound and the findings obtained were compared with laparoscopy / laparotomy findings and finally with histopathological report.

In the present study male preponderance was noted (74.29%) with male female ratio of 2.88:1. Most of the patients were aged between 18 to 30 years (54.29%) and the mean age was 28.32 ± 13.15 years. The commonest symptom was anorexia (97.14%). 8.57% of the patients had pallor. 75.71% and 57.14% of the patients had rebound tenderness and guarding respectively. Based on ultrasound findings, 77.14% of the patients had acute appendicitis. The laparoscopy/laparotomy findings revealed acute appendicitis in 85.71% of the patients and histopathological report also revealed acute appendicitis in 85.71% and acute

suppurative appendicitis in 28.57% of the patients. Out of 54 patients who were diagnosed to have acute appendicitis on USG, the diagnosis was confirmed in 52 (96.30%) patients on laparoscopic findings as well as histopathology ($p < 0.001$).

The sensitivity, specificity and positive predictive value of USG compared with laparotomy / laparoscopic findings and histopathological findings as a gold standard is high - 86.87% 80% and 96.30% respectively. The negative predictive value is 50% and diagnostic accuracy is 85.71%.

BIBLIOGRAPHY

1. Fitz RH. Perforating inflammation of the vermiform appendix, with special reference to its early diagnosis and treatment. *New Engl J Med* 1935;213:245-8.
2. Mohamed A, Bhat N. Acute Appendicitis Dilemma of Diagnosis and Management. *The Internet J Surg* 2009;23(2):
3. Reginelli A, Pezzullo MG, Scaglione M, Scialpi M, Brunese L, Grassi R. Gastrointestinal disorders in elderly patients. *Radiol Clin North Am* 2008; 46(4):755-71.
4. Pinto F, Pinto A, Russo A, Coppolino F, Bracale R, Fonio P, et al. Accuracy of ultrasonography in the diagnosis of acute appendicitis in adult patients: review of the literature. *Crit Ultrasound J* 2013;5 Suppl 1:S2.
5. Magaam S. Acute appendicitis in patients with different ages at Hodeidah City, Yemen. *World J Med Sci* 2011;6(3):136-41.
6. O' Connel PR. The Vermiform Appendix. In: Williams NS, Bulstrode CJK, O'Connell PR (Ed.). *Bailey and Love's - Short practice of surgery*. 25th ed., London: Arnold; 2008. p. 1204-8.
7. Polat DA, Münevver M, Selçuk U, Mahir OM, Vasfi OM, Selda S, et al. Unusual findings in appendectomy specimens: Evaluation of 2458 cases and review of the literature. *Indian J Surg* 2004;66:221-6.

8. Khairy G: Acute appendicitis. Is removal of a normal appendix still existing and can we reduce its rate? *Saudi J Gastroenterol* 2009;15:167-70.
9. Marcia LM, David Z, Darshani N, Melinda AM, Clifford Y. Negative appendectomy rate: Influence of CT scans. *Am Surg* 2005;71:803-8.
10. Kumar RV, Kumar RM, Pradeep Kumar NS, Ananthakrishnan N. Diagnostic value of C-reactive protein in suspected acute appendicitis - A prospective case control study. *Indian J Med Sci* 2011;65:399-405.
11. Jain RK, Jain M, Rajak CL, Mukherjee S, Bhattacharyya PP, Shah MR. Imaging in acute appendicitis: A review. *Indian J Radiol Imaging* 2006;16:523-32.
12. Puylaert JB. Acute appendicitis: US evaluation using graded compression. *Radiology* 1986;158:355-60.
13. Balthazar EJ, Birnbaum BA, Yee J, Megibow AJ, Roshkow J, Gray C. Acute appendicitis: CT and US correlation in 100 patients. *Radiology* 1994;190(1):31-5.
14. Brenner DJ, Hall EJ. Computed tomography - an increasing source of radiation exposure. *N Engl J Med* 2007;357(22):2277-84.
15. Yale SH, Musana KA. Famous names and medical eponyms *CM & R* 2005; 3(3):187-9.
16. Williams GR. Presidential Address: a history of appendicitis. With anecdotes illustrating its importance. *Ann Surg* 1983;197(5):495-506.

17. Russel RCG, Williams NS, Bulstrode CJK. Bailey and Loves short practice of surgery. 24th ed., London: Edward Arnold Ltd.; 2004.
18. Williams PL, Warwick R, Dyson M, Bannister LH. Gray's anatomy. 37th Ed. New York: Chruchill Livingstone; 1989.
19. Schumperick V, Dreau B, Ophoff K, Prescher A. Appendix and caecum: Embryology, anatomy and surgical applications. Surg Clin North Am 2000;80:295-318.
20. Chevre F, Gillet M, Vuilleumier H. Agencies of the vermiform appendix. Surg Lap End Percut Tech 2000;10:110-2.
21. Zinner MJ, Ashley SW. Maingot's Abdominal Operations. 12th ed., McGraw-Hill Education 2012.
22. Lohar HP, Asger Calcuttawala MA, Nirhale DS, Athavale VS, Malhotra M, Priyadarshi N. Epidemiological aspects of appendicitis in a rural setup. Med J DY Patil Univ 2014;7:753-7.
23. Craig S, Inceu L, Taylor C. Appendicitis. Medscape 2014;17:773-895.
24. Partrick DA, Janik JE, Janik JS, Bensard DD, Karrer FM. Increased CT scan utilization does not improve the diagnostic accuracy of appendicitis in children. J Pediatr Surg 2003;38:659-62.
25. Buckius MT, McGrath B, Monk J, Grim R, Bell T, Ahuja V. Changing epidemiology of acute appendicitis in the United States: Study period 1993-2008. J Surg Res 2012;175:185-90.

26. Anderson DK, Billiar TR, Dunn DL, Hunter JG, Matthews JB, Pollock RE. Schwartz's principles of surgery. 9th ed., New York: McGraw Hill; 2009.
27. Wilcox RT, Traverso LW. Have the evaluation and treatment of acute appendicitis changed with new technology? *Surg Clin North Am* 1997; 77:1355-70.
28. Graffeo CS, Counselman FL. Appendicitis. *Emerg Med Clin North Am* 1996;14:653-71.
29. Hardin MD. Acute Appendicitis: Review and Update. *Am Fam Phys* 1999;60(7);2027-34.
30. Petroiano A. Diagnosis of acute appendicitis. *International J Surg* 2012;10: 115-9.
31. Ebell MH. Diagnosis of appendicitis. *Am Fam Physician* 2008;77:828-30.
32. Howell JM, Eddy OL, Lukens TW, Thiessen MEW, Weingart SD, Decker WW. Critical issues in the evaluation and management of emergency department patients with suspected appendicitis. *Ann Emerg Med* 2010;55:71-116.
33. Shelton T, McKinlay R, Schwartz RW. Acute appendicitis. *Curr Surg* 2003; 60:502-5.
34. Humes DJ, Simpson J. Acute appendicitis. *Br Med J* 2006;333:530-4.
35. Alvarado A. A practical score for the early diagnosis of acute appendicitis. *Ann Emerg Med* 1986;15(5):557-64.

36. Prabhudesai SG, Gould S, Rekhraj S, Tekkis PP, Glazer G, Ziprin P. Artificial Neural Networks: Useful Aid in Diagnosing Acute Appendicitis. *World J Surg* 2008;32(2):305-9.
37. Hsieh CH, Lu RH, Lee NH, Chiu WT, Hsu MH, Li YC. Novel solutions for an old disease: Diagnosis of acute appendicitis with random forest, support vector machines, and artificial neural networks. *Surgery* 2011;149(1):87-93.
38. Humes DJ, Simpson J. Clinical Presentation of Acute Appendicitis: Clinical Signs-Laboratory Findings-Clinical Scores, Alvarado Score and Derivate Scores. In: Keyzer C, Gevenois PA. (eds.), *Imaging of Acute Appendicitis in Adults and Children*. Berlin Heidelberg: Springer-Verlag; 2011.
39. Andersson M, Andersson RE. The appendicitis inflammatory response score: a tool for the diagnosis of acute appendicitis that outperforms the Alvarado score. *World J Surg*. 2008;32(8):1843-9.
40. Ohmann C, Yang Q, Franke C. Diagnostic scores for acute appendicitis. *Abdom Pain Study Group. Eur J Surg* 1995;161(4):273-81.
41. Lintula H, Pesonen E, Kokki H, Vanamo K, Eskelinen M. A diagnostic score for children with suspected appendicitis. *Langenbeck's Arch Surg* 2005; 390(2):164–70.
42. Lintula H. Diagnostic score in acute appendicitis. Validation of a diagnostic score (Lintula score) for adults with suspected appendicitis. *Langenbeck's Arch Surg* 2010;395(5):495-500.

43. Fenyö G, Lindberg G, Blind P, Enochsson L, Oberg A. Diagnostic decision support in suspected acute appendicitis: validation of a simplified scoring system. *Eur J Surg* 1997;163(11):831–8.
44. Samuel M. Pediatric appendicitis score. *J Pediatr Surg* 2002;37(6):877–81.
45. Goldman RD, Carter S, Stephens D, Antoon R, Mounstephen W, Langer JC. Prospective validation of the pediatric appendicitis score. *J Pediatr* 2008; 153(2):278-82.
46. Hawkins JD, Thirlby RC. The accuracy and role of cross-sectional imaging in the diagnosis of acute appendicitis. *Adv Surg* 2009;43:13-22.
47. Hlibczuk V, Dattaro JA, Jin Z, Falzon L, Brown MD. Diagnostic accuracy of noncontrast computed tomography for appendicitis in adults. *Ann Emerg Med* 2010;55:51-9.
48. Birnbaum BA, Wilson SR. Appendicitis at the millennium. *Radiology* 2000;215:349-52.
49. Petroianu A. Faecal loading in the caecum as a new radiological sign of acute appendicitis. *Radiography* 2005;11:198-200.
50. Petroianu A, Alberti LR, Zac RI. Faecal loading in the caecum as a new radiological sign of acute appendicitis. *World J Gastroenterol* 2005;11:4230-2.

51. Petroianu A, Alberti LR, Zac RI. Assessment of the persistence of faecal loading in the caecum in presence of acute appendicitis. *Int J Surg* 2007;5:11-6.
52. Old JL, Dusing RW, Yap W and Dirks J. Imaging for suspected appendicitis. *Am Fam Phys* 2005;71(1):71-8.
53. Rodrigue G, Kanniyan L, Gopashetty M, Rao S, Shenoy R. Plain X-Ray In Acute Appendicitis *The Internet J Radiol* 2004;3:2.
54. Birnbaum BA, and. Wilson SR. Appendicitis at the Millennium. *Radiology* 2000;215:337-48.
55. Doria AS. Optimizing the role of imaging in appendicitis. *Pediatr Radiol* 2009;39(Suppl. 2):S144-8.
56. Poortman P, Oostvogel HJ, Bosma E, Lohle PN, Cuesta MA, de Lange-de Klerk ES, et al. Improving diagnosis of acute appendicitis. *J Am Coll Surg* 2009;208:434-41.
57. Morrow SE, Newman KD. Current management of appendicitis. *Sem Pediat Surg* 2007;16:34-40.
58. Puig S, H rmann M, Rebhandl W, Prokop RF-PM, Paya K. US as a Primary Diagnostic Tool in Relation to Negative Appendectomy. Six Years Experience. *Radiology* 2003;226:101-4.

59. Baldisserotto M and Marchiori E. Accuracy of Noncompressive sonography of children with appendicitis according to the potential positions of the Appendix. *AJR* 2000;175:1387-92.
60. Rettenbacher T, Hollerweger A, Macheiner P, Gritzmann N, Daniaux M, Schwamberger K, et al. Ovoid Shape of the Vermiform Appendix: A Criterion to Exclude Acute Appendicitis-Evaluation with US. *Radiology* 2003;226:95-100.
61. Neumayer L, Kennedy A. Imaging in appendicitis. *Obstet Gynecol* 2003;102:1404-9.
62. Raptopoulos V, Katsou G, Rosen MP, Siewert B, Goldberg SN, and Kruskal JB. Acute Appendicitis: Effect of Increased Use of CT on Selecting Patients Earlier. *Radiology* 2003; 226:521-6.
63. Incesu L, Coskun A, Selcuk MB, et al: Acute appendicitis: MR imaging and sonographic correlation. *AJR Am J Roentgenol* 1997;168(3):669-74.
64. Kraemer M, Ohmann C, Leppert R, Yang Q. Macroscopic assessment of the appendix at diagnostic laparoscopy is reliable. *Surg Endosc* 2000;14:625-33.
65. Walker SJ, West CR, Colmer MR. Acute appendicitis: does removal of a normal appendix matter, what is the value of diagnostic accuracy and is surgical delay important? *Ann R Coll Surg Engl* 1995;77:358-63.
66. Van den Broek WT, Bijnen AB, de Ruiter P, Gouma DJ. A normal appendix found during diagnostic laparoscopy should not be removed. *Br J Surg* 2001;88:251-4.

67. Flum DR, Morris A, Koepsell T, Dellinger EP. Has misdiagnosis of appendicitis decreased over time? *JAMA* 2001;286:1748-53.
68. Jones PF: Suspected acute appendicitis: trend in management over 30 years. *Br J Surg* 2001;88:1570-7.
69. Bisard D, Rosenfield JC, Estrada F, Reed JF. Institutioning a clinical guideline practice to decrease the rate of normal appendectomies. *Am Surg* 2003;69:796-8.
70. Mann CV. Appendix. In: Russel, Williams WS, eds. *Short Practice of Surgery*. 22nd ed., 1995. p. 832-6.
71. Styurd J, Eriksson S, Nilsson I, Ahlberg G, Haapaniemi S, Neovius G, et al. Appendectomy versus antibiotic treatment in acute appendicitis. A prospective multicenter randomized controlled trial. *World J Surg* 2006;30:1033-7.
72. Hansson J, Körner U, Khorram-Manesh A, Solberg A, Lundholm K. Randomized clinical trial of antibiotic therapy versus appendicectomy as primary treatment of acute appendicitis in unselected patients. *Br J Surg* 2009;96:473-81.
73. Khanal BR, Ansari MA, Pradhan S. Accuracy of ultrasonography in the diagnosis of acute appendicitis. *Kathmandu University Med J* 2008;6(1):70-4.

74. Taurof, Premanand TS, Aithala PS, George C, Suresh H, Acharya D, John P. Ultrasonography Is Still A Useful Diagnostic Tool In Acute Appendicitis. *J Clin Diagnostic Res* 2009;3:1731-6.
75. Nasiri S, Mohebbi F, Sodagari N, Hedayat A. Diagnostic values of ultrasound and the Modified Alvarado Scoring System in acute appendicitis. *International J Emerg Med* 2012;5:26.
76. Douglas CD, Macpherson NE, Davidson PM, Gani JS. Randomised controlled trial of ultrasonography in diagnosis of acute appendicitis, incorporating the Alvarado score. *BMJ* 2000;321:1-7.
77. Fujii Y, Hata J, Futagami K, Hamada T, Mitsuoka H, Teramen K, et al. Ultrasonography Improves Diagnostic Accuracy of Acute Appendicitis and Provides Cost Savings to Hospitals in Japan. *J Ultrasound Med* 2000;19:409-14.
78. Abu-Yousuf MM, Bleicher JJ, Maher JW, Urdaneta LF, Franken EA, Metcalf AM. High resolution sonography of acute appendicitis. *AJR* 1987; 149:53-8.
79. Rioux M. Sonographic detection of normal and abnormal appendix. *AJR* 1992;158:778-887.
80. Grebeldinger S. Ultrasonographic diagnosis of acute appendicitis. *Med Pregl* 1996;49:487-91.

81. Javidi PP, Pourhabibi ZN, Paydar S, Abbasi HR, Bolandparvaz S. Accuracy of Ultrasonography in Diagnosing Acute Appendicitis. *Bull Emerg Trauma* 2013;1(4):158-63.
82. Ca layan K, Günerhan Y, Koç A, Uzun MA, Altınlı E, Köksal N. The role of computerized tomography in the diagnosis of acute appendicitis in patients with negative ultrasonography findings and a low alvarado score. *Ulus Travma Acil Cerrahi Derg* 2010;16(5):445-8.
83. Lin WC, Lin CH. Re-appraising the role of sonography in pediatric acute abdominal pain. *Iran J Pediatr* 2013;23(2):177-82.
84. Nasiri S, Mohebbi F, Sodagari N, Hedayat A. Diagnostic values of ultrasound and the modified alvarado scoring system in acute appendicitis. *Int J Emerg Med* 2012;5(1):26.
85. Mittal MK, Dayan PS, Macias CG, Bachur RG, Bennett J, Dudley NC, et al. Performance of ultrasound in the diagnosis of appendicitis in children in a multicenter cohort. *Acad Emerg Med* 2013;20(7):697-702.
86. Al-Omran M, Mamdani M, McLeod RS. Epidemiologic features of acute appendicitis in Ontario, Canada. *Can J Surg* 2003;46:263-8.
87. Galindo Gallego M, Fadrique B, Nieto MA, Calleja S, Fernández-Aceñero MJ, et al. Evaluation of ultrasonography and clinical diagnostic scoring in suspected appendicitis. *Br J Surg* 1998;85(1):37-40.

88. Terasawa T, Blackmore CC, Bent S, Kohlwes RJ. Systematic review: Computed tomography and ultrasonography to detect acute appendicitis in adults and adolescents. *Ann Intern Med* 2004;141:537-46
89. Tauro LF, Premanand TS, Aithala PS, George C, Suresh HB, Acharya D, et al. Ultrasonography is still a useful diagnostic tool in acute appendicitis. *J Clin Diagnostic Res* 2009;3:1731-6.
90. Skanne P, Amland PF, Nordshus T, Solheim K. Ultrasonography in patients with suspected acute appendicitis. A prospective study. *Br J Radiol* 1990;63:787-93.
91. Hahn HB, Hoepner FU., Kalle T, Macdonald EB, Prantl F, Spitzer IM, et al. Sonography of acute appendicitis in children: 7 years experience. *Paediatr Radiol* 1998;28:147-51.
92. Tarjan Z, Mako E, Winternitz T, Kiss I, Kálmán A. The value of ultrasonic diagnosis in acute appendicitis. *Orv Hetil* 1995;136:713-7.
93. Puylaert JB. A prospective study of Ultrasonography in diagnosis of acute appendicitis. *NEJM* 1987;317:666-9.
94. Yu SH, Kim CB, Park JW, Kim MS, Radosevich DM. Ultrasonography in the diagnosis of appendicitis: evaluation by meta-analysis. *Korean J Radiol* 2005;5:267-77.

ANNEXURE I – CONSENT FORM

TITLE OF RESEARCH STUDY: “A STUDY TO ASSESS THE ACCURACY OF ULTRASONOGRAPHY IN ACUTE APPENDICITIS IN COMPARISON WITH LAPAROTOMY / LAPAROSCOPIC FINDINGS”

CONSENT FOR PARTICIPATION IN RESEARCH STUDY

Mr. /Mrs. /Miss. _____ we are requesting you to enroll yourself in study titled “A STUDY TO ASSESS THE ACCURACY OF ULTRASONOGRAPHY IN ACUTE APPENDICITIS IN COMPARISON WITH LAPAROTOMY/LAPAROSCOPIC FINDINGS” conducted by Dr. *****, Post Graduate in M.S. General Surgery under the guidance of Dr. *****, Professor, Department of General Surgery, J. N. Medical College, Belagavi under KLE university, Belagavi.

Respected Sir/Madam We request you to enroll yourself in our study as you are eligible for participating in the study. During the study you will be asked some questions regarding your present complaint and you are supposed to answer to the best of your knowledge.

Your participation in this research is voluntary. Your decision whether or not to participate in the study will not affect your relationship with J. N. Medical College. If you decide to participate you are free to withdraw at any time.

Purpose of the study

This study is conducted to know the accuracy of USG in diagnosing Acute Appendicitis in comparison with operative and histopathological findings.

Procedure involved

If you agree to enroll yourself in my study, I will ask your present, past and family history. Then you will be clinically examined in detail and routine investigations like Hb, TC, DC, Platelet Count ,Urine routine , RBS, Blood Urea, Serum Creatinine, Blood Grouping, Chest X-ray, ECG and ultrasound of abdomen will be done.

Risks and benefits

There are no risks involved.

Benefits

This study will help in evaluating the dependability of USG in diagnosing appendicitis.

Alternatives

Taking part in the study is voluntary. You may choose not to enroll yourself in this study. Your decision will not change present or future health care services offered to you at K.L.E. hospital. Even if you decline the participation in the study, you will get the routine line of management.

Privacy and Confidentiality

The only people to know that you are a research subject are members of the research team. No information about you or information provided by you during the research will be disclosed to others without your written permission except: a) In emergency to protect your rights and welfare, b) If required by law.

Authorization to Publish Results

When the results of the research are published or discussed, in a conference, no information will be displayed that would disclose your identity. Any information

that is obtained in connection with this study and that can be identified with your identity remains confidential.

Financial Incentives for participation

No financial incentives are being offered to enrolled patients. It is purely being done with the idea of research. There will be no additional cost to you for participating in this study.

Compensation

In the event of injury related to the study, treatment will be made available through KLES' Hospital & MRC, Belgaum. There is no compensation or payment for such medical treatment by law. If you are injured you may contact Dr. *****
***** at the Department of General Surgery, KLES Hospital& MRC or by Ph. No: ***** *****.

Questions

In case you have any questions related to the study, in future or in case of study related injury or illness, you can contact Dr. ***** *****, Dept. of General Surgery, KLES Hospital and MRC Belgaum at ***** ***** or Dr. *****, Professor, Dept. of General Surgery, KLES Hospital and MRC at ***** *****.

If you have any queries about your rights as a study subject, you may call Dr. *****, Professor, Department of Pathology and Chairman, Jawaharlal Nehru Medical College Institutional Ethical Committee for Human Subjects Research, Phone number- *****, or extension ***** at J.N. Medical College, Belgaum.

Consent for participation in research trial

I, Mr. /Ms. /Mrs. _____ voluntarily agree for the participation as a subject of study. By signing this consent form I am not giving up any of my legal rights, I may withdraw from the study anytime. I am signing the consent form after having read or been read for me in vernacular language, including the risks and the benefits and having all my questions answered.

Subject Name: _____

Signature or the Left Thumb Print of Subject: _____

Date:

Witness Name: _____

Signature: _____

Date:

Investigators Name: _____ Signature:

Date:

Place:

INFORMED CONSENT FORM

Dear Mr./Mrs./Dr _____ you are kindly requested to consent to enroll your child to participate in a research study titled “A STUDY TO ASSESS THE ACCURACY OF ULTRASONOGRAPHY IN ACUTE APPENDICITIS IN COMPARISON WITH LAPAROTOMY/LAPAROSCOPIC FINDINGS” conducted by Dr. ***** *****, Post Graduate in M.S. General Surgery under the guidance of Dr. **** ***** Professor, Department of General Surgery, J. N. Medical College, Belgaum under KLE university, Belgaum.

Respected Sir/Madam We requests you to permit your child to participate in this study as your child fits into the criteria for a study subject/participant.

Objective and purpose of the study

This study is conducted to know the accuracy of USG in diagnosing Appendicitis in comparison with operative and histopathological findings.

Procedure

If you permit your child to be a part of the research study your child shall be subjected to relevant history taking detailed clinical examination and relevant investigations like Hb, TC, DC, Platelet Count, Urine routine, RBS, Blood Urea, Serum Creatinine, Blood Grouping, Chest X-ray, ECG.

Risk and Benefits

This study has no risks on the health of your child.

Alternatives

Taking part in this study is voluntary. You may choose your child not to take part in this study, or if you decide your child to take part you can later change your mind and withdraw from the study. Your decision will not change the present or future health care or other services that your child will receive. The study doctor or

sponsor may stop his/her participation in this study any time. If you choose your child not to take part in the study he/she will receive the standard treatment.

Privacy and Confidentiality

All information collected about your child during the course of this study will be kept confidential to the extent permitted by law. Your child will be identified in research records by a code number. Information of the study may be published but your child's identity will be kept confidential.

Financial incentives for participation

Your child will not be paid / offered any gifts /incentives for participating in the study.

Authorization to publish the results

The results of the study would be forwarded to the KLE University, Belagavi as part of requirement towards the completion of MS degree for review and publishing.

Questions

In case you have any questions related to the study, in future or in case of study related injury or illness, you can contact Dr. ***** *****, Dept. of General Surgery, KLES Hospital and MRC Belgaum at ***** ***** or Dr. ***** *****, Professor, Dept. of General Surgery, KLES Hospital and MRC at ***** *****.

If you have any queries about your child's rights as a study subject, you may call Dr. ***** *****, Professor, Department of Pathology and Chairman, J. N. Medical College Institutional Ethical Committee for Human Subjects Research, Phone number- ***** *****, or extension ***** at Jawaharlal Nehru Medical College, Belgaum.

CONSENT STATEMENT

I voluntarily agree to enroll my child in this study by signing below. I may withdraw at any time. I am not giving up any of my legal rights by signing this form. My signature below indicates that I have read, or it has been read to me, this entire consent form, and have had all my questions answered.

Name of the Participant or legally authorized representative:

Signature / Thumb print _____

Principal investigator : Dr. *****

Signature _____

Guide : Dr. *****

Name of the Witness _____

Signature _____

Investigator Name and Signature _____

Date:

Place:

ANNEXURE II – PROFORMA

TITLE OF RESEARCH STUDY: “A STUDY TO ASSESS THE ACCURACY OF ULTRASONOGRAPHY IN ACUTE APPENDICITIS IN COMPARISON WITH LAPAROTOMY/LAPAROSCOPIC FINDINGS”.

Name& Address of the patient: _____

Age of the Patient : _____

In Patient Number : _____

Weight of Patient : _____

Sex : _____

Pre Operative Evaluation

Chief Complaints

Vomiting

Day's: Color:

Projectile: Non projectile:

Blood: Sour / acidic:

Abdominal pain

Day's: Diffuse: Colicky:

Continuous: Intermittent:

Loose stools

Day's:

Fever - day's

High grade: Low grade:

Continuous: Intermittent:

Past History

Diabetes mellitus:

Hypertension:

Asthma:

Drug therapy-specify:

Previous surgeries-specify:

General Physical Examination

Weight:

Temperature:

Pallor:

Height:

Cyanosis:

Pedal Edema:

Clubbing:

Pulse:

Blood Pressure:

Respiratory rate:

Systemic Examination

Cardiovascular system :

Respiratory system :

Per abdomen :

Central Nervous system :

InvestigationsComplete Blood Count

HB:

TC:

DC:

Platelet count:

ESR:

LFT

Total bilirubin

Direct bilirubin

SGOT

SGPT

ALP

Total protein

Serum Albumin

RFT

Blood Urea

Serum Creatinine

Serum sodium

Serum potassium

Urine Routine

Albumin Sugar Pus Cells Epithelial cells Casts

USG Abdomen findings

Laparotomy / Laparoscopic findings

HPR findings

ANNEXURE III - KEY TO MASTER CHART

%	-	Percentage
/Cumm	-	Per cubic millimeter
/Minute	-	Per minute
A	-	Absent
C	-	Continuous
DBP	-	Diastolic blood pressure
F	-	Female
gm %	-	Gram percent
I	-	Intermittent
M	-	Male
mm Hg	-	Millimeters of mercury
N	-	Normal
P	-	Present
RIF	-	Right iliac fossa
SBP	-	Systolic blood pressure
USG	-	Ultrasound

"A STUDY TO ASSESS THE ACCURACY OF
ULTRASONOGRAPHY IN ACUTE APPENDICITIS
IN COMPARISON WITH
LAPAROTOMY/LAPAROSCOPIC AND
HISTOPATHOLOGICAL FINDINGS"

REG NO. BH0113008

Dissertation

submitted to the
KLE University, Belagavi, Karnataka

in partial fulfillment
of the requirements for the degree of

MASTER OF SURGERY (M.S.)
in
GENERAL SURGERY

**DEPARTMENT OF SURGERY,
JAWAHARLAL NEHRU MEDICAL COLLEGE,
BELAGAVI, KARNATAKA**

APRIL - 2016

**KLE UNIVERSITY, BELAGAVI,
KARNATAKA**

ENDORSEMENT

This is to certify that the dissertation titled
“**A STUDY TO ASSESS THE ACCURACY OF
ULTRASONOGRAPHY IN ACUTE APPENDICITIS IN
COMPARISON WITH LAPAROTOMY/LAPAROSCOPIC AND
HISTOPATHOLOGICAL FINDINGS**” is a bonafide research
work done by **CANDIDATE REG NO. BH0113008.**

Dr. S. S. Shimikore MS
Professor and Head,
Department of Surgery,
J. N. Medical College,
Nehru Nagar, Belagavi – 590010

Date:
Place: Belagavi

Dr. N. S. Mahantshetti MD
Principal,
J. N. Medical College,
Nehru Nagar, Belagavi – 590010

Date:
Place: Belagavi

LIST OF ABBREVIATIONS USED

/L	-	Per Liter
°C	-	Degree centigrade
°F	-	Degree Fahrenheit
AA	-	Acute appendicitis
ALP	-	Alkaline phosphatase
cm	-	Centimeter
CRP	-	C-reactive protein
CT	-	Computed Tomography
Cumm	-	Cubic millimeters
DBP	-	Diastolic blood pressure
DC	-	Differential count
e.g.,	-	For example
ECG	-	Electrocardiogram
ESR	-	Erythrocyte sedimentation rate
gm	-	Grams
h	-	Hours
Hb	-	Haemoglobin
HB	-	Haemoglobin
HPR	-	Histopathological report
LA	-	Laparoscopic appendectomy
mg per dL	-	Milligrams per deciliter
MHz	-	Mega Hertz
mm Hg	-	Millimeters of mercury
mm	-	Millimeter

MRI	-	Magnetic resonance imaging
n	-	Total number
NPV	-	Negative predictive value
OA	-	Open appendectomy
p	-	Probability
P.C	-	Platelet count
PAS	-	Paediatric appendicitis score
PPV	-	Positive predictive value
RBS	-	Random blood sugar
RFT	-	Renal function test
RIF	-	Right iliac fossa
RLQ	-	Right lower quadrant
SBP	-	Systolic blood pressure
SGOT	-	Serum glutamic oxaloacetic transaminase
SGPT	-	Serum glutamic-pyruvic transaminase
TC	-	Total count
US	-	Ultrasound
USG	-	Ultrasonography
UTI	-	Urinary tract infection
vs.	-	Versus
WBC	-	White blood cell

ABSTRACT

Background and objectives

Despite the advances in medical diagnostic, the diagnosis of acute appendicitis (AA) remains a clinical challenge which is a common emergency in surgical practice. This study was designed to determine the sensitivity, specificity, positive and negative predictive values of ultrasound for the diagnosis of AA in comparison to laparotomy/laparoscopic findings and histopathological report.

Methodology

The present one year hospital based study was carried out in Department of General Surgery, KLES Dr. Prabhakar Kore Hospital and Medical Research Centre, Belagavi from January 2014 to December 2014. A total of 70 patients were studied. These patients were evaluated for AA by ultrasound and the findings were compared with laparoscopy/laparotomy findings and histopathological reports.

Results

Most of the patients were males (74.29%) and male:female ratio was 2.88:1. Nearly half of the study population (54.29%) was aged between 18 to 30 years and the mean age was 28.32 ± 13.15 years. The commonest symptom was anorexia (97.14%) and rebound tenderness (75.71%) was the commonest sign. Ultrasound findings revealed 77.14% of the patients with AA. During laparoscopy/laparotomy, AA was noted in 85.71% of the patients and histopathological report also revealed AA in 85.71%. Out of 54 patients who

were diagnosed to have AA on USG, the diagnosis was confirmed in 52 (96.30%) patients on laparoscopic findings as well as histopathology ($p < 0.001$).

Conclusion and interpretation

Ultrasound examination showed sensitivity, specificity and positive predictive value of 86.87% 80% and 96.30% when compared to laparotomy / laparoscopic findings and histopathological findings as a gold standard respectively. Further, the negative predictive value is 50% and diagnostic accuracy is 85.71%.

Keywords

Acute appendicitis; Ultrasound;

CONTENTS

SL. NO.	TOPIC	PAGE NO.
1.	INTRODUCTION	1
2.	OBJECTIVES	5
3.	REVIEW OF LITERATURE	6
4.	METHODOLOGY	47
5.	RESULTS	53
6.	DISCUSSION	73
7.	CONCLUSION	79
8.	SUMMARY	80
9.	BIBLIOGRAPHY	82
10.	ANNEXURES	
	ANNEXURE I – CONSENT FORM	94
	ANNEXURE II – PROFORMA	101
	ANNEXURE III – MASTER CHART	104

LIST OF TABLES

TABLE NO.	DESCRIPTION	PAGE NO.
1	Distribution of study population according to the sex	54
2	Distribution of study population according to the age	55
3	Distribution of study population according to clinical features	56
4	Distribution of study population according to the comorbidities	57
5	Distribution of study population according to the history of drug therapy	58
6	Distribution of study population according to the surgical history	59
7	Distribution of study population according to the general examination findings	60
8	Distribution of study population according to the abdominal examination findings	61
9	Clinical profile of the patients	62
10	Distribution of study population according to the USG findings	63
11	Distribution of study population according to the laparoscopy / laparotomy findings	64
12	Distribution of study population according to the histopathological report	65
13	Accuracy of USG in predicting acute appendicitis considering laparoscopic / laparotomy findings as reference standard	67
14	Accuracy of USG in predicting acute appendicitis in comparison to HPR	68

LIST OF GRAPHS

GRAPH NO.	DESCRIPTION	PAGE NO.
1	Distribution of study population according to the sex	54
2	Distribution of study population according to the age	55
3	Distribution of study population according to clinical features	56
4	Distribution of study population according to the comorbidities	57
5	Distribution of study population according to the history of drug therapy	58
6	Distribution of study population according to the surgical history	59
7	Distribution of study population according to the general examination findings	60
8	Distribution of study population according to the abdominal examination findings	61
9	Distribution of study population according to the USG findings	63
10	Distribution of study population according to the laparoscopy / laparotomy findings	64
11	Distribution of study population according to the histopathological report	66
12	Accuracy of USG in predicting acute appendicitis considering laparoscopic / laparotomy findings as reference standard	67
13	Accuracy of USG in predicting acute appendicitis in comparison to HPR	68

LIST OF FIGURES

FIGURE NO.	DESCRIPTION	PAGE NO.
1	Anatomic variation in the position of the appendix	8
2	Appendiceal ultrasound showing distended non compressible appendix measuring 1.7 cms in transverse dimension	31

LIST OF PHOTOGRAPHS

PHOTO NO.	DESCRIPTION	PAGE NO.
1	Ultrasound examination of right iliac fossa	50
2	USG showing axial view of appendix	69
3	USG showing periappendicular fat stranding	69
4	USG showing thickened edematous wall suggestive of inflammation	70
5	USG showing diameter of appendix 1.02 cms	70
6	Photograph showing laparoscopic view of inflamed appendix	71
7	Photograph showing laparoscopic view of inflamed appendix with mesoappendix	71
8	Photograph showing inflamed appendix on open appendicectomy	71
9	Appendix showing ulceration of mucosa	72
10	Appendix showing dense inflammatory infiltrate	72
11	High power(40x):showing dense inflammatory infiltrate of neutrophils in muscularis propria	72