
“ A ONE YEAR RANDOMIZED CONTROL STUDY TO
COMPARE THE OUTCOMES OF TWO INCISIONS THREE
PORTS AND FOUR PORTS LAPAROSCOPIC
CHOLECYSTECTOMY AT KLES DR. PRABHAKAR KORE
HOSPITAL AND MEDICAL RESEARCH CENTRE,
BELAGAVI ”

BY

REG. NO. BH0116005

Dissertation

Submitted to the

KLE Academy of Higher Education and Research, Belagavi,
Karnataka

In partial fulfillment

of the requirements for the degree of

MASTER OF SURGERY (M.S)

IN

GENERAL SURGERY

DEPARTMENT OF GENERAL SURGERY,
J. N. MEDICAL COLLEGE
BELAGAVI - 590010. KARNATAKA

APRIL – 2019

**KLE Academy of Higher Education and Research, Belagavi,
KARNATAKA**

**Endorsement by the HOD/ Principal/ Head
of the Institution**

This is to certify that the dissertation entitled “A ONE YEAR
RANDOMIZED CONTROL STUDY TO COMPARE THE OUTCOMES OF
TWO INCISIONS THREE PORTS AND FOUR PORTS LAPAROSCOPIC
CHOLECYSTECTOMY AT KLES DR. PRABHAKAR KORE HOSPITAL AND
MEDICAL RESEARCH CENTRE, BELAGAVI” is a bonafide research work done
by **REG. NO. BH0116005**

Dr. A.S.GOGATE M.S.
Professor and Head,
Department of General Surgery,
J. N. Medical College,
Nehru Nagar, Belagavi – 10

Date:
Place: Belagavi

Dr. N.S. Mahantashetti MD
Principal,
J. N. Medical College,
Nehru Nagar, Belagavi – 10

Date:
Place: Belagavi

LIST OF ABBREVIATIONS USED

CBD	-	Common bile duct
CVS	-	Critical view of safety
i.e.	-	That is
LC	-	Laparoscopic cholecystectomy
mm	-	Millimeter
mmHg	-	Millimetres of mercury
NOTES	-	Natural Orifice Transluminal Endoscopic Surgery
RHD	-	Right hepatic duct
SILC	-	Single Incision Laparoscopic Cholecystectomy
SILS	-	Single Incision Laparoscopic Surgery
Vs	-	Versus
VAS	-	Visual Analogue Scale

ABSTRACT

INTRODUCTION

Laparoscopic cholecystectomy has been accepted as the gold standard procedure for symptomatic gall bladder disease with the benefits of short length of hospital stay, immediate regaining of physical activity, less post-operative pain, morbidity and mortality, and good cosmetic outcomes. Standard laparoscopic cholecystectomy is done by using four trocars. With increasing surgeon experience, laparoscopic cholecystectomy has undergone many refinements including reduction in port size and number to reduce the post-operative pain and improve cosmetic outcome. Three port, two port and even single incision laparoscopic cholecystectomy (SILC) has emerged. The present study was undertaken to establish the efficacy and safety of two incisions three ports laparoscopic cholecystectomy as compared to standard four port laparoscopic cholecystectomy.

METHODOLOGY

This one year randomized control study was conducted in the department of general surgery of K.L.E.S Dr. Prabhakar Kore Hospital and Medical Research Centre, Belagavi from January 2017 to December 2017. A total of 61 patients were divided into two groups, group A (two incision three ports laparoscopic cholecystectomy) and group B (standard four port laparoscopic cholecystectomy).

RESULTS

There was significantly lesser post-operative pain at both 6 hours and 24 hours with a better cosmetic satisfaction in the two incisions three ports laparoscopic cholecystectomy group with no significant difference in operating time.

CONCLUSION

The two incisions three ports laparoscopic cholecystectomy can be performed as a feasible and safe procedure like the standard four port procedure. The outcomes of post-operative pain and cosmetic satisfaction were better than the standard four port procedure with equivalent operative time.

Keywords:

Laparoscopic cholecystectomy, two incisions three ports laparoscopic cholecystectomy

CONTENTS

S.NO	TOPIC	PAGE NO
1	INTRODUCTION	1-3
2	OBJECTIVES	4
3	REVIEW OF LITERATURE	5-25
4	MATERIALS AND METHODS	26-41
5	RESULTS	42-50
6	DISCUSSION	51-59
7	CONCLUSION	60
8	SUMMARY	61-62
9	BIBLIOGRAPHY	63-69
10	ANNEXURES	
	ANNEXURES I: CONSENT FORM	70-76
	ANNEXURES II: PROFORMA	77-80
	ANNEXURES III: MASTER CHART	81

LIST OF TABLES

TABLE NO.	DESCRIPTION	PAGE NO.
1	Age distribution	43
2	Post-operative pain at 6 hours	45
3	Post-operative pain at 24 hours	46
4	Operating time	48
5	Cosmetic outcome	49
6	Cosmetic outcome at followup	50

LIST OF GRAPHS

GRAPH NO.	DESCRIPTION	PAGE NO.
1	Age distribution	43
2	Gender distribution	44
3	Mean operating time	48

LIST OF FIGURES

FIGURE NO.	DESCRIPTION	PAGE NO.
1	Stages in the development of gall bladder and biliary tree	6
2	Stages in the development of gall bladder and biliary tree	6
3	Gall bladder and bile ducts	8
4	Cystic duct variations	9
5	Triangle of Calot- Laparoscopic View	10
6	Rouviere's Sulcus	11
7	Critical View Of Safety	12
8	Conventional Laparoscopic Cholecystectomy Setup	18
9	Visual Analogue Scale	20
10	SILS Port	21
11	Standard Laparoscopic Cholecystectomy Setup	29
12	Port Placement in Standard Laparoscopic Cholecystectomy	30
13	Four Port Laparoscopic Cholecystectomy	31
14	Four Ports After Closure	31
15	Two Incisions Three Ports Laparoscopic Cholecystectomy Setup	33

FIGURE NO.	DESCRIPTION	PAGE NO.
16	Suture passed through cystic plate	33
17	Suture passed through diaphragm	34
18	Suture taken transcutaneously	34
19	Suture retracts the gall bladder	35
20	Port Placement in Two Incisions Three Ports Laparoscopic Cholecystectomy	35
21	Umbilical Port Site Showing Two Ports in a Single Incision	36
22	Suture Passer	36
23	Two Incisions Three Ports- After Closure	37
24	Wound after Passage of Transcutaneous Suture	38
25	Two Incisions Three Ports- Post-op Day 3	38
26	Two Incisions Three Ports- After Suture Removal	39
27	Two Incisions Three Ports- At Followup	39

INTRODUCTION

The first open cholecystectomy was performed in 1882 and the first laparoscopic cholecystectomy (LC) was performed in 1987 by Phillip Mouret and later established by Dubois and Perissat in 1990.^{1,2} Since then, laparoscopic cholecystectomy has been met with widespread acceptance as the gold standard procedure for symptomatic gall bladder disease. Short length of hospital stay, immediate regaining of physical activity, less postoperative pain, morbidity and mortality, and good cosmetic outcomes contribute to the benefits of laparoscopic cholecystectomy.³

Standard laparoscopic cholecystectomy is done by using four trocars, one for the camera, two for manipulation of tissues and another for retraction. The fourth (lateral) trocar is used to grasp the fundus of the gallbladder so as to expose Calot's triangle. With increasing surgeon experience, laparoscopic cholecystectomy has undergone many refinements including reduction in port size and number. It has been argued that the fourth trocar may not be necessary, and laparoscopic cholecystectomy can be performed safely without using it.⁴

Current surgical standards of practice continue to evolve to less invasive procedures by minimizing the number and size of ports. Reducing the size or number of ports did not affect the safety of the procedure and further enhanced the advantages of laparoscopic over open cholecystectomy. These modifications actually reduced the pain and analgesia requirement. Three trocars and even two trocars were used to perform laparoscopic cholecystectomy with even mini instruments.^{5,6} Cooperative manipulation of the surgical instruments is very important for these procedures, for

exposing Calot's triangle and dissecting the gallbladder from the gallbladder bed when using the three and two port techniques.⁴

There was emergence of a much lesser invasive procedure known as Single incision laparoscopic cholecystectomy (SILC) with the benefits of single periumbilical incision and therefore decreased pain, improved cosmesis and faster recovery. SILC however had its disadvantages of technical difficulty, prolonged operating time and cost of special instruments and ports.^{7,8,9}

Another completely newer technique that is evolving is natural orifice transluminal endoscopic surgery (NOTES), where the goal is to perform intraperitoneal operations safely through a natural orifice obviating the need for any skin incision. This reduces surgical pain, decreases anesthesia and analgesia, shortens recovery time, avoids hernia formation and adhesions, and eliminates any surgical site infection and visible scarring. This technique involves breaching the wall of the stomach, colon, vagina or bladder by endoscopic means to gain access into the peritoneum. Several NOTES surgery has been performed even on humans, such as transvaginal cholecystectomy. However several challenges are faced such as the need for proper channels for instruments, special orientation, triangulation for dissection and retraction, closure techniques to prevent intraperitoneal infection and the higher costs involved and the associated learning curve.¹⁰

The SILC and NOTES which required special instruments, higher costs and learning curve could not gain popularity even though they are less invasive in nature.

Thus lesser invasive procedures with the use of regular conventional instruments and ports such as two incisions three ports laparoscopic cholecystectomy and its benefits in terms of lesser post-operative pain and good cosmetic outcome and the practicality, feasibility and safety of the procedure needs to be assessed.

There are hardly few studies where they have compared two incision laparoscopic cholecystectomy and conventional four port laparoscopic cholecystectomy.

In this study, we compared this modified method of reduced port (two incisions three port) laparoscopic cholecystectomy using standard laparoscopic instruments with the standard four port laparoscopic cholecystectomy.

OBJECTIVES

Primary objective-

To compare the post-operative pain of two incisions three ports laparoscopic cholecystectomy versus conventional four ports laparoscopic cholecystectomy.

Secondary objectives

1. Operating time,
2. Cosmetic satisfaction,
3. Technical feasibility and complications.

REVIEW OF LITERATURE

HISTORY OF LAPAROSCOPIC CHOLECYSTECTOMY

The first open cholecystectomy was performed in 1882 by Carl Langenbuch, and it took a century to perform the first laparoscopic cholecystectomy by Philippe Mouret of Lyon, France in 1987. It was later established by dubois and perissat in 1990.^{11,12} The development of laparoscopic surgery is an example of how newer technology has significantly changed the way surgeons operate. At its infancy, laparoscopy was faced with numerous obstacles to its progress. Over the past two decades the four port laparoscopic cholecystectomy has become the standard of care for gall bladder disease.¹⁰

For any surgical procedure, the understanding of embryology and surgical anatomy is important.

EMBRYOLOGY

In the third week of fetal life, the liver bud or hepatic diverticulum develops from the foregut and the connection between the diverticulum and foregut narrows forming the bile duct. A ventral outgrowth from the bile duct gives rise to the gall bladder and the cystic duct. In the 12th week when the bile is formed by hepatic cells, it flows through the biliary tree to enter the gastrointestinal tract. Due to positional changes in the duodenum, the entrance of the bile duct shifts from its initial anterior to posterior position and the bile duct passes behind the duodenum.¹³

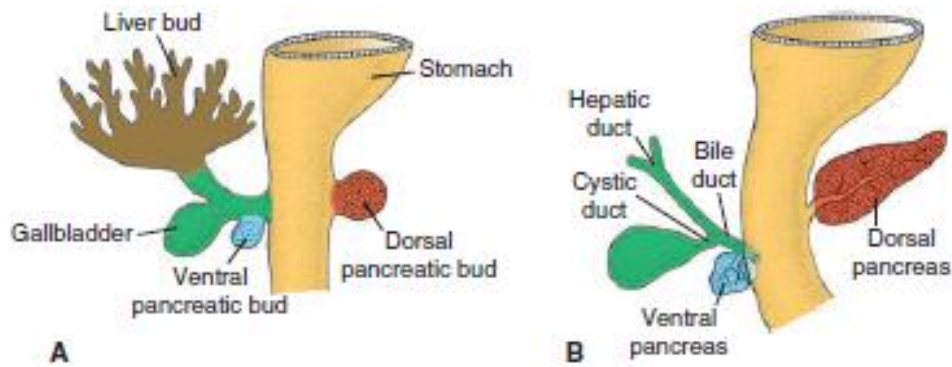


Figure 1: Stages in the development of gall bladder and biliary tree¹³

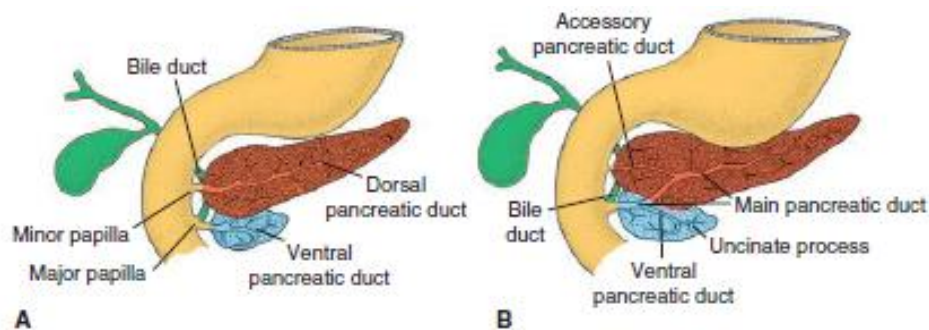


Figure 2: Stages in the development of gall bladder and biliary tree¹³

SURGICAL ANATOMY OF THE GALL BLADDER

The gallbladder is a flask-shaped, blind-ending diverticulum attached via the cystic duct to the common bile duct. It has a grey-blue colour and is attached to the inferior surface of the right lobe of the liver by connective tissue. The gallbladder is 7 to 10 cm long and has a capacity up to 50 ml. It lies in a shallow fossa in the visceral surface of the liver parenchyma at the junction of the right lobe and medial segment of the left lobe, covered by peritoneum on its nonhepatic surface continued from the liver surface. It is connected to the liver by connective tissue of the liver capsule. At

one extreme variation, the gallbladder may be almost completely buried within the liver surface, having no peritoneal covering (intraparenchymal pattern); or it may hang from a short mesentery formed by the two layers of peritoneum separated only by connective tissue and a few small vessels (mesenteric pattern) in about 4%. The gallbladder consists of a fundus, body, infundibulum and neck. The neck lies at the medial end close to the porta hepatis, and almost always has a short peritoneal covered attachment to the liver (mesentery); this mesentery usually contains the cystic artery. The mucosa at the medial end of the neck forms oblique ridges, forming a spiral groove called spiral valve of Heister, continuous with the spiral valve of the cystic duct. At its lateral end the neck widens out to form the body of the gallbladder and this widening is called 'Hartmann's pouch'. The neck is 'S' shaped and lies in the free border of the lesser omentum anterior to the second part of the duodenum. It narrows to form the cystic duct.

The body of the gallbladder normally lies in contact with the inferior liver surface in the fossa. It lies anterior to the second part of the duodenum and the right end of the transverse colon. The fundus lies at the lateral end of the body and usually projects beyond the inferior border of the liver, in contact with the anterior abdominal wall behind the ninth costal cartilage where the lateral edge of the right rectus abdominis crosses the costal margin. The fundus commonly lies adjacent to the transverse colon.^{14,15}

A gall bladder deformity seen in 2-6% of individuals is the Phrygian cap where the fundus is folded back on the body of the gall bladder.^{14,15}

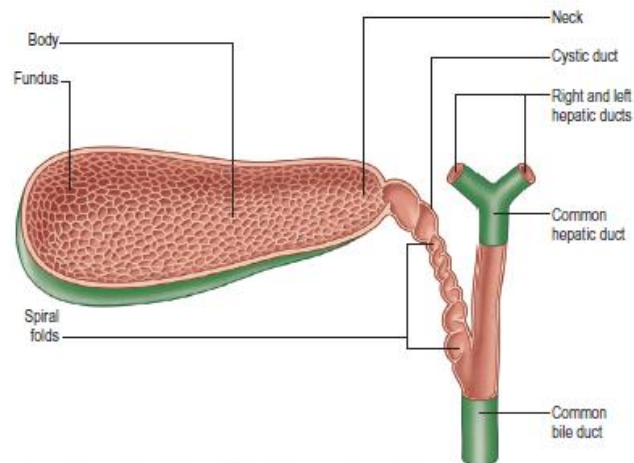


Figure 3: Gall bladder and bile ducts

The cystic duct drains the gallbladder into the common bile duct. It is 2-4 cm long, 3mm in diameter and passes posteriorly to the left from the neck of the gallbladder, and joins the common hepatic duct to form the common bile duct. It almost always runs parallel to, and is adherent to, the common hepatic duct for a short distance before joining it. In most individuals, the cystic duct joins the middle third of the combined lengths of the common hepatic and common bile ducts. The mucosa of the cystic duct bears 5-12 crescentic folds, continuous with those in the neck of the gallbladder. They appear to form a spiral valve when the duct is cut in longitudinal section. When the duct is distended, the spaces between the folds dilate and externally it appears twisted like the neck of the gallbladder.^{14,15}

Vatiations in Anatomy

In most individuals, the cystic duct joins the middle third of the combined lengths of the common hepatic and common bile ducts. In others, it may drain into the distal common bile duct, proximal common hepatic duct or right hepatic duct. The cystic duct usually joins the right lateral aspect of the common hepatic duct at an

angle. This junction may also occur medially, anteriorly or posteriorly. The cystic duct can also spiral around the common hepatic duct, run parallel to it for a variable distance before merging with it. The cystic duct can also be double, short or absent and can drain directly into the bile duct. It can also receive an anomalous hepatic duct from the segment V of liver.^{14,15}

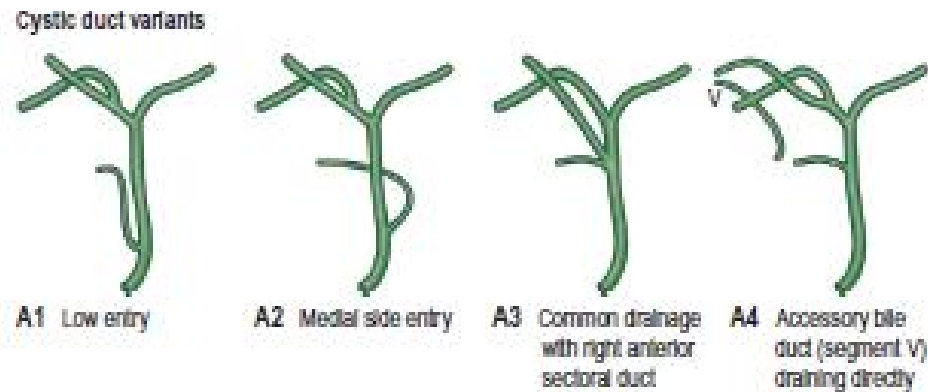


Figure 4: Cystic duct variations¹⁴

The gall bladder may be duplicated with or without a duplication of cystic duct, absent, have internal septation or be ectopically located.

Triangle of Calot and Rouviere's Sulcus

The calot triangle is the region bounded by the cystic duct, common (or right) hepatic duct, and inferior border of the liver. The triangle that helps to frame and identify the cystic artery that lies within it. Recognition of critical structures and dissection within Calot's triangle is of great importance during cholecystectomy, especially at the apex of the triangle. The apex of the triangle contains the cystic artery, as well as the right branch of the hepatic artery, 95% of accessory right hepatic arteries, and 90% of accessory bile ducts.¹⁶

Bile duct injuries during cholecystectomy most frequently occur due to poor exposure of Calot's triangle, causing confusion between the common hepatic or common bile duct and the cystic duct. Similarly, vascular injuries and significant bleeding that can obscure the dissection can occur if the exposure of this anatomy is inadequate.¹⁶

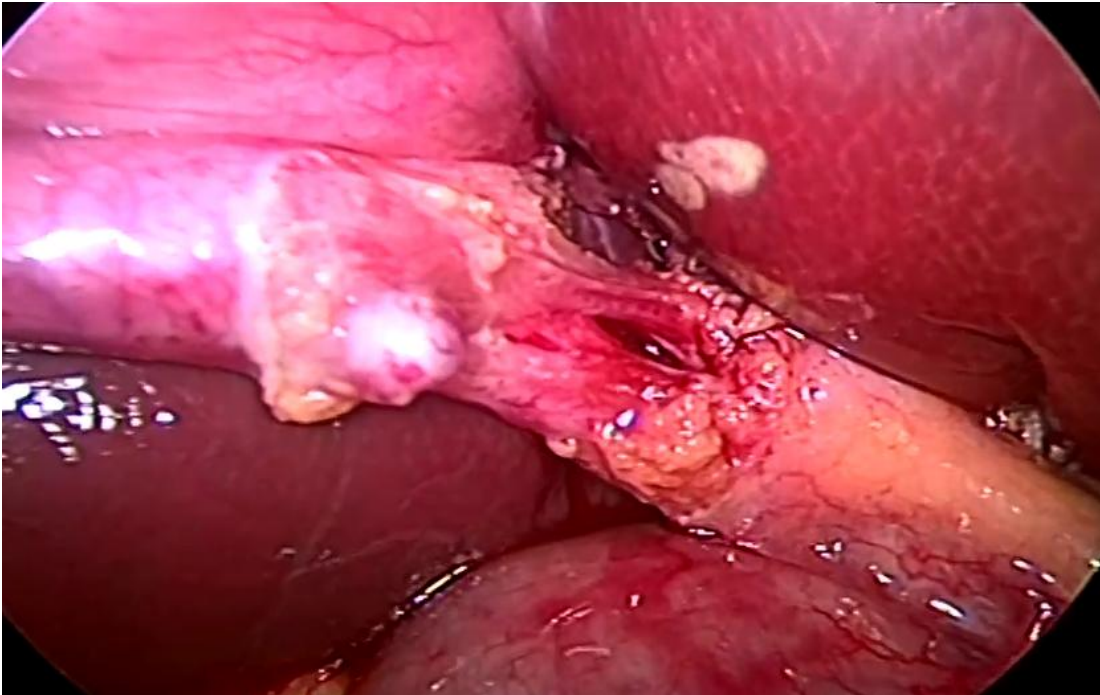


Figure 5: Triangle of Calot- Laparoscopic View

Another landmark in this region to help identify the plane of the common bile duct and to avoid injuries during cholecystectomy is Rouviere's sulcus, identified by Rouviere in 1924. It is a 2- to 5-cm sulcus lying anterior to the caudate lobe and running to the right of the liver hilum and usually containing the right portal triad. This sulcus is identifiable in approximately 75% of patients and accurately identifies the plane of the common bile duct.¹⁶

Identification of the sulcus requires anterosuperior and leftward retraction of the neck of the gallbladder with exposure and dissection of the posterior hepatobiliary triangle bounded by the neck of the gallbladder, the liver surface, and the plane of the sulcus. Dissection maintained ventral to the plane of the common bile duct, with care taken to identify a possible posterior cystic artery branch or tortuous hepatic artery, is safe even with tenting of the common bile duct.^{16,17}

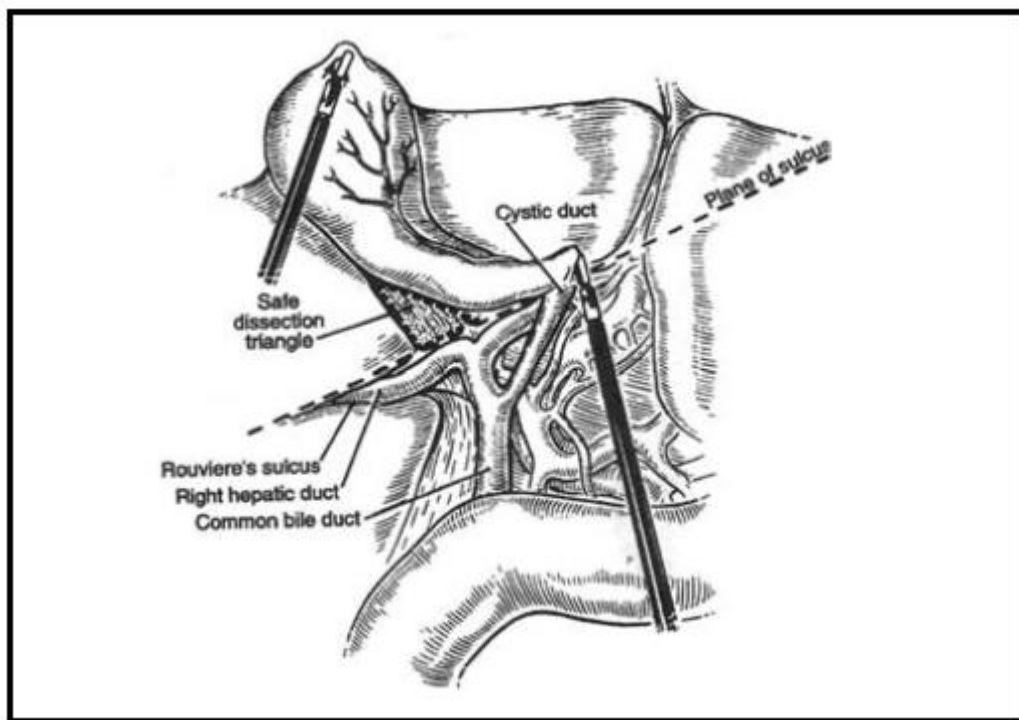


Figure 6: Rouviere's Sulcus¹⁷

THE CRITICAL VIEW OF SAFETY

Laparoscopic cholecystectomy is associated with a sharp increase in major bile duct injuries. The classical injury is the common bile duct is thought to be the cystic duct and is divided. Aberrant hepatic ducts may also be mistakenly identified as the cystic duct or cystic artery. The Critical View of Safety (CVS) is a method of target identification, the targets being the cystic duct and the cystic artery.¹⁸ It is accepted as a good means of identification of the cystic structures. In this technique, the first requirement is that the lower one-third of the gallbladder is separated from the cystic plate. The other requirements, is that the hepatocystic triangle be cleared of fat and fibrous tissue and only 2 structures, cystic duct and cystic artery remain attached to the gallbladder. Intraoperatively, CVS should be confirmed in which the 3 elements of CVS are demonstrated.^{19,20}

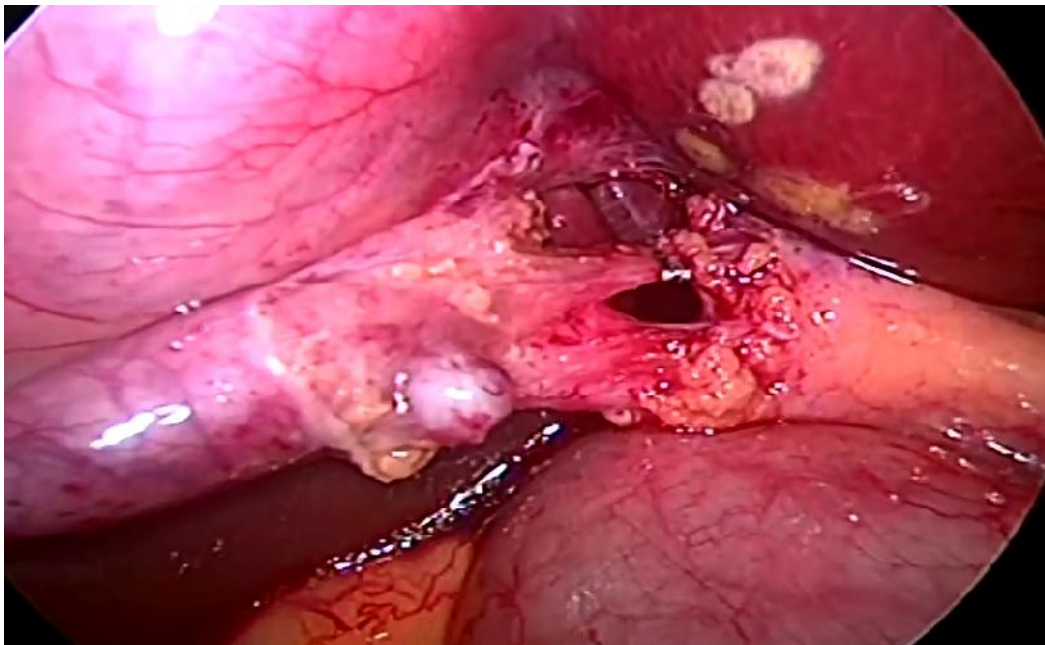


Figure 7: Critical View of Safety

INDICATIONS FOR LAPAROSCOPIC CHOLECYSTECTOMY²¹

- Symptomatic cholelithiasis (biliary colic, acute cholecystitis)
- Choledocholithiasis with gall stone pancreatitis or cholangitis/obstructive jaundice
- Asymptomatic cholelithiasis due to sickle cell disease, Total parental nutrition, chronic immunosuppression, no immediate access to healthcare, incidental cholecystectomy in patients undergoing other surgical procedures
- Acalculous cholecystitis
- Gall bladder polyps more than 10mm in size
- Porcelain gall bladder

CONTRAINDICATIONS TO LAPAROSCOPIC CHOLECYSTECTOMY

- Absolute- unable to tolerate general anesthesia, refractory coagulopathy, suspicion of gall bladder carcinoma
- Relative- previous upper abdominal surgery, cholangitis, diffuse peritonitis with hemodynamic compromise, cirrhosis/ portal hypertension, chronic obstructive pulmonary disease, cholecystoenteric fistula, morbid obesity, pregnancy.²¹

CONVERSION TO OPEN PROCEDURE

Conversion to open procedure is a judgement call and should not be seen as a complication. Indications include unclear anatomy that requires tactile feedback only manual palpation can achieve in the setting of inflammation, adhesions, anomalies, hemorrhage, bile duct injury, fistulae between biliary system and bowel, gall bladder carcinoma and CBD stones that cannot be extracted laparoscopically or even endoscopically.²¹

COMPLICATIONS OF LAPAROSCOPIC CHOLECYSTECTOMY

Complications can arise related to the procedure of laparoscopic removal of the gall bladder itself as in the open procedure and due to the pneumoperitoneum created and the insertion of trocars. The complications of the procedure itself include hemorrhage, bile duct injury, bile leak, retained stones, pancreatitis, wound infections and incisional hernias. Pneumoperitoneum related injuries include carbon dioxide embolism, vaso-vagal reflex, cardiac arrhythmias and hypercarbic acidosis. The insertion of trocars can cause abdominal wall bleeding and hematoma, visceral injury and vascular injury.

Surgeons experience with the procedure is said to be the only significant factor associated with an adverse outcome.^{21,22}

Of all the potential complications, biliary injury is most widely attended to. Studies quote a major bile duct injury of around 0.2% in open cholecystectomy and the incidence of bile duct injury in laparoscopic cholecystectomy is said to be 0.40% or higher. The classic biliary injury occurs when CBD or RHD is misidentified as cystic duct and divided after clipping.^{22,23}

OPEN CHOLECYSTECTOMY

A right-sided subcostal (Kocher) incision provides the optimum exposure. The incision should be of sufficient size to provide adequate exposure of the gall bladder and hepatoduodenal ligament and to admit the examining hand. Laparotomy sponges may be placed between the liver and the dome of the diaphragm, on the right to retract the hepatic flexure of the colon inferiorly, and on the left to displace the stomach and the medial segment of the left lobe superiorly. Adhesions of the gall bladder to the

omentum, transverse colon may be divided using sharp dissection or electrocautery. If the gallbladder is distended, decompression facilitates removal.²¹

The fundus and the infundibulum are grasped with clamps. The fundus is retracted superiorly and anteriorly, the infundibulum retracted inferiorly and laterally away from the cystic duct, opening up the calot's triangle.²¹

The peritoneum overlying the Calot's triangle is incised and the dissection is continued close to the gallbladder, displacing the cystic node and the fatty, areolar tissues to expose the cystic duct and artery. The cystic artery is identified and traced onto the surface of the gallbladder to confirm that it is not the right hepatic artery. The artery is doubly ligated as close to the gall bladder surface and divided between the tied ligatures. The cystic duct is identified by blunt dissection, doubly ligated and divided. It is not necessary that it be ligated flush with the bile duct.²¹

Dissection of the gallbladder from the liver is then performed from the fundus down by entering the submucosal plane. Dissection within the correct plane can be facilitated by incising the peritoneum over a right-angled clamp using electrocautery. By displacing the gallbladder from side to side, the attachments between the gallbladder and liver can be exposed and incised. The dissection is continued down until the peritoneal incision over the gallbladder is continuous with that made previously over Calot's triangle. In a diseased, thick-walled, or fibrotic gallbladder, care should be taken not to enter the cystic plate as dissection deep to this structure risks injury to the right portal pedicle and the right hepatic duct. The procedure may be limited to a subtotal cholecystectomy. Any bleeding from the gallbladder bed in the liver is managed by electrocautery once the gallbladder is fully mobilized.²¹

LAPAROSCOPIC CHOLECYSTECTOMY

Two video monitors are used on each side of the operating table one for the operating surgeon and one for the assistant. The surgeon stands to the left of the patient, the assistant to the right and the camera to the left of the surgeon. Pneumoperitoneum is created either with the open technique or closed technique with a veress needle. A 30 degree laparoscope is preferred to gain multiple views of the operative field.

A 10mm laparoscope is inserted through the periumbilical port. The patient is placed in a reverse trendelenberg position with right side tilted upwards to facilitate the colon and bowel to shift away from the operating field. The gall bladder is visualised protruding beyond the lower border of the liver. A 10mm port is placed in the midline in the epigastric region about 5cm below the xiphoid process. Additionally two accessory 5mm ports are placed in the subcostal region in the midclavicular line and the anterior axillary line. The gall bladder is grasped with forceps placed through these two 5mm ports. The assistant uses the lateral grasping forceps to hold the fundus and elevate the gall bladder with the liver. The fundus of the gall bladder is elevated in cephalad and lateral direction thus rolling up the entire right lobe cranially. Dissecting forceps is inserted through the epigastric port.

The infundibulum is grasped and lateral traction is given to distract the cystic duct away from the CBD. Maryland forceps is used to dissect the overlying peritoneal covering and the fibroareolar tissue from the infundibulum. The initial dissection frees the lower one third of the gall bladder from the liver bed. The hepatocystic triangle is opened by retracting the infundibulum inferiorly and laterally. The lymphnode if found is dissected away from the artery. The junction between the infundibulum and

the cystic duct is dissected from the surrounding areolar/ neurovascular/ peritoneal tissues to visualise a clear segment. A window is created around the posterior aspect of the cystic duct. The dissection need not be done till the junction of the cystic duct with the CBD to avoid potential injury. The cystic artery is bluntly dissected from the surrounding structures. At the end of dissection, the critical view of safety should be achieved visualising only two structures (the cystic artery and duct). The duct is clipped using clip applicator, two placed proximally and one placed toward the gall bladder end and divided. The cystic artery is clipped proximally and distally and divided. The stumps are checked for leaks.

The gall bladder is now dissected from the hepatic bed using an electrocautery (hook or spatula) maintaining cephalad traction with the axillary forceps and manipulating the neck to expose the tissue between the gall bladder and the liver. The dissection is done from the infundibulum to the fundus and the gall bladder is separated. Liver bed is examined for bleeding points and bile leak and coagulated.

The gall bladder is placed in an entrapment sac and extracted using “claw” grasping forceps either from the umbilical port or epigastric port. If the specimen is large due to heavy stone burden, the incision (preferably umbilical) can be extended or the gall bladder contents can be aspirated through an incision in the neck to decompress it or stone stone forceps can be placed to extract/ crush calculi.

The fascia of the umbilical incision is closed with absorbable sutures. The epigastric incision need not be closed. Skin is sutured.²¹

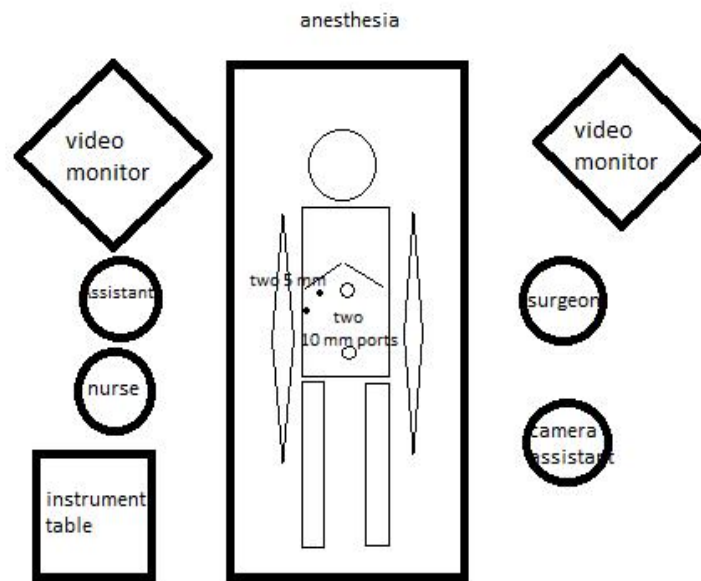


Figure 8: Conventional Laparoscopic Cholecystectomy Setup

PAIN AFTER LAPAROSCOPIC CHOLECYSTECTOMY

Pain is the most common complaint after laparoscopic cholecystectomy and is the main reason for overnight stay at the hospital on the day of surgery.²⁴ Pain after laparoscopic cholecystectomy is multi factorial and includes rupture of blood vessels due to rapid distension of the peritoneum, traction on the nerves, trauma to the abdominal wall during port insertion and gall bladder retrieval and pneumoperitoneum created by using CO₂ to maintain high abdominal pressure.²⁵ Incisional pain has been reported to be more intense than visceral pain and is dominant during the first 48 h after laparoscopic cholecystectomy.²⁶ Pain reaches its peak in the first few hours following surgery, and diminishes in the next 2 or 3 days. Three types of pain have been described i.e. visceral, parietal and shoulder tip pain, with different intensity and time. Visceral and parietal pain is the most important during first 24–48 h after surgery. The main sources of pain are: incision sites within the abdominal wall; the pneumoperitoneum in association with both local (peritoneal and diaphragmatic stretching, acidosis and ischemia) and systemic (hypercarbia causing sympathetic nervous system excitation with an amplification of local tissue inflammatory response) changes; and the “postcholecystectomy wound” within the liver (visceral pain). The largest component (50–70%) arises from incisional sites, followed by the pneumoperitoneum (20–30%) and “cholecystectomy wound” (10–20%). Some dynamic conditions such as coughing and mobilization can further aggravate the pain.²⁷

The visual analogue scale (VAS) is commonly used to measure the intensity of pain for comparison in studies. It is a 100-mm horizontal line on which the patient’s pain intensity is represented by a point between the extremes of “no pain at all” and

“worst pain imaginable.” Its simplicity, reliability, and validity, as well as its ratio scale properties, make the VAS the optimal tool for describing pain severity or intensity. If descriptions like ‘mild’, ‘moderate’, ‘severe’ or a numerical scale is added to the VAS, it is called as Graphic Rating Scale (GRS).²⁸

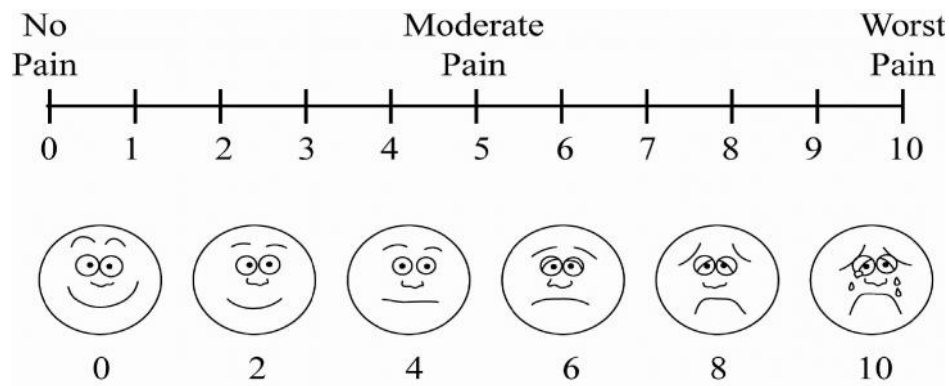


Figure 9: Visual Analogue Scale

NEWER TECHNIQUES IN LAPAROSCOPIC CHOLECYSTECTOMY

The surgeon's desire to explore new avenues and the patient's desire for cosmesis and less post operative pain along with newer emerging technologies has lead to numerous modifications of the same procedure with different techniques of access. The four port laparoscopic cholecystectomy has become the standard of care for gall bladder disease over the last two decades. From the conventional four port surgery, it is advancing to two and single port surgery.¹⁰ Surgery through natural orifices is a new surgical technique in its development. The potential advantage is in it's absence/further concealment of scars and reduced pain and discomfort. The most natural point of access for surgeons is already existing scars, such as the naval, to introduce the instruments that facilitate laparoscopic procedures.¹⁰ This approach was first used by Navarra et al. in 1997 in a laparoscopic cholecystectomy using two periumbilical incisions that were later joined to remove the gallbladder²⁹. Although

Single incision laparoscopic surgery (SILS) is not a revolutionary concept as was laparoscopy initially, it is being evaluated and adopted.¹⁰ The several described techniques of SILS depend on the number of trocars used, there being 2, 3, or 4 trocar techniques. As the number of instruments increase, the retraction and flexibility in instrumentation is better but the conflicts increase. Retraction instruments are replaced with sutures or hooks or magnets. The procedure can be performed with multiple separate trocars or commercially available multiport devices such as TriPort, AirSeal, SILS port that are expensive or to save costs, innovative ideas like the use of glove and retractor.^{10,30} The main advantages were a better cosmetic outcome with or without reduced post-operative pain. Disadvantages include concerns of higher costs, loss of triangulation as all the instruments are introduced through the same port, a longer learning curve, longer operating time and it's doubtful benefits.¹⁰ There are several published reports of single incision laparoscopic cholecystectomy where multiple ports are placed through a single umbilical incision and are compared to the standard cholecystectomy.^{31,32}

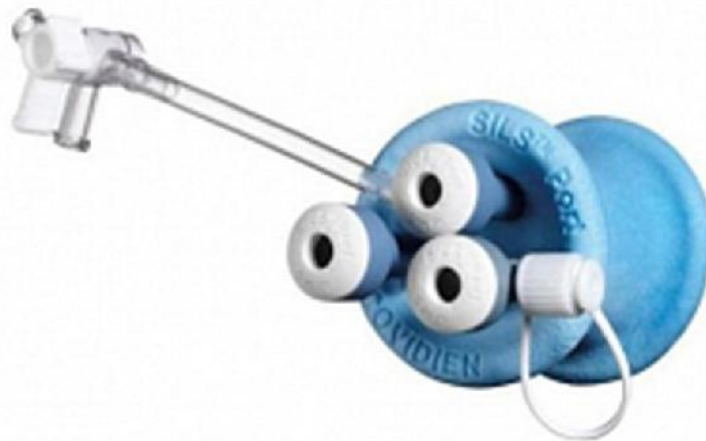

Figure 10: SILS Port

In natural orifice transluminal endoscopic surgery (NOTES), the goal is to perform intraperitoneal operations safely through a natural orifice obviating the need for skin incisions. This reduces surgical pain, decrease anesthesia and analgesia, shorten recovery time, avoid hernia formation and adhesions, and eliminate any surgical site infection and visible scarring. This technique involves breaching the wall of the stomach, colon, vagina or bladder by endoscopic means to gain access into the peritoneum. NOTES can be 'pure' or 'true' or 'totally' where the procedure is done only with transluminally placed flexible or rigid tools without laparoscopic assistance. 'Hybrid' NOTES uses laparoscopic transabdominal assistance for entry, dissection, retraction or closure. Several NOTES surgery has been performed even on humans, such as transvaginal cholecystectomy.^{10,33}

The evolution of modes of access reflects the desire to cause minimal trauma to the patient thereby minimising post operative pain and improving cosmesis. Techniques such as percutaneous retraction sutures are used to minimize instrumentation. The "Pick and Fix" Suture is one such method. It involves a simple pass of the suture (with a needle) through the body wall (transabdominal or transthoracic), the organ of interest (gall bladder, mesoappendix, large bowel, gubernaculum of testis etc) and out through the wall again. Tagging the two ends with an artery forceps allowed traction to be applied to facilitate dissection.^{34,35}

To facilitate adequate visualisation in laparoscopic cholecystectomy, studies have mentioned the utilization of the cystic plate for safe and steady retraction of the liver before and after the removal of the gall bladder. The cystic plate is a tough fibrous connective tissue between the gall bladder wall and the liver surface and prevents injury to the liver parenchyma during retraction. Retraction is done at this

point either using blunt instruments or by retracting sutures passed at the junction of the fundus of the gall bladder and liver. We have utilized similar principles in our study to achieve adequate visualisation and retraction with the help of transcutaneous sutures.^{36,37}

Several modifications of the standard 4 port laparoscopic cholecystectomy have been attempted, all of them designed to achieve smaller and lesser wounds by decreasing the size and/or number of ports penetrating the abdominal wall to decrease post operative pain, improve cosmesis and hasten recovery. However in some studies, these modified techniques have been reported to have increased level of difficulty. There have been multiple studies conducted comparing three port laparoscopic cholecystectomy and the standard four port cholecystectomy all of which challenged the usefulness of the fourth lateral trocar at the anterior axillary line thus being able to effectively reduce the number of ports used for the procedure.³⁸ Dhafir Al-Azawi et al compared the safety and advantages of the three port technique in acute and chronic cholecystitis retrospectively. They concluded that the three port laparoscopic technique was safe in both acute and chronic cholecystitis with a decrease in postoperative pain and hospital stay, equivalent operative time and no differences in the conversion rates and postoperative complications between the three and four port techniques.³⁹

Burhan Mayir et al also in his study concluded that three port laparoscopic cholecystectomy was safe and feasible with similar operative times and that laparoscopic cholecystectomy can be attempted with three ports initially with the forth port inserted only if required.⁴⁰

In a randomized control trial by Manoj Kumar et al, they concluded that early postoperative pain was less in the three port group. The mean postoperative time was

shorter in the three port group explained by less time taken to establish and close the port. Although there was a finding of difficulty in handling longer gallbladders, it was concluded that the three port procedure was safe with no increase in biliary injuries and can be a viable alternative in laparoscopic cholecystectomy.⁴

Heng Hui Lien et al retrospectively analysed the effectiveness of the two-, three-, and four port methods of cholecystectomy for its feasibility and effectiveness on the basis of operation time, post surgery stay and pain score. They concluded that the standard 4 port technique is the procedure of choice for acute surgery and the operative time increased as the number of ports decreased. The pain score was less for the three port technique.⁴¹

In an article on scarless cholecystectomy by Ali Aminian et al using standard laparoscopic instruments, two ports were inserted through supra and infraumbilical incision and two traction sutures are passed to retract the gall bladder and liver. It concluded that this modified approach was feasible and safe with good cosmetic result.⁴²

In a study conducted by Ranendra et al, two port and three port laparoscopic cholecystectomy were compared. In the three port technique, two 10mm and one 5mm port was used along with a suture passed for retraction of the fundus. In the two port technique, two 10mm ports and two sutures were passed for fundus retraction and lateral traction. Post operative pain, cosmesis and operative time were assessed. It was concluded that as compared to three port laparoscopic cholecystectomy, two port cholecystectomy is technically safe and feasible and has better patient satisfaction.⁴³

Poon et al. in his randomised study comparing four-port and two-port laparoscopic cholecystectomy found that two-port technique involved less operative time, less port-site pain with fewer surgical scars.⁶

In a study conducted by Mushtaq Chalkoo et al on 50 cases of gallstone disease, a modified technique of three port laparoscopic cholecystectomy was done where a 10mm port is inserted at the umbilicus, 5mm port also at the umbilicus and a 10mm port at the epigastric region thus concealing three ports in two incisions and thereby assessing its feasibility and safety. The concealed port helps in retraction of the gall bladder during dissection of calot's triangle. The advantages in this technique was claimed that both the hands of the surgeon lie on the same plane and do not cross the body of the surgeon making it easier to manoeuvre and avoiding the use of transcutaneous sutures. Only two cases required the addition of an extra port for retraction of long gall bladders.⁴⁴

In our study, we have developed a similar technique of reduced port laparoscopic cholecystectomy using three working ports placed through two incisions using standard laparoscopic instruments. Hence the aim of concealing the third port in the same umbilical incision and thereby reducing the total number of incisions from four in the conventional laparoscopic cholecystectomy and only two in our modified procedure- two incision three port laparoscopic cholecystectomy. We have also incorporated the use of transabdominal retraction sutures to help in retraction of the gall bladder for better and safe dissection of the triangle of calot. The proposed advantages of this procedure being the easy availability and familiarity with the instruments, avoiding added costs of special instruments or ports and the added advantage of concealing the third port in the same incision.

METHODOLOGY

This study was conducted among patients admitted and willing for elective laparoscopic cholecystectomy in the department of general surgery at K.L.E.S Dr. Prabhakar Kore Hospital and Medical Research Centre, Belagavi from January 2017 to December 2017.

Study design

The study design was a randomized controlled trial. The present study was carried out for a period of one year from January 2017 to December 2017

Place

This study was done in the Department of General Surgery, K.L.E.S Dr. Prabhakar Kore Hospital and Medical Research Centre, Belagavi a tertiary care teaching hospital attached to KLE University's Jawaharlal Nehru Medical College, Belagavi.

Source of Data

Patients scheduled for elective laparoscopic cholecystectomy were included in the study.

Sample size

Calculated using the formula

$$N = 2(z_1 + z_2)^2 (s_1^2 + s_2^2) / (x_1 - x_2)^2$$

$$Z_1 = 1.96 \quad S_1 = 1.06 \quad X_1 = 2.19 \quad \alpha = 0.05$$

$$Z_2 = 0.84 \quad S_2 = 1.2 \quad X_2 = 2.91 \quad \beta = 0.2$$

As per the calculation, sample size was 40 in each group with Group A (two incisions three ports laparoscopic cholecystectomy) and Group B (four port laparoscopic cholecystectomy)

Sampling method

Every patient who fulfills the inclusion criteria was included in the study. The sealed envelope method was used to assign patients to each group.

Selection Criteria

Inclusion Criteria

Patients aged 18 years and above who were indicated for elective laparoscopic cholecystectomy.

Exclusion Criteria

Patients with acute cholecystitis and empyema gallbladder, choledocholithiasis and patients who were not fit for laparoscopic surgery on anesthetic grounds.

Ethical clearance

The Ethical Clearance was obtained from the Institutional Ethics Committee, Jawaharlal Nehru Medical College, Belagavi prior to the commencement.

Informed Consent (Annexure I)

Those patients who fulfilled selection criteria were briefed about the nature of study and the laparoscopic procedures. The patients who were not willing for the study and control groups were excluded.

Method of collection of data

Patients satisfying the selection criteria were interviewed and the demographic data such as age and sex, presenting complaints were noted. The patients underwent clinical and systemic examination and the findings were recorded on a predesigned and pretested proforma (Annexure II).

Randomization

Patients who were undergoing laparoscopic cholecystectomy were enrolled for this study. Those patients who were not willing for the study were excluded. Totally 61 cases were included. Patients were randomly assigned to one of the two groups as below.

Group A (two incisions three port laparoscopic cholecystectomy):22 patients

Group B (four port laparoscopic cholecystectomy):39 patients

After randomization, the patient was assigned to Group A or B, consent for the proposed procedure taken and the same was informed to the operating surgeon and the procedure was done. Over the course of the given time period of 1 year, in group A, a total of 22 patients were willing to undergo the proposed procedure and 39 patients underwent the proposed procedure in group B. The patients who refused to give consent for either procedure were excluded. All the surgeries in both groups were done by a single operating surgeon in a single surgical unit.

Operative procedure

Under general anesthesia, the patient was placed in supine position. Nasogastric tube was inserted to decompress the stomach during the procedure, since

a distended stomach can obscure the operative field. It may be kept in place after the procedure. The urinary bladder was catheterised. Preparation and draping was done in a standard manner. The surgeon stood on the left side of the patient with the assistant holding the camera next to him. The monitor was placed on the right of the patient.

STANDARD FOUR PORT LAPAROSCOPIC CHOLECYSTECTOMY: Access to the peritoneal cavity and pneumoperitoneum creation is done either by closed technique using veress needle or by open hassan's technique. The initial access is through a supra umbilical/ infraumbilical or umbilical incision. Pneumoperitoneum is created. This is followed by insertion of a 10mm trocar. The intra-abdominal pressure is kept at 12-15mmHg. A 30 degree camera is introduced. The insufflated abdomen is inspected for sites of injury or bleeding, other intra-abdominal conditions and for feasibility of laparoscopic cholecystectomy. The remaining ports are then inserted under vision, the 10mm port at the epigastric region, 5mm ports at the mid clavicular line and anterior axillary line at the subcostal margin.

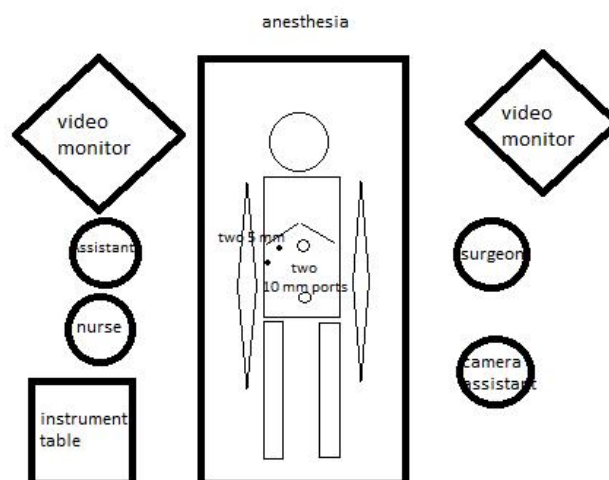


Figure 11: Standard Laparoscopic Cholecystectomy Setup

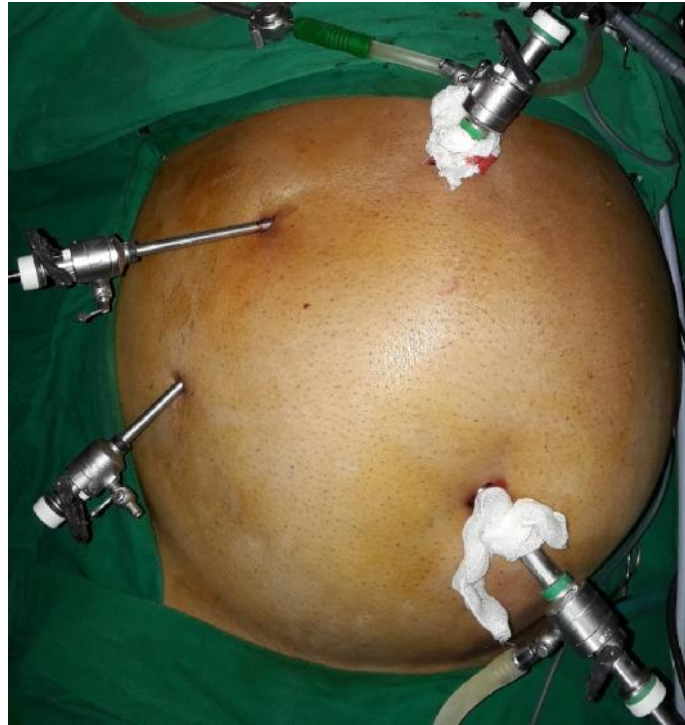


Figure 12: Port Placement in Standard Laparoscopic Cholecystectomy

Through the lateral most port, a grasper is introduced to hold the fundus of the gall bladder and retract it upwards and laterally toward the patients right shoulder. A second grasper is inserted through the midclavicular port to grasp the infundibulum and retract the gall bladder laterally and inferiorly to open up the cystic triangle. Maryland forceps is used to dissect the peritoneal covering and areolar tissue over the lower infundibulum and neck, towards the cystic duct. The cystic duct is freed from the surrounding tissue as is the cystic artery and a window is created thus achieving the critical view of safety. The cystic duct is clipped and divided. The cystic artery is clipped and divided. Traction is then applied on the gall bladder to separate the gall bladder from the liver bed using monopolar cautery from the infundibulum to the fundus. The gall bladder fossa is checked for hemostasis and bile leaks.

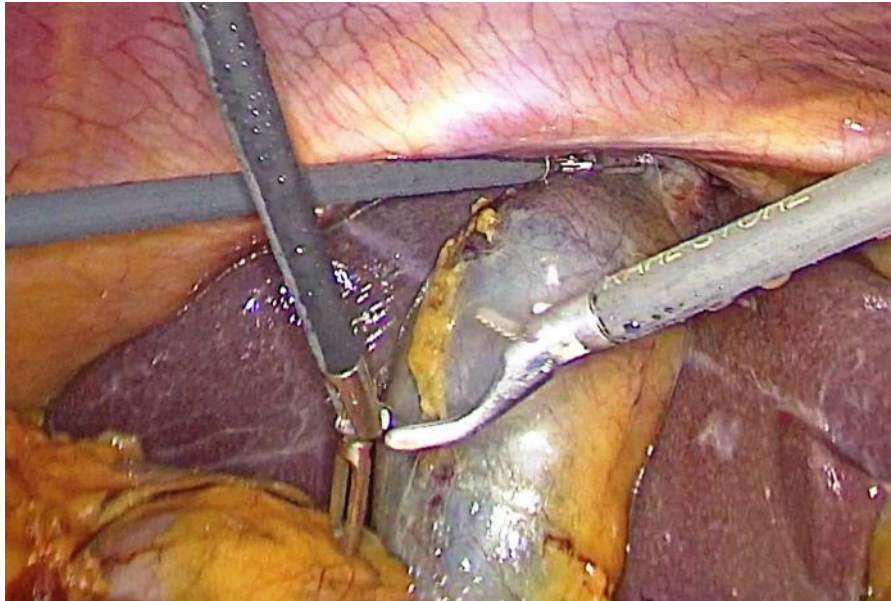


Figure 13: Four Port Laparoscopic Cholecystectomy

The specimen is then placed in an endobag and retrieved with claw forceps through the epigastric port. Pneumoperitoneum is evacuated. The fascia of the umbilical port is closed with absorbable polyglactin (vicryl) sutures. The skin is sutured with non absorbable nylon sutures. Sterile dressing is applied.

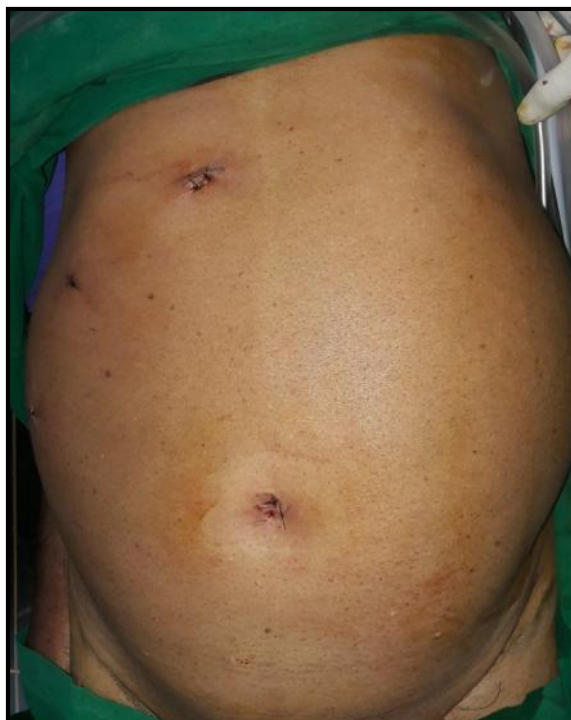

Figure 14: Four Ports After Closure

Once the patients are extubated, they are monitored during the post operative period.

TWO INCISIONS THREE PORT LAPAROSCOPIC CHOLECYSTECTOMY:

Access to the peritoneal cavity and pneumoperitoneum creation is done either by closed technique using veress needle or by open hassan's technique. The initial access is through a supra umbilical/ infraumbilical or umbilical 10mm incision. Pneumoperitoneum is created. Through the initial incision, 10mm trocar is inserted. A 30 degree camera is introduced. The same incision is extended for another 5 mm. A 5mm trocar is inserted thus creating two ports through one incision. The second 10mm incision is made in the epigastric region and a 10mm trocar is introduced. Thus, in this procedure there are three laparoscopic ports placed through two incisions. To facilitate retraction of the gall bladder cephalad and laterally, 2-0 prolene is introduced into the peritoneal cavity. The needle is passed through the cystic plate (thick fibrous tissue) at the junction of the fundus and the gall bladder fossa of the liver first, then through the uppermost anterolateral aspect of the right dome of diaphragm. Both ends of the suture are passed transcutaneously and brought out through the abdominal wall in the subcostal margin in the anterior axillary line using a suture passer. (figure 16-19)

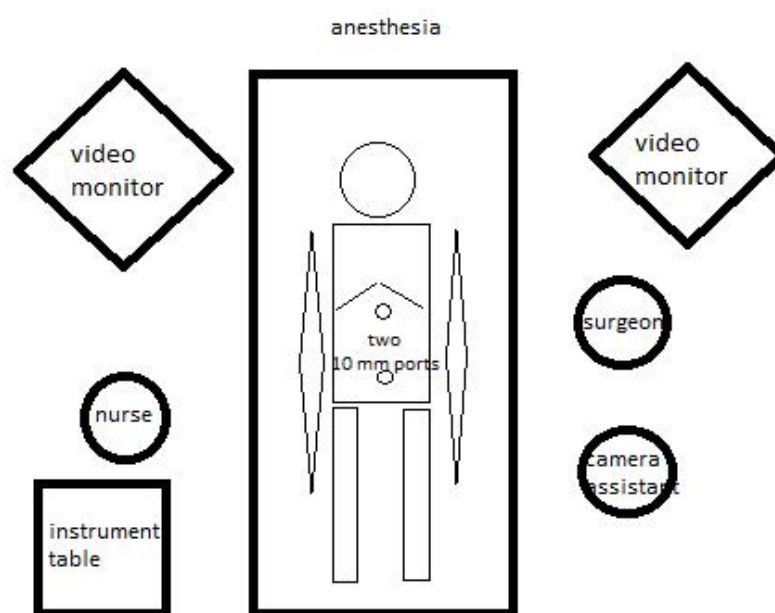


Figure 15: Two Incisions Three Ports Laparoscopic Cholecystectomy Setup

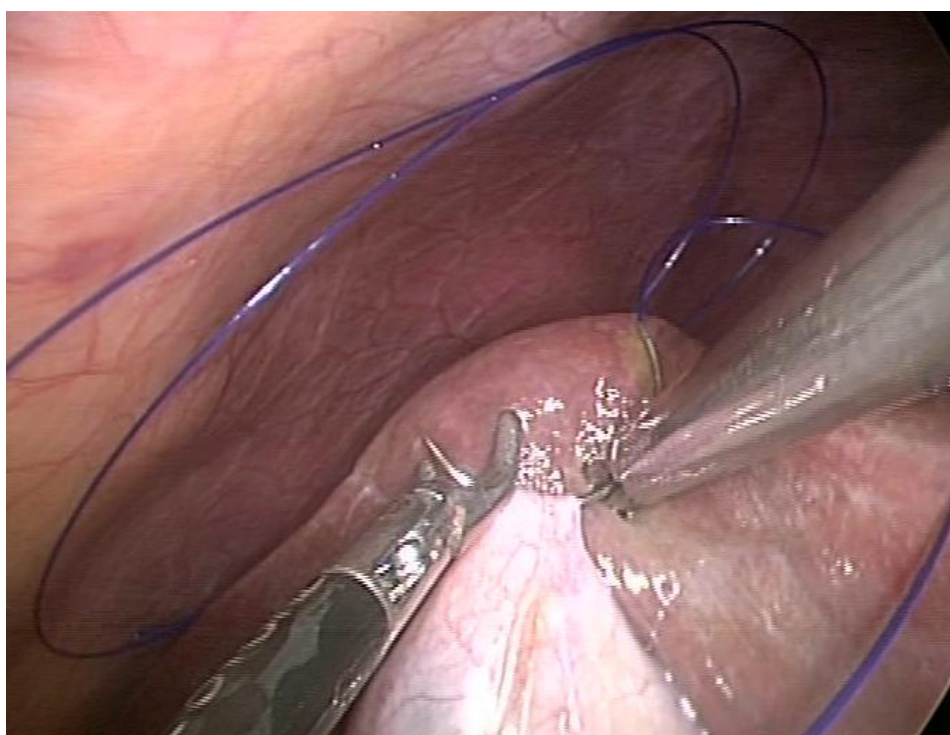

Figure 16: Suture passed through cystic plate

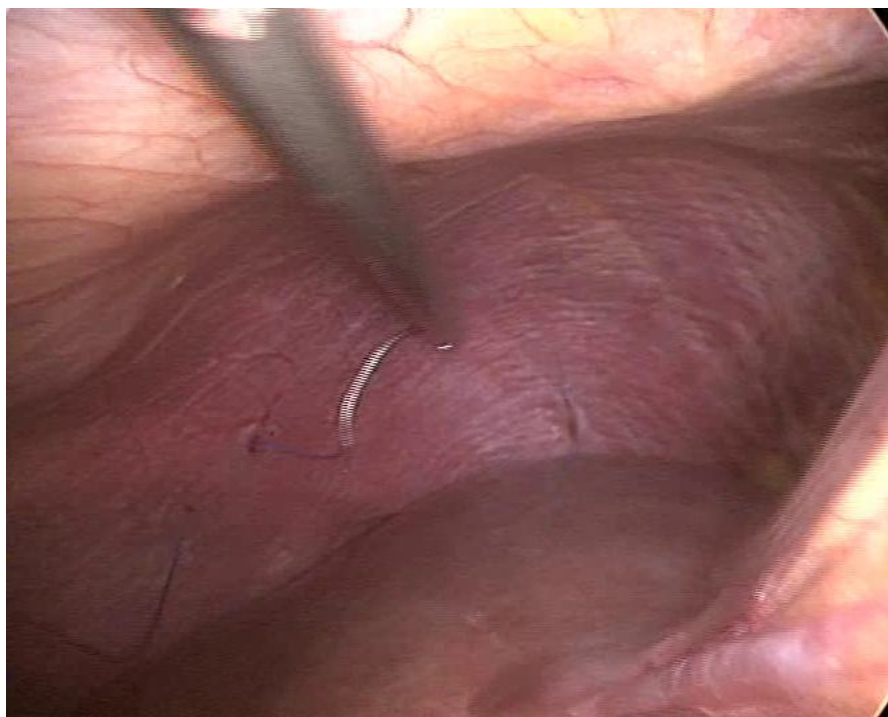


Figure 17: Suture passed through diaphragm

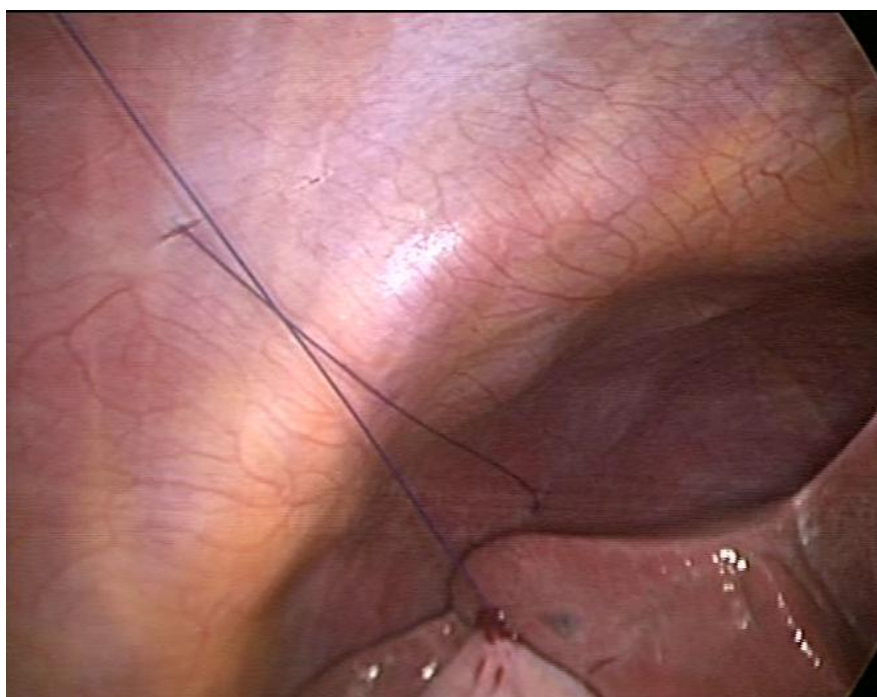


Figure 18: Suture taken transcutaneously

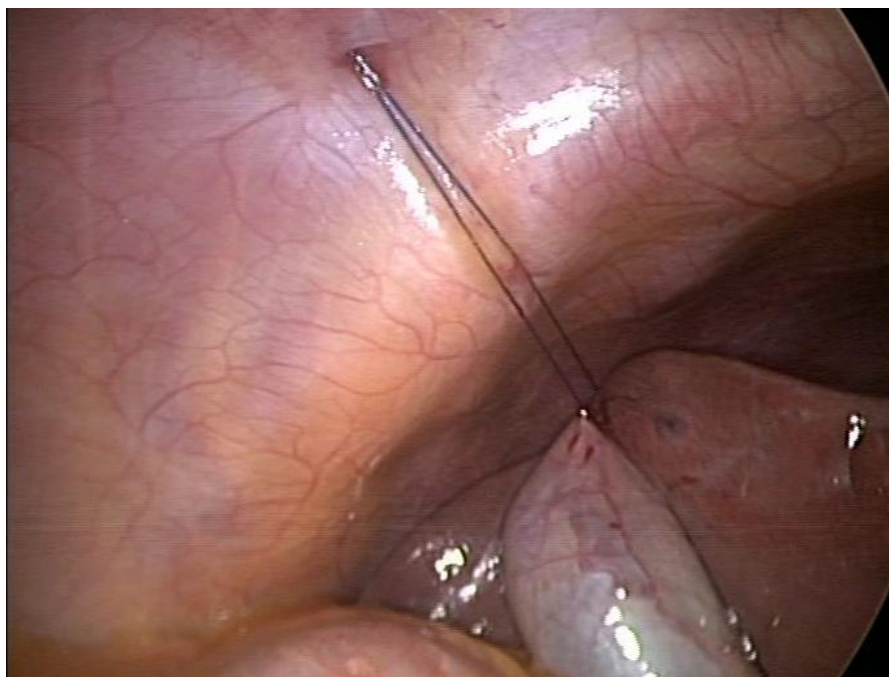

Figure 19: Suture retracts the gall bladder

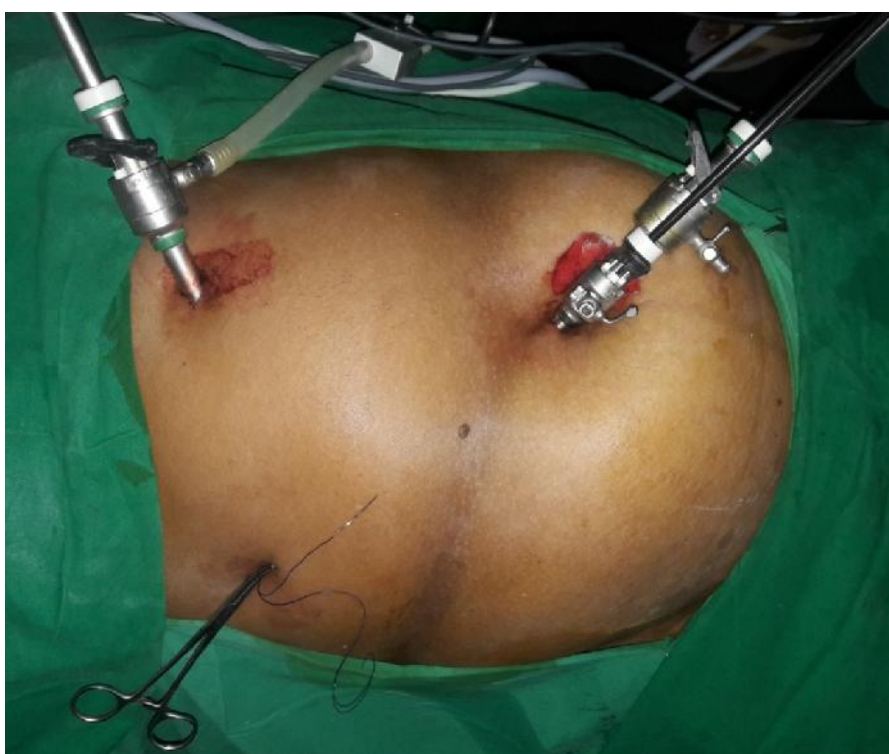

Figure 20: Port Placement in Two Incisions Three Ports Laparoscopic Cholecystectomy

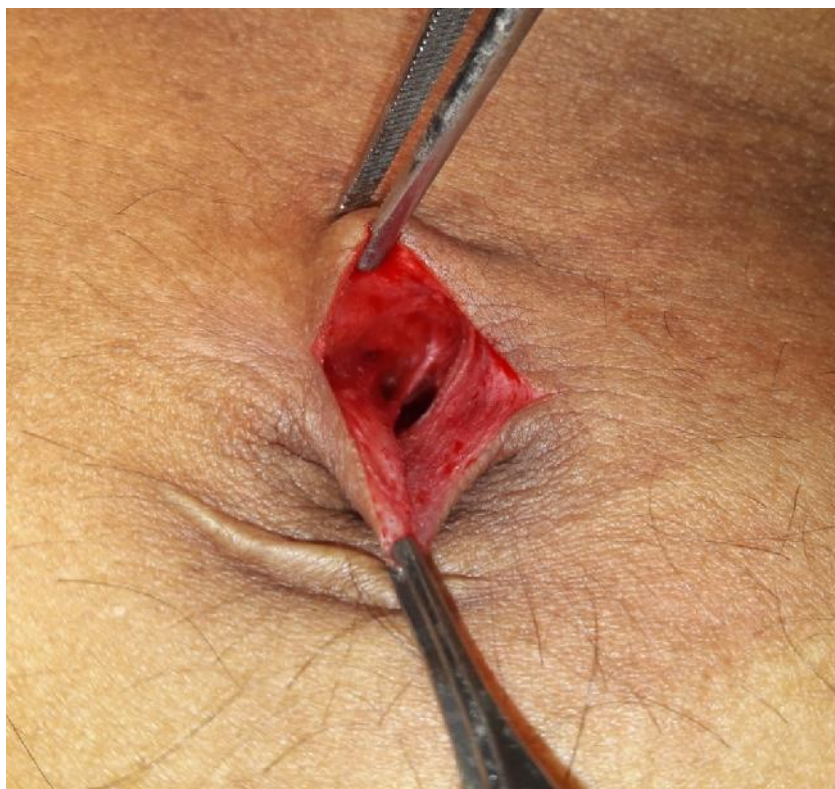


Figure 21: Umbilical Port Site Showing Two Ports in a Single Incision

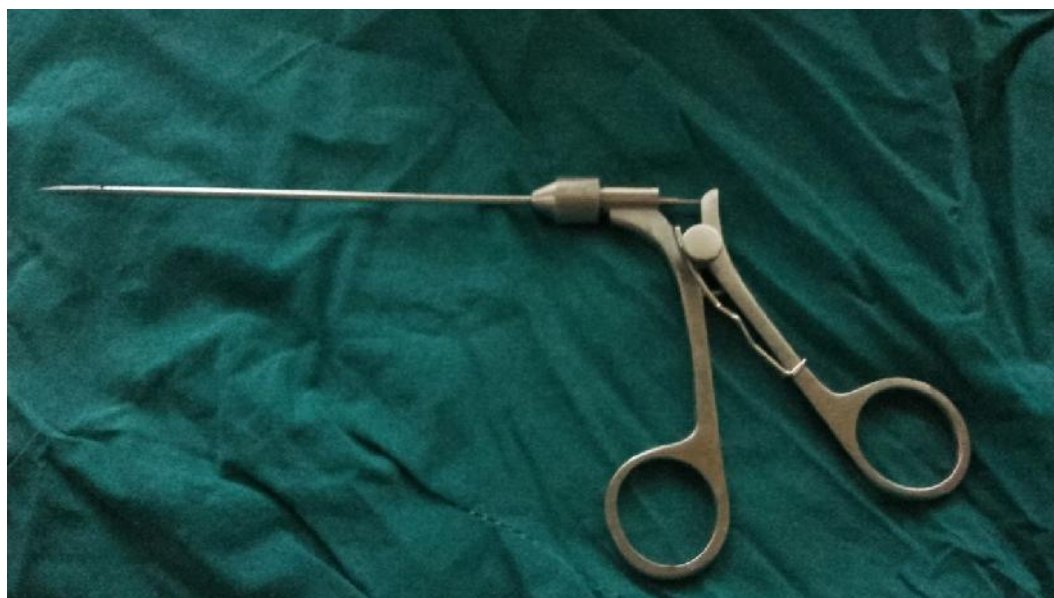

Figure 22: Suture Passer

Traction is placed on the suture to produce upward and lateral retraction of the fundus of the gall bladder and fixed with artery forceps. The infundibulum of the gall bladder is retracted inferiorly and laterally using the 5mm umbilical port. Further dissection of the cystic duct and artery is carried out with Maryland forceps from the epigastric port. Once the cystic duct and artery are clipped and divided, the gall bladder is dissected from the liver bed while maintaining the suture retraction. After the gall bladder is separated completely, the suture is removed. The gall bladder is retrieved through the epigastric port in an endobag. The liver bed is inspected for hemostasis. Pneumoperitoneum is evacuated and the ports removed. The umbilical port is closed with absorbable vicryl suture. The skin is sutured with nonabsorbable nylon. Sterile dressing is applied.

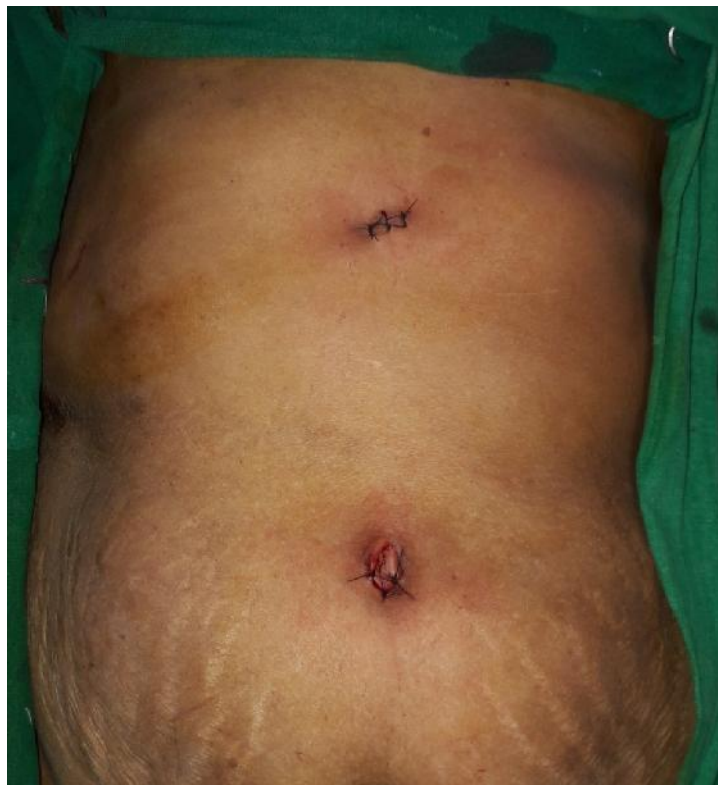

Figure 23: Two Incisions Three Ports- After Closure

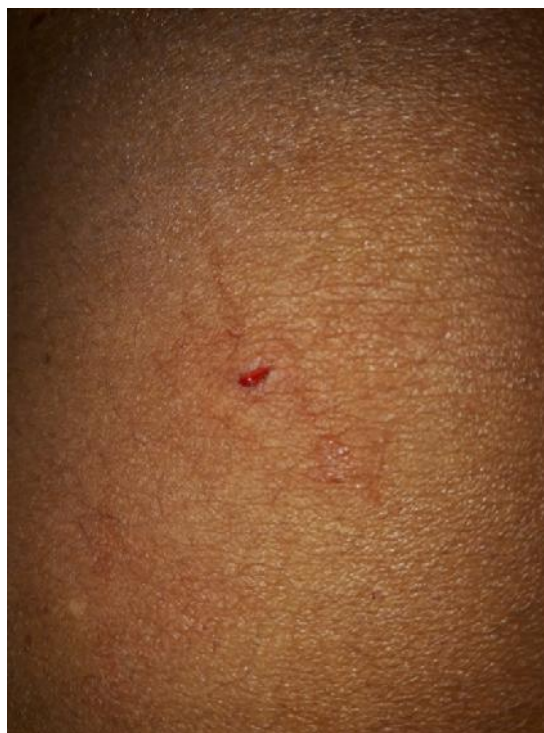

Figure 24: Wound after Passage of Transcutaneous Suture

The patient is extubated and monitored post-operatively.

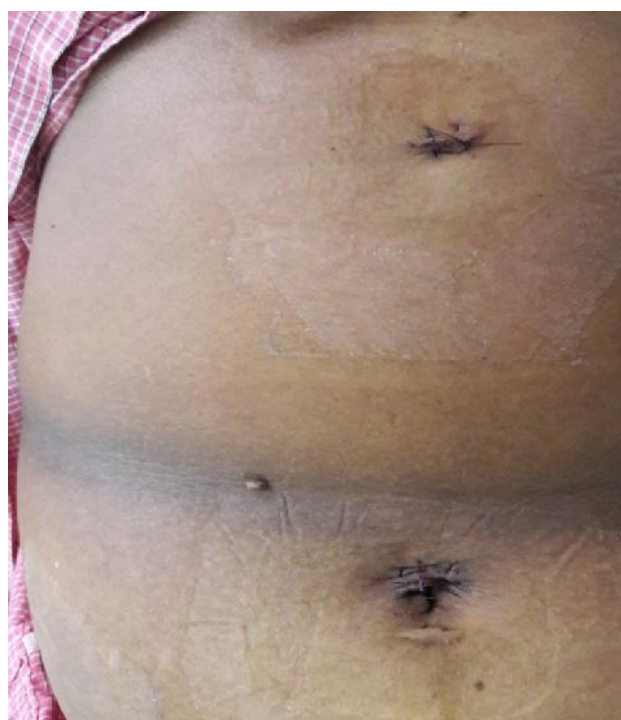

Figure 25: Two Incisions Three Ports- Post-op Day 3

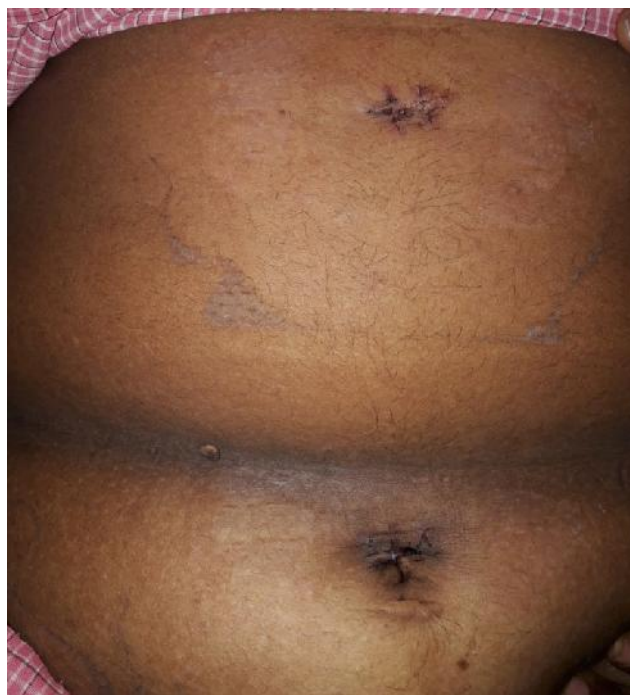

Figure 26: Two Incisions Three Ports- After Suture Removal

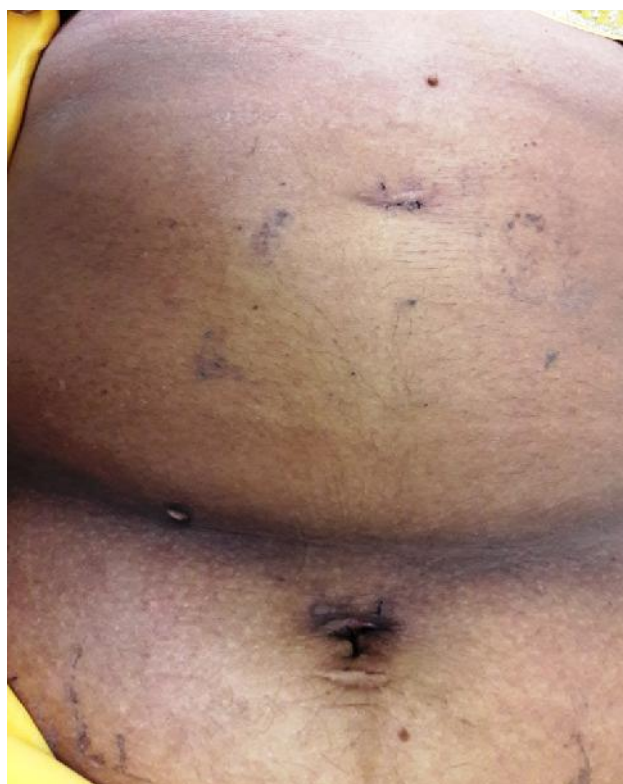

Figure 27: Two Incisions Three Ports- At Followup

Post-operative care was the same in both groups with antibiotics and analgesics. One dose of paracetamol infusion was administered intra-op after induction. Next dose of analgesic- paracetamol was administered after 6 hours, and before the administration of analgesic, the patient's pain scale is measured on the visual analogue scale. Intravenous dose of paracetamol was given every 6 hours for the first 24 hours. If a patient complains of severe pain inspite of previous dose of paracetamol, a rescue dose of analgesic (paracetamol) is administered. Once the patient was taking orally, the patient was discharged. Sutures were removed between the 7th and 10th post-op day. The patients were followed up till 3 months post surgery.

Outcome variables

The variables that were evaluated were:

1. Operating time- time taken from the first skin incision at the umbilicus to closure of the two ports.
2. Post-operative pain at 6 and 24 hours after surgery by visual analogue scale. On the visual analogue scale, pain is scored from 0 to 10 with 0 being no pain and 10 being maximum pain. Score of 1 to 3 is mild pain, 4 to 6 is moderate pain and 7 to 10 is severe pain. When the patient complains of severe pain inspite of the scheduled dose of analgesic, a rescue dose of analgesic- paracetamol 1 gram was administered.
3. Patient satisfaction with the cosmetic outcome by visual analogue scale measured at the time of suture removal and at 3 months follow up. The lowest to highest score was measured from 0 to 10 with zero being the worst satisfaction score and 10 being the highest.

Statistical Analysis

The data was tabulated in Microsoft Excel Spread sheet (Annexure III). The data was analysed by MedCalc 17. The categorical data was expressed as rates, ratios, percentages and comparisons were made using mann whitney U test. Numerical data was compared by student t test. A probability 'p' value of less than/equal to 0.05 at 95% confidence interval was considered as statistically significant.

RESULTS

This prospective randomised control study consisted of 61 patients with symptomatic benign gall bladder disease that warranted laparoscopic cholecystectomy who were admitted in KLES Dr. Prabhakar Kore Hospital and Medical Research Centre, Belagavi and underwent Laparoscopic cholecystectomy from January 2017 to December 2017.

All the cases underwent pre-operative assessment. The duration of surgery, post-operative pain, cosmetic satisfaction were recorded. The findings were tabulated and the following observations were made.

Total number of cases was 61.

The patients in the study were divided into two groups:

Group A: two incision three port laparoscopic cholecystectomy- 22 cases

Group B: conventional four port laparoscopic cholecystectomy- 39 cases

All patients in the study were posted for laparoscopic cholecystectomy after pre-op evaluation and pre-anesthetic evaluation. The patients were randomly assigned to groups A or B and underwent the proposed procedure – two incision three port laparoscopic cholecystectomy or conventional laparoscopic cholecystectomy after attaining appropriate consent.

This study comprising of 22 cases of two incision three port laparoscopic cholecystectomy and 39 cases of conventional four port laparoscopic cholecystectomy compared the post operative pain, duration of surgery and cosmetic satisfaction between the two groups.

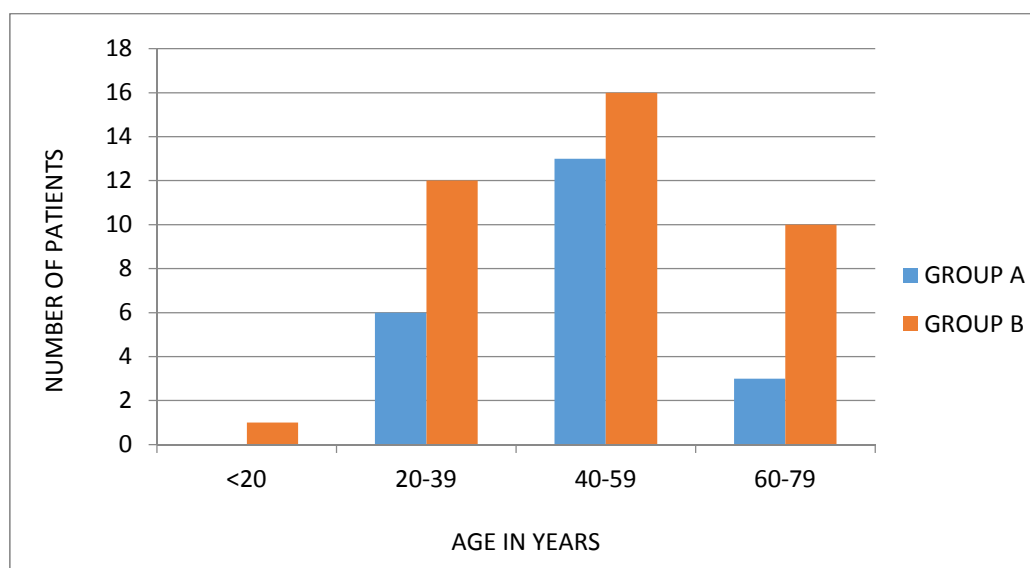
AGE DISTRIBUTION

Table 1

AGE (YEARS)	GROUP A		GROUP B	
	NUMBER	PERCENTAGE	NUMBER	PERCENTAGE
< 20	0	0.00	1	2.56
20-39	6	27.27	12	30.77
40-59	13	59.09	16	41.03
60-79	3	13.64	10	25.64
TOTAL	22	100.00	39	100.00

	GROUP A		GROUP B	
	MEAN	STANDARD DEVIATION	MEAN	STANDARD DEVIATION
AGE (YEARS)	46.64	11.47	45.67	15.45

Graph 1



In group A, 6 patients were in the age group of 20-39 years, 13 patients in the age group 40-59 years and 3 patients in the 60-79 years. The mean age was 46.64 years and standard deviation of 11.47 years.

In group B, 1 patient was in the age group less than 20 years, 12 patients in the age group 20-39 years, 16 patients in the age group 40-59 years and 10 patients in the age group 60-79 years. The mean age was 45.67 years and the standard deviation was 15.45 years.

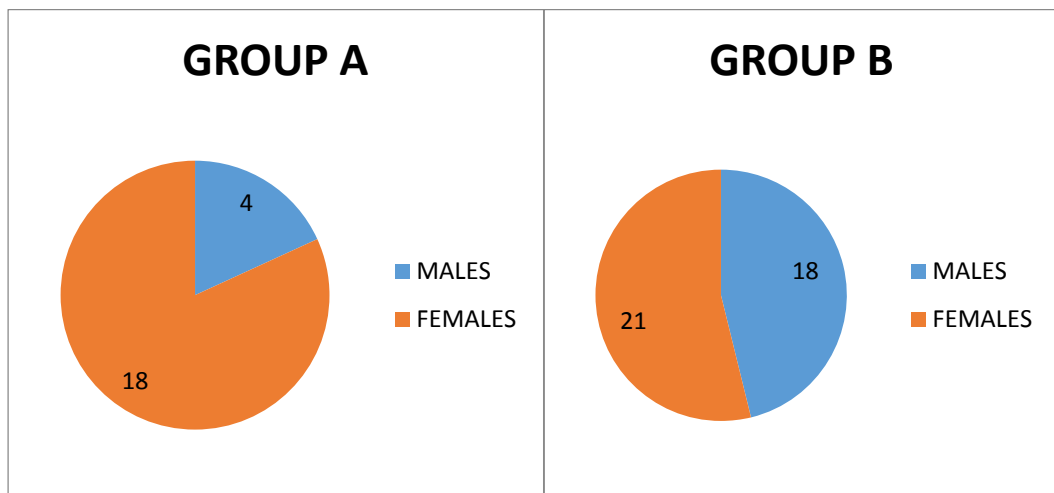
The p value was 0.5753 and so the difference in mean age was statistically not significant.

GENDER DISTRIBUTION

In group A, there were 4 males and 18 females.

In group B, there were 18 males and 21 females.

Graph 2



POST-OPERATIVE PAIN AT 6 HOURS

The post-operative pain was recorded by visual analogue scale at 6 hours.

Table 2

PAIN AT 6 HOURS	GROUP A		GROUP B	
	NUMBER	PERCENTAGE	NUMBER	PERCENTAGE
4	0	0.00	1	2.56
5	5	22.73	2	5.13
6	8	36.36	10	25.64
7	7	31.82	12	30.77
8	2	9.09	12	30.77
9	0	0.00	2	5.13
TOTAL	22	100.00	39	100.00

In group A, 22.73% had a pain scale of 5, 36.36% had pain scale of 6, 31.82% had pain of 7 and 9.09 had pain of 8.

In group B, 2.56% had pain level of 4 in the pain scale, 5.13% had pain of 5, 25.64 had pain of 6, 30.77% had pain of 7, 30.77% had pain of 8 and 5.13% had pain of 9.

Using Mann-whitney U test, the mean rank in group A was 23.73 with a median score of 6 and the mean rank of group B was 35.10 with a median score of 7 showing a significantly smaller rank for group A with a p value of 0.0127 ie. a significantly lesser pain score at 6 hours.

There were 2 patients in each group that required administration of rescue doses of analgesic within the first 24 hours of surgery inspite of the regular 6 hourly dosing of paracetamol.

	GROUP A		GROUP B	
	MEAN RANK	MEDIAN	MEAN RANK	MEDIAN
POST-OPERATIVE PAIN AT 6 HOURS BY VISUAL ANALOGUE SCALE	23.73	6	35.10	7

POST-OPERATIVE PAIN AT 24 HOURS

The post-operative pain was recorded by visual analogue scale at 24 hours.

Table 3

PAIN AT 24 HOURS	GROUP A		GROUP B	
	NUMBER	PERCENTAGE	NUMBER	PERCENTAGE
4	10	45.45	11	28.21
5	7	31.82	9	23.08
6	5	22.73	14	35.90
7	0	0.00	4	10.26
8	0	0.00	1	2.56
TOTAL	22	100.00	39	100.00

In group A, 45.45% had pain of 4 on the pain scale, 31.82% had pain of 5, 22.73% had pain of 6.

In group B, 28.21% had pain of 4, 23.08% had pain of 5, 35.90% had pain of 6, 10.26% had pain of 7 and 2.56% had pain of 8.

Using the Mann-whitney U test, group A had a mean rank of 25.07 with a median score of 5 and group B had a mean rank of 34.35 with a median score of 5 showing a significantly smaller rank for group A with a p value of 0.0400 ie. significantly lesser pain score at 24 hours.

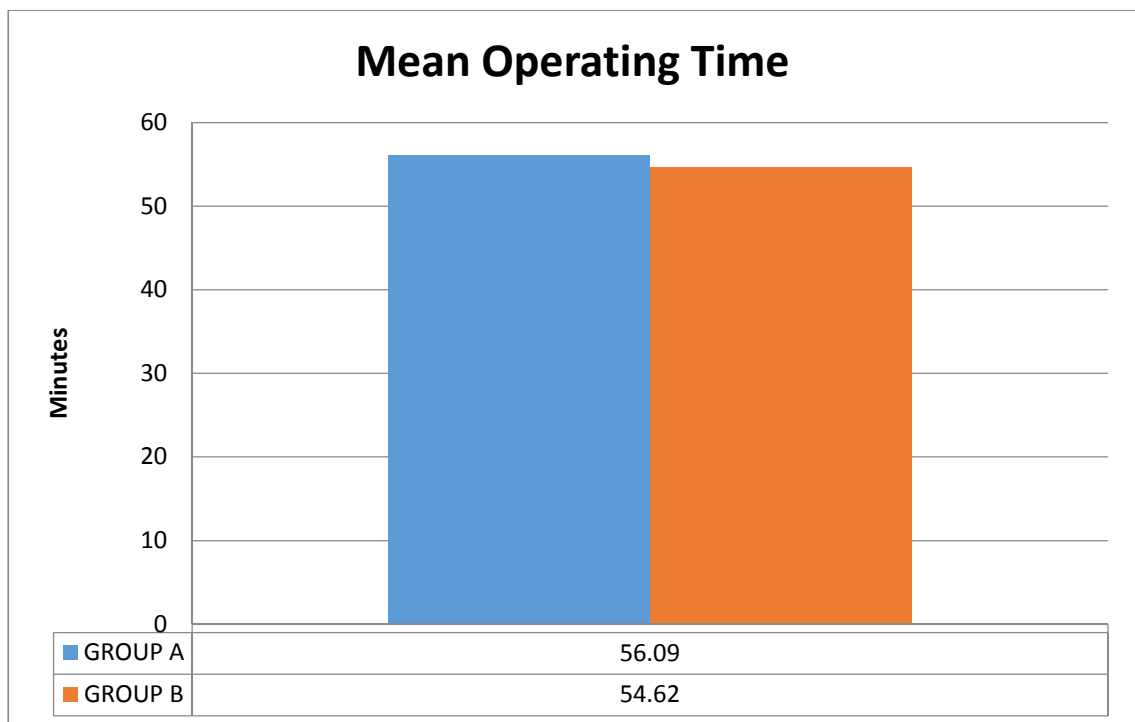
	GROUP A		GROUP B	
	MEAN RANK	MEDIAN	MEAN RANK	MEDIAN
POST-OPERATIVE PAIN AT 24 HOURS BY VISUAL ANALOGUE SCALE	25.07	5	34.35	5

OPERATING TIME

The operating time was compared between the two groups. The mean operating time in group A was 56.09 minutes and in group B was 54.62 minutes. The p value was 0.45 and the inference was not statistically significant.

Table 4

OPERATING TIME IN MINUTES	GROUP A		GROUP B	
	NUMBER	PERCENTAGE	NUMBER	PERCENTAGE
20-39	0	0.00	1	2.56
40-59	13	59.09	26	66.67
60-79	9	40.91	12	30.77
TOTAL	22	100.00	39	100.00



Graph 3

COSMETIC SATISFACTION

The cosmetic satisfaction was recorded at the time of suture removal by the visual analogue scale.

Table 5

COSMETIC OUTCOME VISUAL ANALOGUE SCALE SCORE	GROUP A		GROUP B	
	NUMBER	PERCENTAGE	NUMBER	PERCENTAGE
5	0	0.00	8	20.51
6	2	9.09	15	38.46
7	7	31.82	10	25.64
8	10	45.45	6	15.38
9	3	13.64	0	0.00
TOTAL	22	100.00	39	100.00

The difference in cosmetic satisfaction was highly significant with better cosmetic satisfaction in group A with a mean rank of 43.50 and median score of 8 than in group B with a mean rank of 23.95 and median score of 6 as compared by the mann whitney U test.

	GROUP A		GROUP B	
	MEAN RANK	MEDIAN	MEAN RANK	MEDIAN
COSMETIC OUTCOME (VISUAL ANALOGUE SCALE)	43.50	8	23.95	6

The p value was <0.0001 which was highly significant.

The patients were followed up on outpatient basis for the next three months. The cosmetic satisfaction was recorded at follow-up by visual analogue scale. Three patients in group A and four patients in group B were lost to follow-up.

Table 6

	GROUP A		GROUP B	
	MEAN RANK	MEDIAN	MEAN RANK	MEDIAN
COSMETIC OUTCOME AT FOLLOW UP (VISUAL ANALOGUE SCALE)	38.11	8	21.74	6

The difference in cosmetic satisfaction at the time of follow-up was highly significant with better cosmetic satisfaction in group A with a mean rank of 38.11 and median score of 8 than in group B with a mean rank of 21.74 and median score of 6 as compared by the mann whitney U test.

The p value was < 0.0001 which was highly significant.

DISCUSSION

At present, laparoscopic cholecystectomy is considered the gold standard in the management of benign gall stone disease.³ The conventional procedure required the use of four ports through four incisions.³ It has been accepted that the four port laparoscopic cholecystectomy procedure is safe, with an uneventful post operative course and minimal duration of disability with return to full activity in an average of 8 days.³

Minimal access surgery is constantly striving towards minimal percutaneous access to further enhance the advantages of laparoscopy over open procedure and improve further on the established technique of laparoscopic cholecystectomy.¹³ This is done by reducing the number and size of the surgical ports and instruments. These techniques such as mini laparoscopic cholecystectomy, three and two port and even single port techniques have been shown to decrease the post-operative pain, to have better cosmetic outcome and quicken the time to recovery.⁴¹

Single incision laparoscopic cholecystectomy (SILC) has emerged as a potentially less invasive alternative to conventional laparoscopic cholecystectomy. Navarra et al performed the first SILC procedure in 1997 through a single periumbilical incision. The potential advantages of SILC are less scars and so a better cosmetic outcome, less post-operative pain, shorter length of hospital stay and faster recovery. It however required the development of special ports, special modified instruments for triangulation and dissection and to reduce instrument clash which came as a disadvantage of the procedure in addition to the increased costs involved. Single incision laparoscopic cholecystectomy has been reported to be a feasible and safe procedure.^{10,29} In a prospective randomized study conducted by Eric C H Lai et al comparing single incision laparoscopic cholecystectomy and the conventional four

port laparoscopic cholecystectomy, SILC was performed using a SILS Port through a 20mm umbilical incision and a few modified instruments along with suture retraction. A total of 54 patients underwent surgery with 27 patients in each group. The operative time was similar in both the SILC group and the 4 port group. The post-operative pain by the visual analogue scale at 6 hours after surgery was similar in both the groups (4.5 vs 4.0) but the SILC group had a significantly worse pain score on day 7 than the conventional group. The higher pain score on day 7 was explained by the fact that the single incision wound was larger than the conventional port. They concluded that the SILC procedure was superior in terms of cosmetic outcome but not in post-operative pain or recovery. It was said to be feasible and safe for properly selected patients in experienced hands. The learning curve was highly variable for surgeons with different levels of experience.⁴⁵

In a similar study performed by Daniel J Ostlie et al in a pediatric population comparing SILC and conventional four port laparoscopic cholecystectomy, they also required the use of SILS port and had longer operative times (mean 68.6 mins vs 56.1 mins, difference of 12 minutes) as compared to the four port procedure both of which resulted in increased procedure costs. There was also seen a trend toward more doses of post-operative analgesia in the single port approach.⁴⁶

With the intention of avoiding any new or special reticulating instruments specific to single incision laparoscopic surgery, studies on single incision laparoscopic cholecystectomy were conducted using standard laparoscopic instruments. This was done to avoid the associated costs and also to avoid the additional learning curve. One such study was conducted by A M Abdelaziz Hassan on 80 patients with benign gall bladder disease through a single umbilical incision using conventional laparoscopic instruments and traction sutures. Three ports were

placed through the single incision. The study concluded that such a procedure is safe and feasible to perform even with conventional laparoscopic instruments thus avoiding the added costs of special articulating instruments and ports and good aesthetic results and patient satisfaction. Challenges that were faced while performing the procedure included clash between instruments, deflection of laparoscope's light source by operating instruments, interference of wires which connected to instruments (i.e. cautery) and proprioception loss because of crossed instruments. These challenges contributed to an increased operative time.⁴⁷

Another such study was conducted by Ali Aminian et al where standard laparoscopic instruments are placed through two periumbilical incisions. Surgical exposure of the calot's triangle was achieved by placing two transcutaneous sutures, one passed through the fundus and the other through the infundibulum. The study concluded that such an approach with standard instruments was safe and feasible and claimed to have good cosmetic results as well but however further standardised trials were required.⁴²

All these studies where SILC was compared with conventional laparoscopic cholecystectomy did not conclude that SILC was better than conventional laparoscopic cholecystectomy. However they opined that SILC is a feasible procedure with a favourable cosmetic outcome. Because of mixed results and factors such as the increased costs and need for sophisticated instruments, it did not become a popular procedure.

Other studies compared the outcomes of SILC and three port laparoscopic cholecystectomy. M A Omar et al compared 89 and 98 patients respectively in the SILC and the three port group in terms of postoperative pain, operative time and patient aesthetic satisfaction among other parameters. The SILC was performed using

either a single port device in a 2 cm infraumbilical incision or 3 ports closely placed within the same 3 cm incision. The three port technique was performed using two 10mm trocars and 5mm trocars through an infraumbilical, midepigastic and right midclavicular incision. The need for additional trocar placement was greater in the SILC group than the three port group. Operative time in SILC was also significantly greater than the 3 port group. Other studies also mention similar outcomes of increased operative time with improvement as the experience increases. M A Omar et al showed no significant differences in postoperative pain and analgesic requirement between the SILC and three port group, but there are conflicting reports.⁴⁸ Whereas some studies showed lesser pain in the SILC group attributed to the single incision in SILC than the three port group⁴⁹, other studies found pain scores were more in the SILC due to more tissue trauma caused by the single port and local trauma to the abdominal wall.⁵⁰ Deveci et al reported a difference in VAS at 24 hours and lack of difference on VAS at 6 hours and analgesic requirement⁵¹, while Sharma et al reported more pain in the SILC group in VAS at 6 hours and lack of any difference in VAS at 24 hours.⁵² Regarding aesthetic outcome, SILC results was better than the three port group in many studies.^{53,54,55} Ming Xin Pan et al conducted a similar study between SILC and three port laparoscopic technique comparing postoperative pain, duration, cosmetic result. Pain score by VAS was worse at 8 hours after surgery but similar score on day 7. Cosmetic satisfaction was also better in the SILC group but the operative time, total costs were not statistically different.⁴⁹

Regarding the subject of minimally invasive or lesser invasive procedures, there are hardly few studies in literature. Several modifications and techniques are described to reduce the invasiveness of the procedure by reducing the number or size of ports to achieve the minimal level of invasiveness as compared to SILC and also to

achieve the safety and efficacy of standard laparoscopic cholecystectomy in terms of dissection and to circumvent the disadvantages that hinder the acceptance of SILC.

In a study conducted by Mushtaq Chalkoo et al on 50 cases of gallstone disease, a modified technique of three port laparoscopic cholecystectomy was done where a 10mm port is inserted at the umbilicus, 5mm port also at the umbilicus and a 10mm port at the epigastric region thus concealing three ports in two incisions. The concealed port at the umbilicus helped retract the gall bladder to facilitate the dissection of calot's triangle. The other advantages in this technique was claimed that both the hands of the surgeon lie on the same plane and do not cross the body of the surgeon making it easier to manoeuvre and avoiding the use of transcutaneous sutures.⁴⁴ However this study did not compare this modified technique and its results with the standard/ conventional laparoscopic cholecystectomy. In our study, we used a similar kind of port placement and the use of transcutaneous retraction sutures was further able to achieve retraction of gall bladder to achieve better visualisation for dissection.

The advantages of such three port laparoscopic cholecystectomy studies as in our study, that is the two incisions three ports technique performed using conventional/ standard laparoscopic instruments and scopes and the use of transabdominal sutures is that there is no increased costs and any additional learning/ training that is required if we were to use the more sophisticated single port instruments.

Our study was conducted in a single centre by a single surgeon and included a total of 61 cases divided into two groups based on the procedure performed that is two incisions three ports laparoscopic cholecystectomy and conventional four port laparoscopic cholecystectomy. In our study we placed a 10mm trocar and a 5mm

trocar at the umbilicus and a 10mm trocar separately in the epigastric region. Thereby the two working ports of the surgeon were far apart for easy manoeuvring without much instrument clashing. The use of transcutaneous sutures helped in retracting the fundus of the gall bladder without the need for an additional trocar and assistants hand just for that purpose.

There have been no studies till now that have compared such two incisions three ports laparoscopic cholecystectomy with the conventional laparoscopic cholecystectomy.

A study of 30 patients conducted by Dario D Antonio et al involved a double incision laparoscopic cholecystectomy done using three ports (laparoscope, assistant grasper, main surgeon's instrument) at the umbilical incision and a 3mm port at the subcostal margin (surgeons left hand instrument) and its feasibility and safety, and also its role in routine intraoperative cholangiogram(done through 3 mm port). In this study, the wider angle between the operative instruments helped achieve the required critical view of safety similar to standard laparoscopic surgery by improving exposure and obtaining adequate traction. This double incision procedure was thus seen to overcome the pitfalls of SILC such as inadequate exposure, the constant clashing of straight instruments or the 'chopsticks effect' and also the risk of biliary injury.⁵⁶ While in our study, a routine intraoperative cholangiography was not performed, we were able to achieve a better visualisation of the calot's triangle using a combination of retraction sutures and straight instruments placed far apart unlike the SILC.

In a study conducted by Ranendra Hajong et al, a two port technique was compared with a three port technique of laparoscopic cholecystectomy in a total of 60 patients using a combination of standard laparoscopic ports and sutures. While the three port technique was performed with 10mm trocars at the umbilicus and the

epigastrium, 5mm port at the epigastrium and a suture at the anterior axillary line to retract the gall bladder, the two port technique used 10mm trocars at the umbilicus, epigastrium and two sutures to retract the gall bladder at its fundus and neck. Post operative pain, operative time and cosmetic appearance were assessed.⁴³ There was no statistically significant difference in operative time between the two groups. In the three port group, the postoperative pain score was mild in 26.67%, moderate in 60% and severe in 14.33%. In the two port group, the pain score was mild in 66.67%, moderate in 20% and severe in 3.33%. Although the two port technique was technically feasible and associated with better patient satisfaction in terms of pain and cosmesis, it was reported to be technically difficult due to the limited operative field.^{22,6} There were no reported complications at the sites of abdominal needle puncture in other reported studies and this study.

In our study, the post-operative pain at 6 hours and 24 hours in the two incision three port group were significantly less ($p=0.0127$ at 6 hours and $p=0.0400$ at 24 hours) as compared to the conventional four port group by the mann whitney U test. A retrospective study by Heng Hui Lien et al comparing two-, three- and four-port laparoscopic cholecystectomies showed significant differences in post operative pain between four- and three port surgeries but not between three and two port and four- and two- port surgeries.⁴¹ Other studies conducted by Trichak S et al showed less analgesic use in the three trocar group.⁵⁷ Another study by Leung K F on two port laparoscopic cholecstectomy showed that pain was significantly less than in four port approach.⁵⁸

In our study on comparing the operating time between the two groups, the two incision three port technique had an operating time of 56.09 minutes and the conventional laparoscopic technique had an operating time of 54.62 minutes. The p

value was 0.45 and the inference was not statistically significant which meant that the two incision laparoscopic cholecystectomy technique did not take additional time when compared to conventional four port laparoscopic cholecystectomy. In other studies, the operating times were also found to be similar between the conventional and reduced port techniques with no statistically significant differences.^{39,40,43} In a study by Manoj Kumar et al on three port versus four port laparoscopic cholecystectomy and Poon et al on two port versus four port laparoscopic cholecystectomy, they reported a decreased operating time in the reduced port group. The explanation given was the less time spent in establishing and closing the additional port.^{4,6} Other explanations are that in the three port cholecystectomy, all the instruments used to manipulate the gall bladder are held by the surgeon except the camera whereas the assistant holds the fundus in the four port technique and the surgeon must spend additional time orienting the assistant for adequate positioning.⁴⁰ Other studies that involved use of glove ports required additional operative time that was avoided in our study. One such study by Heng Hui Lien⁴¹ et al compared the operative times between two-, three- and four port laparoscopic cholecystectomies. The study showed statistically significant operative time differences between the four and three port surgeries and four and two port surgeries. This time difference was mainly attributed to the increased time and steps required for setting the ports.

Most studies on reduced port laparoscopic cholecystectomy reported on patient satisfaction with the cosmetic outcome of the procedure striving towards the cosmetic satisfaction single incision laparoscopic cholecystectomy (SILC) achieved. The aim was to achieve a balance between safety and practicality of the reduced port procedure and a better cosmetic satisfaction as compared to the conventional four port technique. In our study, the cosmetic outcome was measured by the visual analogue

scale. When we compared the mean rank of the cosmetic outcome between the two incision group with the conventional group, there was a higher mean rank of the satisfaction scores according to the visual analogue scale in the two incision group (43.50 with a median of 8) as compared to the four port group (rank of 23.95 with a median of 6) with a p value of <0.0001 making it statistically significant. Several other studies including those done by Trichak et al and Poon et al also report a better cosmetic outcome for reduced port procedures when compared to standard four port technique.^{6,57}

Regarding safety and feasibility, our study did not involve any complications such as biliary duct injury, complications related to the transabdominal placement of retraction sutures, the ability to attain the critical view of safety or local port site complications. There were no cases in our study where the two incisions three ports technique was abandoned or converted to the conventional four port laparoscopy or converted to the open cholecystectomy procedure or the need for additional ports. Because only two trocars (the 30 degree scope and grasper) were introduced through the umbilical port and the dissecting forceps was introduced through the epigastric port similar to the conventional method, multiple clashes of instruments was limited and we were able to achieve better triangulation than if all the instruments were introduced through a single incision.

CONCLUSION

The present study comparing standard/ conventional four port laparoscopic cholecystectomy with two incisions three ports laparoscopic cholecystectomy has proved that the two incisions three ports technique can be performed with operative time equivalent to the conventional four port laparoscopic technique without any additional complications and thus is feasible and safe like the standard four port procedure. The outcomes of post-operative pain and cosmetic satisfaction were better than the standard/conventional four port procedure. However there are no other studies where such modified method of two incisions three ports laparoscopic cholecystectomy are compared with the conventional laparoscopic cholecystectomy. Further studies and larger multicentric studies are required.

SUMMARY

Two incisions three ports laparoscopic cholecystectomy can be considered as a bridge technique between the standard four port laparoscopic cholecystectomy and more superior techniques such as SILC and NOTES but with the use of standard laparoscopic instruments thereby avoiding the more expensive and special instruments required and the longer learning curve involved. The present study was done to evaluate the efficacy and safety of two incisions three ports laparoscopic cholecystectomy and to compare the post-operative pain, operating time, and cosmetic satisfaction.

This one year randomised control trial was done in the Department of General Surgery in KLES Dr Prabhakar Kore Hospital and MRC, Belagavi from January 2017 to December 2017. A total of 61 patients who required laparoscopic cholecystectomy participated in this study. Based on the surgical intervention, the patients were divided into two groups, group A with 22 patients who underwent the two incisions three ports laparoscopic cholecystectomy and group B with 39 patients who underwent standard four port laparoscopic cholecystectomy.

In this study, the mean age was 46.64 years with a standard deviation of 11.47 in group A and 45.67 years with a standard deviation of 15.45 in group B with a p value of 0.5753 which was statistically not significant. The post-operative pain score at 6 hours was measured on the visual analogue scale. Using mann-whitney U test, the mean rank in group A was 23.73 with a median score of 6 and the mean rank of group B was 35.10 with a median score of 7 showing significantly lesser pain score at 6 hours. The post-operative pain score at 24 hours was measured. Using the Mann-whitney U test, group A had a mean rank of 25.07 with a median score of 5 and group B had a mean rank of 34.35 with a median score of 5 showing a significantly lesser

pain score at 24 hours. The mean operating time was compared in both the groups. The mean operating time was 56.09 minutes in group A and 54.62 minutes in group B. The p value was 0.45 which was statistically not significant. The difference in cosmetic satisfaction was highly significant with better cosmetic satisfaction in group A with a mean rank of 43.50 and median score of 8 than in group B with a mean rank of 23.95 and median score of 6 as compared by the mann whitney U test.

Thus on comparison of both groups, there was significantly lesser post-operative pain at both 6 hours and 24 hours in group A and a significantly better satisfaction in cosmetic outcome in group A and equivalent operating time.

Therefore based on the results of this study, it can be concluded that two incisions three ports laparoscopic cholecystectomy when compared to standard four port laparoscopic cholecystectomy has better operative outcomes in terms of post-operative pain and cosmetic satisfaction with an equivalent operating time and is a safe and feasible procedure.

BIBLIOGRAPHY

1. Morgenstern L. Carl Langenbuch and the first cholecystectomy. *Surg Endosc.* 1992;6:113–114
2. Litynski GS. Profiles in laparoscopy: Mouret, Dubois, and Perissat: the laparoscopic breakthrough in Europe (1987/1988). *JSLS.* 1999 3 (2): 163–167
3. Soper NJ, Stockmann PT, Dunnegan DL, Ashley SW. Laparoscopic Cholecystectomy The New 'Gold Standard'?. *Arch Surg.* 1992;127(8):917–923.
4. Kumar M, Agrawal CS, Gupta RK. Three-Port Versus Standard Four-Port Laparoscopic Cholecystectomy: a Randomized Controlled Clinical Trial in a Community-Based Teaching Hospital in Eastern Nepal. *JSLS: Journal of the Society of Laparoendoscopic Surgeons.* 2007;11(3):358-362.
5. Osborne D, Boe B, Rosemurgy AS, Zervos EE. Twenty-millimeter laparoscopic cholecystectomy: Fewer ports results in less pain, shorter hospitalization, and faster recovery. *Am Surg* 2005; 71:298-302.
6. Poon CM, Chan KW, Lee DW, Chan KC, Ko CW, Cheung HY, *et al.* Two-port versus four-port laparoscopic cholecystectomy. *Surg Endosc* 2003;17: 1624-7.
7. Pan MX, Jiang ZS, Cheng Y, Xu XP, Zhang Z, He GL, Xu TC, Zhou CJ, Liu HY, Gao Y. Single-incision vs three-port laparoscopic cholecystectomy: Prospective randomized study. *World J Gastroenterol* 2013; 19(3): 394-398
8. Barbaros U, Sümer A, Tunca F, Gözkün O, Demirel T, Bilge O, Randazzo V, Dinçça A, Seven R, Mercan S, Budak D. Our early experiences with single-incision laparoscopic surgery: the first 32 patients. *Surg Laparosc Endosc Percutan Tech* 2010; 20: 306-311

9. Yu WB, Zhang GY, Li F, Yang QY, Hu SY. Transumbilical single port laparoscopic cholecystectomy with a simple technique: initial experience of 33 cases. *Minim Invasive Ther Allied Technol* 2010; 19: 340-344
10. Kumar V, Dadhwal US. Cholecystectomy: What's new? *Medical Journal, Armed Forces India*. 2012;68(3):288-292.
11. Van Gulik TM. Langenbuch's cholecystectomy – once a remarkably controversial operation. *Neth J Surg*. 1986;38(5):138-141
12. Reynolds W Jr. The first laparoscopic cholecystectomy. *JLS*. 2001;5(1):89-94.
13. T.W.Sadler. Langman's Medical Embryology 12th Edition. Lippincott Williams & Wilkins. 2012
14. Susan Standring. Gray's Anatomy. The Anatomical Basis Of Clinical Practice. 41st Edition. Elsevier. 2016 page 1173-1175
15. John E Skandalakis, Panajotis N Skandalakis, Lee John Skandalakis. Surgical Anatomy and Technique. A Pocket Manual. 2nd Edition. Springer. Page 575 to 578
16. Bruce V Macfayden Jr et al. Laparoscopic Surgery Of The Abdomen. Springer
17. M. Zubair, L. Habib, F. Memon, M. R. Mirza, M. A. Khan, and M. S. Quraishy, "Rouviere's sulcus: a guide to safe dissection and laparoscopic cholecystectomy," *Pakistan Journal Of Surgery*, vol. 22, no. 2, pp. 119–121, 2009
18. Strasberg SM, Brunt LM. The critical view of safety: why it is not the only method of ductal identification within the standard of care in laparoscopic cholecystectomy. *Ann Surg*. 2017;265:464–5
19. Strasberg SM, Hertl M, Soper NJ. An analysis of the problem of biliary injury during laparoscopic cholecystectomy. *J Am Coll Surg*. 1995;180:101–125

20. Strasberg SM, Brunt LM. Rationale and use of the critical view of safety in laparoscopic cholecystectomy. *J Am Coll Surg.* 2010;211:132–138.
21. Michael J Zinner, Stanley W Ashley. *Maingot's Abdominal Operations* 12th Edition. McGraw Hill. 2013
22. Davidoff A, Pappas T, Murray E et al mechanisms of major biliary injury during laparoscopic cholecystectomy *Ann Surg.* 1992;215:196-202.
23. Lao H, Lo Cy, Patil NG, Yuen WK. Early versus delayed- interval laparoscopic cholecystectomy for acute cholecystitis. *Surg Endosc.* 2006;20:82-87
24. Bisgaard T, Klarskov B, Rosenberg J, Kehlet H. Characteristics and prediction of early pain after laparoscopic cholecystectomy. *Pain* 2001;90(3):261-9.
25. Liu YY, Yeh CN, Lee HL, Wang SY, Tsai CY, Lin CC, et al. Local anesthesia with bupivacaine for patients undergoing laparoscopic cholecystectomy. *World Journal of Gastroenterology* 2009;15(19):2376.
26. Lee IO, Kim SH, Kong MH, Lee MK, Kim NS, Choi YS, et al. Pain after laparoscopic cholecystectomy: the effect and timing of incisional and intraperitoneal bupivacaine. *Canadian Journal of Anesthesia/Journal canadien d'anesthésie* 2001;48(6):545-50.
27. Siddiqui NA, Azami R, Murtaza G, Nasim S. 2012. Postoperative port-site pain after gall bladder retrieval from epigastric vs. umbilical port in laparoscopic cholecystectomy: a randomized controlled trial. *International Journal of Surgery* 10:213–216.
28. Katz J, Melzack R: Measurement of pain. *Surg Clin North Am* 1999; 79: 231–52
Katz, J Melzack, R
29. Navarra G, Pozza E, Occhionorelli S, Carcoforo P, Domini I. One wound laparoscopic cholecystectomy. *Br J Surg.* 1997;84:695.

30. Kuon Lee S, You YK, Park JH, Kim HJ, Lee KK, Kim DG. Singleport transumbilical laparoscopic cholecystectomy a preliminary study in 37 patients with gallbladder disease. *J Laparoendosc Adv Surg Tech* 2010;19:495-499.
31. Tsimoyiannis E, Tsimogiannis K, Pappas-Gogos G, et al. Different pain scores in single transumbilical incision laparoscopic cholecystectomy versus classic laparoscopic cholecystectomy: a randomized controlled trial. *Surg Endosc.* 2010;24:1842-1848.
32. Chang SK, Tay CW, Bicol RA, Lee YY, Madhavan KA. Casecontrol study of single-incision versus standard laparoscopic cholecystectomy. *World J Surg.* 2010;35:289-293.
33. Moreira-Pinto J, Lima E, Correia-Pinto J, Rolanda C. Natural orifice transluminal endoscopy surgery: A review. *World J Gastroenterol.* 2011 Sep 7;17(33):3795-3801.
34. Bajpai M and Mitra A. The Percutaneous ‘Pick and Fix’ Suture: A Surrogate Port for Paediatric Laparoscopic Procedures. *Austin J Gastroenterol.* 2015;2(4): 1045.
35. Cuschieri A. Single-incision laparoscopic surgery. *J min access surg.* 2011; 7.1: 3.
36. Jategaonkar, P.A., Jategaonkar, S.P. & Yadav, S.P. *Hellenic J Surg* (2016) 88: 52.
37. Tian MG, Zhang PJ, Yang Y, Shang FJ, Zhan J. Two-port laparoscopic cholecystectomy with modified suture retraction of the fundus: A practical approach. *J Min Access Surg* 2013;9:122-5.
38. Slim K, Pezet D, Stencl J Jr, Lechner C, Roux SL, *et al.*: Laparoscopic cholecystectomy: an original three trocar technique. *World J Surg* 1995, 19:394-397.

39. Al-Azawi D, Houssein N, Rayis AB, McMahon D, Hehir DJ (2007) Three-port versus four-port laparoscopic cholecystectomy in acute and chronic cholecystitis. *BMC Surg* 7:8
40. Mayir B, Dogan U, Koc U, Aslaner A, Bilecik T, Ensari CO, Cakir T, Oruc MT. Safety and effectiveness of three-port laparoscopic cholecystectomy. *Int J Clin Exp Med*. 2014;7:2339–2342.
41. Lien HH, Huang CC, Huang CS. A retrospective comparison of two-, three-, and four-port laparoscopic cholecystectomies. *Formos J Surg* 2017;50:169-74.
42. Aminian, A., Mishra, R., & Mirsharifi, R. (2011). Scarless Cholecystectomy with Standard Laparoscopic Instruments in Selected Patients. *World Journal Of Laparoscopic Surgery With DVD*, 4, 129-131.
43. Hajong R, Khariong PD. A comparative study of two-port versus three-port laparoscopic cholecystectomy. *J Min Access Surg* 2016;12:311-4.
44. Chalkoo M, Ahangar S, Patloo AM, Madoo AR, Baqal FS, Iqbal S. A medical school experience with three port laparoscopic cholecystectomy with a new modification in technique. *Int J Surg*. 2013;11(1):37–40.
45. Lai EC, Yang GP, Tang CN, Yih PC, Chan OC, Li MK. Prospective randomized comparative study of single incision laparoscopic cholecystectomy *versus* conventional four-port laparoscopic cholecystectomy. *Am J Surg* 2011; 202: 254–258.
46. Ostlie DJ, Juang OO, Iqbal CW (2013) Single incision versus standard 4-port laparoscopic cholecystectomy: a prospective randomized trial. *J Pediatr Surg* 48: 209-214.

47. Abdelaziz Hassan AM, Elsebae MM, Nasr MM, Single institution experience of single incision trans-umbilical laparoscopic cholecystectomy using conventional laparoscopic instruments. *Int J Surg.* 2012;10(9):514–7.
48. Omar MA, Redwan AA, Mahmoud AG: Single-incision versus 3-port laparoscopic cholecystectomy in symptomatic gallstones: a prospective randomized study. *Surgery* 2017; 162: 96–103.
49. Pan MX, Jiang ZS, Cheng Y, Xu XP, Zhang Z, Qin JS, et al. Single-incision vs three-port laparoscopic cholecystectomy: prospective randomized study. *World J Gastroenterol* 2013;19:394-8.
50. Jung GO, Park DE, Chae KM. Clinical results between single incision laparoscopic cholecystectomy and conventional 3-port laparoscopic cholecystectomy: prospective case-matched analysis in single institution. *J Korean Surg Soc* 2012;83:374-80.
51. Deveci U, Barbaros U, Kapakli MS, Manukyan MN, Sims,ek S, Kebudi A, et al. The comparison of single incision laparoscopic cholecystectomy and three port laparoscopic cholecystectomy: prospective randomized study. *J Korean Surg Soc* 2013;85:275-82.
52. Sharma A, Soni V, Baijal M, Khullar R, Najma K, Chowbey PK. Single port versus multiple port laparoscopic cholecystectomy - a comparative study. *Indian J Surg* 2013; 75:115-22.
53. Cheng Y, Jiang ZS, Xu XP, Zhang Z, Xu TC, Zhou CJ, et al. Laparoendoscopic single-site cholecystectomy vs. three-port laparoscopic cholecystectomy: a large-scale retrospective study. *World J Gastroenterol* 2013;19:4209-13.

54. Hua J, Gong J, Yao L, Song Z. Single-incision versus conventional laparoscopic cholecystectomy: a systematic review and meta-analysis. *Open Sci J Clin Med* 2014;2:103-18.
55. Sabuncuoglu MZ, Benzin MF, Cakir T, Sozen I, Sabuncuoglu A. Triple, double- and single-incision laparoscopic cholecystectomy: a prospective study. *Int J Clin Exp Med* 2014;7:3385-91.
56. D'Antonio D, Franzato B, Fusco G, Ruperto M, Dal Pozzo A (2013) Double incision laparoscopic cholecystectomy (DILC) with routine intra-operative cholangiography (IOC): less trauma, same safety. Report on 30 consecutive non-selected cases. *Updates Surg* 65(2):109–114
57. Trichak S: Three-port vs standard four-port laparoscopic cholecystectomy. *Surg Endosc* 2003, 17(9):1434-6.
58. Leung KF, Lee KW, Cheung TY, Leung LC, Lau KW. Laparoscopic cholecystectomy: Two-port technique. *Endoscopy* 1996;28:505-7.

ANNEXURE I – CONSENT FORM

Dear Mr./Mrs./Dr. _____, you are kindly requested to enroll yourself in a research study titled, **“A ONE YEAR RANDOMIZED CONTROL STUDY TO COMPARE THE OUTCOMES OF TWO INCISIONS THREE PORTS AND FOUR PORTS LAPAROSCOPIC CHOLECYSTECTOMY AT KLES DR. PRABHAKAR KORE HOSPITAL AND MEDICAL RESEARCH CENTRE, BELAGAVI”** being conducted by **Dr.** _____, a post graduate student in M.S. General Surgery and the study will be carried out under the direct supervision and guidance of **Dr.** _____, Professor, Department of General Surgery, Jawaharlal Nehru Medical College, Belagavi.

You have been requested to participate in this as you fit into the laid out criteria for a study ‘subject’/ participant.

Your participation in study is voluntary. During the study you will be asked some questions and you are supposed to answer to the best of your knowledge. Your decision whether or not to participate in the study will not affect your treatment in any form during your hospital stay. If you decide to participate you are free to withdraw at any time.

TITLE OF THE STUDY:

“A ONE YEAR RANDOMIZED CONTROL STUDY TO COMPARE THE OUTCOMES OF TWO INCISIONS THREE PORTS AND FOUR PORTS LAPAROSCOPIC CHOLECYSTECTOMY AT KLES DR. PRABHAKAR KORE HOSPITAL AND MEDICAL RESEARCH CENTRE, BELAGAVI”

PURPOSE OF THE STUDY:

To compare the post operative pain, operative time and cosmetic satisfaction of two incisions three ports and four ports laparoscopic cholecystectomy at a tertiary care centre.

PROCEDURES INVOLVED:

If you agree to enroll yourself in my study, you will be interviewed regarding your present, past and family history then you will be clinically examined in detail and investigated accordingly.

You will be randomly allocated using sealed envelope method into group A (two incisions three port) and group B (four port). The surgery laparoscopic cholecystectomy will be done by a consultant general surgeon under general anesthesia.

Post operative analgesia is standardized in both groups.

Operative time for each procedure will be recorded and compared.

Post operative pain will be assessed by visual analogue scale.

Patient satisfaction regarding cosmetic outcome and post operative scars will be assessed.

RISKS AND BENEFITS:

Risks related to the surgical procedure and anesthesia such as injury to intra-abdominal structures, hemorrhage, post-operative infection, surgical site infection, pneumonia. Benefits include reduced post operative pain, improved cosmetic satisfaction, reduced hospital stay.

No bias will be done to the patients who are not willing to participate in the study from the treatment point of view.

VOLUNTARY PARTICIPATION / WITHDRAWAL FROM THE STUDY:

Taking part in the study is voluntary. You may choose not to enroll yourself in this study and may choose to leave the study anytime in between. Treatment will not be withheld if you leave the study.

ALTERNATIVES:

Your decision regarding participation in study will not change present or future health care services offered to you at KLES Dr. Prabhakar Kore Hospital and Medical Research Centre, Belagavi. You would simply be excluded from the study if you wish to, and all your details shall be kept confidential and you will get the routine line of management.

PRIVACY AND CONFIDENTIALITY:

All data collected or disclosed by you during the course of participation of study, will be kept fully confidential. If however during the course it becomes necessary for the progress of the course to disclose the identity, it would be done so only after your informed & written consent.

The only people to know that you are a research subject are members of the research team. No information about you will be disclosed to other without your written permission except:

- In emergency to protect your rights AND welfare.
- If required by law.

AUTHORIZATION TO PUBLISH RESULT:

The results of the study may be used to publish an article. When the results of research published or discussed, in a conference, no information will be displayed that would disclose your identity. Any information obtained in connection with this study and that can be identified with you will remain confidential.

FINANCIAL INCENTIVES FOR PARTICIPATION:

No additional costs shall be incurred upon you for the purpose of this study.

It is purely being done with the idea of research and all the cost of study will be borne by the investigator.

COMPENSATION:

In the event that you become injured as a result of taking part in this study, treatment will be offered to you at KLES Dr. Prabhakar Kore Hospital and Medical Research Centre, Belagavi, or you will be given information about where to receive medical care. However, no reimbursement, compensation or free medical care will be given.

QUESTIONS/CONTACT DETAILS:

You shall be free to contact the below mentioned name & addresses anytime during the study period for any clarification or help as you may desire for.

Dr. _____

MS (Post Graduate Student)

Department of General Surgery

Jawaharlal Nehru Medical College,

Nehru Nagar, KLE Hospital Road,

Belagavi 590010

Dr. _____

MBBS, MS GENERAL SURGERY,

Professor,

Department of General Surgery

Jawaharlal Nehru Medical College,

Nehru Nagar, KLE Hospital Road,

Belagavi 590010

In case you need any further information regarding your rights as study participant you may contact:

Dr. GANGA. S. PILLI

Professor of Pathology & Chairman,
JNMC Institutional Ethics Committee
on Human Subjects Research,
Jawaharlal Nehru Medical College
Nehru Nagar, KLE Hospital Road
Mobile – 9480275601

CONSENT STATEMENT:

I the undersigned Mr/Mrs/Dr_____ do hereby give consent for my participation in this research study after being explained in-depth about the important elements of this study in my own vernacular language.

I give this consent voluntarily in my sound mind and good faith, knowing very well the risks involved and been given enough time to clear my doubts and other queries to participate as a ‘subject’ in this study. I do hereby also give consent for publication of this article in any media / journal and have no objections whatsoever.

Signature or left thumb print of participant or legally authorized representative

Participants name: _____

Signature: _____

Witness/guardian name: _____

Signature_____

Investigator’s name: _____

Signature_____

Guide’s name: _____

Signature_____

Date: ___/___/_____ Place: _____

**ANNEXURE II- PROFORMA / QUESTIONNAIRE TO BE
USED FOR DATA COLLECION**

The proposed proforma/ questionnaire to be used for data collection for the study titled “**A ONE YEAR RANDOMIZED CONTROL STUDY TO COMPARE THE OUTCOMES OF TWO INCISIONS THREE PORTS AND FOUR PORTS LAPAROSCOPIC CHOLECYSTECTOMY AT KLES DR. PRABHAKAR KORE HOSPITAL AND MEDICAL RESEARCH CENTRE, BELAGAVI**” is as follows:

PATIENT DETAILS:

I.P.D/O.P.D NO.:

D.O.A:

NAME:

D.O.D:

SEX:

AGE:

ADDRESS:

Chief Complaints:

Pain abdomen

Yes/No

Duration

Site of pain: Umbilical region/ right iliac fossa/ left iliac fossa/ epigastrium/ right

hypochondrium/ left hypochondrium

Type of pain: radiating/ localised

Throbbing/pricking/ dull aching

Intensity: mild/ moderate/ severe

Association with food intake: yes/no

Associated with fever: yes/no

Degree of fever: Mild/moderate/severe

Type of fever: continuous/ intermittent/ spiking

Vomiting: yes/no

Continuous/intermittent

Content-

Loss of weight; yes/no

History of medical illness such as diabetes/hypertension/ asthma/ tuberculosis/ drug regimes

History of previous surgeries:

History of anaphylaxis to diclofenac sodium: Yes/No

History of anaphylaxis to tramadol: Yes/No

Family history:

GENERAL EXAMINATION:

Built and Nourishment:

Weight:

Pulse

Blood pressure

Respiratory rate:

Temperature:

SYSTEMIC EXAMINATION: NORMAL

ABNORMAL

CVS:

RESPIRATORY:

CNS:

PER ABDOMEN: soft/ guarding/ rigidity

Tender/ Non-tender

Site of tenderness: Umbilical region/ epigastric region/ right iliac fossa/left iliac fossa/right hypochondrium/ left hypochondrium

Bowel sounds: normal/ abnormal

INVESTIGATIONS:

CBC:

RBS:

Blood Urea:

Sr. Creatinine:

LFT:

Urine:

Routine

Microscopy

PT INR:

CONTROL:

TEST:

INR:

HIV

HBsAg:

USG ABDOMEN REPORT:

ANNEXURE III - KEY TO MASTERCHART

Sl. No. - Serial number

IP Number - Inpatient Number

Post-op - Post operative

Sl.No.	IP Number	Age	Gender	Group	Post- OP Pain at 6 hours	Post-op pain at 24 hours	Operating Time(mins)	Cosmetic Outcome	Cosmesis at followup
1	756932	24	M	B	6	5	65	7	7
2	823599	46	M	B	9	8	60	6	7
3	824999	48	F	B	6	6	55	8	8
4	787589	65	F	B	6	5	50	7	7
5	828465	45	F	B	6	6	47	8	8
6	788238	18	F	B	5	4	70	6	6
7	821340	53	M	B	8	7	60	6	7
8	827348	74	M	B	8	5	45	7	7
9	827864	23	M	B	8	6	55	8	8
10	804062	40	M	B	7	4	65	6	6
11	821771	65	M	B	8	6	50	8	8
12	828010	45	M	B	8	6	45	5	6
13	831066	38	M	B	7	4	37	8	lost at followup
14	832970	38	F	B	6	4	45	6	6
15	833531	35	F	B	8	6	50	6	6
16	841799	42	F	B	7	6	75	7	7
17	792639	27	F	B	4	4	55	5	6
18	794083	27	M	B	7	7	45	7	7
19	822003	24	M	B	8	5	50	5	6
20	799180	45	F	B	8	5	57	7	7
21	808342	49	M	B	7	6	60	5	5
22	838399	25	F	B	8	5	40	6	6
23	840967	43	M	B	7	6	55	6	6
24	783811	57	F	B	8	6	50	7	8
25	823253	60	M	B	9	6	70	6	6
26	823599	46	M	B	5	4	45	5	lost at followup
27	796937	45	F	B	6	6	55	5	6
28	797955	75	F	B	7	5	70	7	7
29	820405	65	F	B	7	6	60	8	8
30	797025	60	F	B	6	4	56	6	lost at followup
31	802754	50	M	B	6	5	48	7	7
32	804663	60	F	B	7	4	55	5	5
33	805960	35	F	B	6	4	75	6	6
34	814100	20	F	B	8	7	50	6	6
35	815197	30	F	B	7	6	55	5	5
36	815910	59	M	B	7	4	45	6	6
37	819254	60	F	B	6	4	40	7	lost at followup
38	819251	62	M	B	7	5	65	6	6
39	819829	58	F	B	8	7	55	6	6