

---

**DIAGNOSTIC EFFICACY OF MAGNETIC RESONANCE  
VENOGRAPHY IN PATIENTS OF CEREBRAL VENOUS  
THROMBOSIS – A CROSS SECTIONAL STUDY**

---

**By**

**Dr. AHAMMED KABEER. P**

**DISSERTATION**

*Submitted to the*

*K. L. E. University, Belgaum, Karnataka*

*In partial fulfillment*

*of the requirements for the award of the degree of*

**M.D. (GENERAL MEDICINE)**

Under the Guidance of

**Dr. Rekha Patil M.D.**

**Professor**

---

DEPARTMENT OF GENERAL MEDICINE,  
JAWAHARLAL NEHRU MEDICAL COLLEGE, BELGAUM - 10

**MAY – 2009**

**K.L.E. UNIVERSITY, BELGAUM, KARNATAKA**

**DECLARATION BY THE CANDIDATE**

*I hereby declare that this dissertation entitled “**DIAGNOSTIC EFFICACY OF MAGNETIC RESONANCE VENOGRAPHY IN PATIENTS OF CEREBRAL VENOUS THROMBOSIS - A CROSS SECTIONAL STUDY**” is a Bonafide and Genuine Research work carried out by me under the Guidance of **Dr. Rekha Patil**<sub>M.D.</sub> Professor, Department of Medicine, Jawaharlal Nehru Medical College, Nehru Nagar, Belgaum-590 010.*

Date:

Place: Belgaum

**(Dr. Ahammed Kabeer P.)**

**K.L.E. UNIVERSITY, BELGAUM, KARNATAKA**

**CERTIFICATE BY THE GUIDE**

*This is to certify that the dissertation entitled “**DIAGNOSTIC EFFICACY OF MAGNETIC RESONANCE VENOGRAPHY IN PATIENTS OF CEREBRAL VENOUS THROMBOSIS - A CROSS SECTIONAL STUDY**”*

*is a Bonafide Research work done by **Dr. AHAMMED KABEER P.** in partial fulfillment of the requirement for the Degree of **M.D. (General Medicine)**, Examination to be held in May 2009.*

**Date :**  
**Place :** Belgaum

**Guide**  
**Dr. REKHA PATIL<sub>M.D.</sub>**  
Professor,  
Department of General Medicine,  
J. N. Medical College, Belgaum – 10

**K.L.E. UNIVERSITY, BELGAUM, KARNATAKA**

**CERTIFICATE BY THE Co-GUIDE**

*This is to certify that the dissertation entitled “**DIAGNOSTIC EFFICACY OF MAGNETIC RESONANCE VENOGRAPHY IN PATIENTS OF CEREBRAL VENOUS THROMBOSIS - A CROSS SECTIONAL STUDY**” is a Bonafide Research work done by **Dr. AHAMMED KABEER P.** in partial fulfillment of the requirement for the Degree of **M.D. (General Medicine)**, Examination to be held in May 2009.*

**Date :**  
**Place :** Belgaum

**Co-Guide**  
**Dr. ASHWIN S. PATIL** M.D.  
Associate Professor,  
Department of Radio Diagnosis,  
J. N. Medical College, Belgaum – 10

**K.L.E. UNIVERSITY BELGAUM, KARNATAKA**

**ENDORSEMENT BY THE HOD, PRINCIPAL/HEAD OF THE  
INSTITUTION**

*This is to certify that the dissertation entitled “**DIAGNOSTIC EFFICACY OF MAGNETIC RESONANCE VENOGRAPHY IN PATIENTS OF CEREBRAL VENOUS THROMBOSIS - A CROSS SECTIONAL STUDY**” is a Bonafide Research work done by **Dr. AHAMMED KABEER P.** under the Guidance of **Dr. Rekha Patil<sub>M.D.</sub>**, Professor, Department of General Medicine, Jawaharlal Nehru Medical College, Nehru Nagar, Belgaum-590010.*

Seal & Signature of the  
HOD

**Dr. V.A. Kothiwale**  
Professor & Head,  
Department of General Medicine  
J. N. Medical College,  
Nehru Nagar, Belgaum-590 010.

**Date:**  
**Place:** Belgaum

Seal & Signature of the  
Principal

**Dr. V. D. Patil<sub>M.D. D.C.H</sub>**  
Principal,  
J. N. Medical College,  
Nehru Nagar, Belgaum-590 010.

**Date:**  
**Place:** Belgaum

**K.L.E. UNIVERSITY BELGAUM, KARNATAKA**

**COPYRIGHT**

**Declaration by the Candidate**

*I hereby declare that the KLE University, Belgaum, Karnataka shall have the rights to preserve, use and disseminate this dissertation in print or electronic format for academic / research purpose.*

Date:

Place : Belgaum

Signature of the Candidate

**(Dr. AHAMMED KABEER P.)**

**© K.L.E. University Belgaum, Karnataka**

## ACKNOWLEDGEMENT

I am extremely grateful to my respected teacher and Guide Dr. Rekha Patil M.D. Professor, Department of Medicine, J. N. Medical College, Belgaum, for her able guidance, supervision, invaluable suggestions, and kind help, rendered throughout the course of my study, and in the preparation of this dissertation.

I sincerely thank my Co-guide Dr. Ashwin S. Patil, Associate Professor, Department of Radio Diagnosis, J. N. Medical College, Belgaum, for his constant support

I am extremely grateful to Dr. V. A. Kothiwale, Professor and Head, Department of General Medicine, J. N. M. C., Belgaum for his timely guidance, encouragement and help in preparing this dissertation.

It is with great respect that I express my thanks to Dr. S. B. Kalagate, Dr. V. G. Somannavar, Dr. B. Srinivas. Dr. P. K. Phadnis, Professors, Department of Medicine, J. N. Medical College, Belgaum, for their constant inspiration and help.

I am thankful to Dr. K. Ravishankar Naik D. M., Neurology, Professor and H.O.D. Department of Neurology, Dr. A. O. Saroja M.D., D. M., Neurology, Associate Professor, Department of Neurology, Dr. Kutub Makandar M.D. D. M., Neurology Associate Professor, Department of Neurology for their constant help during the course.

I am very grateful to The Principal Dr. V. D. Patil, J. N. Medical College, Belgaum, for his support and permission to undertake this study.

I also thank Dr. M. V. Jali, MD & CEO, K.L.E'S Hospital and MRC, for allowing me to utilize the clinical material for this dissertation.

My sincere thanks to Dr. Arathi Darshan Dr. Neeta Deshpande, Dr. I. B. Ganiger, Associate Professors, Department of Medicine, J. N. Medical College, Belgaum, for their constant help.

My special thanks to Dr. Prakash B, Dr. Naveen Angadi, Dr. Anjali M, Dr. Dyanesh Morkar, Dr. Raju Badiger and Dr. Mallikarjun B., Assistant Professors for their encouragement and timely advise during the study.

I would like to acknowledge the tireless work of Mr. Mahesh Desai of Malta Computers for excellent data processing and completion of this manuscript.

I wish to offer my thanks to Department of Medical Education for their valuable information and support.

No amount of words can measure up to the deep sense of gratitude and thankfulness that I feel towards my parents Mr. SAIDALAVI HAJI and Mrs. FATHIMA SAIDALAVI whose cherished blessings and countless sacrifices are behind whatever success I have achieved in my life.

I whole-heartedly thank my wife Mrs. Zeenath Sani and my daughter Diya Kabeer for their inspiration and love.

I would also like to thank all my colleagues for their constant help during the study.

Last but not the least, this acknowledgement is incomplete if I fail in my duty to thank all the patients who have whole heartedly participated in the study and have made the study complete

I bow my head in respect before God, the Almighty.

Dr. Ahammed Kabeer. P.

## ABBREVIATIONS

APLAS	Antiphospholipid antibody syndrome
CSF	Cerebrospinal fluid
CSVT	Cerebral venous sinus thrombosis
CT	Computed tomography
CVT	Cerebral venous thrombosis
DSA	Digital subtraction angiography
MRA	Magnetic resonance angiography
MRI	Magnetic resonance imaging
MRV	Magnetic resonance venography
OCP	Oral contraceptive pill

## ABSTRACT

**Background and objectives :** To detect the diagnostic efficacy of magnetic resonance venography in clinically suspected cases of cerebral venous thrombosis.

**Methods :** Magnetic resonance imaging and magnetic resonance venography was performed in 30 patients, who were clinically suspected of cerebral venous thrombosis admitted in KLES Dr.Prabhakar Kore Hospital and MRC, Belgaum, over a period of one year.

**Results :** Out of 30 patients 24 patients (80%) had venous infarct on MRI, all 30 patients had venous thrombosis on MRV study. Out of 30 patients 18 were (60%) females and 12 were males. CVT was common in age group of 21 to 40 years. Alcohol was the commonest cause of CVT in males 5 (16.66%). CVT was common in post partum females 4 (13.33%). Dehydration was next common cause in both males and females 4 (13.3%). Cause of CVT was unknown in 8 patients (26.66%). Headache was the commonest symptom present in 28 patients (93.33%). Next common symptoms were seizures 20 (66.6%), vomiting and altered sensorium in 15 patients (50%) and neurodeficit in 10 patients (33.3%).superior sagittal sinus was involved in 19 patients (63.33%), transverse sinus involvement in 12 patients (40%) followed by sigmoid sinus involved in 11 patients (36.66%). Hemorrhagic venous infarct was seen in 15 patients (50%). Non hemorrhagic venous infarct was present in 9 patients (30%). Cerebral oedema was present in 14 patients (46.66%). one sinus

involvement was present in 11 patients (36.66%), two sinus involvement in 8 patients (26.6%), three sinus involvement in 8 patients (26.66%) and four sinus involvement in 3 patients (10%). Out come of CVT depends on number and extent of sinus involvement. 14 patients (46.6%) had fully recovered with no residual disability and 3 patients (10%) expired. Glasgow coma scale below 6 associated with poor outcome.

**Interpretation & Conclusion :** Magnetic resonance venogram is the only non invasive, safe, in-vivo diagnostic modality for cerebral venous thrombosis.

**Key words. :**

Cerebral venous thrombosis (CVT) or cerebral venous sinus thrombosis (CSV), Magnetic resonance imaging (MRI), Magnetic resonance venography (MRV), Digital subtraction angiography (DSA).

## TABLE OF CONTENTS

<b>Sl. No.</b>	<b>Particulars</b>	<b>Page No.</b>
1.	Introduction	1
2.	Objectives	3
3.	Review of literature	5
4.	Methodology	42
5.	Results	44
6.	Discussion	72
7.	Conclusion	81
8.	Summary	82
9.	Bibliography	84
10.	Annexures	97

## LIST OF TABLES

Table No.	Particulars	Page No.
1.	Sex wise distribution of patients with cerebral venous thrombosis	44
2.	Age wise distribution of patients with cerebral venous thrombosis	46
3.	Age & Sex wise distribution of the patients with CVT	48
4.	Distribution of symptoms in CVT patients	50
5.	Duration of symptoms prior to admission in patients with CVT	52
6.	Distribution of patients based on the signs in CVT	54
7.	MRI findings in CVT Patients	56
8.	MRV finding in patients with CVT (Thrombosis)	58
9.	Distribution of patients with CVT depending on the number of sinuses involved.	60
10.	Correlation of the symptoms of CVT patients to their MRV findings	62
11.	Distribution of patients depending on the aetiology	64
12.	Outcome of the CVT patients at the time of discharge (as per modified RANKIN SCALE)	68

## LIST OF GRAPHS

<b>Graph No.</b>	<b>Particulars</b>	<b>Page No.</b>
1.	Sex wise distribution of patients with cerebral venous thrombosis	45
2.	Age wise distribution of patients with cerebral venous thrombosis	47
3.	Age & Sex wise distribution of the patients with CVT	49
4.	Distribution of symptoms in CVT patients	51
5.	Duration of symptoms prior to admission in patients with CVT	53
6.	Distribution of patients based on the signs in CVT	55
7.	MRI findings in CVT Patients	57
8.	MRV finding in patients with CVT (Thrombosis)	59
9.	Distribution of patients with CVT depending on the number of sinuses involved	61
10.	Correlation of the symptoms of CVT patients to their MRV findings	63
11.	Distribution of patients depending on the aetiology	65
12.	Out of the CVT patients at the time of discharge (as per modified RANKIN SCALE)	69
13.	Correlation of Glasgow Coma Scale at Admission with outcome In CVT Patients	71

## INTRODUCTION

Cerebral veno-occlusive disease is an elusive, often under diagnosed cause of acute neurological deterioration. Because clinical signs and symptoms are often non-specific, imaging is critical to the diagnosis of this disorder.<sup>1</sup> Cerebral venous sinus thrombosis (CVST) is a common medical problem in India which has serious clinical consequences. It is often clinically unsuspected and has varied clinical presentation. It is thus a challenging condition.

CVT is remarkable by its large spectrum of clinical presentation, its highly variable mode of onset, its numerous causes, its unpredictable but usually favourable outcome. So CVT does remain a diagnostic and therapeutic challenge for clinician.<sup>2</sup>

Cerebral vein and sinus thrombosis (CSVT) predominates in children, young and middle-aged adults. Some of their associated conditions, such as pregnancy, puerperium, and use of oral contraceptives,<sup>3</sup> are no longer present in elderly patients, whereas others such as malignancy and dehydration may be more frequent. The clinical features, associated conditions, outcome, and prognostic factors in elderly CVT patients have not been described previously.<sup>3</sup>

CVST is a relatively under diagnosed and under treated condition. Exact incidence of CVT is still under debate because of scarcity of scientifically planned epidemiological studies in the available literature. The studies have demonstrated 5-15% mortality rate.<sup>4</sup>

The role of Neuroimaging techniques, including CT, MRI, and magnetic resonance venography (MRV) are crucial for the diagnosis of CVT.<sup>5,6</sup>

Recently, the mortality rate of CVT has been reported to be less than 10%.<sup>7,8</sup> There is, however, a subgroup of patients with a high mortality (69%),<sup>7</sup> characterized by a rapid progressive clinical deterioration. There are no clear clinical or neuroradiologic signs that can differentiate patients with a poor prognosis from those with a good prognosis.<sup>6,7</sup>

In the past, the diverse clinical presentation has made CVST a difficult and often delayed diagnosis; however an increased awareness and developments in non-invasive imaging techniques have led to earlier and more frequent detection. This is important, since early treatment may prevent serious neurological sequelae.<sup>8</sup>

So there is reason to evaluate newer methods using advanced radiological modality to diagnose the condition early and aid in its effective treatment.

With the introduction of helical Computed tomography (CT), the intracranial venous system can be reliably assessed using CT venography.<sup>9</sup> Conventional CT techniques miss the presence of CSVT in 16-40% of children and adults and underestimate both the extent of sinus involvement and the presence and extent of venous infarcts<sup>6,8,10</sup> Additionally, CT can yield false-positive results.<sup>11</sup>

CT can yield false-positive results in patients with<sup>12</sup>

1. Subarachnoid and subdural hemorrhage as well as subdural epidural abscess causing pseudo empty delta sign.
2. Filling defects in the sinus like prominent arachnoid granulations, CSF space.

Cerebral angiography is gold standard for diagnosis of CSVT. But sometimes even selective injections in the common or internal carotid artery may not completely opacity the dural sinus and angiography may cause local thrombosis at the site of catheter insertion, may be seen on serial imaging, it is invasive, can be time consuming and carries 1.5-2% risk of significant morbidity and mortality.<sup>13</sup>

These drawbacks of the CT and conventional angiography have led to development of non-invasive technique. Over the last decade magnetic resonance imaging (MRI) has been shown to be an effective alternative to this method and with the use of MVR venographic (MRV) techniques, is fast and becoming one of modality of choice for diagnosis and evaluation of dural sinus and cerebral venous thrombosis, whenever MRI facilities are available.<sup>14</sup>

Magnetic resonance imaging and magnetic resonance venography is extremely sensitive in identifying underlying parenchymal alterations in cerebral venous thrombosis. The combination of MRI and MRV allows for an accurate diagnosis of CVT and is now the gold standard in the investigation of this disease.<sup>15</sup>

The study will give efficacy of magnetic resonance venography.

**OBJECTIVE**

To detect the diagnostic efficacy of magnetic resonance venography in clinically suspected cases of cerebral venous thrombosis.

## **REVIEW OF LITERATURE**

### **HISTORICAL REVIEW OF CEREBRAL VENOUS THROMBOSIS**

In 1925, Ribes described the clinical history of a 45 year old man who died after six month history of headache, epilepsy and delirium, suffering from the disseminated malignancy. Post mortem examination showed thrombosis of Superior sagittal sinus (SSS), the left lateral sinus (LS), and a cortical vein in the parietal region.<sup>16</sup> The first ever description of superior sagittal sinus (SSS) thrombosis occurring in puerperium was described in one study.<sup>17</sup> Later another of monograph on CVT stated that aseptic thrombosis is not an uncommon entity especially in children, puerperium, and elderly.<sup>18</sup>

Since then, numerous case reports and series have been published, most of them from autopsy material. They led to the classical description of a rare and sever disease characterized clinically by headache, papilledema, seizures, focal deficits, progressive coma and death and pathologically by hemorrhagic infarction that was thought to contraindicate the use of anticoagulants.

With the advent of three dimensional M.R. Flow imaging it has been shown that the prevalence of CVT is more common than reported previously and carries a less serious prognosis. This early and the history of CVT have been extensively covered in two excellent French and English monographs. However, angiography and more recently magnetic resonance imaging (MRI) and magnetic resonance

angiography (MRA) have made intra vitamin diagnosis possible, and evidence has accumulated that many patients do not fall in to this classical description.<sup>19</sup>

Classically, dural venous sinus thrombosis has been described as a rare and usually fatal condition. Morbidity occurs when a thrombus occludes a major dural sinus or prpropagated in to cortical vein, thus impairing the venous drainage of the brain. The clinical presentation includes non specific symptoms such as headache, seizures and focal neurological complaints. The diagnosis is often overlocked and early cases usually were discovered at autopsy.<sup>20</sup> Conventional cerebral angiography,<sup>21</sup> computed tomography<sup>22</sup> intravenous digital angiography,<sup>23</sup> magnetic resonance imaging,<sup>24</sup> and recently, MR venography,<sup>25</sup> have increased the ability to detect his condition. Dural sinus thrombosis is now thought to occur more often than previously assumed<sup>26</sup>

While the mortality rate in recent studies has been reported as low as 10%<sup>26,27</sup> Survivors often have clinically significant morbidity. Reports on the efficacy of heparin anti coagulation in dural sinus thrombosis have established administration of systemic heparin as the standard therapy.<sup>28</sup> Smaller series and case reports describe a dramatic response to locally infused thrombolytic agents such as urokinase in sever acute cases.<sup>29,30,31</sup> The availability of successful treatment has increased the need for prompt and accurate diagnosis.

Early and accurate diagnosis of cerebral venous thrombosis (CVT) is possible with the help of computed tomography (CT) scan and magnetic resonance

imaging (MRI). Empty sign on post contrast CT is present in only up to 30% of the cases. The role of CT venography is not yet established, but it is emerging as an effective modality for diagnosis of CVT. T2 MRI sequence is superior to spin echo in detecting CVT and small hemorrhages. MR venography is considered the technique of choice for diagnosis and follow-up of CVT, but in certain cases, MRI could be superior as it shows the thrombus itself and not just the absence of signal as seen on MR venography. Diffusion-weighted imaging is a relatively new MRI technique that is extremely sensitive in detecting acute arterial strokes and can distinguish cytotoxic and vasogenic edema. The presence of hyperintense signal on diffusion-weighted imaging in the occluded veins or sinuses at the time of diagnosis may predict a low rate of vessel recanalization. Contrast angiography should be strongly considered if isolated cortical vein thrombosis is suspected.<sup>32</sup>

## **HISTORICAL REVIEW OF MRI AND MR VENOGRAM**

MRI is based on the principles of nuclear magnetic resonance (NMR), a spectroscopic technique used by scientists to obtain microscopic chemical and physical information about molecules. The technique was called magnetic resonance imaging rather than nuclear magnetic resonance imaging (NMRI) because of the negative connotations associated with the word nuclear in the late 1970's. MRI started out as a tomographic imaging technique, that is it produced an image of the NMR signal in a thin slice through the human body. MRI has advanced beyond a tomographic imaging technique to a volume imaging technique.

The Concept of Nuclear Magnetic Resonance (NMR) was described by Dutch Physicist C.J Goiter in 1936. Felix Bloch and Edward Purcell, both of whom were awarded the Nobel Prize in 1952, discovered the magnetic resonance phenomenon independently in 1946.<sup>33</sup> In the period between 1950 and 1970, NMR was developed and used for chemical and physical molecular analysis.

In 1971 Raymond Damadian was among the first to suggest the use of NMR in medical diagnosis and he showed that the nuclear magnetic relaxation times of tissues and tumors differed, thus motivating scientists to consider magnetic resonance for the detection of disease. In 1973 the x-ray-based computerized tomography (CT) was introduced by Hounsfield. This date is important to the MRI timeline because it showed hospitals were willing to spend large amounts of money for medical imaging hardware. Lauterbur published the first NMR image on small test tube samples in 1972 at Stony Brook, New York, He was able to generate the first two-dimensional NMR image of proton density and spin lattice relaxation time. Lauterbur coined the term "Zeugmatography" (From Greek Zeugma, meaning that which joins together) for his technique. He used a back projection technique similar to that used in CT.<sup>34</sup> In 1975 Richard Ernst proposed magnetic resonance imaging using phase and frequency encoding, and the Fourier Transform. This technique is the basis of current MRI techniques.<sup>35</sup>

It was in 1976 and 1977, when first images of human anatomy were produced by groups at Nottingham University. In 1977, Raymond Damadian

produced whole body image using field-focusing nuclear magnetic resonance. In this same year, Peter Mansfield developed the echo-planar imaging (EPI) technique.<sup>36</sup> This technique will be developed in later years to produce images at video rates (30 ms / image).

The multiplanar facility of MRI (Magnetic Resonance Imaging) was first demonstrated in 1980 by Hawkes, who also reported the first intracranial pathology. Edelstein and coworkers demonstrated imaging of the body using Ernst's technique in 1980. A single image could be acquired in approximately five minutes by this technique. In 1981, General Electric Oxford Instruments produced images using high field (1.5.T) whole body magnets. By 1986, the imaging time was reduced to about five seconds, without sacrificing too much image quality. The same year people were developing the NMR microscope, which allowed approximately 10 Dm resolution on approximately one cm samples. In 1987 echo-planar imaging was used to perform real-time movie imaging of a single cardiac cycle.<sup>37</sup> In this same year Charles Dumoulin was perfecting magnetic resonance angiography (MRA), which allowed imaging of flowing blood without the use of contrast agents.<sup>38</sup> Since then there has been widespread clinical application with many sub modalities like multislice, multiecho, spectroscopy, angiography, fast scanning, surface coil etc.

In 1991, Richard Ernst was rewarded for his achievements in pulsed Fourier Transform NMR and MRI with the Nobel Prize in Chemistry. In 1992 functional MRI (fMRI) was developed.<sup>39</sup> This technique allows the mapping of the function of

the various regions of the human brain. Five years earlier many clinicians thought echo-planar imaging's primary applications were to be in real-time cardiac imaging. The development of MRI opened up a new application for EPI in mapping the regions of the brain responsible for thought and motor control. In 1994, researchers at the State University of New York at Stony Brook and Princeton University demonstrated the imaging of hyperpolarized  $^{129}\text{Xe}$  gas for respiration studies.<sup>40</sup>

Interventional MRI was first shown by Lufkin et al in 1995 and hold great promise for diagnosing and treating patients within a single visit. Functional MR of brain which uses endogenous blood oxygen level dependent (BOLD) changes to map activities such as vision, motion and even memory formation was introduced by Ogawa et al in 1991 developed by Rosen et al. Functional MR of pulmonary ventilation has been developed by Middleton et al, McFall et al, Ebert et al and others using hyperpolarize MR imaging. Improvements in diffusion, perfusion, flow, spectroscopy anetization transfer methods from large number of groups are fascinating new insight cardiac and cerebral pathology.<sup>41</sup>

New parallel encoding methods used with phased array radiofrequency coils such as SMASH introduced by Sodickson et al in 1997 and SENSE introduced by Pruessmann et al in 1999 are changing the rules of imaging speed with MRI. As we enter twenty first MRI and spectroscopy development is increasing pace and it is anticipated that will continue with vigour.

In 2003, Paul C. Lauterbur of the University of Illinois and Sir Peter Mansfield of university of Nottingham were awarded the Nobel Prize in Medicine for their discoveries concerning magnetic resonance imaging. MRI is clearly a young, but growing since.

MR imaging is currently the diagnostic study of choice in CS VT because of its to visualize flow, thrombus, infarction, and any underlying abnormality.<sup>42</sup>

TOF MR Angiography (MRA) is based on principle of flow-related enhancement and highlights differences in magnetization between nuclei in flowing blood and those in stationary tissue. TOF MR angiographic methods have included both 2D and 3D techniques, the latter is considered much inferior when visualizing the intracranial venous system primarily because of signal loss from in-plane saturation.<sup>43</sup>

Three-dimensional phase contrast MRA is based on the principle of using velocity induced phase shifts to depict flowing blood. In contrast with stationary tissue, spins moving through a magnetic field will experience a phase shift that is proportional to the velocity of flow, amplitude of the bipolar gradients, and time interval between the gradient lobes. The major advantages of PC MRA are the greater suppression of background (stationary) tissues, and the ability to quantify flow and determine flow direction. Although 3D PC MRA is comparable to 2D TOP techniques in visualization of intracranial venous structures, its disadvantages include relatively long acquisition times and the need to predict the optimal VENC which is generally not known in advance.<sup>43</sup>

Recently, High resolution 3D contrast-enhanced magnetization prepared rapid acquisition gradient-echo (MPRAGE) imaging has been used as a means to depict intracranial dural sinus thrombosis.<sup>44</sup> Intradural thrombus, which is generally hypo- or isointense relative to brain parenchyma, has high contrast relative to the high signal intensity of flowing blood on 3D contrast-enhanced MPRAGE images.<sup>45</sup> This pulse sequence, which uses a 1.25-mm section thickness and 3D data set, would also be expected to precisely depict normal structures within dural sinuses and distinguish normal structures from occlusive disease.

A more widely used modification of MR imaging is a dynamic gadolinium bolus-injection technique in which the acquisition of images is triggered by the arrival of the gadolinium bolus at the vessel of interest. At the University of Toronto, we have recently started using such a three-dimensional auto-triggered, elliptic centric-ordered (ATECO) gadolinium-enhanced MR angiogram with great success in studying the cerebral venous system. In studies comparing the latter technique with conventional angiography, the morphology of the dural venous sinuses is equally well-visualized.<sup>44</sup>

MR imaging is the preferred technique for visualizing brain tissue changes. The sensitivity of MR imaging offers over CT. In neonates, however, unmyelinated brain presents challenges, to T2 weighted imaging of venous infarcts. Monitoring neonates and sick children in MR imaging requires the availability of specialized MR-compatible equipment and trained personnel. Sedation issues and the availability of urgent/emergent time slots for MR imaging are problematic. For the

direct imaging of thrombosis within veins or sinuses, CT venography with multi-slice CT is comparable to gadolinium enhanced MR venography in most stages of evolution of CSVT, and both these techniques are more accurate than TOF MR Venography.

The diffusion weighted imaging (DWI) is known to be more sensitive than T2- weighted images in arterial ischemic stroke. There has been only limited experience with diffusion-weighted imaging with CSVT; however, the latter technique has shed valuable insights into the presence of cytotoxic and vasogenic edema during venous infarction in adults with CSVT.<sup>46</sup> In CSVT in adults, diffusion-weighted imaging/apparent diffusion coefficient (ADC) pattern is reported to be more heterogeneous. It is reported that areas of increased or normal ADC without hemorrhage have a good prognosis and, unlike arterial stroke, areas with initially decreased ADC values can also be reversible.<sup>47</sup>

#### **ANATOMY OF INTRACRANIAL VENOUS SYSTEM :**

Knowledge of the anatomy of intracranial venous system is essential in evaluating patients with venous sinus thrombosis since symptoms associated with conditions to area of thrombosis.

The intracranial venous system is a complex three dimensional structure that is often asymmetric and considerably more variable than the arterial anatomy. More detailed description of its many possible variants requires a level of embryologic understanding. We discuss the intracranial venous system in a craniofugal approach,

moving from deep to cortical, and finally to dural. In this section, the supratentorial compartment is considered first, followed by the infratentorial compartment.

### **DEEP VENOUS SYSTEM**

The deep venous system is concerned with centripetal venous drainage of deep cerebral white matter and basal ganglia and, using a classification suggested by Lasjaunias, can be considered at two separate levels: (1) the internal cerebral vein, the basal vein (of Rosenthal), and the great cerebral vein (of Galen), and (2) the trans cerebral venous system. These two levels operate in a hemodynamic balance such that some overlap and variation in their venous drainage is common.

The paired internal cerebral veins are located near the midline within the tela choroidea in the roof of the third ventricle. The internal cerebral vein originates at the interventricular foramen of Monro where it is formed by the confluence of the septal, anterior caudate, ventricular, choroidal, and terminal (thalamostriate) subependymal veins, although anatomical variation in this region is common. The internal cerebral veins run posteriorly to where they unite in the rostral part of the quadrigeminal cistern and form the great cerebral vein (of Galen).<sup>48</sup>

The septal vein drains the deep structures of the frontal lobes and courses around the anteromedial aspect of the lateral ventricle before passing posterior to the foramen of Monro to join the internal cerebral vein. The caudate nucleus is drained by several caudate veins, which drain into the thalamostriate vein or directly into the internal cerebral vein. The thalamostriate vein drains the posterior frontal and

anterior parietal lobes, caudate nucleus, and internal capsule, and is therefore usually a prominent tributary feeding the internal cerebral vein. The choroid plexus is drained by two choroidal veins (superior and inferior) that empty either directly into the internal cerebral vein, or first to the thalamostriate vein.<sup>48</sup>

The basal vein of Rosenthal originates deep within the sylvian fissure, near the medial part of the anterior temporal lobe, and receives veins draining the insula, cerebral peduncles, and multiple cortical (temporal) tributaries. The basal vein courses posteriorly at the base of the brain and curves around the cerebral peduncles to its junction with the great cerebral vein (of Galen) or internal cerebral vein. The basal vein has important anastomoses with its openings into the deep middle cerebral vein anteriorly, great cerebral vein (of Galen) posteriorly, and petrosal veins inferiorly. The great cerebral vein (of Galen) is a short, unpaired, midline structure that curves posteriorly beneath the splenium of the corpus callosum. It unites with the inferior sagittal sinus at the tentorial apex and forms the straight sinus.<sup>48</sup>

The transcerebral veins are a group of superficial and deep medullary veins that drain the cerebral hemispheric white matter. The transcerebral veins are typically not visualized, however, during angiography because of their small caliber unless certain conditions are met that alter their normal hemodynamic state.<sup>48</sup>

## **SUPERFICIAL CEREBRAL VEINS**

The superficial cerebral veins course over the surface of the brain, draining the cortex and a portion of the subjacent white matter. Despite a highly variable

appearance, several large cortical veins can often be identified individually and include the (1) superficial middle cerebral vein, (2) superior anastomotic vein and (3) inferior anastomotic vein. The latter two anastomotic veins are often in a reciprocal relationship such that if one is dominant, the other is usually hypoplastic or absent. <sup>48</sup>

The superficial middle cerebral vein runs anteriorly along the lateral (sylvian) fissure and receives smaller veins draining the lateral surface of the hemisphere. This large vein curves around the anterior temporal pole and either drains medially into the cavernous sinus or inferiorly into the pterygoid plexus. Anastomotic channels allow the superficial middle cerebral vein to drain in other directions. These include the superior anastomotic vein (of Trolard), which opens into the superior sagittal sinus, and the inferior anastomotic vein (of Labbe), which opens into the transverse sinus. There are a variable number of other superiorly directed superficial cortical veins, often 10-12 in number, that also empty into the superior sagittal sinus along with the vein of Trolard. <sup>48</sup>

### **DURAL VENOUS SINUSES**

The cerebral veins empty into the venous sinuses, from which blood eventually flows into the internal jugular veins. Dural venous sinuses are enclosed between the periosteal and meningeal layers of dura, and they lack valves.

**SUPERIOR SAGITTAL SINUS** : It lies along the attached border of the falx cerebri and extends from the foramen cecum to the torcular Herophili. As it extends

posteriorly, the superior sagittal sinus increases in caliber as it collects the superficial cerebral veins draining the cerebral convexities. Arachnoid granulations, contained within venous lacunae, are found protruding into the superior sagittal sinus along its course and may produce normal filling defects on imaging studies.<sup>48</sup>

**INFERIOR SAGITTAL SINUS:** It lies along the inferior free margin of the falx cerebri and drains the falx, anterior part of the corpus callosum, and medial aspects of the cerebral hemispheres. The inferior sagittal sinus extends anteriorly and is joined by the great cerebral vein (of Galen) to form the straight sinus.

**STRAIGHT SINUS:** Lies within the attachment of the falx cerebri and tentorium cerebelli. It runs posteroinferiorly, terminates at the internal occipital protuberance, and is usually continuous with the left transverse sinus. The torcular Herophili confluence of sinuses; is formed by the union of the superior sagittal sinus, straight sinus, and transverse sinuses, although the confluence is often asymmetric and quite variable in appearance.<sup>48</sup>

**TRANSVERSE SINUSES :** It lies along the attached margin of the tentorium cerebelli within a groove on the occipital bone. Each transverse sinus courses anterolaterally and, on reaching the base of the petrous portion of the temporal bone, turns inferomedially to form the sigmoid sinus that lies in the sigmoid sulcus of the temporal bone. The transverse sinus receives several important veins from the inferolateral temporal and occipital lobes, the cerebellum, and, when present, the anastomotic cortical vein of Labbe. The transverse sinuses are commonly

asymmetric, with the right transverse sinus being dominant in the majority of cases.

Other common variations include a unilateral atretic segment and normal intraluminal filling defects resulting from arachnoid granulations, similar to those seen in the superior sagittal sinus. The sigmoid sinuses represent the anteroinferior continuation of the transverse sinuses and, in turn, drain into the jugular bulbs and terminate by becoming the internal jugular veins at the Jugular foramen.<sup>48</sup>

**CAVERNOUS SINUSES** : are situated on each side of the sphenoid body and represent an important confluence of intracranial and extracranial venous structures. Each cavernous sinus is a multi-compartmental extradural space that extends from the superior orbital fissure to the petrous portion of the temporal bone. This sinus encloses the cavernous segment of the internal carotid artery and the abducens nerve, whereas the lateral wall of the sinus contains the oculomotor, trochlear, and ophthalmic division of the trigeminal nerves between its dural leaves. The superior petrosal sinus extends from the posterior aspect of the cavernous sinus to the transverse sinus, running along the attachment of the tentorium cerebelli to the petrous part of the temporal bone.<sup>48</sup>

**INFERIOR PETROSAL SINUS** : also extends from the posterior aspect of the cavernous sinus but runs posterolaterally in a groove along the petro-occipital fissure to usually terminate by joining the jugular bulb.

**SPHENOPARIETAL SINUS** : It lies along the lesser wing of sphenoid and drains usually the superficial middle cerebral (sylvian) vein into the cavernous sinus. Less

common variations include the sphenoparietal sinus bypassing the cavernous sinus to drain into either the pterygoid plexus, or inferior petrosal or transverse sinus. The small variable occipital sinus lies in the midline at the attachment of the falx cerebelli, and it extends from the foramen magnum to drain upward into the torcular Herophili. Alternatively, with variant anatomy, the occipital sinus may drain toward the foramen magnum or into either the jugular fossa or suboccipital veins.<sup>48</sup>

### **INFRATENTORIAL VEINS**

The veins of the posterior fossa collect into three major drainage systems: (1) superiorly into the vein of Galen and related tributaries, (2) anteriorly into the petrosal sinuses, and (3) posteriorly into dural sinuses bordering on or between the leaves of the tentorium cerebelli. In contrast with the dural sinuses and supratentorial veins, MR venography does not commonly visualize most of these deep and superficial venous structures such that only the most important ones are discussed here and the reader is referred to previous works based on DSA technique for a more complete discussion.

The precentral cerebellar vein originates in the midline, between the lingula and central lobule of the cerebellar vermis, and runs superiorly, paralleling the roof of the fourth ventricle before opening into the great cerebral vein (of Galen). The superior vermian vein collects numerous small intrafissural venous tributaries of the upper vermis, and it empties into the great cerebral vein (of Galen), either directly or after uniting with the precentral cerebellar vein to first form the superior cerebellar

vein. The anterior pontomesencephalic vein runs along the anterior surface of the pons and commonly drains superiorly via the peduncular vein into the posterior mesencephalic vein, which in turn runs around the upper midbrain to drain into the great cerebral vein (of Galen). The petrosal vein lies in the cerebellopontine angle cistern and receives drainage from the anterior cerebellar veins, in addition to other venous tributaries from the pons and medulla, before emptying into the middle portion of the superior petrosal sinus. The inferior vermian veins are important paired paramedian veins that course posterosuperiorly along the inferior vermis and open into the tentorial sinuses. Each receives multiple small venous tributaries draining the inferior cerebellar hemispheres.<sup>48</sup>

#### **AETIOPATHOGENESIS OF CVT :**

More than 100 causes of CVT have been recorded in the scientific literature. Predisposing factors can be identified in up to 80% of patients. However even with extensive investigations, no cause is identified in 20-25% of cases. The host of well known conditions can cause or predispose to CVT. They include all known surgical, gynecologic and medical causes of deep vein thrombosis as well as a number of local or regional causes, either infective or non-infective, such as head trauma, brain tumors and arterial infarcts.<sup>49</sup>

---

---

**RECOGNISED CAUSES AND PREDISPOSING FACTORS OF CEREBRAL  
VENOUS SINUS THROMBOSIS;**

**1. INFECTIVE CAUSES**

- Local :** Penetrating septic head injury
- Intracranial infection: abscess, empyema, meningitis.
- Regional infection: otitis, tonsillitis, sinusitis, stomatitis.
- General :** Bacterial: Septicemia, endocarditis, typhoid, tuberculosis.
- Viral: measles, hepatitis, encephalitis (Herpes, HIV), CMV.
- Parasitic: Malaria, trichinosis.
- Fungal: Aspergillosis.

**2. NON-INFECTIVE CAUSES**

- Local:** Head injury
- Neurosurgery
- Stroke and hemorrhage.
- Space occupying lesions
- Idiopathic intracranial hypertension.
- Systemic :** Infusions via central venous catheter.
- Surgery with immobilisation.
- Hormonal and endocrine causes.
- Cardiac disease.
- Malignancies.
- Severe dehydration.

Inflammatory bowel disease.

Connective tissue diseases.

Behcet's disease.

Sarcoidosis, SLE, Jogens.

Nephrotic syndrome.

**Drugs:**

Oral contraceptive pills.

Hormonal replacement therapy.

Androgens.

L-asparaginase, epsilonaminocaproic acid

Ecstasy.

**Blood Dyscrasias :** Leukemia, Thrombocythemia,

Red blood cell disorders

Sickle cell trait.

Paroxysmal nocturnal hemoglobinuria.

TTP.

**Coagulopathies :** Protein S, C, antithrombin III deficiency.

Factor V Leiden.

Antiphospholipids antibody.

**Others :**

Pregnancy.

Thyrotoxicosis.

Electrocution.

---

**Idiopathic :** Although infections still constitute the major identifiable cause and cavernous sinus is the commonest affected. Usually, following an infection of the middle third of the face due to staphylococcus aureus or sphenoid or ethmoid sinusitis, dental abscess and less often, otitis media.

## **PATHOLOGY**

Blood from the brain drains through small cerebral veins into larger veins such as the vein of Galen. These bigger veins empty into dural sinuses which themselves are drained mostly by the internal jugular veins. The venous territories are less well defined than are arterial territories due to the presence of extensive anastomoses between cortical veins. These allow the development of collateral circulation in the event of an occlusion.

The main cerebral venous sinuses affected by CVST are the superior sagittal sinus (72%) and the lateral sinuses (70%). In about one-third of cases more than one sinus is affected. In further 30% both sinuses and cerebral or cerebellar veins are involved.

Pathophysiologically, there are important differences between arterial and venous thrombosis. CVST has been described as a continuing process in which the balance of prothrombotic and thrombolytic processes is disturbed, leading to progression of the venous thrombus with time. This slow growth of the thrombus and the good collateralizations of the venous vessels probably explain the usually gradual onset of symptoms, frequently over weeks and months. Sudden onset,

however, has been described. From the large number of patients with complete reversibility of their neurological deficit, it can be inferred that there must be a large area of only transiently and reversibly disturbed cerebral tissue. Recovery appears to be unrelated to the duration of symptoms and signs. Haemorrhagic infarction occurs in approximately 10-50% of cases, principally affecting the cortex and adjacent white matter. This is thought to be primarily due to elevated venous and capillary pressure caused by the persistence of thrombosis. The classical anatomical presentation is that of extensive bilateral hemorrhagic infarcts, located in the superior and internal part of both hemispheres, due to thrombosis of SSS and its tributaries.<sup>50</sup>

#### **INCIDENCE:**

The true incidence of CVT is totally unknown in the absence of epidemiologic studies. Authors found only 16 SSS thromboses in a series of 12,500 autopsies, and another study found only 39 noninfective CVTs in 20 years. One study indicated that CVT was the principal cause of death in only 21.7 persons / year in England and Wales between 1952 and 1961. The more recent publication indicated that CVT was the principal cause of death in only 21.7 persons / year in England and Wales between 1952 and 1961. The more recent publication of large clinical series suggests that the true incidence is much higher than that thought from autopsy series, possibly 10 times higher because of a present mortality rate of approximately 10%.<sup>50</sup>

**RACE :** No racial predilection has been observed.

**SEX :** CVT is believed to be more common in women than men. In series of 110 cases, author found a female to male ratio of 1.2911.

**AGE :** Study reported a uniform age distribution in men with CVT while 61% of women with CVT were aged 20-35 years. This may be related to pregnancy or the use of oral contraceptives.

**CLINICAL PRESENTATION:**

CVST presents with a wide spectrum of symptoms and signs. Headache is the presenting symptom in 70-90% of cases.<sup>26</sup> Focal deficits such as hemiparesis and hemisensory disturbance, seizures, impairment of level of consciousness and papilloedema occur in one-third to three-quarters of cases.<sup>51</sup> The onset may be acute, subacute or insidious, most patients presenting with symptoms which have evolved over days or weeks.<sup>8</sup> There are several typical clinical constellations: 18-38% of cases present with a syndrome resembling benign intracranial hypertension with headache, papilloedema and visual disturbances; up to 75% of cases are characterised by a focal neurological deficit and headache; a third group of between 30% and 50% may present with seizures often followed by a Todd's paresis. Rare but classical clinical pictures are that of superior sagittal sinus thrombosis (4%) with bilateral or alternating deficits and/or seizures and cavernous sinus thrombosis (3%) with chemosis, proptosis and painful ophthalmoplegia. An even less frequent presentation is a rapidly progressive illness with deepening coma, headache, nausea

---

---

and pyramidal signs, due to extensive involvement of the deep cerebral veins.<sup>52</sup>

Thunderclap headache with neck stiffness, mimicking subarachnoid haemorrhage has been described. In the early stages there may be cortical vein thrombosis without sinus thrombosis, the latter developing only later due to progression of the thrombotic process.

Thrombosis of the deep venous system or transtentorial herniation, resulting from cerebral edema, may lead to impairment of consciousness.

A sixth nerve palsy is usually secondary to intracranial hypertension, however, cranial nerve palsies may also result from thrombus extension to the transverse sinus or sigmoid sinus (III - VIII), petrosal sinus (V), and jugular vein (IX-XI).

There is no well-defined clinical syndrome to suggest this, although the rapid onset of focal deficit and/or seizures is thought to be typical of this situation. There is strong overlap between all these outlined groups and patients may progress from one to the other in the course of their illness.

## **PROGNOSIS**

Between 57 and 86% of patients have complete functional recovery. Mortality ranks between 5.5% and 18% in recent series.<sup>53,54</sup> Even though there appears to be no clear correlation between disease severity and outcome, several factors are associated with a poorer prognosis. These are, most importantly, infancy and advanced age, rapid onset with coma and focal deficits, and thrombosis

affecting largely the deep venous system. The underlying condition, particularly sepsis, malignancy, and paroxysmal nocturnal haemoglobinuria adversely affect outcome. Twelve per cent of patients suffer a recurrence of CVST and 14% a different form of venous thrombosis. Seizures rarely occur beyond the acute stages.<sup>54</sup> The outcome of CVST is therefore generally favourable and aggressive and potentially dangerous therapeutic intervention should be confined to those patients who deteriorate rapidly despite heparin or who demonstrate poor prognostic indicators.

### **NEQNATES**

In neonates, the most frequent illness is that of acute illness with seizures. It has been suggested that CVT is important and under recognized cause of seizures in first 2 weeks of life in term infants.<sup>55</sup>

### **COMPLICATIONS**

Increasing venous congestion results in raised dural venous sinus and CSF pressure if collateral venous drainage is insufficient. Parenchymal edema with venous infarction and hemorrhage complicate up to 50% of venous sinus thrombosis.

Pulmonary embolism from a dural sinus thrombosis is uncommon but carries poor prognosis.

Hypopituitarism may result from cavernous sinus thrombosis.

DVST has been cited by several authors as an etiologic association of dural arterio-venous fistulas, although it may be difficult in some cases to ascertain if thrombosis was a primary or secondary event.

Focal seizures with or without secondary generalization may persist following dural sinus thrombosis, requiring continuing anti-epileptic therapy.<sup>56</sup>

## **INVESTIGATIONS IN CVT**

### **MRI AND MRV:**

MRI in conjunction with MRV is both sensitive and specific enough to provide the best noninvasive method of diagnosing cerebral venous thrombosis. The diagnosis usually can be made without intravenous contrast although contrast enhancement can aid in confirming the diagnosis. MR imaging findings are as follows: A thrombus can be directly visualized within a vessel.

Secondary venous infarction and foci of hemorrhage can be seen with gradient echo images. Susceptibility induced signal loss from deoxyhemoglobin provides a basis for detection of even small foci of hemorrhage, which tend to occur in the subcortical white matter, thalami, and basal ganglia.<sup>57</sup>

Dilated venous collaterals such as transcortical medullary veins provide indirect evidence of venous thrombosis. The appearance of intravenous thrombus on conventional MRI depends on the age of the blood clot within the vessels.

In acute venous thrombosis, loss of flow void on T1-weighted images occurs along with hypointensity on T2-weighted images, making the determination of sinus occlusion difficult.

In subacute phase, blood clot can result in loss of normal flow void on T1-weighted images and T1 hyperintensity; conversely, on T2-weighted images blood clot can be of low signal intensity, thus mimicking flowing blood. In this instance, blood is in the intracellular methemoglobin stage. Flow-related enhancement phenomenon created by slow flow can occur in veins and cause T1 hyperintensity.<sup>57</sup>

To circumvent this problem, flow sensitivity imaging techniques can be used (i.e. 2D TOP or Phase contrast MRV) to accurately assess the venous sinuses; 2D TOP MRV pulse sequence is sensitive to slow flow. Maximum signal is produced when blood flows orthogonal to the imaging plane, and since many cerebral veins course in an antero-posterior direction, coronal acquisition is often used with an inferior saturation pulse to eliminate arterial signal.

In MRA, 2D TOP sequence takes less time than PC MRV, however 2D TOP is limited by high signal substances like fat or methemoglobin.

Degree of confidence: Variants of venous anatomy are common, and a hypoplastic sinus or prominent arachnoid granulations may simulate venous sinus thrombosis.<sup>58</sup> With 2D TOP MRV techniques, thrombus in the intracellular or extracellular methemoglobin stage can present with increased signal and falsely simulate blood flow. Phase contrast MRV may avoid this error.

False Positive/Negatives : Hypoplasia or severe attenuation of a transverse sinus, which are normal anatomic variants, may simulate venous sinus thrombosis.<sup>58</sup>

In plane flow related signal loss in 2D TOP MRV also can mimic intravenous thrombus.

This flow related enhancement can be reduced with a "saturation band". High signal can also result from rephasing of spins. Comparison of scans obtained with and without gradient moment nulling techniques may help to identify the artifact.

Prominent arachnoid granulations may simulate thrombus. A careful review of the MRV images and conventional MRI may lead to correct diagnosis.

## **COMPUTED TOMOGRAPHY AND CT VENOGRAPHY**

CT scan with or without contrast injection is usually the first investigation undertaken. It is extremely useful to rule out the many conditions that can mimic CVT. It can occasionally detect lesions that can themselves cause CVT, such as meningiomas, abscesses, sinusitis, or mastoiditis. It is also useful in showing brain or sinus changes suggestive of CVT.

### **DIRECT SIGNS OF CVT:**

**The delta sign :** On noncontrast CT scan, the classic finding is the delta sign, which is observed as a dense triangle (from hyperdense thrombus) within the superior sagittal sinus. However, this is not specific, since high attenuation in the healthy nonthrombosed sinus can be observed occasionally and is common in neonates because of an elevated hematocrit.

---

---

**The empty (reverse) delta sign :** appears after contrast injection and reflect the opacification of collateral vein in the SSS wall contrasting with the non-injection of clot inside the sinus. It is most frequent direct sign. However, it is absent when thrombosis does not affect the posterior third of SSS or when CT is performed in the first five days after onset of symptoms or more than two months later. Its sensitivity and specificity are increased with some technical refinement such as orthogonal sections, different window and level setting and multiplanar reformations.<sup>57</sup>

**The cord sign :** Visible on plain CT represents thrombosed cortical veins. It can also be seen in internal cerebral vein and vein of Galen thrombosis.

**The dense triangle :** also reflects spontaneous SSS opacification by freshly coagulated blood. It is very early sign, extremely rare, difficult to asses.

**INDIRECT SIGNS OF CVT:**

**Intense contrast enhancement of the flax and tentorium:** is present in 20% of cases. It is easily recognized in tentorium but can be difficult to asses flax, particularly in aged patients. It indicates venous stasis or hyperemia of the duramater. Tentorium enhancement is usually thought to suggest Straight Sinus thrombosis, but it is not rare in SSS thrombosis. It can be associated with dilated transcerebral medullary veins indicating a major venous stasis, usually in relation to an extensive SSS thrombosis.

**Brain edema :** A Common finding is the presence of small ventricle with swelling and sometimes diffuse low density suggestive of edema. However, this is a non-

specific sign and is frequently difficult to differentiate from normal brain, particularly in the young.

**Venous infarcts** : usually describes as hemorrhagic venous infarcts on CT scan present with spontaneous hyperdensity in 10-50% of cases. Two main aspects are encountered: large subcortical often multifocal hematomas.

In rare instances, there is an associated subarachnoid hemorrhage or subdural hematoma, which can even, be the only sign of CVT. Non-hemorrhagic venous infarcts are almost as frequent. They are protean in appearance, focal hypodensity with gyral enhancement, areas of hypodensity without enhancement or isolated gyral enhancement. Hemorrhagic or non-hemorrhagic infarcts can be unilateral, bilateral, single or multiple. They are seen superficially in the hemispheres in the SSS thrombosis and within the basal ganglia in deep venous system thrombosis.

### **CAVERNOUS SINUS THROMBOSIS (CST)**

CT scan is useful in demonstrating CST, showing on post contrast CT as multiple irregular filling defects with bulging cavernous sinuses and enlarged orbital veins. The presence of air seen on coronal sections has been reported on septic thrombosis.

### **NORMAL SCAN**

In 10-20% cases, CT scan is normal in patients with proven CVT, more frequently so upto 50% in patients presenting with intracranial hypertension than those with focal signs.

---

---

**FALSE POSITIVE CT STUDY**

1. High torcular Herophili, high splitting of SSS, fenestrated SSS.
2. Subarachnoid and subdural hemorrhage as well as epidural abscess causing pseudo empty delta sign.
3. Filling defects in the sinus like prominent arachnoid granulations, CSF space.  
Here clinical correlation is required.
4. In neonates, thrombosis may be over diagnosed because low density, unmyelinated brain and relatively high hematocrit cause the venous sinuses to appear very dense.<sup>59</sup>

**CONVENTIONAL ANGIOGRAPHY**

Carotid arteriography with delayed filming technique to visualize the venous system was the procedure of choice in the diagnosis of venous thrombosis prior to the advent of MRV. It is an invasive procedure and is therefore associated with a small risk (1%).<sup>57</sup>

Classical findings include the following :

- ❖ Filling defects from thrombus within the venous sinuses.
- ❖ Occlusion of the draining sinuses.
- ❖ When the sinus is perpendicular to the imaging plane, an angiographic empty delta sign may be observed.
- ❖ Abnormal cortical veins (broken or corkscrew-like).<sup>60</sup> Secondary indirect angiographic findings are as follows:

- ❖ Decreased focal venous circulation around a thrombosed venous sinus.
- ❖ Visualization of collaterals circulation, irregular venules or medullary veins.
- ❖ Narrowing of arteries in the involved region.
- ❖ Prolonged contrast blush in the brain parenchyma.
- ❖ Tortuous vessels in the capillary and venous phases.
- ❖ Collateral flow in dilated anastomotic vessels.

Degree of confidence: With classical findings the diagnosis is certain; however, several pitfalls exist.

- ❖ Prolonged venous circulation can arise from other etiologies (E.g., local mass effect).
- ❖ A dural venous sinus can be congenitally hypoplastic or absent. Anterior third of SSS and one LS are hypoplastic or absent in 20% cases. (Hurst96).
- ❖ Prominent arachnoid granulations at the junction of the vein of Galen and straight sinus may simulate thrombus. This is also a diagnostic problem with MR and CT venography.

## **ULTRASONOGRAPHY**

In general, ultrasonography is not useful except in neonates where the diagnosis of venous sinus thrombosis may be made by color Doppler ultrasound. In young infants, the presence of an open fontanel enables the use of ultrasound to image the brain and sinovenous system. Cranial ultrasound is useful for defining centrally located venous infarcts or hemorrhages in infants with CVT. Though the technique is highly operator dependent, it can be very useful and effective in skilled

hands. Doppler ultrasound define absent or reduced flow in the sinovenous channels in CVT, although this technique is most successful at defining complete occlusion of the superior sagittal sinus. The major limitation of Doppler ultrasound is in the evaluation of lateral venous sinuses when there is incomplete occlusion of residual flow may be mistaken for normal flow. <sup>61,62</sup>

Power Doppler appears to be superior to conventional color Doppler in assessing sinovenous thrombosis. The power Doppler technique measures the energy of moving red blood cells instead of the velocity and direction of flow, and it is more sensitive for identifying flow in slow-flow states. <sup>63</sup>

## **NUCLEAR MEDICINE**

Nuclear medicine has no significant role in the evaluation of cerebral venous thrombosis; however, localized reduced perfusion in the affected venous distribution can be observed.

- ❖ False positives / negatives:
- ❖ Radionuclide study may result in false positive findings in partial thrombosis.
- ❖ Because of low spatial resolution\*<sup>1</sup> pf the radionuclide study, collateral vessels adjacent to a thrombosed venous sinus may mimic a patent sinus.
- ❖ Congenital variations in venous anatomy (Eg. Unilateral transverse sinus) are not discernible from venous sinus occlusion.

## **OTHER INVESTIGATIONS**

**EEG** : May be normal and useful in evaluating a seizure focus.

**Lumbar puncture** : is helpful in evaluating for meningitis as an associated infectious process. A large unilateral hemispheric lesion or posterior fossa lesion demonstrate on CT or MRI is a contraindication to the procedure. In the past, compression of the jugular vein unilaterally with pressure measurement has been utilized. Pressure may be elevated if thrombosis of the contralateral transverse sinus is present. However, collateral circulation or incomplete compression of the jugular vein may yield a false negative result.

**CBC** : Complete blood count is done to look for polycythemia as an etiologic factor.

Decreased platelet count would support thrombotic thrombocytopenic purpura; ieucocytosis might be seen in sepsis. In addition, if heparin is used as treatment, platelet counts should be monitored for thrombocytopenia.

**Antiphospholipid and anticardioliipin antibodies**, should be obtained to evaluate for antiphospholipid syndrome. Other tests that may indicate hypercoagulable states include protein S, protein C, antithrombin III, lupus anticoagulant, and Leiden factor V mutation.

These evaluations should not be made while the patient is on anticoagulant therapy.

Sickle cell preparation or hemoglobin electrophoresis should be obtained in individuals of African decent.

ESR and Antinuclear antibody: should be performed for screening of systemic lupus erythematosus, Wegener granulomatosis, and temporal arteritis. If

elevated, further evaluation including complement levels, anti-DNA antibodies, and neutrophil cytoplasmic antibodies (ANCA) could be considered. Liver function studies should be performed to rule, out cirrhosis.

## **TREATMENT**

Medical care: Initial management revolves around the stabilizing the patient. Seizures should be treated with appropriate anticonvulsants. Specific therapy for CVT involves anticoagulation or thrombolytic therapy.

The current management for CVT is determined mostly on a case-by-case basis.<sup>64</sup> In general, anticoagulation using heparin has been used as a safe and clinically effective treatment method.<sup>65</sup> Recently, endovascular management, including direct thrombolysis with or without mechanical thrombus extraction, has been advocated and has shown favorable outcomes.<sup>66,67</sup>

These reports were based on nonrandomized uncontrolled case series, however.

## **HEPARIN**

Heparin treatment for CVT has been considered a standard therapy. Theories on the pathophysiology of CVT suggest a continuing process of disequilibrium between prothrombotic and thrombolytic mechanisms. Heparin treatment may act by shifting the equilibrium away from the prothrombotic action toward thrombolysis and inhibiting further thrombosis.<sup>51</sup>

Two randomized trials and one meta-analysis of heparin treatment for CVT have been performed. The first trial, was a randomized blinded placebo-controlled

---

study in 20 patients with dural sinus thrombosis.<sup>7</sup> The trial was discontinued after 20 patients because of significant differences in the recovery rate and mortality between the heparin and control group. The authors concluded that anticoagulation with dose-adjusted intravenous (IV) heparin (unfractionated heparin, bolus dose of 3000 IU and continuous infusion of 25,000-65,000 IU/day) was an effective treatment and an associated intracranial hematoma was not a contraindication for its use. This trial was criticized, however, because its outcome assessment was not validated and there was a significant treatment delay after onset of symptoms. The trial failed to clarify the issue of duration of heparin treatment and the use of warfarin was questioned.<sup>64,68</sup> A randomized, placebo-controlled study investigated the role of subcutaneous low-molecular-weight heparin (LMWH) in the management of CVT. In this study, 20% of patients in the heparin treatment group and 24% in the placebo group had a poor outcome after 3 weeks, and 13% in the treatment group and 21% in the placebo group had a poor outcome after 12 weeks. The definition of poor outcome was death or a Barthel index score of less than 15. This study did not demonstrate statistically significant clinical outcome improvement differences between the heparin treatment group and the control group; however, it revealed that the group treated with LMWH followed by oral anticoagulation showed a favorable outcome compared with the control group. The safety of anticoagulation was supported even in the setting of cerebral hemorrhage. A meta-analysis of the previously described two trials did not reveal a statistically significant improvement in outcome but demonstrated a 14.3% mortality reduction rate with heparin treatment and 15.5% risk reduction for death and dependency.<sup>53</sup>

Heparin treatment remains a first-line treatment option in CVT because of the demonstrated safety of heparin and the favorable trend of clinical outcomes as shown in previous trials.<sup>69</sup>

## **INTERVENTION - ENDOVASCULAR TREATMENT**

Patients with a rapidly progressive thrombosis and diffuse brain swelling, with or without multiple hemorrhages, should be considered for endovascular thrombolytic therapy. It has been the authors' practice to start with at least 24 hours of heparin treatment. If clinical worsening of the patient's condition continues during that time period, endovascular thrombolytic therapy should be considered.

Since 1988, several reports have demonstrated the feasibility of direct infusion of thrombolytic agents into the thrombosed dural sinus by way of a percutaneous or retrograde transvenous approach.<sup>70,71,72</sup> With improved catheter technology, it became possible to access and infuse thrombolytic agents into deep cerebral venous system.<sup>73,74</sup> The potential benefit of local administration of thrombolytic therapy is that it may avoid the systemic hemorrhagic effect caused by high-dose IV anticoagulation therapy. The technique of endovascular thrombolytic therapy has changed over the past decade, from a therapy of prolonged infusions of low dose urokinase (2- to 24-hour infusion, 0.5 - 20 million units) to a relatively rapid pulse-spray technique using recombinant tissue plasminogen activator (rtPA; 2-4 hours to administer 50-300 mg).<sup>75,76</sup>

The rtPA has many pharmacologic advantages over urokinase, including a short half-life,<sup>77</sup> low antigenicity, and clot selectivity. The rtPA produces the lowest level of fibrinogen degradation products,<sup>78</sup> which might contribute to the lower likelihood of hemorrhagic complications. There are two case series of local rtPA treatment with concomitant IV heparin treatments. Authors<sup>76</sup> reported complete flow restoration in 18 hours and clinical improvement in all patients after rtPA treatment. They reported two non-neurologic rtPA-related complications (22.2%), including intrapelvic hematoma and puncture-site oozing but no intracranial hemorrhagic complication. A study<sup>79,80</sup> showed flow restoration in 75% (complete in 50% and partial in 25%) of the patients within 29 hours of the rtPA treatment. They demonstrated that clinical recovery was closely related to the degree of flow restoration. In the group with complete flow restoration, 83% of patients had a complete clinical recovery. In the group with partial recanalization, 66% had a complete recovery. In the group that did not recanalize, only 33% demonstrated functional independence. The rtPA treatment resulted in neurologic deterioration in 16.7% of patients, who experienced enlargement of the parenchymal hematoma. These two series show that the local infusion of rtPA in CVT was technically feasible and flow restoration after rtPA treatment was important for future clinical outcome. There is, however, a risk of clinical deterioration, especially in patients with intracranial hemorrhage.

At present, there does not exist a scientifically proven regimen of endovascular therapy that includes inclusion or exclusion criteria, dosage of

thrombolytic agent, duration of treatment, concomitant usage of heparin, and a radiologic endpoint of the interventional procedure. Endovascular treatment can be performed' only in highly sophisticated centers where interventional neuroradiologic expertise is available.<sup>64</sup> In the authors' institution, physicians perform endovascular treatment in patients who show clinical deterioration despite 24 hours of heparin therapy. The authors and other physicians in their institution use a rapid-pulsed direct-infusion technique of 30 to 50 mg of rtPA through a microcatheter over 15 to 20 minutes. The authors use concomitant IV heparin; their angiographic endpoint is antegrade flow within the dural sinus and not the total absence of thrombus within the dural sinus. In the authors' experience, the reestablishment of antegrade flow with continued anticoagulation is sufficient to facilitate clinical improvement.

Various dural sinus revascularization techniques other than local thrombolytic treatment have been reported, such as mechanical disruption using guide wires, rheolytic thrombectomy catheters, balloon thrombectomy with fibrinolysis, transluminal balloon angioplasty, with or without stenting, and surgical thrombectomy. The role of endovascular reopening of the dural sinuses using angioplasty and stent placement in the presence of severe intracranial venous hypertension is anecdotal and long-term results are not known.<sup>81</sup>

In conclusion, heparin is a first-line treatment option for CVT, and endovascular therapy should be considered if rapid clinical worsening occurs, despite anticoagulation. Endovascular treatment for CVT is feasible and effective in selected cases. Because the technology continues to improve, the potential role of endovascular treatment for CVT is promising.

## METHODOLOGY

### **Source of data**

All patients who are clinically suspected of cerebral venous sinus thrombosis admitting in KLES Dr. Prabhakar Kore Hospital and MRC, Belgaum during 1<sup>st</sup> Jan 2007 to 31<sup>st</sup> Dec 2007.

### **Method of Collection of Data**

#### **Sample size:**

The study comprised a total of 30 patients of cerebral venous sinus thrombosis which was calculated by taking 80% of average of similar cases in the previous 3 years (2005-41 cases, 2004-25 cases and 2003-15 cases) hospitalised in KLES Dr. Prabhakar Kore hospital and medical research centre, Belgaum.

Data was collected from the patients with clinical features of cerebral venous sinuses thrombosis by predesigned proforma after obtaining the informed consent. Patient was subjected to both magnetic resonance imaging and magnetic resonance venography and their correlation with clinical presentation of cerebral venous thrombosis was done.

**Study design** : One year cross sectional study from 1st Jan 2007 to 31st Dec 2007

**Study subjects** : All patients who fulfill the inclusion criteria.

#### **Inclusion criteria :**

- Patient presenting in the age group above 15 years with history and physical examination suggestive of cerebral venous thrombosis confirmed by MR venography.

**Exclusion criteria :** All patients with normal MR venography are excluded.

**Statistical analysis :**

- Agreement between the clinical finding of cerebral venous thrombosis and magnetic resonance venography.
- My data doesn't require any statistical calculations to support the conclusions since all the thirty cases who have undergone MRV are positively detected as thrombosis.

### **EQUIPMENTS**

The patients were scanned using 1.5 Tesla superconducting magnet, MAGNETOM SYMPHONY SIMENS SOFTWARE VERSION 2002 OF GERMANY

### **MRI AND MRV PROTOCOL**

A complete clinical history of patients was taken which included name, age, sex, occupation, presenting complaints. This was followed by general physical examination and detailed Central nervous system with examination of other significant systems.

**Anesthesia / analgesia :**

We tried to do the study without anesthesia or analgesic agents in most of the -patients. Few patients required sedation in the form of Inj. Haloperidol 10 mg in consultation with referring physician and anesthetist.

**RESULTS****Table No. 1 : Sex wise distribution of patients with cerebral venous thrombosis**

<b>Sex</b>	<b>No. of Patients (n=30)</b>	<b>Percentage (%)</b>
Males	12	40
Females	18	60
<b>Total</b>	<b>30</b>	<b>100</b>

In the present study there is female preponderance, female : male ratio being 1.5:1.



**Table No. 2 : Age wise distribution of patients with cerebral venous thrombosis**

<b>Age (Years)</b>	<b>No. of Patients (n=30)</b>	<b>Percentage (%)</b>
15-20	05	16.66
21-40	16	53.33
41-60	08	26.66
>60	01	03.33
<b>Total</b>	<b>30</b>	<b>100</b>

In the present study the peak incidence of CVT is seen in the age group of 21 to 40 years. Incidence of CVT is less above the age of 60



**Table No. 3 :Age & Sex wise distribution of the patients with CVT**

Age (Yrs)	Male (n=12)	Female (n=18)	Total (n=30)
15-20	1	4	5
21-40	6	10	16
41-60	4	4	8
> 60	1	0	1
<b>Total</b>	<b>12</b>	<b>18</b>	<b>30</b>

Female predominance, age group of 21-40 Yrs shows maximum presentation of CVT in both males and Females



**Table 4: Distribution of symptoms in CVT patients**

Symptom	No. of Patients (n=30)	Percentage (%)
Head ache	28	93.3
	20	66.6
Seizure      Generalised	12	40
(n=20)      Focal	8	26.6
Vomiting	15	50
Altered sensorium	15	50
Neurodeficit	10	33.3
Fever	4	13.3
Visual disturbances	2	6.6

The most common symptom with which the patients presented in this study was headache 28(93.3%) followed by Seizure, seen in 20 patients(66.6%), generalized(40%), or focal(26.66%), Vomiting in 15 patients(50%), Altered Sensorium in 15 patients(50%), Neurodeficit in 10 patients(33.3%). Fever in 4 patients (13.3%) and Visual disturbances in 2 patients (6.6%).



**Table no. 5: Duration of symptoms prior to admission in patients with CVT**

<b>Duration (days)</b>	<b>No. of Patients (n=30)</b>	<b>Percentage (%)</b>
1-5	18	60
6-10	7	23.3
11-15	5	16.6
<b>Total</b>	<b>30</b>	<b>100</b>

The duration of symptoms prior to admission ranged from 1 day to a maximum of 15 days. Majority of patients i.e. 18 patients (60%) had a symptom duration between 1 to 5 days, 7 patients (23.33%) between 6 to 10 days and 5 patients (16.66%) between 11 to 15 days. The mean duration of symptoms prior to admission was 6 days with a standard deviation of 4 days.



**Table 6 : Distribution of patients based on the signs in CVT**

	<b>No. of Patients (n=30)</b>	<b>Percentage (%)</b>
Papilloedema	14	46.6
Motor deficit (hemip-aresis)	Right	8
	Left	2
Cranial nerve involvement	2	6.6
Signs of meningeal irritation	9	30
Aphasia	5	16.6

In this study, the most common signs seen in CVT patients were Papilloedema 14 (46.6%), followed by Motor deficits in 10 (33.33%). Right sided hemiparesis in 8 patients (26.6%), and left sided hemiparesis in 2 patients (6.6%), cranial nerve involvement in 2 patients(6.6%), Signs of meningeal irritation in 9 patients (30%) and Aphasia in 5 patients(16.6%).



**Table No. 7: MRI findings in CVT Patients.**

MRI findings		No. of Patients (n=30)	Percentage (%)
Hemorrhagic venous infarct (n=15)	Right	8	26.66
	Left	6	20
	Bilateral	1	3.33
Non-hemorrhagic Infarct (n=9)	Right	4	13.33
	Left	5	16.66
Cerebral edema (n=14)			
a. Associated with above findings		8	26.66
b. Only cerebral edema		6	20

The most common MRI finding was Hemorrhagic Venous Infarct, which was seen in 15 patients (50%) out of these 8 patients(26.66%) had Right Hemorrhagic Venous Infarct, 6 patients (20%) had Left Hemorrhagic Venous Infarcts, 1 patient(3.33%) had bilateral Hemorrhagic Venous Infarct. Non hemorrhagic Infarct was seen in 9 patients (30%), out of these, 4 patients (13.33%) had Right Infarct, and 5 patients (16.66%) had left infarct. Cerebral edema was seen in 14 patients (46.66%), out of these 8 patients (26.66%) had venous infarct, and 6 patients (20%) had only Cerebral edema.



**Table No. 8: MRV finding in patients with CVT (Thrombosis)**

<b>Sinus</b>	<b>No. of Patients (n=30)</b>	<b>Percentage (%)</b>
Superior sagittal sinus	19	63.33
Transverse sinus	12	40.00
Sigmoid sinus	11	36.66
Cortical veins	05	16.66
Internal cerebral vein	03	10.00
Internal jugular vein	03	10.00
Straight sinus	02	06.66
Vein of galen (vog)	02	06.66
Cavernous sinus	01	03.33
Basal vein of rosenthal	01	03.33
Inferior sagittal sinus	01	03.33

Involvement of superior sagittal sinus was seen in 19 patients (63.33%), the next common sinus involved was transverse sinus in 12 patients(40%) followed by sigmoid sinus in 11 patients (36.66%).



**Table No. 9: Distribution of patients with CVT depending on the number of sinuses involved.**

<b>No. of Sinuses involved</b>	<b>No. of Patients (n=30)</b>	<b>Percentage (%)</b>
One	11	36.66
Two	08	26.66
Three	08	26.66
Four	03	10.00
<b>Total</b>	<b>30</b>	<b>100%</b>

In this study, 11 patients had only one sinus involvement (36.66%), 8 patients had two sinus involvement (26.66%), another 8 patients had three sinus involvement and 3 patients had four sinus involvement.



**Table No. 10 : Correlation of the symptoms of CVT patients to their MRV findings**

MRV findings	Headache (n=28)	Vomiting (n=15)	Seizures			Hemiparesis (n=10)	Visual disturbance (n=2)	Fever (n=4)
			Focal (8)	Genera lised (17)	Altered sensorium (n=15)			
SSS (n=19)	19	8	6	9	7	9	1	1
TS(n=12)	11	9	2	7	10	1	0	0
Sigmoid sinus (n=11)	10	7	3	6	11	4	1	0
CV(n=05)	5	4	1	5	0	5	0	1
ICV(n=03)	3	2	0	3	1	3	0	3
IJV (n=03)	3	3	1	2	1	3	0	0
Vog(n=02)	2	0	0	0	1	0	0	2
ISS(n=01)	1	0	1	0	1	1	0	0
CS(n=01)	1	0	0	0	1	0	1	0
BV of R (n=01)	1	1	0	1	0	1	0	0
SS(n=02)	2	1	1	1	1	1	0	0

**Correlation of symptoms of CVT patients to their MRV findings**

In the present study most common sinus involved was superior sagittal sinus in 19 patients and all had headache (100%). Patients with transverse sinus involvement presented with (headache 11(91.66%), vomiting 9 (75%), altered sensorium 10(83.33%). Patients with sigmoid sinus involvement presented with headache 10(90.9%), vomiting 7 (63.63%), altered sensorium 11 (100%).

Generalized Tonic Clonic seizure was present in all the 5 patients with cortical vein involvement (100%).



**Table No. 11 : Distribution of patients depending on the aetiology**

<b>Etiology</b>	<b>No. of Patients (n=30)</b>	<b>Percentage (%)</b>
Undetermined	8	26.66
Alcohol	5	16.66
Postpartum	4	13.33
Dehydration	4	13.33
Sepsis	2	6.66
Antiphospholipid syndrome	2	6.66
Mastoiditis	2	6.66
Oral contraceptive pills	1	3.33
Primary polycythemia	1	3.33
Cerebral malaria	1	3.33
<b>Total</b>	<b>30</b>	<b>100%</b>

In the present study, the cause was undetermined in 8(26.66%), alcohol was the common cause for the CVT in males 5 patients (16.66%) followed post partum and dehydration constituted 4 patients (13.33%) each.



**Details of 6 patients who had only cerebral edema as a finding in MRI.**

A. Symptom profile

- Headache and vomiting- 3
- Seizures- 2
- Altered sensorium with fever- 1

B. Duration of symptom

- 1-3 days- 5
- 5-10 days- 1

C. Sinus involvement

- Superior sagittal sinus- 3
- Cortical venous sinus + bilateral transverse sinus + superior sagittal sinus posteriorly- 2
- Sigmoid sinus + transverse sinus- 1

**OUTCOME (USING MODIFIED RANKIN SCALE)**

<b>Score</b>	<b>Description</b>
<b>0</b>	No symptoms at all
<b>1</b>	No significant disability despite symptoms: able to carry out all usual duties and activities.
<b>2</b>	Slight disability: unable to carry out all previous activities but able to look after own affairs without assistance
<b>3</b>	Moderate disability: requiring some help, but able to walk without assistance
<b>4</b>	Moderately severe disability : unable to walk without assistance and unable to attend own bodily without assistance.
<b>5</b>	Severe disability : bedridden, incontinent and requiring constant care and attention
<b>6</b>	Dead

**Table No. 12 : Outcome of the CVT patients at the time of discharge (as per modified RANKIN SCALE)**

<b>Outcome score</b>	<b>No. of Patients (n=30)</b>	<b>Percentage (%)</b>
0	14	46.6
1	4	13.3
2	3	10
3	1	3.3
4	2	6.6
5	3	10
6	3	10

While studying the outcome of CVT patients at the time of discharge, using the modified rankin scale, it was found that out of 30 patients, 14 patients (46.6%) had full recovery with no residual disability with rankin scale 0, 13 patients (43.3%) with rankin scale 1 to 5 had disability varying from mild to severe. 3 patients (10%) with rankin scale 6 expired.



---



---

**CORRELATION OF GLASGOW COMA SCALE AT ADMISSION WITH  
OUTCOME IN CVT PATIENTS**

<b>Glasgow coma scale</b>	<b>Outcome (As per Modified Rankin Scale)</b>						
	<b>0</b>	<b>1</b>	<b>2</b>	<b>3</b>	<b>4</b>	<b>5</b>	<b>6</b>
0-3	-	-	-	-	-	-	2
4-6	3	-	1	1	-	-	1
7-9	3	-	-	-	-	-	-
10-12	-	-	-	-	2	1	-
13-15	8	4	2	-	-	2	-

---

On comparing the consciousness level at admission (according to Glasgow Coma Scale) with the outcome at discharge (according to Modified Rankin Scale) it was observed 19 patients (63.3%), had Glasgow Coma Scale between 10 and 15, 8(42%) were discharged with full recovery and no deficits, 4 patients were discharged with no significant disability & 2 patients discharged with slight disability. 2 were discharged with moderately severe disability & 3 were discharged with severe disability. Out of 8 patients (26.6%), who had Glasgow Coma Scale 0 and 6, 3 patients (10%) expired, 2 patients (6.6%) had mild disability and only 3 patients (10%) recovered with no residual deficits. Out of 3 patients (10%) who had Glasgow coma scale 7 & 9 were discharged without any symptoms.



## DISCUSSION

The present study was conducted from 1<sup>st</sup> January 2007 to 31<sup>st</sup> December 2007 to detect the diagnostic efficacy of magnetic resonance venography in clinically suspected cases of cerebral venous thrombosis admitted in KLES Dr.Prabhakar Kore Hospital and MRC, Belgaum.

### **Sex**

CVT believed to be more common in women than men. In a series of 110 cases, Ameri and Bousser found a female to male ratio was 1.29:1 (Ameri 1992).<sup>8</sup> Female predominance was also seen in present study where female to male ratio was 1.5:1. In literature there is a female preponderance in the incidence of CVT.<sup>84,85</sup>

### **Age**

In our study most commonly affected age group (Males & Females) was 21 to 40 years comprising 53.33% of total patients. Similar findings have been supported by Sanchetee and Dhamija in 1992<sup>82</sup> and Parikh et al<sup>83</sup> in their respective studies.

### **Clinical presentations**

Majority of cases (60%) in the present study developed their signs and symptoms within 1 to 5 days. Padmavati S, Gupta S, Singh B in a clinical study of 44 cases of hemiplegia in adult women, observed that CVT can occur antenatally or in association with abortion, and that majority of cases of peripartum CVT are seen in the first four weeks of delivery.<sup>82</sup>

Cerebral venous thrombosis patients present with a wide spectrum of symptoms and signs. In the present study headache and seizures were the most common symptoms seen in 93.3% and 66.6% of patients respectively. The most common presentation was headache, seizures and vomiting in combination seen in 9 patients (30%). Eight patients presented with only headache.

Occasionally, the presentation of CVT is atypical, like behavioural symptom such as anxiety or depression.<sup>86</sup>

Similar findings have been reported by Einhaupl et al. (1990)<sup>88</sup> when they observed that 91% of patients presented with headache and 48% with seizures. Cantu et al<sup>87</sup> found that headache was one of the most common symptoms, seen in 70% of non puerperal and 88% of puerperal cases. Daif et al<sup>89</sup> reported that headache was the leading symptom seen in 82% of patients whereas seizures were seen in only 10% of patients.

The incidence of generalized seizures in CVT patients in our study was 40% and focal seizures 26.6%. Toole F James<sup>86</sup> in his literary work on venous thrombosis obtained similar data : generalized seizures being more common, seen in 40% of patients whereas 30% of patients presented with focal seizures with or without generalization. 20% of their presents presented in status epilepticus. In our study no patient presented in status epilepticus. Sanhetee et al.<sup>82</sup> found that 44% of patients had generalized seizures and 32% had focal seizures with or without secondary generalization.

In the present study 15 patients (50%) had altered sensorium with Glasgow coma scale of less than 8 out of which 9 patients (60%) were comatose, 6 patients (40%) were stuporous and drowsy. Sanchettee and Dhamija in their study in 1992<sup>82</sup> found 48% of the patients to be comatose during acute stage of illness, 40% drowsy and stuporous.

Other presenting symptoms seen in our study in order of decrease in frequency were vomiting, (50%), neurological deficit (33.3%), fever (13.3%) and visual disturbances in the form of diplopia (6.6%)

Bousser MG et al<sup>84</sup> reported the most frequent deficits encountered were motor and sensory deficits. In our study on examination, motor deficits were the most common sign seen in 32.2% of CVT patients. Right sided hemiparesis was found in 8 patients (26.6%), left sided in 2 patients (6.6%).

Out of 10 patients of hemiparesis, 2 patients expired, 3 patients being severely disabled, 5 patients having completely recovered. Similar outcome were observed by Parikh and Sukhthankar et al<sup>83</sup> in 1996 with hemiparesis being most common motor deficit seen in 60% of patients. In our study no patient presented with sensory deficit.

Papilloedema was present in 46.6% of patients which was found to be comparable to earlier studies<sup>84,87</sup>. In contrast Daif et al 1995<sup>89</sup> reported 80% of patients to be having papilloedema.

In our study (6.6%) patient had cranial nerve involvement, out of which 3.3% had Abducent (VIth) nerve and 3.3% had oculomotor nerve palsy respectively. Parikh and Sukhthankar et al.<sup>83</sup> found facial nerve in 56% of their patients. Sachetee and Dhamija et al<sup>82</sup> observed oculomotor abnormalities in 36% of patients due to VIth cranial nerve palsy, IIIrd cranial nerve palsy, cortical blindness and horizontal gaze palsy.

The probable etiology behind facial palsy is that it is caused by transient neuropraxia in the intracranial segment of the nerve.

Signs of meningeal irritation were seen in 30% patients out of these 1 patient had cerebral malaria, two patients had (22.2%) sepsis, where as other 66.66% had neck stiffness.

Aphasia was seen in 5 patients (16.6%) out of which 4 patients had global aphasia and 1 patient had motor aphasia. In contrast Parikh and Sukhthankar et al<sup>83</sup> reported aphasia in only 2.7% patients and Daief et al<sup>89</sup> in 40% patients .

#### **Anticardiolipin Antibodies (ACA)**

We found 2 patients (6.66%) to be positive for anticardiolipin antibodies. Similarly Daif et al<sup>89</sup> reported 10% cases and Deschiens Marie Anne7.5% cases positive for ACA.

**Cerebrospinal fluid (CSF)**

Examination of CSF does not necessarily help in establishing the diagnosis as there are no pathognomonic features. In the present study patients (30%) with signs of meningeal irritation were subjected to CSF examination. CSF abnormalities were not detected in single case. Nevertheless, examination of the CSF remains important in the appropriate clinical context to rule out meningitis or subarachnoid hemorrhage before the diagnosis of CVT has been established.

**Neuro imaging**

In present study MRI scan showed infarct in 24 patients (80%), hemorrhagic infarct in 50% (right 26.66% and left 20% and bilateral in 3.33%), non-hemorrhagic infarct in (30%), cerebral edema in 46.66% (out of these 26.66% patient had associated venous infarct, 20% had only cerebral edema).

In a study by Panagariya and Maru <sup>90</sup> MRI scan findings showed hemorrhagic infarcts in 60% (left 39%, right 10.5% and bilateral in 10.5%), cerebral edema in 12.28%, non hemorrhagic infarct (left 20% and right 10%).

Hemorrhagic infarction occurs in nearly all patients principally affecting the cortex and adjacent white matter. This is thought to be primarily due to elevated venous and capillary pressure caused by the persistence of thrombosis. <sup>91</sup>

The present study showed superior sinus thrombosis in 63.33% cases, transverse sinus thrombosis in 40% and sigmoid sinus thrombosis in 36.66% cases.

Superior sagittal sinus is the commonest venous sinus to be involved in cerebral venous sinus thrombosis. The study done by Kalbag and Wolf in 1967 showed the incidence of superior sagittal sinus thrombosis in 72%, Lateral sinus thrombosis in 63% and sigmoid sinus thrombosis in 50% cases.<sup>18</sup>

In all the recent series of CVT<sup>84,89,87</sup> SSS was the commonest sinus involved followed by transverse sinus and then sigmoid sinus. Incidence of thrombosis in superior sinus is higher, because the lumen of superior sinus with laminal an fibrous trabeculae favours thrombosis. Similar findings have been reported by Cantu et al<sup>87</sup>. In contrast to our findings Bousser et al<sup>84</sup> had 3 patients with cavernous sinus involvement.

The present study revealed, in most of the patients the extent of involvement is only one sinus, which was 36.66%. Two or three sinuses involved in equal number of patients (26.66%), only 10% of patients had involvement of four sinuses.

### **Etiology**

Cerebral venous thrombosis has been described as a continuing process in which the balance of prothrombotic and thrombolytic process is distributed, leading to progression of the venous thrombosis with time.<sup>91</sup> This slow growth of the thrombus and the good collateralization of the venous vessels probably explain the usually gradual onset of symptoms, frequently over weeks and months.<sup>92</sup>

Apart from perinatal insults, the cerebral venous occlusive disease may be associated with systemic illnesses like congenital heart diseases, infectious diseases

in infancy and childhood, pyogenic infections of the paranasal sinuses and face and post operative periods. Cachexia, dehydration and polycythemia predispose to the occurrence of cerebral venous thrombosis.<sup>93</sup> Dehydration causing hemoconcentration, sludging and thrombosis is also a significant factor.<sup>83</sup> Alcohol consumption is known to induce a hypercoagulability state.<sup>83</sup> Parikh and Sukhthankar et al<sup>83</sup> found history of chronic alcoholism in 33.6% of cases in their study.

With the extensive investigations conducted by Ameri and Bousser, no cause is identified in 20 to 25% of cases.

In the present study the cause could not be identified in 26.66% of cases of CVT. The commonest causes are Alcohol (16.6%), Postpartum (13.3%) and dehydration (13.3%). Other etiological factors include sepsis (6.6%), antiphospholipidsyndrome (6.6%), Mastoiditis (6.6%) , Oral contraceptives (3.33%), primary polycythemia (3.3%) cerebral malaria (3.3%).

Despite the continuous description of new causes, the proportion of cases of unknown etiology remain high in recent studies.<sup>89,87,88,92</sup>

### **Outcome**

In our study, modified Rankin Scale<sup>94</sup> was used as a functional outcome measure in stroke at the time of discharge. 46.6% of patients had complete recovery and were discharged with no residual deficit, which was comparable with other recent studies.<sup>87,88</sup> Peter M. and Tzourio C. et al in 1996<sup>95</sup> quoted that between 57%

to 86% of patients have complete functional recovery. In our study 33.3% ranked from 1 to 4 on the Modified Rankin scale and at the time of discharge had mild to moderate disability. Three patients (10%) had severe disability, requiring round the clock nursing assistance, and only 10% patients in our study expired, out of which two patients were males and one patient female; similar mortality rate was seen in recent studies<sup>84,89,88</sup>

Mortality ranked between 5.5% and 18% in a study carried out by Peter M. and Tzourio C. et al in 1996.<sup>95</sup> In another study carried out by Sanchetee and Dhamija et al in 1992<sup>82</sup>, it was seen that 60% cases were discharged with good to moderate recovery and 28% patients were left with significant functional impairment in the form of altered mental state, hemiplegia or both.

In our study it was also seen that patients presenting with Glasgow Coma scale below 7 generally had a poor outcome. There were eight such patients-3 expired, 3 had severe disability and only 2 had complete recovery. Whereas patients with Glasgow Coma scale more than 7(73.3%) had a better outcome with twelve patients having complete recovery, seven patients having mild residual deficit and three patients having moderate disability.

In our study patients having bilateral hemorrhagic venous infarction in their MRI scans had 100% mortality, 13.3% mortality was seen in unilateral infarction and 2% mortality in patients with diffuse cerebral edema with venous infarct. No mortality in patients with only cerebral edema has MRI findings. Panagariya and

Maru in 1997<sup>90</sup> showed correlation of MRI scan with outcome with patients having bilateral hemorrhagic venous infarction having mortality of 50%, and in patients having diffuse cerebral edema and unilateral hemorrhagic venous infarction mortality was 28.5% and 20% respectively.

Patients having a single sinus involvement on MRV scan i.e. 11 patients (36.6%) had full recovery at discharge. The outcome in 8 patients (26.6%) having two sinus involvement on MRV, 4 patients fully recovered, 3 had mild deficit, 1 had severe disability. 8 patients (26.6%) with three sinus involvement on MRV, the outcome was generally poor, 3 had severe disability, 2 had moderate to severe disability and 3 patients recovered completely. Three patients (10%) had 4 sinus involvement on MRV. All of them are expired. ME Yeolekar<sup>93</sup> reported that isolated sinus thrombosis carried a good prognosis.

In our study, patients who were left with deficits had either residual paralysis with epilepsy, or epilepsy alone at the time of discharge.

## CONCLUSION

1. The incidence of CVT was more in female population.
2. The peak incidence of CVT was found in the age group of 21-40 years.
3. In most of the cases, cause of CVT was unknown and other common causes were alcohol consumption, post partum and dehydration.
4. The most common clinical feature was headache.
5. Superior sagittal sinus was the commonest sinus involved in cerebral venous sinus thrombosis.
6. In majority of patients, 2 or more sinuses were involved.
7. Hemorrhagic venous infarct was seen commonly when two or more sinuses were involved.
8. Outcome of patient was poor, if more sinuses were involved
9. Magnetic resonance venogram is the only non invasive and sensitive diagnostic modality for cerebral venous thrombosis.

## SUMMARY

The study titled “Diagnostic efficacy of magnetic resonance venography in patients of cerebral venous thrombosis during 1<sup>st</sup> Jan 2007 to 31<sup>st</sup> Dec 2007. The aim of the study is to detect the diagnostic efficacy of magnetic resonance venography in clinical suspected cases of cerebral venous thrombosis” our study include 30 patients presenting with symptoms of cerebral venous thrombosis. MRI showed venous infarct in 24(80%) patients and MRV showed venous thrombosis in 30(100%). The salient features observed in our study group

- Maximum patients (53.33%) were in the age group of 21 to 40 years.
- Male : female ratio of 1:1.5
- Majority of cases (60%) developed their signs and symptoms within a period of 1 to 5 days
- The spectrum of clinical presentation was extremely wide, with patients having headache, seizures, altered sensorium, vomiting, focal deficits and papilloedema in varying combination.
- Headache and seizures were the most common symptoms seen in 93% and 67% respectively.
- Papilloedema was present in 46.6% of patients.
- 6.66% patients were seropositive for anticardiolipin antibodies
- Predominant MRI scan findings were : hemorrhagic venous infarction 50%, non hemorrhagic venous infarct 30%, cerebral edema 46.6%.

- Most common sinus involved was the superior sagittal sinus as seen in 63.33%
- Most common etiologies were chronic alcoholism 16.66% in males, post partum 13.33%, dehydration 13.33%.
- Complete recovery was observed in 46.6% of patients, and 10% of patients were severely disabled.
- A mortality rate of 10% was observed in our study
- A poor outcome was found in association with the following
  - a. Glasgow coma scale score below 6 on admission
  - b. Presences of bilateral hemorrhagic venous infarcts on MRI scan
  - c. Presences of diffuse cerebral edema on MRI
  - d. Presences of more than two sinuses on MRV

Cerebral venous thrombosis over the past decade has been diagnosed more frequently due to greater awareness and the availability of better non invasive diagnostic techniques. The choice of investigation now is MRI with MR venography. Search for acquired or hereditary coagulation disorders is mandatory, particularly in cases with positive medical or family history of thrombotic episodes and where no cause is identified.

## **BIBLIOGRAPHY**

1. Zimmerman RD, Ernst RJ: Neuro imaging of cerebrovenous thrombosis, Neuroimaging din NAiner, 1992; 2:463-485.
2. Wadia NH, Neurological practice. ELSEVIER, 2006;15:338-349.
3. Feno JM, Canhao P, Stam J, Bousser M-G, Barinagarrementeria F; for the ISCVT Investigators. Prognosis of cerebral vein and dural sinus thrombosis. Results of the International Study on Cerebral Vein and Dural Sinus Thrombosis (ISCVT). Stroke. 2004; 35:664-670.
4. Nagaraja D, Tally AB. Stroke in the young in progress in Clinical Neurosciences EDT publ Sinha KK, Ranchi 1988; 2:129-45.
5. Lee SK, Kim BS, Terbrugge K. Clinical presentation, imaging and treatment of cerebral venous thrombosis (CVT). Intervent Neuroradiol 2002; 8:5-14.
6. Bousser MG. Cerebral venous thrombosis: diagnosis and management. J Neurol 2000; 247:252-8.
7. Einhaupl KM, Villringer A, Meister W. Heparin treatment in sinus venous thrombosis. Lancet 1991; 338:597-600.
8. Ameri A, Bousser MG. Cerebral venous thrombosis. Neurol Clin. 1992;10:87-111.

9. Casey SO, Alberico RA, Patel M. Cerebral CT venography. *Radiology* 1996;198(1): 163- 70.
10. Jacewicz M, Plum F. Aseptic cerebral venous thrombosis. In: Jeinhaupl K, editor. *Cerebral sinus Thrombosis*. New York: Plenum Press; 1990j: 157- 70.
11. Hamburger C, Villringer A, Bauer M. Delta (empty triangle) sign in patients without thrombosis of the superior sagittal sinus. In: Einhaupl K, Kempfski O, Baethmann A, editors. *Cerebral sinus thrombosis: experimental and clinical aspects*. New York: Plenum Press; 1990.211- 7.
12. Karthikeyan D., Vijay S., Kumar T., Kanth L. Cerebral venous thrombosis – Spectrum of CT findings. *Ind J Radiol Imag* 2004; 14:2:129-137.
13. Ayanzen RH., Bird CR., Keller PJ., McCully FJ., Theobald MR., Heiseman JE., *Cerebral MR venography : Normal Anatomy and potential Diagnostic pitfalls*. *AJNR. Am J Neuroradiol* 2000;21:74-78.
14. Anne G. Osborn, *Venous Occlusions*. In : *Diagnostic Neuroradiology : Stroke*. U.S.A. : Harcourt Brace and Company Asia PTE LTD, Mosby – Year Book, 2004:385-395.
15. Seon-Kyu Lee, Karel G. terBrugge, *cerebral venous thrombosis in adults: the role of imaging evaluation and management*. *Neuroimaging Clin NAm* 2003; 13:139- 152.

16. Ribes MF. Des recherches faites sur la phlebite Revue Medical Francais ET Etrangere er Journal de clinique Del 'Hotel Dieu et de la Charite de Paris 1825; 3: 5.
17. Aberombei J. Superior sagittal thrombosis in puerperium 83. In Pathological and Practical Researches of the Brain and Spinal Cord Publ. John Carfare and Sons Edinburgh 1828.
18. Kalbag RM, Wolf AL. Etiology of cerebral venous thrombosis in Cerebral Venous Thrombosis publ. Ed Kalbagh RM, Wolf AL. Oxford University Press London 1967; pp 238.
19. Bianchi D, Maeder P, Bogousslavesky J. Diagnosis of cerebral venous thrombosis with routine magnetic resonance, an update. Eur Neurol 1998; 40 (4): 79-90.
20. Barnett HJM, Hyland HH. Non-infective intracranial venous thrombosis. Brain 1953;76:36-49.
21. Krayenbuhl H. Cerebral venous thrombosis: The diagnostic value of cerebral angiography. Schwez Arch Neurol Neurochir Psychiatr 1954; 74:261-287.
22. Buonanno FS, Mody DM, Ball MR, Laster DW. Computed cranial tomographic findings in cerebral sinovenous occlusion. J Comput Assist Tomogr 1978; 2:281-290.

23. Modic MT, Weinstein MA, Starnes DL, Kinney SE, Duchensneau PM. Intravenous digital subtraction angiography of the intracranial veins and dural sinuses. *Radiology* 1983; 146:383-389.
24. Macchi PJ, Grossman RI, Gomori JM, Goldberg HI, Zimmermann RA, Bilanuik LT. High field MR imaging of cerebral venous thrombosis. *J Comput Assist Tomogr* 1985; 10:10-15.
25. Vogl TJ, Bergman C, Villringer A, Einhaupl K, Lissner J, Felix R. Dural sinus thrombosis: Value of venous MR angiography for diagnosis and follow-up. *AJR* 1994; 162:1191-1198.
26. Bousser MG, Chiras J, Bories J, Castaigne P. Cerebral venous thrombosis a review of 38 cases. *Stroke* 1985; 16:199-213.
27. Karabudak R, Caner H, Oztekin N, Ozcan OE, Zileli T. Thrombosis of intracranial venous sinuses. Aetiology, clinical findings and prognosis of 56 patients. *J Neurosurg Sci* 1990; 34:117-121.
28. Einhaupl KM, Villringer A, Meister W. Heparin treatment in sinus venous thrombosis. *Lancet* 1991; 338:597-600.
29. Scott JA, Pascuzzi RM, Hall PV, Becker GJ. Treatment of dural sinus thrombosis with local urokinase infusion. *J Neurosurg* 1998; 68:284-287.

30. Tsai F Y, Higashida RT, Matovich V, Alfieri K. Acute thrombosis of intracranial dural venous sinus: Direct thrombolytic treatment. *AJNR* 1992; 13:1137-1141.
31. Smith TP, Higashida RT, Barnwell SL. Treatment of dural venous sinus thrombosis by urokinase infusion. *AJNR* 1994; 15:801-807.
32. Mohammad Wasay, Muhammad Azeemuddin, Neuroimaging of Cerebral Venous Thrombosis. *Journal of Neuroimaging*, 2005; 15: 2: 118-128.
33. R.V. Damadian "Tumor Detection by Nuclear Magnetic Resonance. *Science* 1971; 171:1151.
34. Thomas S Curry, James E Dowdey, Robert E Murry Jr., Christensen's Physics of Diagnostic Radiology, 4<sup>th</sup> Edn: Nuclear Magnetic Resonance, Paris 1990; 32: 432.
35. A. Kumar, D. Welti, R.R. Ernst NMR Fourier zeugmatography. *J. Magn. Reson*, 1975; 18:69-83.
36. P Mansfield Multi-planar image formation using NMR spin-echos. *J. Phys. C: Solid State Physics*. 1977; 10:L55-L58.
37. B. Chapman, R. Turner, R.J. Ordidge, M. Doyle, M. Cawley, R. Coxon, et al. Real-Time Movie Imaging from a Single Cardiac Cycle by NMR MagnReson. *Med*.1987; 5:246-254.

38. C.L. Dumoulin, S.P. Souza, H.R. Hart Rapid Scan Magnetic Resonance Angiography. *M/gH. Reson. Med.*1987; 5:238-245
39. K.K Kwong, J.W. Belliveau, D.A. Chesler, I.E. Goldberg, R.M. Weisskoff. Dynamic magnetic resonance imaging of human brain activity during primary sensory stimulation. *Proc. Natl. Acad. Sci. (USA)*, 1992; 89:5675.
40. M.S. Albert, G.D. Cates, B. Driehuys, W. Mapper, B. Saam. Biological magnetic resonance imaging using laser-polarized  $^{129}\text{Xe}$ . *Nature* 1994; 370:199-201.
41. Martyn NJ Paley, Iain D Wilkinson, Edwin van Beek and Paul D Griffiths. Grainger and Allison's Diagnostic radiology. A textbook of Medical Imaging 4<sup>th</sup> Edn: Magnetic Resonance imaging: Basic principles, Italy. 2001; 5:101-102.
42. Ozsvath RR, Casey SO, Lustrin ES. Cerebral venography: comparison of CT and MR projection venography. *Am J Roentgenol* 1997; 169:1699- 707.
43. James N. Scott, Richard I. Farb. Imaging and anatomy of the normal intracranial venous system. *Neuroimaging Clin N Am* 2003; 13:1-12
44. Liang L, Korogi Y, Sugahara T. Evaluation of the intracranial dural sinuses with a 3D contrast-enhanced MP-RAGE sequence: prospective comparison with 2D-TOF MR venography and digital subtraction angiography. *AJNR Am J Neuroradiol* 2001; 22:481-492.

45. Takano K, Utsunomiya H, Ono H. Dynamic contrast- enhanced subtraction MR angiography in intracranial vascular abnormalities. *Eur Radio* 1999; 9:1909- 12.
46. Forbes KP, Pipe JG, Heiserman JE. Evidence for cytotoxic edema in the pathogenesis of cerebral venous infarction. *Am J Neuroradiol* 2001; 22:450 - 5.
47. Ducreux D, Oppenheim C, Vandamme X. Diffusion- weighted imaging patterns of brain damage associated with cerebral venous thrombosis. *Am J Neuroradiol* 2001; 22:261-8.
48. James N. Scott, Richard I. Farb. Imaging and anatomy of the normal intracranial venous system, *Neuroimag Clin N Am* 2003; 13:1-12.
49. J. Kimber. Cerebral venous thrombosis. *QJ'Med* 2002; 95:137-142.82
50. Holger Allrogen and Richard J Abbott. Cerebral venous sinus thrombosis, *Postgrad. Med. J.* 2000; 76:12-15.
51. Villringer A, Mehraen S, Einhaupl KM. Pathophysiological aspects of cerebral sinus venous thrombosis. *J Neuroradiol* 1994; 21:72-80.
52. Crawford SC, Digre KB, Palmer CA. Thrombosis of the deep venous drainage of the brain in adults. Analysis of 7 cases with review of the literature. *Arch Neurol* 1995; 52:1101-8.

53. De Bruijn SF, Stam J. for the CVST Study Group. Randomised, placebo-controlled trial of anticoagulant treatment with low-molecular/weight heparin for cerebral sinus thrombosis. *Stroke* 1999; 30:484-8.
54. Preter M, Tzourio C, Ameri A, Bousser MG. Long-term prognosis in cerebral venous thrombosis: follow-up of 77 patients. *Stroke* 1996; 27:243-6
55. deVeber G, Adams M. on behalf of the Canadian Pediatric Ischemic Stroke Study Group. Neonatal sinovenous thrombosis and arterial ischemic stroke: prospective study of clinical and radiographic features. *Can J Neurosci* 1996; 23 (Suppl 1):S16.
56. Zilkha A, Stenzler SA, Lin JH. Computed tomography of normal and abnormal superior sagittal sinus. *Clin Radiol* 1982; 33:415-25.
57. Anne G.Osborn. Venous Occlusions. In: *Diagnostic Neuroradiology: Stroke*. U.S.A: Harcourt Brace and Company Asia PTE LTD, Mosby - Year Book; 2004:385-395.
58. Ayanzen RH, Bird CR, Keller PJ, McCully FJ, Theobald MR. Cerebral MR Venography: Normal Anatomy and Potential Diagnostic Pitfalls. *AJNR Am J Neuroradiol* 2000; 21:74-78.
59. RR Ozsvath, OS Casey, ES Lustrin, RA Alberico. Cerebral venography: Comparison of CT and MR projection venography. *AJR*, tt 169:1699-1707.

60. deVeber G, Andrew M. Canadian Pediatric Ischemic Stroke Study Group: cereb  
sino venous thrombosis in children. *N Engl J Med* 2001; 345:417- 23.
61. Bezinque SL, Slovis TL, Touchette AS. Characterization of superior sagittal  
sinus blood flow velocity using color flow Doppler in neonates and infants.  
*Pedia Radio* 1995; 25:175-9.
62. Govaert P, Voet D, Achten E. Noninvasive diagnosis of superior sagittal sinus  
thrombosis in a neonate. *Am J Perinatal* 1992; 9: 201- 4.
63. Tsao PN, Lee WT, Peng SF. Power Doppler ultrasound imaging in neonatal  
cerebral venous sinus thrombosis. *Pediatr Neural* 1999; 21: 652-5
64. Benamer HT, Bone I. Cerebral venous thrombosis: anticoagulants or  
thrombolytic therapy. *J neural Neurosurg Psychiatry* 2000; 69:427-30.
65. Brucker AB, Vollert-Rogenhofer H, Wagner M. Heparin treatment in acute!  
cerebral sinus venous thrombosis: a retrospective clinical and MR analysis of  
42 j cases. *Cerebrovasc Dis* 1998; 8:331- 7.
66. Chaloupka JC, Mangla S, Huddle DC. Use of mechanical thrombolysis via  
microballoon percutaneous transluminal angioplasty for the treatment of acute  
dural sinus thrombosis: case presentation and technical report. *Neurosurgery*  
1999; 45:650- 6.

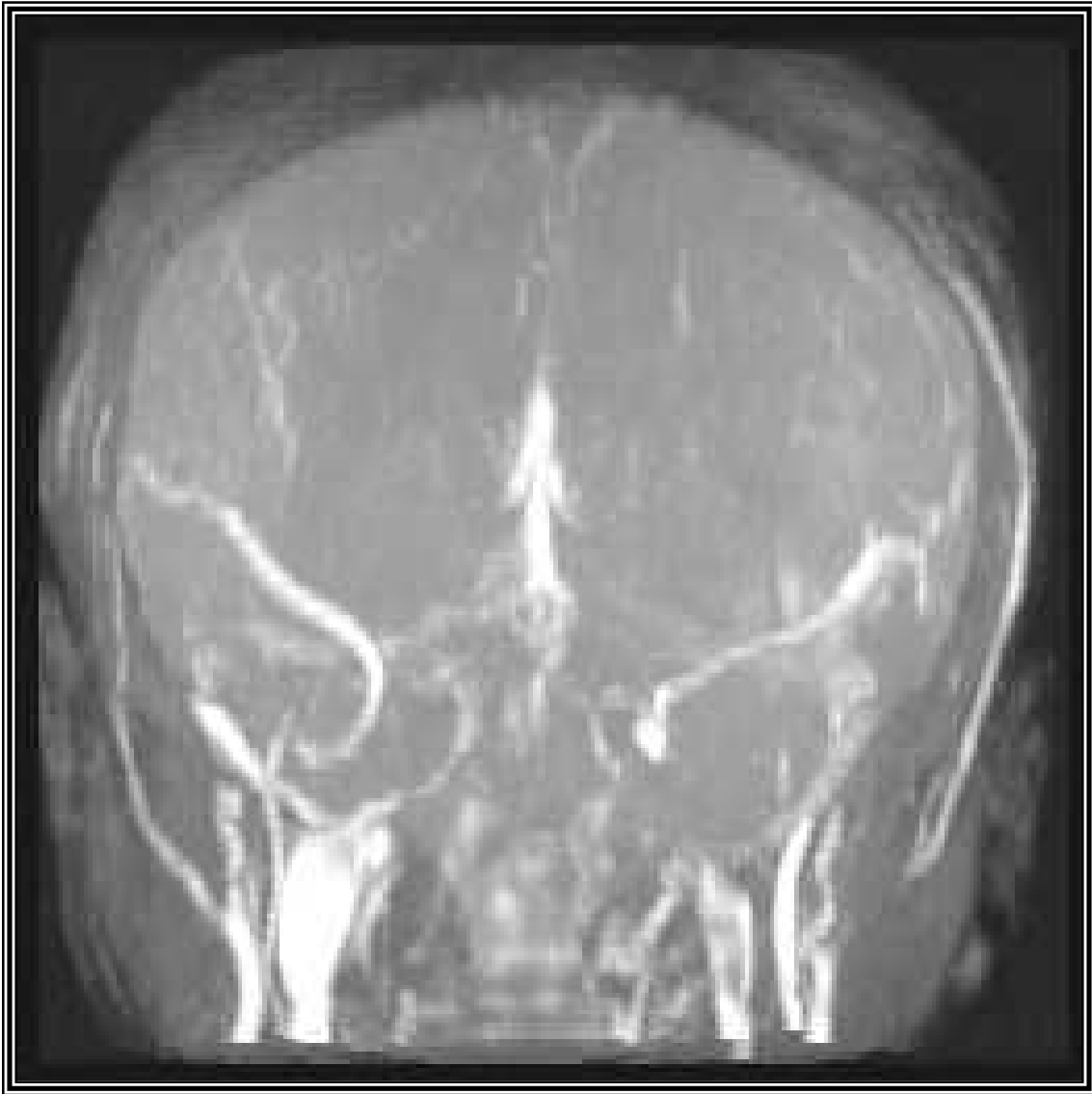
67. Ekseth K, Bostrom S, Vegfors M. Reversibility of severe sagittal sinus thrombosis with open surgical thrombectomy combined with local infusion of tissue plasminogen activator: technical case report. *Neurosurgery* 1998; 43: 960-5.
68. Stam J, Lensing AW, Vermeulen M. Heparin treatment for cerebral venous and sinus thrombosis. *Lancet* 1991; 338:597-600.
69. Bousser MG. Cerebral venous thrombosis: nothing, heparin, or local thrombolysis. *Stroke* 1999; 30:481-3.
70. Barnwell SL, Higashida RT, Halbach VV. Direct endovascular thrombolytic therapy for dural sinus thrombosis. *Neurosurgery* 1991; 28:135- 42.
71. Higashida RT, Helmer E, Halbach VV. Direct thrombolytic therapy for superior sagittal sinus thrombosis. *AJNR Am J Neuroradiol* 1989; 10(Suppl 5): S4-6.
72. Horowitz M, Purdy P, Unwin H. Treatment of dural sinus thrombosis using selective catheterization and urokinase. *Ann Neurol* 1995; 38:58-67.
73. Holder CA, Bell DA, Lundell AL. Isolated straight sinus and deep cerebral venous thrombosis: successful treatment with local infusion of urokinase. Case report. *J Neurosurg* 1997; 86:704- 7.

74. Spearman MP, Jungreis CA, Wehner JJ. Endovascular thrombolysis in deep cerebral venous thrombosis. *AJNR Am J Neuroradiol* 1997; 18:502- 6.
75. Tsai FY, Higashida RT, Matovich V. Acute thrombosis of the intracranial dural sinus: direct thrombolytic treatment. *AJNR Am J Neuroradiol* 1992; 13:1137-41.
76. Kim SY, Suh JH. Direct endovascular thrombolytic therapy for dural sinus thrombosis: infusion of alteplase. *AJNR Am J Neuroradiol* 1997; 18:639- 45.
77. Eisenberg PR, Sherman LA, Tiefenbrunn AJ. Sustained fibrinolysis after administration of t-PA despite its short half-life in the circulation. *Thromb Haemost* 1987; 57:35-40.
78. Sobel BE, Gross RW, Robison AK. Thrombolysis, clot selectivity, and kinetics. *Circulation* 1984; 70:160- 4.
79. Frey JL, Muro GJ, McDougall CG. Cerebral venous thrombosis: combined intrathrombus rtPA and intravenous heparin. *Stroke* 1999; 30:489-94.
80. So"derman M, Johnsson H, Ericson K. Acute sinus thrombosis in a child with antibodies against cardiolipins. *Intervent Neuroradiol* 1996; 2:143 – 8
81. Vilela P, Willinsky R, Terbrugge K. Treatment of intracranial venous occlusive disease with sigmoid sinus angioplasty and stent placement in a case of infantile multifocal dural arteriovenous shunts. *Intervent Neuroradiol* 2001; 7:51- 60.

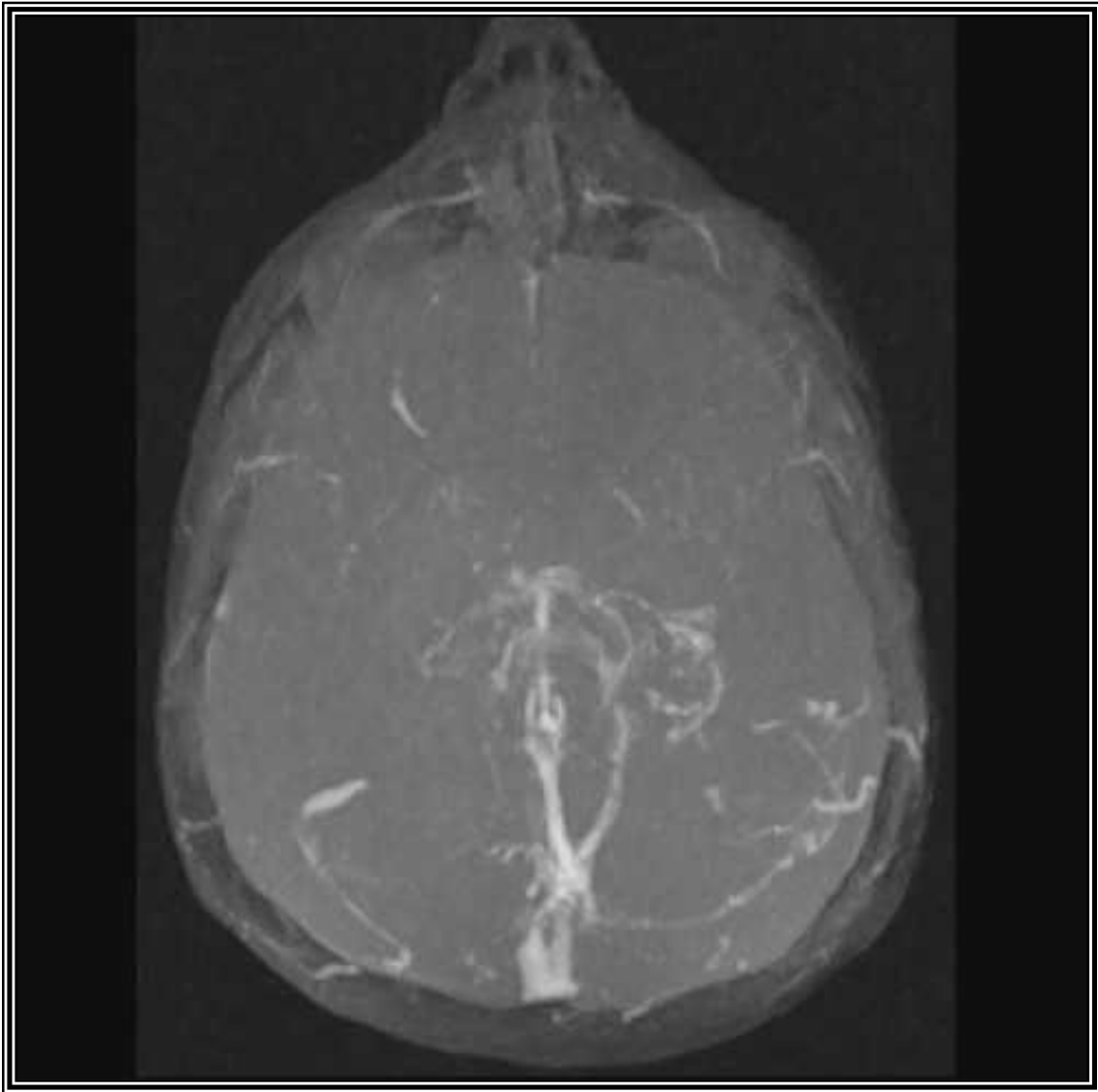
82. Sanchette PC, Dhamija RM. Peripartum cerebral venous thrombosis. JAPI 1992 ; 40(10) : 664-666.
83. Parikh PM, Sukhthankar PR. Cerebral Venous Thrombosis. JAPI 1987 ; 35(5) : 349-352.
84. MG Bousser, HJM Barnett. Cerebral Venous Thrombosis. Chapter 24, stroke 3rd Edition, London 2005 ; 517-537.
85. Deschiens, Marie Anne. Coagulation studies, Factor V Leiden, and Anticardiolipin antibodies in 40 cases of cerebral venous thrombosis. Stroke 1996 ; 27(10) : 1724-1730.
86. Toole F. James Venous thrombosis. Cerebrovascular disorders, 5<sup>th</sup> edition, chapter 24, Brain veins and their diseases Italy 2003 ; 488-507.
87. Cantu C, Barinagarrementaria F. Cerebral venous thrombosis associated with pregnancy and puerperium ; Review of 67 cases. Stroke 24 ; 1880-1993
88. Einhaupi KM, Villringer A, Meister W. Heparin treatment in sinus venous thrombosis. Lancet 1991 ; 338-597.
89. Daif, Abdulkar MD. Cerebral venous thrombosis in Adults. A study of 40 cases from Saudi Arabia. Stroke 1995 ; 26 : 1193-1195.

90. Panagariya A, Maru A. Cerebral venous thrombosis in pregnancy and puerperium. A prospective study JAPI 1997 ; 45(11) : 857-859.
91. Villringer A, Meraein S, Einhaupi KM. Treatment of sinus venous thrombosis, beyond the recommendation of anticoagulation. J Neuroradiol 1994 ; 21 : 72.
92. Ameri A, Bousser MG. Cerebral venous thrombosis. Neurol Clin 1992 ; 10 : 876.
93. Yeolelar ME. Cerebral venous thrombosis – Editorial JAPI 1990 ; 38(5) : 321-322.
94. Van Swieten JC, Koudsteal PJ. Interobserver agreement for the assessment of handicap in stroke patients. Stroke 1988 ; 19(5) : 604-607.
95. Peter M, Tzourio C. Long term prognosis in cerebral venous thrombosis. A follow up of 77 patients. Stroke 1996; 27 : 243.

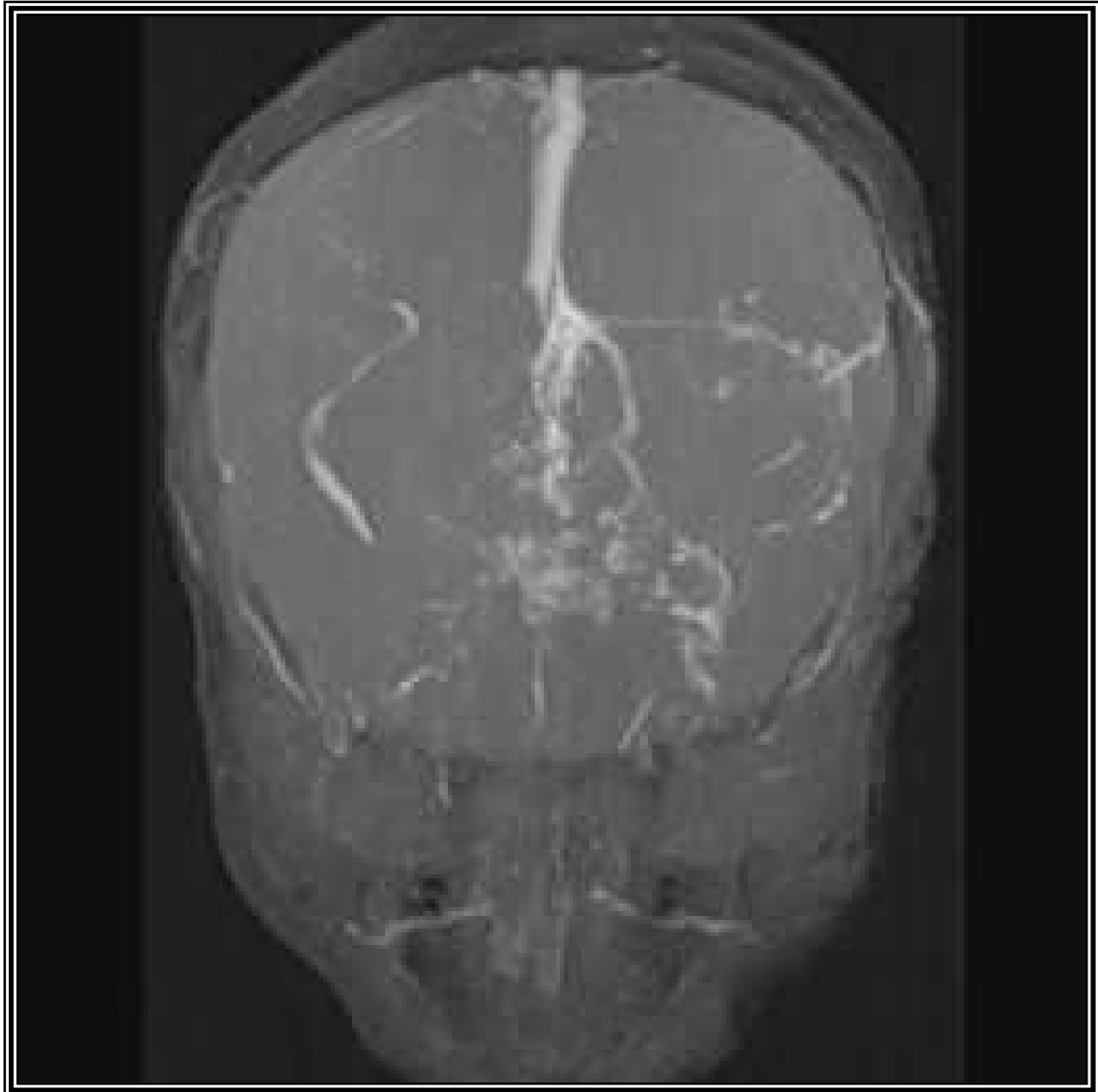
**NEUROIMAGES**



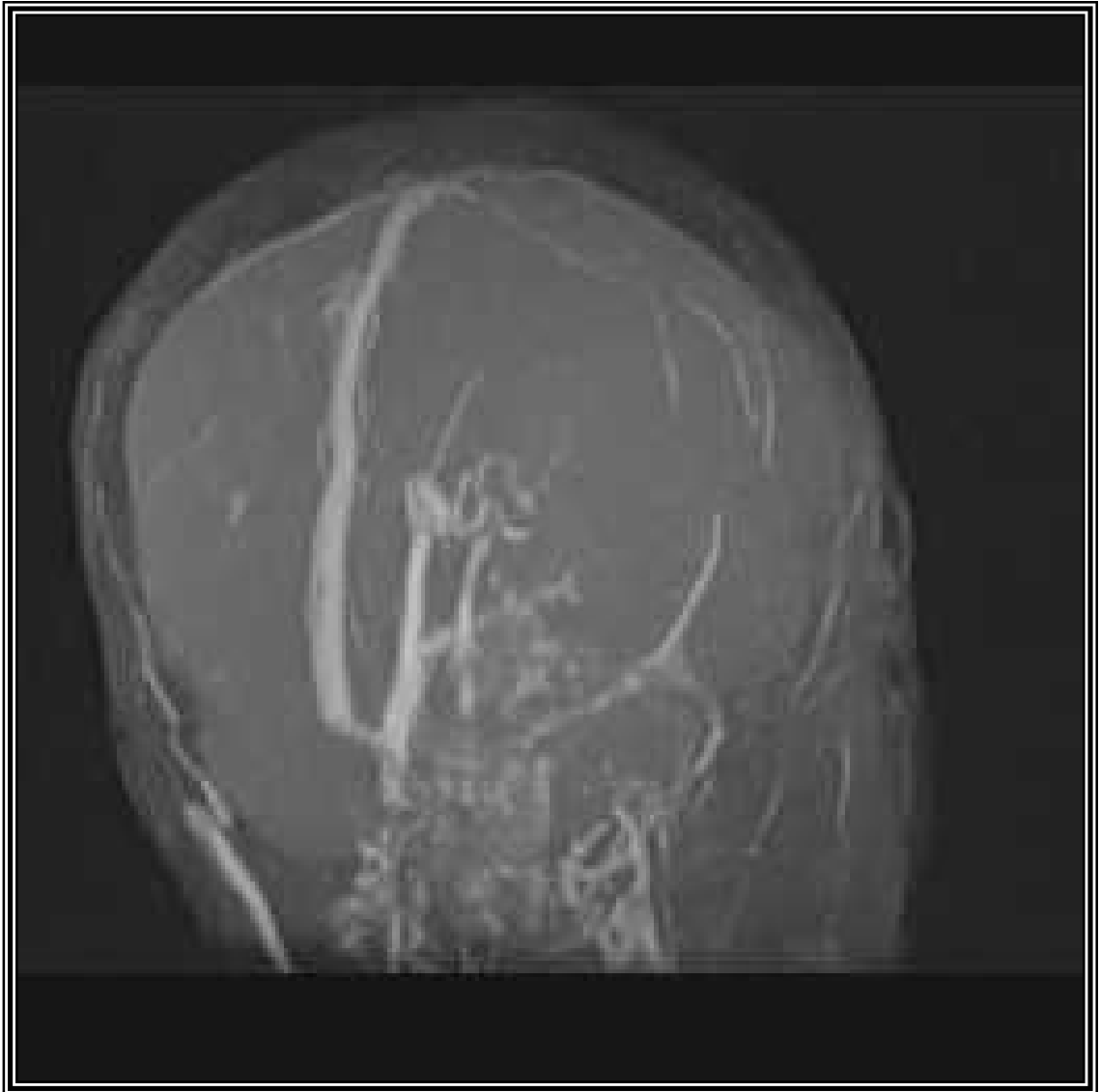
**Cerebral venous thrombosis involving  
Superior sagittal sinus**



**Cerebral venous thrombosis involving  
Bilateral transverse sinuses & Superior sagittal sinuses**



**Cerebral venous thrombosis involving  
Bilateral transverse sinuses & sigmoid sinuses**



**Cerebral venous thrombosis involving  
Bilateral transverse sinuses & inferior saggital sinuses**

**PROFORMA**

**“DIAGNOSTIC EFFICACY OF MAGNETIC RESONANCE  
VENOGRAPHY IN PATIENTS OF CEREBRAL VENOUS  
THROMBOSIS - A CROSS SECTIONAL STUDY”.**

Patients Name :

I.P. No :

Age :

Sex :

Date of admission :

Date of discharge :

Religion :

Occupation :

Address :

**Details of present illness :** (Symptoms with duration and mode of onset)

- ❖ Headache
- ❖ Seizures
- ❖ Vomiting
- ❖ Altered sensorium
- ❖ Focal deficits
- ❖ Speech disorders
- ❖ Visual disturbances
- ❖ Dysphagia / Nasal regurgitation
- ❖ Fever

**Past history :**

- ❖ Any other Neurological illness :
- ❖ Hypertension
- ❖ Diabetes mellitus
- ❖ Ischaemic heart disease
- ❖ Stroke
- ❖ Recent delivery / recurrent abortions
- ❖ Deep vein thrombosis
- ❖ Tuberculosis

**Drug history :**

**Family history :**

- ❖ Hypertension
- ❖ Diabetes mellitus
- ❖ Ischaemic heart disease
- ❖ Stroke
- ❖ Recent delivery / recurrent abortions
- ❖ Arterial / Venous thrombosis

**Personal history :**

- ❖ Smoking
- ❖ Alcohol
- ❖ Tobacco chewing
- ❖ Exposure
- ❖ Use of OCPs
- ❖ Drugs

---

---

**General Physical Examination:**

➤ **Vital signs :**

- ❖ Pulse
- ❖ Blood pressure
- ❖ Respiratory rate
- ❖ Peripheral pulsations
- ❖ Carotid pulsations

➤ **Others :**

- ❖ Weight
- ❖ Temperature
- ❖ Pallor
- ❖ Icterus
- ❖ Cyanosis
- ❖ Clubbing
- ❖ Pedal edema
- ❖ Lymph nodes
- ❖ Bleeding diatheses
- ❖ Deformities
- ❖ Skin
- ❖ Subcutaneous nodules
- ❖ Neuro-cutaneous markers
- ❖ Joints

---

---

**CENTRAL NERVOUS SYSTEM EXAMINATION**

- ❖ Level of consciousness (Using Glasgow Coma scale)
- ❖ Orientation with Place / Time / Person
- ❖ Memory
  - Immediate
  - Recent
  - Remote
- ❖ Intelligence
- ❖ Speech and language
  - Spontaneous speech
  - Comprehension
  - Naming
  - Reading
  - Writing
  - Repetition
  - Calculation
- ❖ Hallucinations/Delusions
- ❖ Evidence of any hemineglect
- ❖ Right – Left orientation
- ❖ Insight
- ❖ Judgment
- ❖ Abstract thinking

---

---

**CRANIAL NERVES**

❖ I (Olfactory)

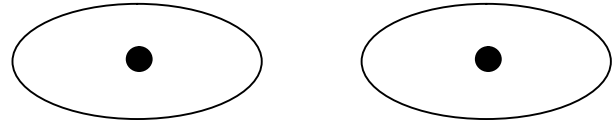
❖ II (Optic)

Visual acuity

Visual fields

Colour vision

Optic fundi



❖ III, IV, VI (Oculomotor, Trochlear and Abducent nerve)

Pupils

Right

Left

Size

Shape

Reaction

Direct

Indirect

Eye movements

Primary position

Range of movements

Accommodation

Saccades

Pursuit

Optokinetic nystagmus

Nystagmus

❖ V (Trigeminal nerve)

Sensations

Mastigatory muscles

❖ VI (Facial nerve)

❖ VIII (Vestibulocochlear nerve)

Hearing

Air

Bone

Calori test

Vestibulo-ocular reflex

❖ IX (Glossopharyngeal nerve)

❖ X (Vagus nerve)

❖ XI (Accessory nerve)

❖ XII (Hypoglossal nerve)

**MOTOR SYSTEM**

Attitude of limbs

Nutrition and bulk

Deformity

Involuntary movements

---

<b>Tone</b>	<b>Right</b>	<b>Left</b>
<b>Power</b>		
Neck		
Trunk		
Shoulder - Flexion		
	Extension	
	Abduction	
	Adduction	
Elbow -	Flexion	
	Extension	
Wrist -	Flexion	
	Extension	
Fingers - Flexion		
	Extension	
Small muscles		
	Hypothenar	
	Thenar	
	Interosii	
	Lumbricals	
Handgrip		
Hip -	Abduction	
	Adduction	

---

Flexion

Extension

Knee - Flexion

Extension

Ankle - Plantar flexion

Dorsiflexion

Toes - Flexion

Extension

Small muscles of feet

### **Coordination**

### **Abnormal movements**

### **Reflexes**

#### *Muscle stretch reflexes*

Biceps Supinator Triceps Finger Flexion Knee Ankle

Right

Left

Jaw Jerk

### **Release reflexes**

**Superficial reflexes**

Corneal

Conjunctival

Abdominal

Cremasteric

Plantars

**Gait**

**Sensory system**

Pain

Touch

Temperature

Vibration

Joint and position

Rombergism

**Cortical sensations**

Tactile localization

Tactile discrimination

Stereognosis

Graphesthesia

**Cerebellar signs**

Nystagmus

Dysarthria

Dysmetria

Hypotonia

Dysdiadokinesia

Rebound phenomenon

Intention tremor

Pendular knee jerk

Ataxia

Gait

**Signs of meningeal irritation**

Neck stiffness

Kernig's sign

Brudzinski's neck sign

Brudzinski's leg sign

**Other systems**

Cerebrovascular system

Respiratory system

Per abdomen

**Investigations**

- Serological
  - Anticardiolipin antibodies
- Lumbar puncture – CSF (As deemed necessary)
  - Cell type
  - Cell count
  - Protein
  - Sugar
  - Gram stain
  - ZN stain
  - India ink preparation
- Neuroimaging
  - MRI scan
  - MRV
- Fundus examination
  - Papilloedema
- Outcome at time of discharge (using modified rankin scale)
- Provisional diagnosis

**Provisional diagnosis**

Anatomical

Pathological

Etiology

**Final diagnosis**

Anatomical

Pathological

Etiology

## **INFORMED CONSENT**

**Objective and purpose of the study :** This is a study to detect the diagnostic efficacy of magnetic resonance venography in clinically suspected cases of cerebral venous thrombosis. The principal investigator of the study is Dr. Rekha Patil and the Co-investigator is Sr. Ahammed Kabeer. P. This study is intended to compare diagnostic efficacy of magnetic resonance venogram over magnetic resonance imaging in clinically suspected cases of cerebral venous thrombosis. The result of this study will help in better diagnose of cerebral venous thrombosis, which will benefit patients in future.

**Procedure :** If I agree to be a part of the study, I will be asked the relevant history and will be subjected to relevant clinical examination. I will also undergo investigations like : Complete blood count, Urine routine and microscopy examination, Renal function test, Magnetic resonance imaging and Magnetic resonance venogram.

**Risk and benefits :** I have been explained by investigators, that there are no potential risks involved in this study.

**Alternatives :** Taking part in this study is voluntary. I may choose not to take part in this study, or if I decide to take part I can later change my mind and withdraw from the study. My decision will not change the present or future health care or other services that I receive. The study doctor or sponsor may stop my participation in this

study any time. If I choose no to take part in this study I will receive standard treatment for patients with my condition.

**Privacy and confidentiality :** All information collected about me during the course of this study will be kept confidential to the extent permitted by law. The code numbers will identify me in this research record.

**Institutional / Sponsor policy :** Does not apply to this research.

**Financial incentives for participants :** I will not be charged any amount for investigations subjected to me. I will not receive compensation or reimbursement for taking part in this study.

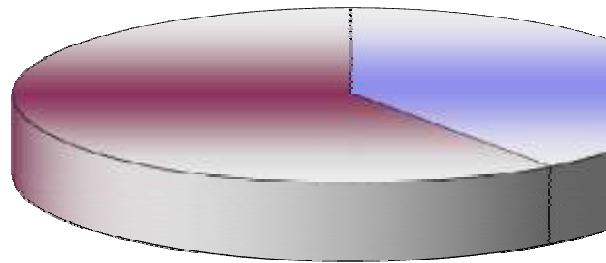
**Authorization to publish results :** Information from this study may be published but my identity will be confidential in any publication.

**Consent statement :** I voluntarily agree to take part in this study by signing below. I may withdraw at any time. I am not giving up any of any legal rights by signing this form. My signature below indicates that I have read, or it has been read to me, this entire consent form, and have had all my questions answered.



S. No.	Name	IP. No.	Age	Sex	Headache	Vomiting	Seizure					Altered Sensorium	Hemiplegia	Visual disturbances	Fever	Duration (days)	Motor Deficit		Papilledema	Cranial nerve involvement	Aphasia	Signs of meningeal	MRI finding	MRV findings	Sinus involved	Level consciousness	Outcome (MRS)	Causes
							Focal	General	Both	Right	Left																	
1	SP	227649	22	F	+	-	+	-	-	-	-	+	+	3	-	-	+	+	-	+	HVI (L)	SSS	1	9	0	Cerebral Malaria		
2	SR	231807	27	F	+	-	-	-	-	-	-	-	-	4	-	-	+	+	+	+	HVI (L)	SSS	1	4	0	Post Partum		
3	SRV	212045	30	F	+	+	-	+	-	-	-	+	-	5	+	-	+	+	+	+	CEO	SSS+TS+CV	3	11	5	Sepsis		
4	SV	247619	28	F	-	+	+	-	-	-	+	-	-	2	-	+	+	+	-	+	CEO	SgS	2	12	4	Sepsis		
5	SH	222948	26	F	+	+	+	-	-	-	-	-	-	3	-	+	+	-	+	+	CEO	SSS	1	5	0	Anti phospholipid AB		
6	GM	255995	35	M	+	+	+	+	+	-	+	-	-	3	+	-	+	-	-	+	CEO	CV+B/L TS+SS	3	14	5	Alcoholic		
7	MP	229250	28	M	+	-	-	-	-	-	+	-	-	3	+	-	+	-	-	+	CEO	SSS	1	6	0	Alcoholic		
8	SV	201305	24	F	+	-	-	-	-	-	-	-	-	2	-	-	+	-	-	+	CEO	SSS	1	15	0	Dehydration		
9	KB	199436	35	M	+	+	-	+	-	-	+	-	-	3	+	-	+	+	+	-	HVI (R)	SSS+CV+ICV+IJV	4	3	D(6)	APLABS		
10	RN	197393	25	M	+	+	-	+	-	-	+	-	-	3	-	-	+	+	+	-	HVI (R&L)	SSS+CV+ICV+IJV	4	3	D(6)	Primary Polycythemia		
11	SD	194126	24	F	+	+	+	-	-	-	+	-	-	4	+	-	+	+	-	-	HVI (L)	SSS+IJV+SgS+SS	4	5	D(6)	Undetermined		
12	SB	214107	32	F	+	-	+	-	-	-	+	-	-	4	+	-	+	+	-	-	HVI (L)	SSS+ISS+SgS	3	14	5	Undetermined		
13	MP	259071	25	F	+	-	+	+	-	-	+	-	-	4	-	-	+	+	-	+	HVI (R)	SSS+TS+SgS	3	12	4	Undetermined		
14	PK	256287	22	F	+	+	-	+	-	-	+	-	-	4	+	-	+	-	-	-	HVI (L)	SSS+ISS+SgS	3	13	0	Post Partum		
15	BG	259156	32	M	+	-	-	+	-	-	-	-	-	4	+	-	-	-	-	-	HVI (L)	SSS+TS+SgS	3	7	0	Alcoholic		
16	VH	249928	34	M	+	-	-	+	-	-	-	-	-	4	-	-	-	-	-	-	HVI (R)	SSS+TS+SgS	3	6	3	Alcoholic		
17	SV	232745	42	F	+	+	-	+	-	-	+	-	-	6	-	-	-	-	-	-	HVI (R)	SSS+TS+SgS	3	8	0	Post Partum		
18	SP	228591	43	F	+	-	-	+	-	-	-	-	-	6	-	-	-	-	-	-	HVI (R)	SS+SS	2	5	2	Post Partum		
19	RP	227735	55	F	+	-	-	+	-	-	+	-	+	8	-	-	-	-	-	-	HVI (R)	CV+ICV	2	13	2	Dehydration		
20	MP	1224815	50	F	+	-	-	-	-	-	+	-	+	7	-	-	-	-	-	-	HVI (R)	ICV+VOG	2	15	2	Dehydration		
21	YP	224069	58	M	+	-	-	-	-	-	-	-	-	7	-	-	-	-	-	-	HVI (R)	ICV+VOG	2	15	1	Dehydration		
22	SB	219045	51	M	+	+	-	+	-	-	+	-	-	7	-	-	-	-	-	-	NHVI (L)	SgS+TS	2	13	1	Mastoiditis		
23	GB	223878	53	M	+	+	-	-	-	-	+	-	+	7	-	-	-	-	-	-	NHVI (L)	SgS+CS	2	13	1	Mastoiditis		
24	MK	231745	54	M	+	+	-	-	-	-	+	-	-	3	-	-	-	-	-	-	NHVI (L)	SgS+TS	2	15	1	Alcoholics		
25	AH	215907	18	M	+	-	-	-	-	-	-	-	-	15	-	-	-	-	-	-	NHVI (R)	SSS	1	15	0	Undetermined		
26	TS	215353	18	F	+	+	-	-	-	-	+	-	-	4	-	-	-	-	-	-	NHVI (L)	TS	1	15	0	Undetermined		
27	GD	204805	20	F	+	+	-	-	-	-	+	-	-	12	-	-	-	-	-	-	NHVI (R)	TS	1	15	0	OCP		
28	VG	223228	16	F	+	-	-	-	-	-	-	-	-	11	-	-	-	-	-	-	NHVI (L)	SSS	1	15	0	Undetermined		
29	SP	217408	17	F	+	+	-	-	-	-	+	-	-	12	-	-	-	-	-	-	NHVI (R)	TS	1	15	0	Undetermined		
30	AP	205256	65	M	+	-	-	-	-	-	-	-	-	12	-	-	-	-	-	-	NHVI (R)	SSS	1	15	0	Undetermined		

**Graph 1 : Showing Sex wise distribution of cerebral venous thrombosis**

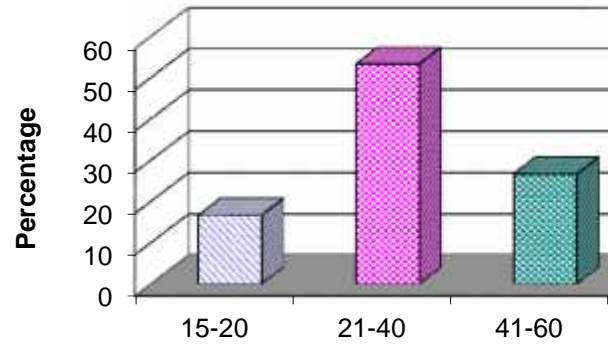


patients with




- ▣ Males
- ▣ Females

**Graph 2 : Showing Age wise distribution of cerebral venous thrombosis**

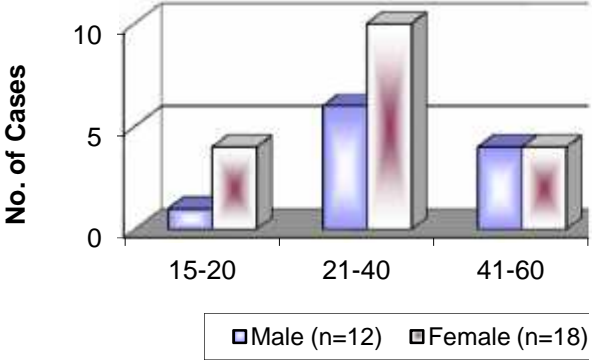


patients with

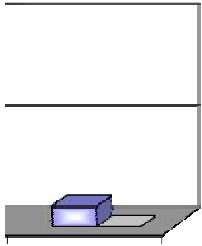


>60

**Graph 3 : Showing Age & Sex wise distributi  
with CVT**



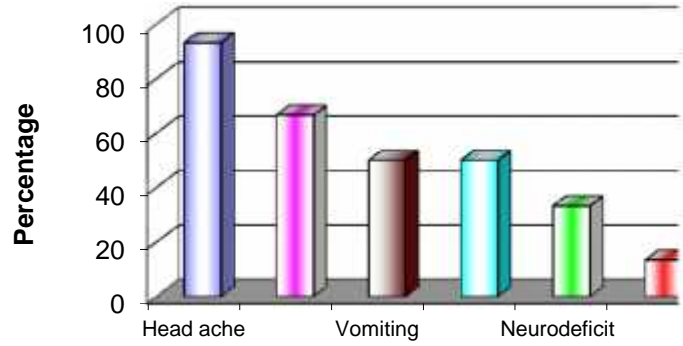
**ution of the patients**




> 60



**Graph 4 : Showing distribution of symptoms in CV**

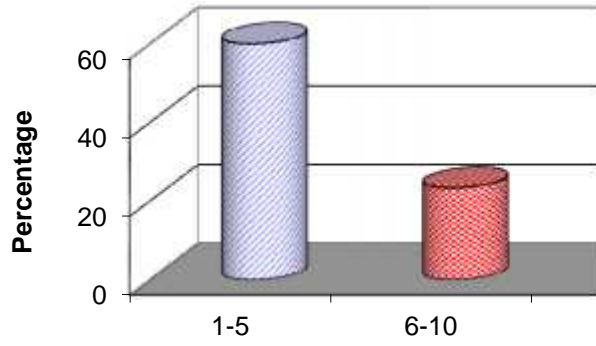


## T patients

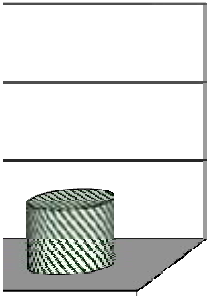


Visual  
disturbances

**Graph 5 : Showing Duration of symptoms prior patients with CVT**

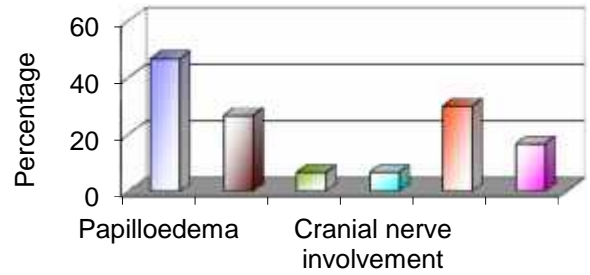


or to admission in



11-15

**Graph 6 : Showing distribution of patients based on signs in CVT**

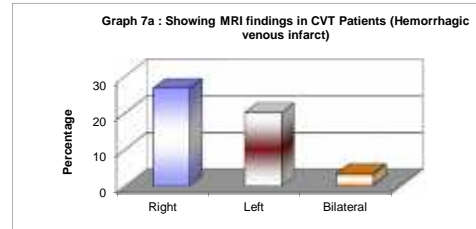


Signs of meningeal irritation	30
Apathia	16.6

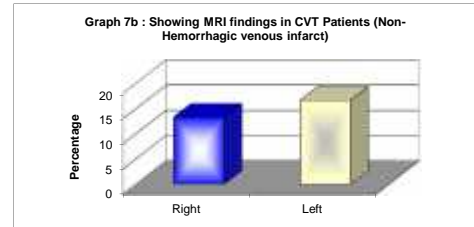
**n the signs**

|

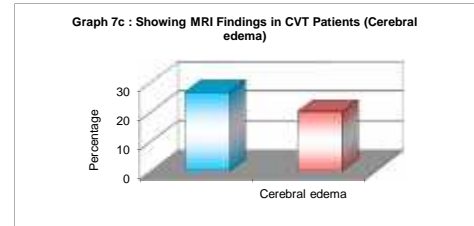
	%
Right	26.66
Left	20
Bilateral	3.33



	%
Right	13.33
Left	16.66

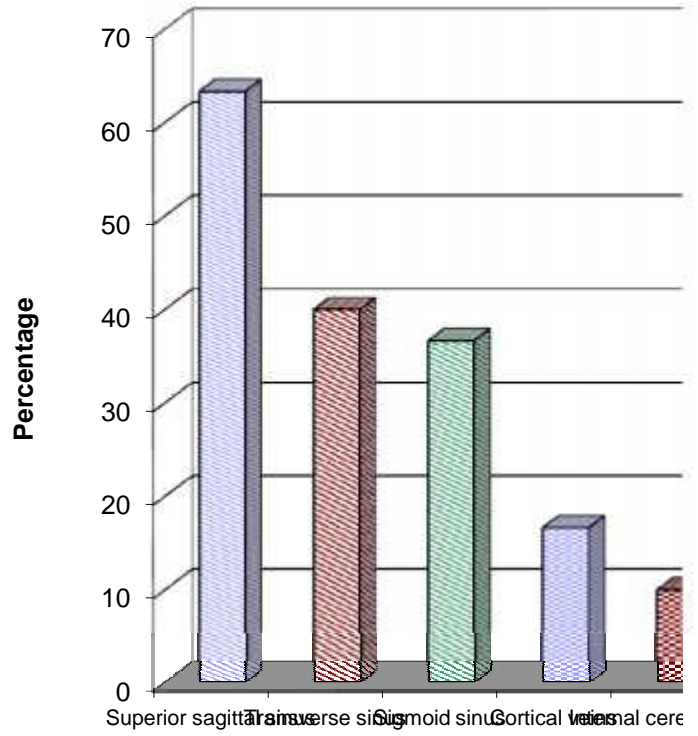


	%
Cerebral edema	26.66
Cerebral edema	20

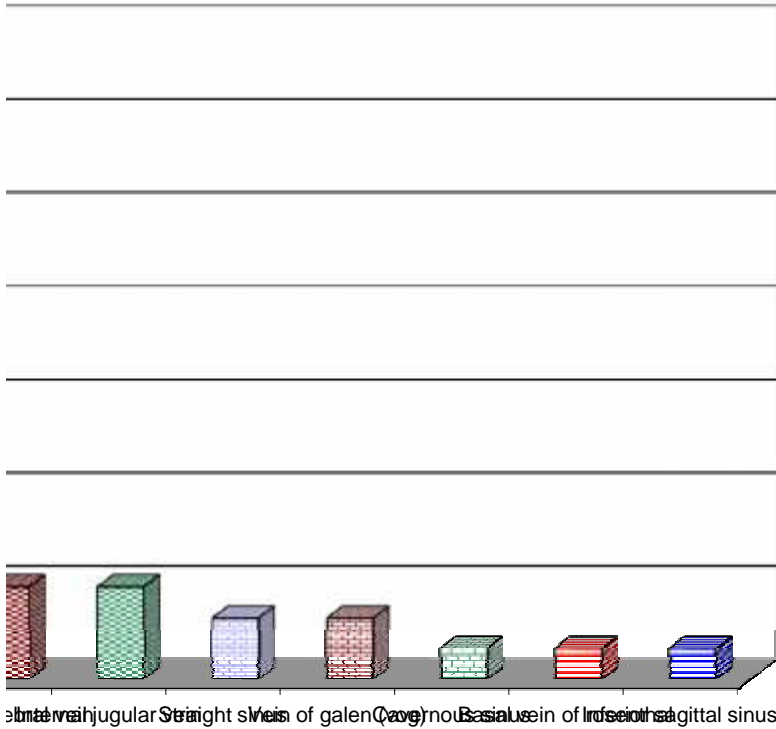


**Percent**

**Graph 8 : Showing MRV find**

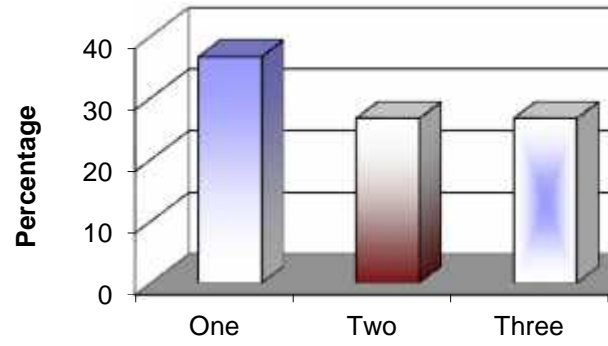


ding in patients with CVT (Thrombosis)

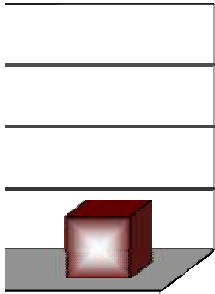


Internal jugular vein, Straight sinus, Sinus of galen (avg), Cavernous sinus, Basilar vein of Irosio, Internal sagittal sinus

**Graph 9 : Distribution of patients with CVT de  
number of sinuses involved**



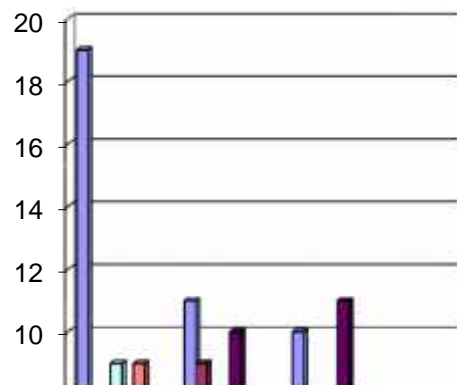
pending on the

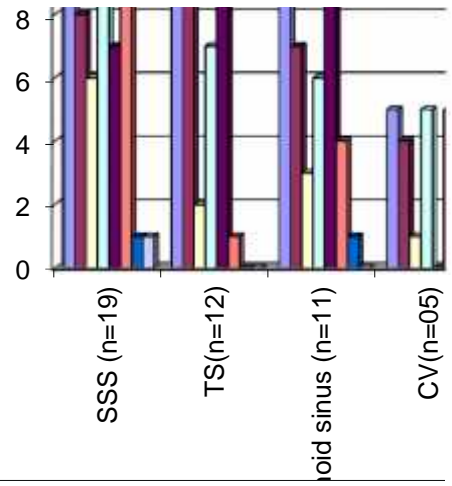


Four

	Headache( n=28)	Vomiting (n=15)	Focal seizure (8)	Generalize d seizure (17)
SSS (n=19)	19	8	6	9
TS(n=12)	11	9	2	7
Sigmoid sinus (n=11)	10	7	3	6
CV(n=05)	5	4	1	5
ICV(n=03 )	3	2	0	3
IJV (n=03)	3	3	1	2
Vog(n=02 )	2	0	0	0
ISS(n=01)	1	0	1	0
CS(n=01)	1	0	0	0
BV of R (n=01)	1	1	0	1
SS(n=02)	2	1	1	1

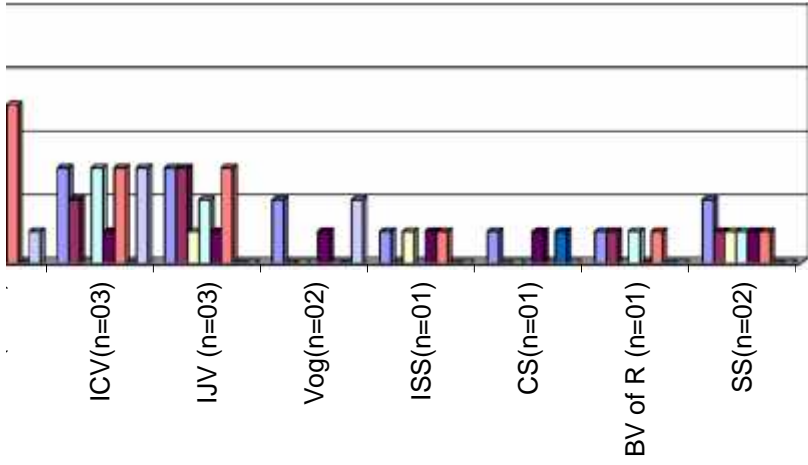
**Graph 10 : Showing Correlatio**





■ Headache(n=28)      ■ Vomiting (n=15)  
 ■ Altered sensorium (n=15)      ■ Hemiparesis (n=15)





n=15      □ Focal seizure (8)      □ Generalized seizure (17)  
 sis (n=10)      ■ Visual disturbance (n=2)      □ Fever (n=4)

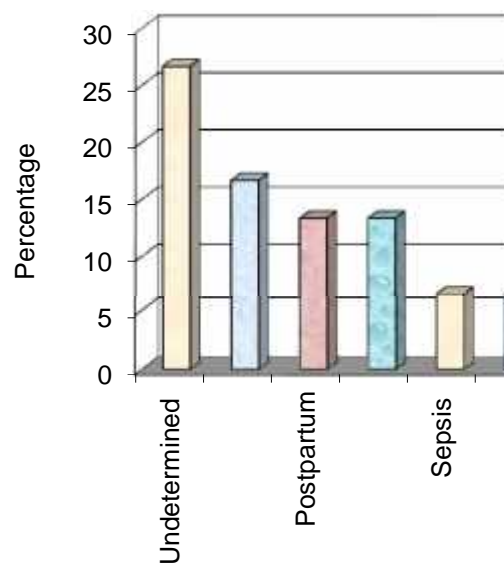
---

<b>Etiology</b>	<b>Percent age (%)</b>
-----------------	----------------------------

Undetermined	26.66
--------------	-------

Alcohol	16.66
---------	-------

**Graph 11 : Showing distribution of patients**



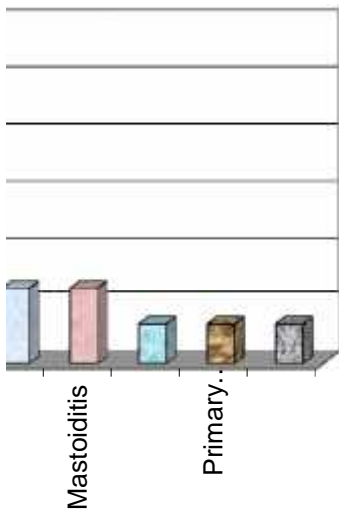
polycythemia

Cerebral	3.33
----------	------

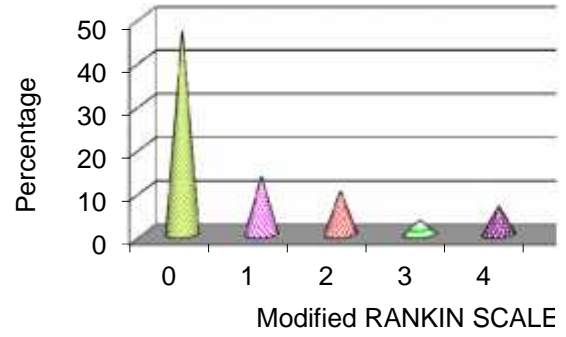
malaria

---


s depending on the aetiology



**Graph 12 : Showing outcome of the CVT patient discharge (as per modified RANKIN :**



nts at the time of  
SCALE)

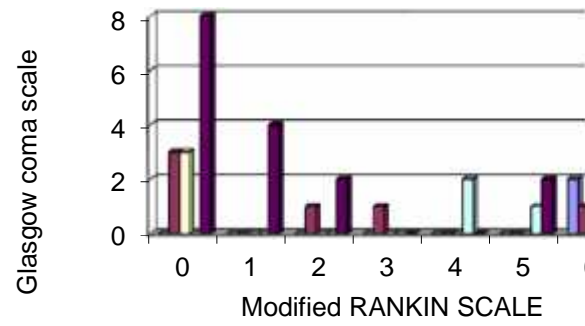


5

6

⋮

**Graph 13 : Correlation of Glasgow coma scale with outcome in CVT patients**



**e at admission**



- 0 - 3
- 4 - 6
- 7 - 9
- 10 - 12
- 13-15

	4	5	6
0	0	0	2
0	0	0	1
0	0	0	0
2	1	0	0
0	2	0	0

**KEYS TO MASTER CHART**

CVT	Cerebral venous thrombosis
MRS	Modified rankin scale

**MRI SCAN FINDINGS**

HVI (L)	Hemorrhagic venous infarct (Left)
HVI (R)	Hemorrhagic venous infarct (Right)
HVI (R&L)	Hemorrhagic venous infarct (Bilateral)
NHVI(L)	Non-hemorrhagic venous infarct (Left)
NHVI(R)	Non-hemorrhagic venous infarct (Right)

**MRV FINDINGS**

SSS	Superior sagittal sinus
TS	Transverse sinus
SgS	Sigmoid sinus
CV	Cortical vein
ICV	Internal cerebral vein
IJV	Internal jugular vein
SS	Straight sinus
ISS	Inferior sagittal sinus
CS	Cavernous sinus
VOG	Vein of galen
BV of R	Basal vein of Rosenthal

**Level of consciousness on admission (using Glasgow coma scale)**

<b>RESPONSE</b>	<b>SCORE</b>
<b>EYES OPEN</b>	
Spontaneous	4
To speech	3
To pain	2
Absent	1
<b>VERBAL</b>	
Converses / oriented	5
Converses / Disoriented	4
Inappropriate	3
Incomprehensible	2
Absent	1
<b>MOTOR</b>	
Obeys	6
Localizes pain	5
Withdraws (Flexion)	4
Decorticate (Flexion) Rigidity	3
Decerebrate (Extension) rigidity	2
Absent	1

**OUTCOME (USING MODIFIED RANKIN SCALE)**

<b>Score</b>	<b>Description</b>
0	No symptoms at all
1	No significant disability despite symptoms: able to carry out all usual duties and activities.
2	Slight disability: unable to carry out all previous activities but able to look after own affairs without assistance
3	Moderate disability: requiring some help, but able to walk without assistance
4	Moderately severe disability : unable to walk without assistance and unable to attend own bodily without assistance.
5	Severe disability : bedridden, incontinent and requiring constant care and attention
6	Dead